This is a digital copy of a book that was preserved for generations on library shelves before it was carefully scanned by Google as part of a project to make the world's books discoverable online.

It has survived long enough for the copyright to expire and the book to enter the public domain. A public domain book is one that was never subject to copyright or whose legal copyright term has expired. Whether a book is in the public domain may vary country to country. Public domain books are our gateways to the past, representing a wealth of history, culture and knowledge that's often difficult to discover.

Marks, notations and other marginalia present in the original volume will appear in this file - a reminder of this book's long journey from the publisher to a library and finally to you.

Usage guidelines

Google is proud to partner with libraries to digitize public domain materials and make them widely accessible. Public domain books belong to the public and we are merely their custodians. Nevertheless, this work is expensive, so in order to keep providing this resource, we have taken steps to prevent abuse by commercial parties, including placing technical restrictions on automated querying.

We also ask that you:

+ *Make non-commercial use of the files* We designed Google Book Search for use by individuals, and we request that you use these files for personal, non-commercial purposes.
+ *Refrain from automated querying* Do not send automated queries of any sort to Google's system: If you are conducting research on machine translation, optical character recognition or other areas where access to a large amount of text is helpful, please contact us. We encourage the use of public domain materials for these purposes and may be able to help.
+ *Maintain attribution* The Google "watermark" you see on each file is essential for informing people about this project and helping them find additional materials through Google Book Search. Please do not remove it.
+ *Keep it legal* Whatever your use, remember that you are responsible for ensuring that what you are doing is legal. Do not assume that just because we believe a book is in the public domain for users in the United States, that the work is also in the public domain for users in other countries. Whether a book is still in copyright varies from country to country, and we can't offer guidance on whether any specific use of any specific book is allowed. Please do not assume that a book's appearance in Google Book Search means it can be used in any manner anywhere in the world. Copyright infringement liability can be quite severe.

About Google Book Search

Google's mission is to organize the world's information and to make it universally accessible and useful. Google Book Search helps readers discover the world's books while helping authors and publishers reach new audiences. You can search through the full text of this book on the web at `http://books.google.com/`

BOSTON
MEDICAL LIBRARY
8 THE FENWAY.

TRANSACTIONS

OF THE

AMERICAN OPHTHALMOLOGICAL SOCIETY.

Vol. XI.

HARTFORD:
PUBLISHED BY THE SOCIETY
1908.

BOSTON MEDICAL
MAR 12 1909
LIBRARY.
CATALOGUED
MAR 12 1909
J. F. B.

TRANSACTIONS

OF THE

AMERICAN

OPHTHALMOLOGICAL SOCIETY.

Forty-second Annual Meeting.

NEW YORK CITY, 1906.

Vol. XI, Part I.

HARTFORD:
PUBLISHED BY THE SOCIETY.
1906.

5717

BOSTON MEDICAL
JAN 26 1907
LIBRARY.

THE CASE, LOCKWOOD & BRAINARD CO., PRINTERS, HARTFORD, CONN.

CATALOGUED
JAN 26 1907
E. H. B.

BOSTON MEDICAL
JAN 26 1907
LIBRARY.

TABLE OF CONTENTS

Page

Members of the society, ... 1
Minutes of the forty-second annual meeting, ... 9
Silver preparations in conjunctival disease; Dr. Myles Standish, . 16
An experimental study on the bactericidal power of various silver preparations; Dr. G. S. Derby, ... 21
The immersion treatment with argyrol of the purulent ophthalmias; Dr. H. Bruns, ... 28
Operation for removal of nasal epithelioma followed by panophthalmitis; Dr. P. Callan, ... 57
Preliminary note on enucleation of eyeball under local anesthesia; Drs. Bruns and Robin, ... 62
Unilateral rotary nystagmus; Dr. A. Duane, ... 63
A tangent-plane for accurately mapping scotomata and the fields of fixation and single vision, and for indicating the precise position of double images in paralysis; Dr. A. Duane, . . . 67
The ocular symptoms in a case of tumor of the pituitary body; Dr. H. F. Hansell, ... 71
Keratitis tuberculosa relieved by tuberculin injections; Dr. S. Lewis Ziegler, ... 78
Concerning the signs in the retina of persistent high arterial tension, and their diagnostic and prognostic import; Dr. G. E. de Schweinitz, ... 87
Retinitis proliferans with development of a system of blood-vessels upon the optic nerve; Dr. W. B. Marple, ... 101
Case of congenital cyst of the orbit with microphthalmos; Dr. A. Quackenboss, ... 106
Multiple myeloma, with involvement of the orbit; Dr. A. Quackenboss, ... 113
Transient myopia due to trauma; Dr. T. R. Pooley, ... 120
A study of the nativity, sex, age, occupation, and social condition of 3,436 cases of senile cataract operated upon at the Wills Hospital in Philadelphia; Dr. C. A. Oliver, ... 123
Pathological report on Dr. May's case of microphthalmos with upper-lid cyst; Dr. Ward A. Holden, ... 130
Concerning siderosis bulbi; Dr. C. J. Kipp, ... 132
Case of invagination cyst of the cornea and of anterior chamber; Dr. C. J. Kipp, ... 149

Page

Extraction of cataract in the capsule; Dr. F. E. Cheney, . . . 153
Extraction of lens in capsule as a method of procedure in cases of immature cataract; Dr. Myles Standish, ... 165
Course and treatment of simple cyclitis; Dr. E. S. Thomson, . . 170
Case of secondary hypernephroma of the iris and ciliary body; Dr. B. K. Chance, ... 178
Case of sarcoma of choroid, with observation on the use of the transilluminator; Dr. W. B. Marple, ... 193
Ulceration and destruction of cornea by bacillus pyocyaneus; Dr. P. A. Callan, ... 201
Bacillus pyocyaneus, its virulence in the eye, its longevity and immunity from it; Dr. A. Ewing, ... 204
Optic neuritis after injury or disease of the anterior half of the eyeball; Dr. A. Knapp, ... 215
Case of pronounced inward and downward squint in *near* vision with binocular fixation and normal muscle-balance in *distant* vision; Dr. S. Theobald, ... 218
Report of cases of polio-encephalitis superior; Dr. W. A. Holden, . 220
An improved electric ophthalmoscope; Dr. W. B. Marple, . . . 225
Plexiform neuroma of orbit; Dr. H. Knapp, ... 229
Case of steel in the eyeball which the Haab magnet failed to remove; Dr. L. H. Taylor, ... 230
The modern operation in frontal sinus disease affecting the orbit with two cases; Dr. E. Gruening, ... 234
Bacteriological examinations of the conjunctival sac in typhoid fever and in pneumonia; Dr. R. L. Randolph, ... 238
Case of congenital dislocation of both lenses, — attempted removal by absorption resulting in failure followed by extraction; Dr. S. D. Risley, ... 245

10981

MEMBERS

OF THE

American Ophthalmological Society. 1906-1907.

ACTIVE MEMBERS.

The (*) indicates *Associates*.

NAME.	RESIDENCE.	PLACE.
Dr. A. E. ADAMS,	44 Grand Street,	Newburg, N. Y.
Dr. J. L. ADAMS,	38 East 51st Street,	New York, N. Y.
Dr. L. A. W. ALLEMAN,	64 Montague Street,	Brooklyn, N. Y.
Dr. A. N. ALLING,	199 York Street,	New Haven, Conn.
Dr. G. W. ALLYN,	515 Penn Avenue,	Pittsburg, Pa.
Dr. A. ALT,	3036 Locust Street,	St. Louis, Mo.
†Dr. J. A. ANDREWS,	107 Madison Avenue,	New York, N. Y.
Dr. S. C. AYRES,	4 West 7th Street,	Cincinnati, Ohio.
*Dr. JAS. H. BELL,	Moore Building,	San Antonio, Texas.
Dr. H. W. BRADFORD,		Wolfboro, N. H.
*Dr. GUSTAVE E. BRUÈRE,	413 Oregonian Building,	Portland, Oregon.
*Dr. H. D. BRUNS,	211 Camp Street,	New Orleans, La.
Dr. CHARLES S. BULL,	47 West 36th Street,	New York, N. Y.
*Dr. W. K. BUTLER,	1207 M St. N. W.,	Washington, D. C.
*Dr. W. GORDON M. BYERS,	346 Mountain Street,	Montreal, Canada.
Dr. PETER A. CALLAN,	35 West 38th Street,	New York, N. Y.
Dr. F. P. CAPRON,	118 Angell Street,	Providence, R. I.
*Dr. W. M. CARHART,	252 Madison Avenue,	New York, N. Y.
Dr. W. H. CARMALT,	87 Elm Street,	New Haven, Conn.
Dr. JOHN T. CARPENTER, JR.,	1624 Walnut Street,	Philadelphia, Pa.
*Dr. BURTON K. CHANCE,	235 So. 13th Street,	Philadelphia, Pa.
Dr. H. B. CHANDLER,	34½ Beacon Street,	Boston, Mass.
*Dr. J. W. CHARLES,	509 Humboldt Building,	St. Louis, Mo.
Dr. WM. CHEATHAM,	303 West Chestnut Street,	Louisville, Ky.
Dr. F. E. CHENEY,	126 Commonwealth Avenue,	Boston, Mass.
Dr. J. H. CLAIBORNE,	34 West 36th Street,	New York City.
Dr. C. F. CLARK,	188 East State Street,	Columbus, Ohio.
Dr. DAVID COGGIN,	7 Chestnut Street,	Salem, Mass.
Dr. WM. G. CRAIG,	15 Fuller Building,	Springfield, Mass.
Dr. C. M. CULVER,	36 Eagle Street,	Albany, N. Y.
*Dr. R. J. CURDY,	614 Bank of Commerce Bldg.,	Kansas City, Mo.
Dr. C. W. CUTLER,	52 West 53d Street,	New York, N. Y.
Dr. W. S. DENNETT,	8 East 49th Street,	New York, N. Y.
Dr. HASKET DERBY,	182 Marlborough Street,	Boston, Mass.

† Temporarily residing at Santa Barbara, Cal.

Name.	Residence.	Place.
Dr. Richard H. Derby,	9 West 35th Street,	New York, N. Y.
Dr. Lewis S. Dixon,	232 Clarendon Street,	Boston, Mass.
Dr. Alexander Duane,	49 East 30th Street,	New York, N. Y.
Dr. J. B. Emerson,	20 East 30th Street,	New York, N. Y.
Dr. Arthur E. Ewing,	2670 Washington Avenue,	St. Louis, Mo.
Dr. T. H. Fenton,	1319 Spruce Street	Philadelphia, Pa.
Dr. George F. Fiske,	100 State Street,	Chicago Ill.
Dr. W. H. Fox,	1826 Jefferson Place,	Washington, D. C.
Dr. Percy Fridenberg,	60 East 58th Street,	New York, N. Y.
Dr. H. Friedenwald,	1029 Madison Ave.,	Baltimore, Md.
Dr. B. F. Fryer,	Cor. 9th and Cherry Streets,	Kansas City, Mo.
Dr. G. M. Gould,	1722 Walnut Street,	Philadelphia, Pa.
Dr. H. Y. Grant,	414 Delaware Avenue,	Buffalo, N. Y.
Dr. John Green,	2670 Washington Avenue,	St. Louis, Mo.
*Dr. Allen Greenwood,	101 Newbury Street,	Boston, Mass.
Dr. Emil Gruening,	36 East 57th Street,	New York, N. Y.
*Dr. C. W. Haddock,		Beverly, Mass.
Dr. G. W. Hale,	Wilcox Building,	Nashville, Tenn.
Dr. Wm. D. Hall,	138 Marlborough Street,	Boston, Mass.
Dr. H. F. Hansell,	1528 Walnut Street,	Philadelphia, Pa.
Dr. George C. Harlan,	1515 Walnut Street,	Philadelphia, Pa.
Dr. Herbert Harlan,	516 Cathedral Street,	Baltimore, Md.
Dr. David Harrower,	9 Elm Street,	Worcester, Mass.
Dr. N. D. Harvey,	262 Benefit Street,	Providence, R. I.
*Dr. H. H. Haskell,	34 Commonwealth Avenue,	Boston, Mass.
Dr. Gustavus Hay,	1 Hathaway Street,	Jamaica Plain, Mass.
Dr. Neil J. Hepburn,	317 West 23d Street,	New York, N. Y.
Dr. Ward Holden,	43 West 48th Street,	New York, N. Y.
*Dr. C. R. Holmes,	8 East 8th Street,	Cincinnati, Ohio.
Dr. E. E. Holt,	723 Congress Street,	Portland, Me.
Dr. Lucien Howe,	87 West Huron Street,	Buffalo, N. Y.
Dr. A. A. Hubbell,	212 Franklin Street,	Buffalo, N. Y.
Dr. D. W. Hunter,	80 West 40th Street,	New York, N. Y.
Dr. J. W. Ingalls,	874 Lafayette Avenue,	Brooklyn, N. Y.
Dr. E. E. Jack,	215 Beacon Street,	Boston, Mass.
Dr. Edward Jackson,	1434 Glenarm Street,	Denver, Col.
Dr. B. Joy Jeffries,	15 Chestnut St., Beacon Hill,	Boston, Mass.
Dr. W. B. Johnson,	170 Broadway,	Paterson, N. J.
*Dr. H. W. Kilburn,	192 Marlborough Street,	Boston, Mass.
Dr. Charles J. Kipp,	560 Broad Street,	Newark, N. J.
Dr. Arnold Knapp,	26 West 40th Street,	New York, N. Y.
Dr. H. Knapp,	26 West 40th Street,	New York, N. Y.
Dr. Carl Koller,	681 Madison Avenue,	New York, N. Y.
Dr. Chas. W. Kollock,	Cor. Wentworth & Com'g Sts.,	Charleston, S. C.
Dr. W. E. Lambert,	47 West 38th Street,	New York, N.
*Dr. W. B. Lancaster,		Amherst, Mass.
*Dr. J. C. Lester,	179 Schermerhorn Street,	Brooklyn, N. Y.
Dr. F. N. Lewis,	616 Madison Ave. Cor 58th St.	New York City.

Name.	Residence.	Place.
Dr. J. A. Lippincott,	Arrott Bdg., Wood St. & 4th Av.,	Pittsburg, Pa.
Dr. F. B. Loring,	1420 K Street,	Washington, D. C.
Dr. D. B. Lovell,	32 Pearl Street,	Worcester, Mass.
Dr. F. W. Marlow,	731 University Block,	Syracuse, N. Y.
Dr. W. V. Marmion,	1110 8th Street, N. W.,	Washington, D. C.
Dr. W. B. Marple,	46 W. 53d Street,	New York, N. Y.
Dr. Arthur Mathewson,	408 5th Street,	Washington, D. C.
Dr. Chas. H. McIlwaine,	264 Willis Avenue,	New York, N. Y.
Dr. Jno. R. McIntosh,	40 Coburg Street,	St. John, N. B.
*Dr. S. C. Maxson,	225 Genesee Street,	Utica, N. Y.
Dr. C. S. Merrill,	23 Washington Avenue,	Albany, N. Y.
Dr. B. L. Millikin,	200 Euclid Avenue,	Cleveland, Ohio.
Dr. Horace Geo. Miller,	189 Bowen Street,	Providence, R. I.
Dr. J. Lancelot Minor,	14 Randolph Building,	Memphis, Tenn.
Dr. W. F. Mittendorf,	140 Madison Avenue,	New York, N. Y.
Dr. Charles A. Oliver,	1507 Locust Street,	Philadelphia, Pa.
Dr. H. S. Oppenheimer,	741 Madison Avenue,	New York, N. Y.
Dr. R. J Phillips,	123 So. 39th Street,	Philadelphia, Pa.
Dr. Thomas R. Pooley,	107 Madison Avenue,	New York, N. Y.
Dr. William C. Posey,	1831 Chestnut Street,	Philadelphia, Pa.
Dr. M. H. Post,	Beaum't St., cor. Wash. Av.,	St. Louis, Mo.
Dr. H. R. Price,	435 Clinton Avenue,	Brooklyn, N. Y.
Dr. J. S. Prout,	26 Schermerhorn Street,	Brooklyn, N. Y.
*Dr. Brown Pusey,	72 Madison Street,	Chicago, Ill.
Dr. Walter L. Pyle,	1806 Chestnut Street,	Philadelphia, Pa.
Dr. Alex. Quackenboss,	277 Dartmouth Street,	Boston, Mass.
*Dr. McCluny Radcliffe,	1812 Chestnut Street,	Philadelphia, Pa.
Dr. Alex'r Randall,	1717 Locust Street,	Philadelphia, Pa.
Dr. R. L. Randolph,	816 Park Avenue,	Baltimore, Md.
Dr. J. M. Ray,	423 West Chestnut Street,	Louisville, Ky.
Dr. R. G. Reese,	58 East 25th Street,	New York, N. Y.
Dr. R. A. Reeve,	48 Bloor Street East,	Toronto, Canada.
Dr. H. O. Reik,	412 Cathedral Street,	Baltimore, Md.
Dr. Stephen O. Richey,	732 17th Street,	Washington, D. C.
Dr. Charles E. Rider,	53 South Fitzhugh Street,	Rochester, N. Y.
Dr. Wheelock Rider,	53 South Fitzhugh Street,	Rochester, N. Y.
*Dr. G. O. Ring,	1900 Chestnut Street,	Philadelphia, Pa.
Dr. H. W. Ring,	187 Church Street,	New Haven, Conn.
Dr. Samuel D. Risley,	1728 Chestnut Street,	Philadelphia, Pa.
Dr. Edmund C. Rivers,	1632 Welton Street,	Denver City, Col.
Dr. Wm. K. Rogers,	188 East State Street,	Columbus, Ohio.
Dr. D. B. St. John Roosa,	20 East 30th Street,	New York, N. Y.
Dr. Dunbar Roy,	Grand Opera House Block,	Atlanta, Ga.
Dr. John D. Rushmore,	129 Montague Street,	Brooklyn, N. Y.
Dr. Robert Sattler,	7th and Race Streets,	Cincinnati, Ohio.
Dr. T. B. Schneideman,	1831 Chestnut Street,	Philadelphia, Pa.
Dr. G. E. de Schweinitz,	1705 Walnut Street,	Philadelphia, Pa.
Dr. P. N. K. Schwenk,	810 North 7th Street,	Philadelphia, Pa.

Name.	Residence.	Place.
*Dr. John R. Shannon,	20 W. 35th Street,	New York, N. Y.
Dr. Henry L. Shaw,	19 Commonwealth Avenue,	Boston, Mass.
*Dr. H. G. Sherman,	736 Rose Building,	Cleveland, Ohio.
Dr. Wm. T. Shoemaker,	2031 Chestnut Street,	Philadelphia, Pa.
Dr. Wm. A. Shoemaker,	1006 Carlton Building,	St. Louis, Mo.
*Dr. E. A. Shumway,	2007 Chestnut Street,	Philadelphia, Pa.
Dr. F. D. Skeel,	58 E. 25th Street,	New York, N. Y.
Dr. J. A. Spalding,	627 Congress Street,	Portland, Me.
Dr. Myles Standish,	6 St. James Avenue,	Boston, Mass
*Dr. E. W. Stevens,	421 McPhee Building,	Denver, Col.
Dr. George T. Stevens,	22 East 46th Street,	New York, N. Y.
Dr. Edw. Stieren,	Westinghouse Building,	Pittsburg, Pa.
Dr. Samuel B. St. John,	68 Pratt Street,	Hartford, Conn.
Dr. Geo. Strawbridge,	202 So. 15th Street,	Philadelphia, Pa.
Dr. T. Y. Sutphen,	999 Broad Street,	Newark, N. J.
Dr. Wm. M. Sweet,	1205 Spruce Street,	Philadelphia, Pa.
Dr. Lewis H. Taylor,	83 South Franklin Street,	Wilkes-Barre, Pa.
Dr. Samuel Theobald,	304 West Monument Street,	Baltimore, Md.
Dr. Ch. Hermon Thomas,	3634 Chestnut Street,	Philadelphia, Pa.
Dr. A. G. Thomson,	1426 Walnut Street,	Philadelphia, Pa.
Dr. Edgar S. Thomson,	19 E. 44th Street,	New York, N. Y.
Dr. William Thomson,	1426 Walnut Street,	Philadelphia, Pa.
Dr. Jas. Thorington,	120 South 18th Street,	Philadelphia, Pa.
*Dr. H. H. Tyson,	47 West 51st Street,	New York, N. Y.
Dr. John Van Duyn,	318 James Street,	Syracuse, N. Y.
Dr. C. A. Veasey,	1833 Chestnut Street,	Philadelphia, Pa.
*Dr. F. H. Verhoeff,	101 Newbury Street,	Boston, Mass.
Dr. O. F. Wadsworth,	526 Beacon Street,	Boston, Mass.
Dr. F. L. Waite,	68 Pratt Street,	Hartford, Conn.
Dr. David Webster,	327 Madison Avenue,	New York, N. Y.
Dr. J. E. Weeks,	46 East 57th Street,	New York, N. Y.
*Dr. Cassius D. Westcott,	31 Washington Street,	Chicago, Ill.
Dr. J. A. White,	200 E. Franklin Street,	Richmond, Va.
Dr. W. H. Wilder,	103 State Street,	Chicago, Ill.
Dr. Chas. H. Williams,	1069 Boylston Street,	Boston, Mass.
Dr. Wm. H. Wilmer,	1610 I Street N. W.,	Washington, D. C.
Dr. F. M. Wilson,	834 Myrtle Avenue,	Bridgeport, Conn.
*Dr. J. Scott Wood,	172 Sixth Avenue,	Brooklyn, N. Y.
*Dr. William L. Wood,	412 Oregonian Building,	Portland, Oregon.
Dr. Hiram Woods,	842 Park Ave.,	Baltimore, Md.
Dr. J. P. Worrell,	20 South 7th Street,	Terre Haute, Ind.
*Dr. S. Lewis Ziegler,	1625 Walnut Street,	Philadelphia, Pa.
*Dr. Wm. Zentmayer,	1819 Spruce Street,	Philadelphia, Pa.
Total,	. . . . .	173

HONORARY MEMBERS.

Dr. C. Schweigger,	. . . . .	Berlin, Prussia.
Dr. F. P. Sprague,	229 Commonwealth Avenue,	Boston, Mass.
Whole number.	. . . .	175

MINUTES OF THE PROCEEDINGS.

FORTY-SECOND ANNUAL MEETING.

ACADEMY OF MEDICINE,
NEW YORK, N. Y., June 28, 1906.

The Forty-second Annual Meeting of the Society was called to order at 10.15 by the President, Dr. Arthur Mathewson, who announced the following committees:

Committee on Bulletin — Drs. D. W. HUNTER and F. N. LEWIS.

Committee on Membership for next year — Drs. THEOBALD, G. C. HARLAN, STANDISH, HARROWER, and HUNTER.

Auditing Committee — Dr. RANDALL.

Drs. Libby of Denver, Radcliffe of Philadelphia, Roberts of Pasadena, and Easterbrook of Worcester were invited to attend and take part in discussion.

Committee on Bulletin reported and the following papers were read:

1. "The bacterial flora of the conjunctival sac in typhoid fever and in pneumonia," Dr. Randolph.

2. "An experimental study of the bactericidal power of various silver preparations," Dr. G. S. Derby (by invitation).

3. "Silver preparations in conjunctival disease," Dr. Standish.

4. "The treatment of purulent ophthalmia by immersion with argyrol solutions," Dr. Bruns.

Discussed by Drs. Gould, Duane, Verhoeff, de Schweinitz, Wilmer, Theobald, Risley, Roosa, G. C. Harlan, Gruening, Pooley, Oliver, H. Harlan, Maxson, Randolph, Thorington, Bruns, Standish, and Derby.

5. "Demonstration of Dr. May's case of upper-lid cyst with microphthalmos showing rosette formations in the rudimentary retinal lining," Dr. W. Holden.

Discussed by Dr. Verhoeff.

6. "The modern operation in diseases of the frontal sinus implicating the orbit," Dr. Gruening.

Discussed by Drs. Pooley, Alleman, Gruening, and Kipp.

7. "Panophthalmitis following operation for removal of epithelioma of ala of nose," Dr. Callan.

8. "Extraction of cataract in the capsule, with report of ten cases," Dr. Cheney.

Adjourned to 2.30 P.M.

9. "Extraction of lens as a method of procedure in cases of immature cataract" (East Indian Operation), Dr. Standish.

Discussed by Dr. H. Harlan.

10. "A preliminary note on enucleation of the eyeball under local anesthesia with cocaine and adrenalin," Dr. Bruns.

11. "Unilateral rotary nystagmus," Dr. Duane.

12. "A tangent plane for accurately mapping scotomata and the fields of fixation and single vision, and for indicating the precise position of double images in paralysis," Dr. Duane.

13. "Ocular symptoms in case of tumor of the pituitary body," Dr. Hansell.

Discussed by Drs. Lippincott, de Schweinitz, Greenwood. and Holden.

14. "Siderosis bulbi," Dr. Kipp.

Discussed by Drs. Cutler and Verhoeff.

15. "The course and treatment of simple cyclitis," Dr. E. S. Thomson.

Discussed by Drs. Bruns, Gruening, Ziegler, Marple, and Thomson.

16. "Keratitis tuberculosa relieved by tubercular injections, with report of a case," Dr. Ziegler.

Discussed by Drs. Callan, Wilder, and Ziegler.

Adjourned to Executive Session at 5 P.M.

June 29. Called to order at 9.30.

17. "A case of hypernephroma of the iris," Dr. Chance.

Discussed by Dr. Veasey.

18. "Concerning the signs in the retina of persistent high arterial tension and their diagnostic and prognostic import," Dr. de Schweinitz.

19. "Case of sarcoma of choroid presenting some difficulties of diagnosis," Dr. Marple.

Discussed by Drs. Kipp and Risley.

20. "A case of retinitis proliferans with development of a system of blood-vessels from the optic nerve," Dr. Marple.

21. "Destruction of cornea after removal of foreign body, due to bacillus pyocyaneus," Dr. Callan.

22. "Case of bacillus pyocyaneus," Dr. Ewing.

23. "Optic neuritis after injury or disease of the anterior half of the eyeball," Dr. A. Knapp.

24. "A case of pronounced inward and downward squint in *near* vision with binocular fixation and normal muscle-balance in *distant* vision," Dr. Theobald (by title).

25. "Report of cases of polio-encephalitis superior," Dr. Holden.

26. "Demonstration of pathological specimens," Dr. A. Knapp.

27. "Presentation of a modification of Dr. Dennett's electric ophthalmoscope," Dr. Marple.

Discussed by Dr. de Schweinitz.

28. "Study of the contributions to ophthalmology made by our society during the past thirty-one years," Dr. Gould.

Discussed by Drs. Gruening, Taylor, Standish, and Alleman.

29. "Case of plexiform neuroma," Dr. H. Knapp.

30. "Multiple myeloma with involvement of the orbit," Dr. Quackenboss.

31. "Congenital cyst of the orbit with microphthalmos," Dr. Quackenboss.

Discussed by Dr. G. C. Harlan.

32. "Case of foreign body which Haab magnet failed to remove; result after seven years," Dr. Taylor.

Discussed by Dr. Sweet.

33. "An invagination cyst of cornea and anterior chamber," Dr. Kipp.

Discussed by Dr. Risley.

34. "Congenital dislocation of both lenses — extraction," Dr. Risley.

Discussed by Dr. G. C. Harlan.

35. "Transient myopia due to trauma," Dr. Pooley (title).

The society then went into executive session.

Executive Session June 28th, 5 P.M.

The President, Dr. A. MATHEWSON, Washington, in the chair.

The Auditing Committee reported the Treasurer's report correct and it was accepted and adopted.

The Secretary read the list of names proposed for membership in the Society, which was referred to the Committee on Membership.

On motion of the Secretary the usual assessment of five dollars was made upon members for the ensuing year.

The Committee on Membership reported favorably on the following candidates:

W. G. M. BYERS, Montreal,
R. J. CURDY, Kansas City,
BROWN PUSEY, Chicago,
H. G. SHERMAN, Cleveland,
W. K. BUTLER, Washington,
C. R. HOLMES, Cincinnati,
MCCLUNY RADCLIFFE, Philadelphia,
J. R. MCINTOSH, St. Johns, N. B.
H. H. TYSON, New York.
J. SCOTT WOOD, Brooklyn.

These were elected Associate Members.

The Committee recommended that the membership limit be increased to 200.

On motion of Dr. Taylor the report of the Committee was adopted.

Dr. F. B. Loring, Washington, was nominated and elected member of Committee of Arrangements for Congress of Phys. and Surgeons for 1907.

The following nominations for officers for the ensuing year were made by the Committee:

President — Dr. C. J. KIPP, Newark.

Vice-President — Dr. S. D. RISLEY, Philadelphia.

Recording Secretary — Dr. S. B. ST. JOHN, Hartford.

Corresponding Secretary — Dr. J. S. PROUT, Brooklyn.

Committee on Publication — Drs. W. S. DENNETT, New York, and D. W. HUNTER, New York, and the Secretary (ex officio).

The Society adopted the report.

Dr. Carmalt called attention to the fact that at the Congress many members failed to register as attending the general meeting, and so did not pay the five dollars registration fee required, and asked for some plan by which this might be remedied.

On motion of Dr. C. J. Kipp, this matter was referred to the Executive Committee with power to act.

The Secretary read a letter from the National Congress on Tuberculosis, inviting the society to send delegates to the Congress to be held in New York in November, 1906.

On motion of Dr. C. J. Kipp, the Chair was instructed to make such appointments.

Executive Session, June 29, 1 P.M.

The list of nominations for officers for the ensuing year was presented, and on motion of Dr. Carmalt, the Secretary was instructed to cast the ballot, and the nominees were declared elected.

Adjourned.

S. B. ST. JOHN, *Secretary.*

List of members present follows:

Members present at the Forty-second Annual Meeting:

Dr. S. B. St. John,
Dr. Allen Greenwood,
Dr. R. L. Randolph,
Dr. Arthur Mathewson,
Dr. T. Lewis Ziegler,
Dr. James Thorington,
Dr. Frank N. Lewis,
Dr. Frank L. Waite,
Dr. Myles Standish,
Dr. H. H. Haskell,
Dr. F. E. Cheney,
Dr. Alex. Quackenboss,
Dr. A. G. Thomson,
Dr. Wm. Cheatham,
Dr. Edw. Stieren,
Dr. T. B. Schneideman,
Dr. C. A. Oliver,
Dr. H. O. Reik,
Dr. H. Harlan,
Dr. A. N. Alling,
Dr. Wm. Zentmayer,
Dr. W. T. Shoemaker,
Dr. A. Duane,
Dr. G. E. de Schweinitz,
Dr. Wm. H. Fox,
Dr. N. J. Hepburn,
Dr. W. A. Shoemaker,
Dr. S. Theobald,
Dr. W. H. Carmalt,
Dr. C. J. Kipp,
Dr, George T. Stevens,
Dr. S. D. Risley,
Dr. C. S. Merrill,
Dr. S. C. Maxson,
Dr. J. A. Lippincott,
Dr. B. Alex. Randall,
Dr. L. H. Taylor,
Dr. G. M. Gould,
Dr. P. A. Callan,
Dr. W. H. Wilmer,
Dr. T. R. Pooley,
Dr. E. Gruening,
Dr. W. H. Wilder,
Dr. L. A. W. Alleman,
Dr. Jno. T. Carpenter,
Dr. E. A. Shumway,
Dr. W. K. Rogers,
Dr. Burton Chance,
Dr. H. F. Hansell,
Dr. W. B. Marple,
Dr. A. Knapp,
Dr. H. Knapp,
Dr. C. A. Veasey,
Dr. Harry Friedenwald,
Dr. C. H. McIlwaine,
Dr. F. H. Verhoeff,
Dr. J. A. White,
Dr. J. B. Emerson,
Dr. C. W. Cutler,
Dr. W. M. Carhart,
Dr. H. S. Oppenheimer,
Dr. W. G. Craig,
Dr. W. A. Holden,
Dr. R. G. Reese,
Dr. J. W. Ingalls,
Dr. F. D. Skeel,
Dr. J. L. Adams,
Dr. J. D. Rushmore,
Dr. Geo. C. Harlan,
Dr. Jno. E. Weeks.
Dr. D. Webster,
Dr. J. R. Shannon,
Dr. Percy Friedenberg,
Dr. W. B. Johnson,
Dr. W. F. Mittendorf,
Dr. H. R. Price,
Dr. Carl Koller,
Dr. D. W. Hunter,

Dr. D. HARROWER,
Dr. H. D. BRUNS,
Dr. D. B. ST.J. ROOSA,
Dr. A. E. ADAMS,
Dr. E. S. THOMSON,
Dr. A. E. EWING,
Dr. MCCLUNY RADCLIFFE,
Dr. WALTER L. PYLE,
Dr. S. N. K. SCHWENK,
Dr. WM. M. SWEET,
Dr. E. C. RIVERS,
Dr. H. H. TYSON.

SILVER PREPARATIONS IN CONJUNCTIVAL DISEASE.

BY MYLES STANDISH, M.D.,

BOSTON, MASS.

Silver preparations have been used and advocated for many years in the treatment of diseases of the conjunctiva, but have proved to have no preëminent therapeutic value except in gonorrhœal infection.

At various times in the past thirty years or more, other remedies have been brought forward to supplant them and earnestly advocated, but upon trial the profession has abandoned them one after another and returned to the use of silver. This return to former methods has been forced in each instance by the belief of the clinicians that they obtained better results by the use of silver.

No one appreciates more strongly than I do the value of pathological and bacteriological laboratories in the advance of medicine. The aid obtained from laboratory methods in the diagnosis of tuberculosis, malaria, diphtheria, and many other diseases has been inestimable. In order to remember the great benefits conferred on mankind by laboratory experiments, one has only to recall the results of the clinical application of the principles of antiseptic surgery and its outgrowth, aseptic surgery, of the control and treatment of diphtheria, malaria, and yellow fever. Nevertheless, it seems almost necessary at the present time to re-state the fact that the relief of pain and the cure of disease is the object of all medicine, and that all laboratory results must be tried and proved efficient in the hands of the clinician before they have established themselves as of value to mankind. It therefore follows that positive laboratory results are worthy of the gravest consideration by the clinician however much they may run contrary to his previous opinions. Negative laboratory

results, on the other hand, form a very poor foundation for clinical advance. The difficulty of reproducing in the laboratory conditions identical to those present in the human system is very great. It is true that we can produce conditions in the laboratory which are absolutely under our control, but the difficulty lies that in conditions present in the human being are many factors of which we have at the present time no knowledge. These modify the laboratory experiments greatly and may even entirely overturn those conclusions.

It must then for a long time remain true that clinical bed-side observations will have great value, and should not be overlooked or scoffed at as unscientific.

The difficulty with bed-side observations lies largely in the multitude of accidental and adventitious circumstances which come in to modify results, and of which the observer who sees the case only at intervals is unaware, and the importance of which he would perhaps instantly recognize if he devoted his whole time to watching and studying a single case.

For this reason I have ventured to draw your attention to the importance of the clinical results obtained in such an isolation ward as the Gardner Building of the Massachusetts Charitable Eye and Ear Infirmary. Here the conditions surrounding the patient are absolutely under control. They are housed under the same conditions of temperature, ventilation, food, nursing, and so on. Experienced nurses long stationed in the same ward caring always for the same class of patients serve all alike. The technique of the nursing and diet are the best we know and the same to each and every patient. When, therefore, a certain line of treatment has been pursued in such a ward for months or years, the results come as near absolute truth as it is possible to determine by any methods now known.

Dr. Derby's experiments as presented to this Society at this meeting are exceedingly interesting, well worth doing and recording. They have involved a great amount of labor, but they illustrate in several particulars the difficulties of trying to reproduce the clinical conditions in the laboratory. In the first place,

the cultivation of the gonococcus in the laboratory is so difficult that it was abandoned, and the experiments made with the staphylococcus aureus. Now I think it will be accepted by all gentlemen of large clinical experience that in the conjunctival sac at least the bactericidal efficiency of silver is much greater when the infection is gonococcic than when it is staphylococcic. It is highly probable also that the condition which is omitted in the laboratory and which makes the growth of the gonococcus on ordinary media so difficult may be the very one which makes silver efficacious in the treatment of the disease.

We must all remember the laboratory experiments reported some years since upon iodoform with the conclusions that it was inert and had no bactericidal properties, but which were afterward modified by the discovery that in the presence of living tissues iodoform had active bactericidal properties.

It occurs to me that from the point of view outlined above, it is of interest to record the results of treatment in the Gardner Building of the Massachusetts Charitable Eye and Ear Infirmary. These statistics are a recapitulation of the statistics heretofore published by me and the addition of the statistics of years since the last report.

Successful results in the treatment of gonorrhœal ophthalmia depend upon absence of corneal lesions, so that in making up these statistics it is necessary to confine our attention to such cases as entered the Infirmary with clear corneæ.

In a paper read before the Section of Ophthalmology of the American Medical Society in 1904 at Atlantic City, I was able to report from the records of the Gardner Building the following statistics:

CASES OF OPHTHALMIA NEONATORUM ENTERING THE INFIRMARY WITH CLEAR CORNEÆ.

Treated with nitrate of silver:

Fifty cases with subsequent corneal infection in three cases or 6%.

Treated with protargol:

One hundred and fifty cases subsequent corneal infection, three cases or 2%.

Treated with argyrol:

Sixty-four cases with subsequent corneal infection in no case.

In the two years since that report of Ophthalmia Neonatorum, all cases entering with clear corneæ, with the exception of six cases mentioned later, were treated with argyrol.

There were 137 cases, of whom four had subsequent corneal infection; adding these to the above 64 cases to bring the record up to date the result is:

CASES OF OPHTHALMIA NEONATORUM ENTERING THE INFIRMARY WITH CLEAR CORNEÆ.

Treated with argyrol:

Two hundred and one cases with subsequent corneal infection in four cases or 2%. A result which no clinical observer will doubt is much better than was obtained under previous methods of treatment, and very satisfactory when we consider the physical inheritance of most of these babes.

Results as favorable as the above are not to be expected in the treatment of Gonorrhœal Conjunctivitis in the adult, and therefore one turns with interest to study the results obtained in adult cases.

In the paper above referred to there were reported

CASES OF GONORRHŒAL OPHTHALMIA IN ADULTS ENTERING THE INFIRMARY WITH CLEAR CORNEÆ.

Treated with protargol:

Thirty-two cases with subsequent corneal infection in 11 cases or 66% of perfect recoveries.

Treated with argyrol:

Twenty-three cases with subsequent corneal infection in seven cases or 69.5% of perfect recoveries.

In the last two years there have been admitted 29 cases in 11

of which the cornea became involved, so that the statistics to date are:

CASES OF GONORRHÆAL OPHTHALMIA IN THE ADULT ADMITTED TO THE INFIRMARY.

Fifty-two cases with subsequent corneal infection in 22 cases or 42%+.

In only four of these cases was there total leucoma or loss of the eye, giving as a result 58% of perfect recovery, and only approximately 7½% in which the outcome was a blind eye.

Such are the results in what is practically a clinical bed-side laboratory, and as such are entitled to respectful consideration.

These statistics include all the patients with Gonorrhœal Ophthalmia, in which the cornea was still clear, admitted to the ward, or with the exception of six cases treated by other remedies, the results of which were not encouraging, and two cases occurring in children of two and five years respectively, which could not easily be included in either of the above classes. There was a corneal infection in each of these latter cases. They entered respectively on the 17th and 23d day of the disease.

The local treatment in all these consisted of cleansing the lids externally often enough to keep them clean and the free instillation of a 25% solution of argyrol every two or three hours.

In 14 of the cases a solution of 50% argyrol was used.

It was suspected that a longer application of collyria to the eye might be more effective, and Dr. E. G. Hussey, the house officer of the Infirmary, devised the following ingenious method: The area about the eye was washed with alcohol to remove any traces of moisture from the tears, and a roll some five inches long and one inch in diameter was made of well worked ordinary painter's putty; this was used to construct a dam commencing at the nose and following the lower edge of the orbit to and upon the temple, thence if necessary along the brow to the point of beginning, and into the reservoir thus created was poured a 25% solution of argyrol completely covering the eye and lids.

Upper Fig. shows putty-dam empty. Lower Fig. shows putty-dam filled with argyrol.

This was allowed to remain from 10 to 25 minutes if it could be borne so long. The patient was encouraged to wink it freely into the eye.

On my service this experiment was used in a number of cases which entered the House with corneæ, which looked as if they were about to slough. It did not as a rule prevent perforation, but the extent of the slough was much less than we had reason to expect from the appearance of the eye, and the course of the disease favorably modified.

I think that this procedure deserves a thorough trial, and will prove to have its uses.

My conclusions are that the results above shown establish the fact that the modern silver preparations are efficient in the control of gonorrhœal infection of the conjunctiva and that they have greater bactericidal properties in this disease than the laboratory experiments upon other micro-organisms would lead us to expect.

AN EXPERIMENTAL STUDY ON THE BACTERICIDAL POWER OF VARIOUS SILVER PREPARATIONS.*

BY GEORGE S. DERBY, M.D.,

BOSTON, MASS.

As more or less uncertainty concerning the efficiency of the various silver preparations exists, the following work was undertaken at the suggestion of Dr. Standish with a view to comparing in the laboratory their bactericidal power. The amount of ground to be covered was, however, so great, and so many side issues presented themselves for consideration, that the work is not as yet finished. Thus this paper simply contains a short

* From the Pathological Laboratory of the Massachusetts Charitable Eye and Ear Infirmary.

description of the work and a summary of the conclusions arrived at thus far, as they seemed to be of sufficient interest to report at the present time.

The main object aimed at was to compare the bactericidal power of nitrate of silver and some of the newer silver preparations which have been placed on the market, giving especial attention to argyrol, for which so much is claimed by its manufacturers, and about which so much has been written from a clinical standpoint by many well-known physicians. It was fully realized that clinical conditions cannot be reproduced in the laboratory, also that great care must always be taken in drawing practical conclusions from laboratory evidence alone. The results are therefore presented for what they are worth, merely calling attention to the fact that the preparations investigated are of a more or less similar nature, and that they were tested under precisely similar conditions. In the first series of tests the following method was pursued. Two ccm. of the solution to be tested were placed in a small sterilized glass dish and a loopful of a 24-hour culture of the staphylococcus pyogenes aureus was stirred in thoroughly until the cocci were evenly distributed throughout the fluid. From this loopfuls were taken at stated intervals and stirred into the water of condensation of blood serum slants. The water of condensation was then run over the surface of the blood serum, and the tube was placed in the incubator for 24 hours, at the end of which time it was examined, and if no growth had taken place the water of condensation was again run over and the tube replaced in the incubator for a second 24 hours.

Remarkably consistent results were obtained in the 600 to 700 cultures taken according to this method. In one respect the conditions were extremely favorable for the solutions tested, namely, that no penetration was required. The staphylococcus aureus was utilized for the work on account of its rapid and abundant growth, and on account of the ease with which it is recognized. The preparations tested were purchased in the original bottles from reputable wholesale firms, and the solu-

tions were prepared in the laboratory according to the directions given by the manufacturers. In certain cases, notably argyrol, other specimens were obtained from the house apothecary of the Massachusetts Charitable Eye and Ear Infirmary.

The following silver preparations were tested: Nitrate of silver, Argyrol, Protargol, Collargol, Largin, Ichthargan, Albargin, Argonin, and Argentamin. For most of these it is claimed that they do not precipitate in the presence of albumen and of urine.

Taking them up now I will endeavor to enumerate briefly and without too many figures the conclusions arrived at.

Nitrate of silver, as is well known, forms dense precipitates with sodium chloride, albumen, and urine. It is an efficient germicide, as many have shown. Solutions varying in strength from ½% to 2% killed the aureus in from two to five minutes. An exposure of 30 seconds to the ½% solution was generally sufficient to prevent a growth in 24 hours, but not sufficient to kill all the cocci.

Protargol. 1%, 2%, 4%, 10%, and 20% solutions of this drug were tested. The age of the solution up to one month seemed to make no difference in its action. No precipitate with albumen or with urine could be detected. Its bactericidal action is efficient though not so efficient as that of nitrate of silver. The aureus is usually killed by a 2% or a 4% solution at the end of from three to five minutes, though occasionally a few colonies will grow after ten minutes exposure. An exposure of one minute will usually prevent a growth of the germ in 24 hours. Solutions of the same strength will kill the pneumococcus in one minute.

Collargol. This preparation is said to be a colloidal solution of metallic silver. It forms a rather opaque solution, and no precipitate with albumen or with urine could be detected. Its bactericidal power is comparatively weak, as a growth of the aureus could be obtained at the end of 20 minutes, using the 4% solution. With a 1% solution a growth was obtained at the end of one hour. A comparatively small amount of time was de-

voted to the following five preparations, and it is hoped to study them more thoroughly later.

Albargin, said to be a combination of nitrate of silver and gelatose, gave a precipitate with albumen and urine. The 1% aqueous solution is very irritating, as the writer found to his cost. Ten per cent. and 20% solutions killed the aureus in from two to five minutes. The 1% solution gave a growth after 15 minutes' exposure.

Ichthargan, a combination of silver and ichthyol, is also very irritating and also precipitates with albumen and with urine. In solutions varying in strength from 1/10% to 1% there was no growth after one to four minutes.

Argentamin. Ethylenediamine — silver nitrate. Practically the same results were obtained with a 5% solution of this drug as with Ichthargan.

Largin, silver protalbin, also gives a precipitate with albumen and with urine. It is rather irritating but is an efficient bactericide. The aureus was killed by a 10% solution in from two to five minutes.

Argonin, argentum casein, in a 5% solution, appeared less irritating than the four preparations just mentioned. As it forms an opaque solution a precipitate could not be detected in the presence of albumen and of urine. No growth of the aureus could be demonstrated after from three to six minutes.

Argyrol. A large number of solutions of this drug were tested since, but little has been written concerning it except from the clinical standpoint. The manufacturers claim that it does not precipitate with albumen or with urine, and that it is a very efficient bactericide.

My results confirm those of Verhoeff in regard to this preparation, and are even more striking. A precipitate is obtained in the presence of albumen and of urine though the opacity of the solution tends to disguise it. Its bactericidal power is exceedingly weak. In a large series of observations a growth of the aureus was obtained after exposure to the 10%, 25%, and 50% solutions for one hour, 1½ hours, and two hours. A diminution in the number of colonies commonly appeared at the end of 20

minutes. Its action was uncertain, and while occasionally the germs were affected by a 20-minute exposure, more often the cultures taken at the end of one hour showed a growth when examined 24 hours later. The age of the solution did not appear to be of importance.

In this first series of experiments the question of penetration was not considered, and this omission would seem to render the results worthless as far as any practical application is concerned. Many writers have taken the ground that on the power of penetration depends in a large measure the efficiency of the drug, and most of those who have worked on the silver salts in the laboratory, have tried to measure this quality. Thus nearly every one of the preparations considered in this paper have been shown to penetrate to a greater depth than does nitrate of silver. Why, therefore, do we note a growing tendency to return to the old solution which has so many disadvantages?

If these newer preparations are less irritating, penetrate to a greater depth and, with a few exceptions, act efficiently on so resistant a germ as the staphylococcus pyogenes aureus, why is it that their action on the severer forms of conjunctivitis is so disappointing? Why is it that germicides are of so little value in all but the most superficial processes?

Nuttall was among the first, if not the very first, to call attention to the efficiency of normal blood serum as a bactericide. Vaughn and McClintock hold that this power is due to a substance secreted by the leucocytes, probably a nuclein. Lubarsch has shown that this quality is more marked when the serum is removed from the tissues as in the case of a blood clot, but it is of transient duration under such conditions. We are all familiar with the protective action of the body fluids. They resist bacterial invasion. They combat the effects of trauma, as is instanced by the formation of a blister to protect the deeper layers and by the covering of a wounded surface with a blood clot. Probably it is to the protective action of the blood serum that we must attribute the disappointing results obtained in the use of bactericides.

In a recent number of the *Journal of the A. M. A.*, Verhoeff called attention to the fact that if human serum be added to sodium aurate or to protargol their bactericidal power is immediately and completely destroyed. Whether attention has previously been called to this fact I am unaware. Verhoeff's observations were made with diphtheria antitoxin and with hydrocele fluid.

My second series of observations was carried out along this line. Two samples of hydrocele fluid and one of bovine serum were obtained and preserved in sterile tubes. One ccm. of the serum was mixed with one ccm. of the silver preparation to be tested, and the aureus stirred in as previously described. A very marked diminution in the bactericidal power of all solutions resulted. Nitrate of silver 2% showed a growth of the aureus after an exposure of 30 and 40 minutes, Protargol 8% after 60 minutes. Argyrol 50% gave an abundant growth after 3½ hours, the longest interval tried. The other preparations showed the same result, being affected in about the same proportion as was nitrate of silver. The three specimens of serum had about the same action as far as could be judged from the amount of work done.

That this same effect is produced on other germicides than the silver preparations is shown by the following: Lugol's solution, composed of iodine one part, KI two parts, and water 100 parts, possesses a wonderful bactericidal action. In one-half strength it killed the aureus in from 30 seconds to one minute. With serum there was a growth at the end of five minutes. Corrosive sublimate 1-1000, to which serum was added, showed a growth after 30 minutes. Ordinarily it works in from three to five minutes although occasionally a few germs escape for a longer period.

Therefore it would seem that in the protective power of the tissue fluids lies the principal reason for the inefficiency of antiseptics. What advantage is penetration to a drug if it reaches the disease focus diluted and with its bactericidal power almost exhausted? And not only must the bactericide reach the dis-

ease focus, but often in order to do good, it must penetrate within the cell. What better opportunity could there be for the action of a germicide than in the gonorrhœal ophthalmia of the adult, and where do we find a more conspicuous failure? Some writers state that with argyrol they obtain better results than with the older solutions, and it seems to me that theoretically there is a certain amount of evidence on their side. Argyrol appears to be an almost inert solution, it is sterile and soothing. It mechanically washes away the pus, certainly does no harm, and does not deter nature from doing her best. Would not normal salt solution be as efficient and less objectionable?

At present it seems that our hope for a specific in gonorrhœal ophthalmia is less likely to be gratified by the pharmacopeia than by the serum therapy of the future.

In the present state of our knowledge it seems possible to group the silver preparations tentatively into three classes. In the first we would put the unirritating ones of low bactericidal power, such as argyrol. The second would include the more effective and slightly more irritating bactericides, such as protargol. In the third, the very irritating preparations like nitrate of silver, which act in two ways, as bactericides and as caustics, their value depending to a large extent on the reaction they set up.

CONCLUSIONS.

The silver preparations tested, with the exception of argyrol and collargol, are efficient bactericides in the laboratory.

Their bactericidal action and that of Lugol's solution and of corrosive sublimate is markedly impaired by the addition of a serum, such as hydrocele fluid or bovine blood serum, and it seems probable that on this fact largely depends the comparative inefficiency of antiseptics.

THE IMMERSION TREATMENT WITH ARGYROL SOLUTIONS OF THE PURULENT OPHTHALMIAS.

BY HENRY DICKSON BRUNS, M.D.,
NEW ORLEANS, LA.

About a year ago I published in the November number of the New Orleans *Medical and Surgical Journal* a paper on "Gonorrhœal Conjunctivitis in the Adult and in the Infant." In that paper I told my experience with argyrol in the treatment of this most dreadful of conjunctival diseases. I was glad to support my position by free quotations from the valuable paper, doubtless familiar to you all, by Dr. Myles Standish, published in the *Journal of the American Medical Association* of December 17, 1904. In the report of the discussion which followed the reading of Dr. Standish's paper before the Ophthalmological Section of the Association, I was surprised to note the long interval allowed between the instillations of the argyrol solution by those who spoke; a practice which seemed to me to vitiate all their conclusions. I shall not pause here to recount these expressions, but shall merely repeat that, "Dr. Standish himself describes his routine use of the solution to be from once every hour to once every four hours in ophthalmia neonatorum;" as he mentions no difference, he presumably employs it in like manner in the adult. I am firmly persuaded that the great advantages of the treatment with argyrol cannot be reaped in this way.* My surprise was increased when correspondence with some distin-

* Dr. Frank C. Todd, of Minneapolis, in maintaining the superiority of Protargol, speaks of using the two drugs in solutions of 50 per cent. in glycerine from one to three times daily. Such a mode of using argyrol is utterly inadequate to obtain the effect sought and the extremely irritating menstruum chosen (glycerin) sacrifices one of the most valuable properties of the remedy. Dr. John C. Weeks, of New York, speaks of using argyrol in 35 per cent. solution "about every two hours"; Dr. Hiram Woods, of Baltimore, of using a 25 per cent. solution every third hour and a 50 per cent. solution twice a day.

guished confrères of the Northeast disclosed that they were regarding argyrol with rather dubious favor; though I could not elicit that they had tried the drug in exactly the manner which had given me what seemed such delectable results. Therefore I turned once more to the subject and began to observe these cases with redoubled care.

My experience with argyrol began about the mid-winter of 1903 in the Eye Clinic of the Eye, Ear, Nose, and Throat Hospital of New Orleans. At once substantiating the claim that it was non-irritating and absolutely painless, our staff began its tentative use in solutions of different strengths.

Believing we perceived favorable effects upon certain infected ulcers of the cornea, we watched closely its action in ophthalmia neonatorum only to be struck with its excellent effect. At first we used it every two hours as an adjuvant to an application of one per cent. silver nitrate solution once a day at the Clinic. In the same way it was used in cases of purulent conjunctivitis in the adult, and with like good results. Noting how soon the secretion of pus diminished and then disappeared, and that far from any ill effect appearing the cases seemed to do better the more frequently we instilled our solutions, it occurred to me that we had come into possession of an antiseptic, not only bland and unirritating, but positively soothing to the inflamed conjunctiva; that to secure the best results, we should, as was sometimes done in general surgery, keep the infected tissues virtually immersed in the antiseptic solution. Acting upon this idea, by 1904 all other applications were abandoned, and the frequency of the argyrol instillations was increased to every 30 or even every 15 minutes, night and day, until pus formation had totally ceased. The results were entirely satisfactory. About this time, too, I was greatly impressed by an accidental observation. Having extracted the dislocated lens from the eye of an elderly man, argyrol was freely instilled into the eye operated upon, and both eyes sealed with a firmly applied dressing, moistened with argyrol solution, and a bandage. On the third day, when the dressing was removed, the wounded eye was found absolutely clean,

while the unoperated one, to which no argyrol had been applied, was affected with a profusely secreting conjunctivitis, which was not well until the 13th day after. During 1905 and 1906 this treatment has been pursued with even greater rigor, if possible. For in 1904, in one or two cases, incipient ulcers of the cornea were washed at the daily visit with 50% enzymol solution for a few days, until they appeared to be clean, but in 1905 and 1906, not even this has been done until pus formation has ceased. During these years argyrol has been incessantly used in the treatment of all wounds, operative or accidental, in all cases with any discharge, in all ulcers, and in most cases of disease of the lachrymal apparatus, the instillations being made at short intervals. This constant use of the drug has led me to very positive opinions as to its qualities. Not only is it painless and non-irritating, but on the contrary so soothing to the irritated eye as to seem slightly anæsthetic. Every one may have occasion to experience this in his own person. Its diffusibility is striking. A drop put into the eye spreads immediately over the globe and the inside of the lids and soon finds its way into the lachrymal sac and down the nasal duct. How persistently it clings to the tissues may be seen by observing it in the minute folds of the conjunctiva hours after it has been instilled, and its accumulation in corneal ulcers when it has been long employed. But I believe it not only clings to but actually soaks into or penetrates the tissues; because, even after 12 hours, when no trace of it can be perceived on the conjunctiva, if the eye be irrigated with a clear solution the irrigating fluid will come back stained; its effect upon the gonococcus sustains this idea. As Dr. Standish (loc. cit.) has said, the high specific gravity of the salt is a telling advantage; for when freely instilled, even in 10% solutions, it floats the pus out between the lids and carries it with the excess of the solution down upon the cheek, whence it may be wiped even by the most clumsy and ignorant nurse without abrading the inflamed conjunctiva or cornea. On the other hand, certain disadvantages which the salt possesses have not been sufficiently emphasized. In the first place it, or at least its solutions, are

unstable. Two or three weeks seems to be the longest time a solution in ordinary use will last without decomposition. In dark and cool places it is said to keep much longer. I am glad to see that its manufacturers have of late begun to call attention to this fact, for the use of old and decomposed solutions may explain many unsatisfactory results. For this reason it should be prescribed in small amounts, the patient should be warned, and the prescription should specify that the solution must be fresh. Its cost makes this important also, for if bought from any but reliable retailers the solution may be furnished in weaker percentage than that ordered. Neglect of these precautions may cost an eye. Fortunately, as soon as decomposition sets in, it begins to sting or smart the conjunctiva and so give us warning. In this condition it is very irritating. Recently I prescribed, as I often do, a 10% solution to be used twice a day in the eyes of an old lady upon whom I was about to do cataract extraction. When I appeared on the third day after to perform the operation, she complained of the stinging produced by the drug; the conjunctiva was inflamed and hypersecreting and the operation had to be postponed for several days. I have observed that even fresh 10% solutions appear to irritate if used too long at frequent intervals. The longest I have ever used the 10% solution as often as once an hour during waking hours has been one month. Finally, it should be well understood that argyrol is not a powerful astringent. I feel sure that failure to seize this clearly has been the cause of many disappointments in its use. In the acute catarrhs, in which there is but faint risk of corneal involvement, and in which, therefore, we can proceed to stamp out the disease as rapidly as possible, one of the more powerful metallic astringents should be employed simultaneously. Thus I have found cases so severe as to be indistinguishable clinically from gonorrhœal infection to yield readily to instillations of argyrol 10% and zinc-sulphate or sulpho-carbolate ⅕ to 1/40% each alternate hour. This, too, without confining the patient or restraining him from his ordinary employments. All the more then in the purulent ophthalmias, when suppuration has been controlled argy-

rol has played its most important part and a metallic astringent must make good the victory. If no remedy but argyrol is used, we observe a tendency on the part of many cases to remain stationary and to assume gradually a chronic condition. Although suppuration has ceased, the conjunctiva keeps thick and red, with a dull, slack, lifeless look, peculiar but difficult to describe. This is doubtless due to the feeble astringency of argyrol. The intervals between the argyrol instillations must therefore be gradually lengthened and silver nitrate in one per cent. solution be applied once daily to the carefully everted lids. But I cannot too strongly emphasize the caution that, no matter how severely our patience may be tried, this part of the treatment should never be begun until suppuration has ceased. My observations convince me, just as Dr. Standish's did him, that the frequent manipulations, syringing, washing, wiping, and pulling at the eye in our attempts to make thorough application of this or that remedy, or to remove every shred of pus from the conjunctival sacs, have been the cause of many of the very complications we most dreaded. No doubt during such manipulations we almost always injure the sick and softened conjunctival and corneal epithelium and open avenues of penetration to the gonococci. Certainly under the argyrol immersion treatment the course of the disease has been much less fierce. Corneal ulcer has been infrequent. In those cases in which it occurred the ulcer extended little in area or depth, and in no instance left behind it scars of any consequence.

Finally, I admit that certainty in the initial diagnosis of conjunctival gonorrhœa can be had by microscopical diagnosis only. We see on the one hand occasionally cases of acute infectious catarrh of such virulence, and on the other hand quite often true conjunctival gonorrhœas of such mildness, that at the first examination we may mistake. But if properly attacked the course after the first 24 hours should resolve our doubt. Thus in the table of cases from my clinic (page 37) two (Nos. 4 and 7) in which the microscopical diagnosis was positive, seen on the third and fourth day of the disease, were practically well, in spite of their mildness, only on the twelfth and thirteenth day respectively.

Pus formation persisted through the fourth in one and the fifth day in the other. The worst case of acute catarrh I ever saw, absolutely indistinguishable by inspection from a gonorrhœal conjunctivitis of severity, was broken up by the second day and recovered under the use of argyrol and zinc-sulphate each alternate hour in six days. The cases in table No. 2, not confirmed by the microscope, were only discharged after 23 to 61 days of treatment, with the exception of case 17; he was not seen until the twenty-first day of the disease, but even then required 10 days of treatment. Considering the errors which may vitiate any single examination, I should prefer the clinical to a negative microscopical diagnosis in a case of purulent conjunctivitis, occurring in an individual affected with clap, or becoming in the first three or four days complicated with slow healing ulcer of the cornea, and lasting for ten days or longer in spite of proper treatment.

CASES.

The cases upon which the foregoing conclusions rest are: First, those given in the table prepared by Dr. Standish; and, second, those treated in the eye department of the Eye, Ear, Nose, and Throat Hospital of New Orleans.

Dr. Standish's table showing results of treatment of gonorrhœal ophthalmia with protargol and argyrol:

PROTARGOL.

Per cent. used.	Entered with clear cornea.	Discharged with clear cornea.	Entered with corneal lesions.	Discharged with leucoma.	Lost or total leucoma.
10	18	14	10	13	1
20	12	5	6	10	3
30	1	1	..	..	..
40	1	1	..	..	..
	32 66+%	21 43+%	16 33+%	23 47+%	4 8+%

ARGYROL.

15 25 50	2 12 9	2 8 6	.. 7 7	.. 6 7	.. 5 3
	23 62+%	16 43+%	14 37+%	13 35+%	8 21+%

[Percentage added by H. D. B.]

This table shows, that under the protargol treatment, while 66+% entered with clear corneæ, only 43+% were discharged with the corneæ clear; under the argyrol treatment only 62+% entered with clear cornea, yet 43+%, the same as under protargol, were discharged with corneæ clear; under the protargol treatment while only 33+% entered with corneal lesion, 47+% were discharged with leucomata; under the argyrol treatment while 37+% entered with corneal lesion, a greater number than in the protargol test, only 35+% were discharged with leucomata, a much less number than under the protargol test, and a number positively less than those admitted with the corneæ affected. Under the protargol treatment 14% *more* than those who entered with corneal lesions were discharged with *leucomata;* under the argyrol treatment 2% *less* than those who entered with corneal lesions were discharged with leucomata. It must be remembered that these percentage differences, though small in themselves, are proportionately large in a table dealing with only 85 cases. It is true that under the protargol treatment only four (8+%) eyes were lost, while under the argyrol treatment eight (21+%) were lost. It is to be observed, however, that 4.5% more with corneal lesions present entered under the argyrol treatment than entered under the protargol treatment; now 4.5% of 85 equals almost exactly four, the very number by which the eyes lost under argyrol exceeds the number lost under protargol; it is easy to conceive, therefore, that if this 4.5% of eyes treated with argyrol chanced to come under treatment with corneæ badly ulcerated, they might, in so small a total as 85 cases, readily ac-

count for the whole excess of total losses, which at first blush seems so unfavorable to argyrol. It is needless to say that no one contends that argyrol can save a cornea already deeply infiltrated and sloughing (necrosed), an achievement the equal of a resurrection. Valuable as these cases are, they are certainly too small in number (37) to stand for more than an awakening suggestion, but taken in connection with those which I shall adduce from my own clinic, they are worthy of particular consideration as the contribution of an independent observer. With this regard they take on special force: That while they were treated within the walls of the Massachusetts Charitable Eye and Ear Infirmary and therefore, presumably, with all exactness, by well-trained attendants, the solution, so far as we can gather, was not instilled oftener than once an hour; a fact which, in my opinion, in large part sacrificed the most beneficent feature of the treatment, — constant immersion of the affected organ. Mine, on the other hand, were without exception out-patients; many were negroes and the whites from the humbler classes of our community; after the daily visit to the clinic they returned to poor surroundings and were nursed by untutored friends or relatives, perhaps with some irregularities; yet under the spur of incessantly reiterated threats, warnings, and encouragements, I believe they attained nearer to what I esteem to be the essential of an efficient treatment with argyrol.

Cases from the eye department of the Eye, Ear, Nose, and Throat Hospital of New Orleans:

All "out-cases," paying one daily visit to the Clinic and treated by friends and relatives at home.

1893-1902.

In the ten years from the beginning of 1893 to the end of 1902, only 39 cases were treated until discharged, the various methods then in vogue being employed. Three of these were allowed to drag on a chronic course, but the average duration of treatment of the remaining 36 was between 39 and 40 days. Of the 39 cases three (7.6%) were discharged worse, which meant that the

eye was lost. How many of the "cured" escaped with more or less incapacitating leucomata, I cannot say, for at that time even eyes seriously crippled by the disease we considered saved.

1903.

In this year we began the use of argyrol.

Six cases treated with 10% argyrol every hour were cured in an average time of 18 days.

1904.

Seven cases treated with 10% argyrol every half hour and washed with 50% enzymol at the Clinic were cured in an average time of 23 days.

1905.

In this year we were able to begin microscopical examinations.

Thirteen cases treated with argyrol 10% every half hour (or oftener), and a borax wash in the catarrhal stage were cured in an average time of 22 days. It is noted in four cases that suppuration ceased after the third day. Microscopic diagnosis was positive in four, probable in two. In the seven in which microscopic diagnosis was negative, in two ulcer of the cornea appeared by the third day and was slow in healing, and in three urethral gonorrhœa was present. One of those with urethral gonorrhœa also had corneal ulceration.

1906.

Four cases in which the microscopical diagnosis was positive. Three were treated for 10, 12, and 60 days each when they quit practically well. Suppuration ceased by the fourth, fifth, sixth, and seventh day. The fourth case, the most severe I have ever treated by this method, is one of those related in full.

From the cases of 1905 and 1906 the following interesting tables can be prepared. Some of the histories were, unfortunately, destroyed after the preparation of our hospital report for 1905, but it can be positively stated that in no case did suppuration persist after the seventh day; it was always greatly diminished by the third day.

TABLE I.

Gonorrhœal Ophthalmia; microscopical diagnosis positive. No other treatment than instillation of 10% argyrol solution every 15 or 30 minutes day and night till suppuration ceased.

Day of Disease.	No pus on	Discharged.	Other treatment.
1. 7th. White man, æt. 23.	4th day of treatment.	On 44th day.	After the 8th day $AgNo_3$ 1%, once daily at clinic.
2. 4th. White man, "dago," æt. 55. Lids greatly swollen; copious discharge; severe case.	2d day.	Never returned after 4th day of treatment. Eyes growing steadily better.	None.
3. 3d. White girl, æt. 3. Specific vaginitis.	3d day.	78th day. Conjunctivitis, struggled to become chronic.	After 6th day, $AgNo_3$ 1%, once daily at clinic.
4. 3d. Negro man, æt. 22.	5th day; little after 3d day.	18th day of treatment.	After 5th day of treatment $AgNo_3$ 1%, at clinic, once daily.
5. 3d. Mulatto man, æt. 27. Brawny lids, bacon fat infiltration of palp. conjunct. Croupous membrane; 3d day, marginal ulcer of cornea.	3d day practically none.	78th day. Treatment of nebula corneæ prolonged. Conjunctiva well 62d day.	After 6th day, $AgNo_3$ 1%, at clinic.
6. 4th. Negro man, æt. 29.	4th day hardly any.	Quit on 4th day. Steadily improving.	None.
7. 4th. White woman, æt. 20. Mild infection.	6th day.	12th day.	Calomel purge.
8. 15th. Negro man, æt 27. "Got lime in eyes." History of gonorrhœa two weeks ago.	6th day.	Practically well 6th day, quit after 10th day.	After 6th day, $ZnSo_4$ Gr. j,t–i–d., at home.
9 14th. White man, æt. 20.	5th day.	70th day. Conjunctiva became granular.	After 7th day, $AgNo_3$ 1%, at clinic.
10. 2nd. Mulatto man, æt. 22. Very bad case; ulcer of cornea on 3d day.	7th day.		$AgNo_3$ Gr. v after 7th day. Tonic after 8th day. After 10th day cleansed ulcer once daily with enzymol.

TABLE II.

No microscopical examination or microscopical diagnosis doubtful, but urethral gonorrhœa or early corneal ulcers or both.

Day of Disease.	No pus on	Discharged.	Other treatment.
11. 3d. White man, æt. 23. Smear doubtful; "probable."	6th day of treatment.	40th day.	After 6th day, $AgNo_3$ 2%, once daily at clinic. Later Zn. Sulph. carb. gr. ¼ t-i-d.
12. 7th. White man, æt. 40. Smear "not typical."	3d day.	49th day.	After 3d day, $AgNo_3$ 1%, once daily.
13. 3d. White man, æt. 42. Ulcer on 3d day of disease; conjunctiva granular.	6th day.	68th day.	After 6th day, $AgNo_3$ 1%, once daily.
14. 3d. White man, æt. 35. Ulcer on 3d day of disease.	3d day of treatment.	23d day of treatment.	After 8th day, $AgNo_3$ gr. ½ to oz. daily.
15. 4th. Mulatto man, æt. 26. Urethral gonorrhœa; ulcers and iritis, 4th day of disease; severe case.	4th day.	85th day. Slight marginal nebulæ. Practically well 61st day, but nebulæ treated longer.	After 8th day, $AgNo_3$ 1%, once daily — Atropin.
16. 5th. Negro man, æt. 25. "Struck in eye by cockroach," urethral gonorrhœa; bad case.	Not stated.	33d day.	After 30th day, $ZnSo_4$ gr. 1 to ounce t-i-d.
17. 21st (?). Negro man, æt. 20. Urethral gonorrhœa.	4th day.	10th day quit cured.	None.

To sum up: Our hospital reports show that from 1903 to the present time 30 cases, comprising a total of 34 eyes, were treated by "immersion" in 10% argyrol. In at least 12 of these cases the diagnosis was confirmed by microscopical diagnosis. In the cases not so confirmed clap was present or slow healing corneal ulcer appeared early and the conjunctivitis persisted long. In the apparent exception, case 17, which quit practically well on the tenth day, it will be noted that the patient only presented himself for treatment on the twenty-first day.

In the 10 positive cases given in table I, corneal ulcer ap-

peared but twice (Nos. 5 and 10). In one negative case (13) although the ulcer was central, the vision on discharge was 20/xx. Out of the whole 34 cases not only was no eye lost, but none was left with leucoma of any consequence. The average duration of treatment ran from 18 days in the smallest group of six cases, to 22 and 23 days in two groups comprising 20 cases. Considering only the 10 positive cases given in the table, pus formation ceased once on the second, twice on the third, twice on the fourth, twice on the fifth, twice on the sixth, and once on the seventh day of treatment. I can offer no explanation of the variation in the time of cessation of pus formation. Cases 2 and 5, in which it ceased on the second and third day of treatment, were very severe; cases 7 and 8, in which it persisted to the sixth day, were mild. This suggests that it depended most upon the fidelity with which the patient and his friends carried out the treatment. Although the unaffected eye was never protected in any way, save by the instillation of the 10% solution every other time it was applied to the diseased one, in not one of the 30 monocular cases did it show the slightest sign of infection.

While it is undesirable to extend this paper by the relation of cases, I desire to recite two examples of the severe type with which we have had to deal. The notes are given without alteration, just as they were made day by day in the Clinic.

CASE I.

(No. 5, Table 1.)

H. T., a mulatto laborer, aged 27, presented himself for treatment on May 31, 1905. The patient, though well nourished, looks rather ill. He says the right eye has been slightly sore for two days and became swollen last night. R. E. cannot be opened wide enough to take V. L. E., V.=20/xx. The lids, especially the upper, are dusky, greatly swollen, and brawny. Pus flows freely from between them. It is barely possible to catch a glimpse of the cornea by drawing up the upper lid as far as possible; when this is done the palpebral conjunctiva seems to be coated with a clinging membrane like that lining an egg shell. So far as we can

see, the cornea is clear. A smear is taken and sent to Dr. P. E. Archinard, the pathologist, for examination. The dangers of his condition are deeply impressed upon the patient, and he is ordered a fresh 10% solution of argyrol to be dropped into his eye every 15 minutes day and night.

June 1, 1905. Less pus. Lids less swollen. The upper one can now be lifted far enough to see that the palpebral conjunctiva is occupied by a "bacon fat" infiltrate like that described by German text-writers in conjunctival diphtheria.

June 2, 1905. Still less pus and swelling of lids, but an erosion of the nasal margin of the cornea has appeared. The report on the smear is *positive*. No change in treatment.

June 3, 1905. At the end of 72 hours practically no pus. Ulcer is clean. Same treatment.

June 6, 1905. No pus; no pain. Ulcer clean and healing. Now $AgNO_3$ — gr. ss. to oz. i at Clinic.

June 13, 1905. Ulcer healing; smaller.

August 16, 1905. Practically well; using yellow oxide of mercury salve for nebula.

CASE II.

(No. 10, Table 1.)

R. C., a mulatto laborer, aet. 22, came to the Clinic, May 30, 1906. General appearance good. Says he woke up yesterday morning and found R. E. sore and swollen. The lids of R. E. are swollen, dusky, and extremely brawny. The upper lid cannot be everted. A moderate amount of thick yellow pus squeezes itself between the lids. The conjunctiva is thickened and elevated around the cornea, which is clear. Questioned, he admits having gonorrhœa three weeks ago. A smear is taken. The patient is warned of his danger and ordered argyrol, 10%, instilled every 15 minutes day and night. The smear is positive.

May 31, 1906. The eye feels more comfortable; brawniness is decreased, secretion slightly diminished. On the temporal margin of the cornea, close together, are three minute infiltrations.

There is one the size of a small pin-head just below the margin of the pupil. Find that patient has not been supplied with absorbent cotton, and has been wiping away excess of argyrol with same handkerchief continually.

June 1, 1906. Brawniness much less; secretion decidedly diminished. The three marginal infiltrations have run into a narrow, shallow ulcer. The central infiltration is unchanged except that it, as well as the marginal ulcer, is deeply stained with argyrol. Patient is kept at Clinic and soaked with argyrol every 15 minutes for more than two hours. Atropin is instilled once. Since early yesterday he has been supplied with argyrol from the hospital, because we were doubtful of the quality of that he was buying.

June 2, 1906. Reports that his medicine gave out at 4 A.M., and he had no treatment till he reached the hospital at 9 A.M. Lids are flaccid; pus about the same as yesterday. The corneal ulcers are deeply stained with argyrol and have not progressed. The one near the center, which can best be examined, is a minute, clear, shining pit, with no area of surrounding infiltration.

June 4, 1906. Secretion decidedly less; lids much more flaccid. The corneal ulcers have perhaps increased slightly in depth. Around the lower half of the corneal margin an elevated ring of infiltration now shows more plainly because the chemosis has subsided. Specimen taken on June 2d shows gonococci, but not so numerous.

June 5, 1906. Pus formation is practically at an end. The ulcers appear perhaps a shade deeper. Complains of feeling feverish; temperature 99½ degrees, and tongue is coated. Calomel and soda grains VII each, to be followed by a saline in the morning.

June 6, 1906. Lids perfectly flaccid. Ulcers a trifle larger and showing a shade of infection. This morning he slept "quite a while," and had no drops. Infiltration of conjunctiva about cornea greatly diminished. No pus. Touch palpebral conjunctiva with $AgNo_3$, Gr. V. Argyrol only every one-half hour at night.

June 7, 1906. No secretion. The central and marginal ulcers

have almost run into one. This means that the central one is about four times its original size. Now about one-eighth of an inch in diameter. Both ulcers are a little deeper, and the central one slightly infected. Put on elixir of bark, iron, strychnine.

June 8, 1906. The central ulcer has joined the marginal one by a narrow band; it remains slightly infected while the marginal one is clear. Make a smear by rubbing lower palpebral conjunctiva. Smear negative.

June 9, 1906. Smear having proved negative, begin to clean up ulcers once daily by soaking with 50% enzymol. $AgNo_3$, Gr. V. is applied daily.

June 12, 1906. Doing well; ulcers healing.

June 22, 1906. General injection much less. For four or five days has been using argyrol only once every hour day and and night.

June 25, 1906. Practically well. Slight leucoma down and inward not involving pupillary area. V.R.+L. = $\frac{20}{xx}$.

It is seen that I do not use cold applications. They seem to me risky and inconvenient, and to add to the discomfort of the patient. The experiments of Dr. Standish have convinced me of their uselessness. I have come to depend upon the 10% solution because I have observed no advantage in the stronger. By greatly increasing the density of the solution, I should fear to promote osmosis from the tissues, and so interfere with the penetration of the salt. This point, however, is certainly still *sub judice.*

Courage of one's convictions is required to persist with argyrol alone in the treatment of such cases as these, especially when we see ulceration of the cornea begin; but if we have the courage to refrain from excessive manipulation and all else that may irritate and abrade the inflamed tissues, it will meet with its reward.

Says Ernest Thomson, in the *Ophthalmoscope* for May, 1906: "Darier, ever ready to champion argyrol, relates a case of gonorrhœal ophthalmia in which argyrol was the main weapon used. Day and night the eye was bathed out with permanganate (0.30 to 1,000), and then flooded with argyrol 10% every half hour.

Darier at his visit used 25%, and occasionally protargol 25%. The eye was out of danger in four days. Silver nitrate was not employed at all. The article extends to eleven columns of the periodical, and reads as dramatically as the account of a battle."

One notes the slight sarcastic tang, but one notes also that had there been fewer medicaments employed the battle might have been less loud and exciting. Darier vitiates his experiment by the employment of several drugs, as we so often do in medicine. This, I believe, was wholly to the detriment of his patient; nevertheless, the argyrol solution having been used freely and frequently day and night, the eye was out of danger in four days.

This paper having already transgressed in length my wish and expectation, I refrain from advancing, as I had intended, any collateral evidence.

In the *Ophthalmoscope* for January, 1906, Mr. James Hinshelwood of the Glasgow Eye Infirmary, relates his experience with argyrol solutions in many other affections of the eye. As his experience corresponds quite closely with my own, permit me to close by submitting the following

CONCLUSIONS.

1. The treatment of gonorrhœal conjunctivitis with argyrol is efficient, provided it is instilled often enough (every 15 to 30 minutes) to keep the diseased tissues practically immersed in the solution.

2. The instillations must be continued day and night so as to render the immersion constant and afford the gonococci no chance of unchecked activity.

3. Until the formation of pus has wholly or virtually ceased the eye should not be irritated by any manipulation or the instillation of any other substance.

4. The less virulent course of the disease when so treated confirms the belief that more strenuous methods often abrade the weakened epithelium of conjunctiva and cornea, and open ways of invasion to the gonococci.

5. As always, the best results are had when the remedy is

thoroughly applied in the beginning of the disease. This can be done no matter how swollen or brawny the lids; a thing not possible with less diffusible liquids or with those which must be applied to the everted lids. It is excusable to repeat, that eversion is dangerous in the early stage when the epithelium is softened and pus formation still profuse.

6. Under this plan corneal ulcers are uncommon, and when they do appear are held in check and do not produce widespread destruction. Corneal ulceration, then, far from forming a counter indication, gives an additional reason for its vigorous employment.

7. Argyrol is not a powerful astringent; therefore, as soon as pus formation has ceased and the lids have become flaccid, $AgNO_3$ solutions should be applied to the everted lids once daily to hasten the reduction of the conjunctiva.

Soaking corneal ulcers once a day in a 50% solution of enzymol seems to cleanse them, as well as the conjunctiva, and thus promote recovery. During this period the frequency of the argyrol instillations should be gradually lessened.

8. In monocular cases the safety of the unaffected eye is secured by instilling the argyrol solution but one-half as often as in the infected eye.

9. The method is far less painful, especially in the acute stage, than any other yet proposed. This is an advantage not merely of good feeling, but enables us to treat many who, even at the cost of an eye, refuse to tolerate severer methods.*

10. I have never observed argyrosis following the use of argyrol.

DISCUSSION.

Dr. George M. Gould, Philadelphia. About ten years ago Dr. Pyle and myself devised a little instrument, which I think would be useful in carrying out this idea of Dr. Bruns. It consists of a lid elevator with a series of small holes around the inner edge.

---

* From 1893 to 1903 only 39 cases out of 157 remained under treatment until discharged. During the past three years 31 cases out of a total of 59 cases remained under the argyrol treatment until discharged.

The discomfort of frequent instillations during the night is less than one imagines. The application being painless, by the second night the patient is rarely awakened.

You can wash out the eye with a stream of water from a source suspended about five feet without irritating the eye in any way. This little device may be employed regardless of what solution is used for washing out and controlling the pus formation. I myself think pure water, or a normal salt solution, as effective, and less dangerous, as the use of germicides. The essential thing is frequency of cleansing.

DR. ALEXANDER DUANE, New York. In experiments made by Groenouw in 100 cases of ophthalmia neonatorum, he found less than 50% produced by gonococci infection. These latter were treated in alternate cases with silver nitrate and protargol, and Groenouw found that the cases treated with protargol not only get well quicker, but that the gonococci disappeared more rapidly than with the use of the silver nitrate.

DR. F. H. VERHOEFF, Boston. (Explaining on the blackboard, with drawings, the methods used in making bactericidal tests). While Dr. Derby's results are satisfactory from a comparative standpoint, I do not think they give a fair idea of the real antiseptic properties of the various preparations. For instance, in the case of protargol, after an exposure of thirty seconds to the one per cent. solution, it is rare to obtain even a single colony at the end of 24 hours. This certainly indicates a powerful bactericidal effect. If, however, as is done by Dr. Derby, the water of condensation is again flowed over the solid media, at the end of another 24 hours there will usually be a multitude of colonies. This is no doubt due to the escape of a few organisms from the action of the antiseptic, possibly owing to their floating on the surface of the fluid, or to their having been protected by an air bubble. In the case of argyrol, even the 50% solution requires an exposure of over twenty minutes before there is an appreciable reduction in the number of colonies, and several colonies are usually found after an exposure of an hour. The results indicate, therefore, that a 1% solution of protargol is over one hundred times as bactericidal as a 50% solution of argyrol. Protargol as well as argyrol, however, is rendered ineffective when mixed with serum, and hence can have no effect on bacteria within the tissues.

These antiseptics are undoubtedly of some value in the treatment of simple conjunctivitis, since by disinfecting the conjunctival sac they decrease the number of organisms and the amount of

toxin with which the tissues have to contend. But the actual cure of the infection depends solely upon the bactericidal action of the patient's serum and leucocytes, in other words, upon the resistance of the patient. If this is insufficient, as it is in gonorrhœal ophthalmia, the use of antiseptics is unavailing.

As to the comparative value of clinical and laboratory methods, we all know that clinical statistics may be made to show almost anything. Laboratory experiments are valuable in offering a rational basis for clinical experimentation. The clinical use of these silver preparations in gonorrhœal ophthalmia, however, is clearly based on a misconception of their effective bactericidal powers. If, as it is claimed, argyrol really penetrates and kills the bacteria within the tissues, there would be no doubt in regard to it in the mind of any one. It would be an exceptional thing for a case *not* to be cured by it.

Dr. Standish takes in his statistics only the cases which enter the hospital with clear corneæ. Such cases must necessarily be of a less malignant type. If argyrol can cure these cases, why can it not cure the ulcer cases also?

Dr. G. E. de Schweinitz, Philadelphia. First, I desire to express my high appreciation of the three important papers which have just been read, and particularly to compliment Dr. George Derby on his admirable presentation of his side of the question. To discuss the subject of the value of protargol and argyrol as compared with nitrate of silver would lead into too long a discussion, and I am therefore contenting myself with giving my personal experience, and it is remarkable how observers differ in the results which have been obtained. I began in the fall of 1902 to use argyrol, and like many others was at first, if I may so express myself, hypnotized by this remedy, but with accumulated experiences have gradually changed my views. I entirely agree with Dr. Bruns that it is a substance of service under certain conditions, largely because it is bland and harmless and free from the objections which the irritating quality of nitrate of silver possesses, but as compared with this medicament under the conditions at present in discussion in my judgment it is not nearly as valuable a remedy. Should I be so unfortunate as to have a gonococcal infection of my ocular conjunctiva, I would certainly not be satisfied to permit argyrol alone to be the remedy of selection, and this I think would be the opinion of those who assist me in my clinical service and of a number of my colleagues,

who with myself have recently discussed this remedy in the Section of Ophthalmology of the College of Physicians of Philadelphia, the results of which have already been published. In one hospital, where a number of cases of gonorrhœal ophthalmia are treated in my wards, there have occurred since I began to use this remedy 88 cases of gonorrhœal infection of the conjunctiva, divided as follows: 37 gonorrhœal ophthalmia of adults and 51 gonorrhœal ophthalmia neonatorum, and it should be remembered that only those are included in which bacteriological examination has demonstrated the presence of gonococci. I have a right to speak only for my own service, and therefore, as there are four of us on this staff, of about one-fourth of these cases, although I am also quite familiar with the work in the wards of one of my colleagues, who is in entire accord with my own views. I believe also that my views in this respect are shared by still another colleague, namely, Dr. Oliver, but as he is present he can make his own statements. In a word, referring again to those cases with which I am personally familiar, as well as to the cases treated by Dr. Hansell, and therefore to about one-half of these patients, argyrol in our experience has ceased to be a safe and satisfactory remedy. Personally, I continue to use the drug and have found it useful in the infantile form of the disease, namely, in ophthalmia neonatorum, largely because it is bland and unirritating, and not in any sense superior to nitrate of silver, but I do not think these cases are the ones on which we should base our opinion as to the value of this remedy, because, with certain well-known exceptions, if properly treated from the beginning, they practically always get well with any reasonable method of treatment. Referring especially to the case of adult gonorrhœal ophthalmia, I may say, in the first place, that, as in the Massachusetts General Eye and Ear Infirmary, they are all placed in an isolation ward, they have special nurses in attendance, and the plan of treatment is practically that which Dr. Bruns has so well described as the "immersion method." After some correspondence with Dr. Bruns, I exactly followed his method, in other words increasing the frequency of the drug so that the conjunctival sac was kept constantly bathed in a 25% solution of the remedy, and yet I have within the last year been obliged either to discontinue it and resort to nitrate of silver, or to follow Dr. Bruns' plan, and use it in conjunction with nitrate of silver. The pharmaceutical chemists who have developed argyrol are most accomplished men, and no one would be happier than I if

they had been able to produce a remedy which was superior to nitrate of silver, but they have not succeeded in so far as the treatment of this disease is concerned, nor has any other substitute for nitrate of silver, in my judgment, reached this position among the remedies at our disposal.

It is not the purpose of the present discussion to develop what value argyrol has in other conditions, because it certainly has very great value, and it has value in gonorrhœal ophthalmia if used, as Dr. Bruns uses it, in connection with nitrate of silver. It is harmless, bland, but unfortunately of itself inefficient, and it is my deliberate opinion, based not upon impressions but upon the results achieved by careful clinical work, not only in the wards of the Philadelphia Hospital, but in my service in the University Hospital, that it is not satisfactory in checking the invasion of gonococci, and up to the present time I have never seen any preparation which for this purpose equals nitrate of silver, when properly applied, and it is quite important that the term " properly applied " should be emphasized.

I have also made a considerable investigation in the maternity hospitals of Philadelphia, not only those in which my own examinations allow me to speak with authority, but in those under the care of colleagues, and without exception have found that they, as well as myself, have ceased to regard argyrol as in any sense an efficient substitute for nitrate of silver in the prevention of gonorrhœal ophthalmia neonatorum.

In a word, then, while freely admitting the value of the remedy as a non-bactericidal agent, bland and unirritating, and therefore of use in the manner already described, it cannot, in my judgment, be regarded in any general sense as a substitute for nitrate of silver, nor can it substitute this remedy in the treatment of of gonorrhœal ophthalmia of adults, when properly used.

Dr. Samuel Theobald, Baltimore. I want to say a word in favor of the newer silver salts. It is remarkable to see such absolutely contradictory results in the hands of equally competent men. I have not used silver nitrate in gonorrhœal ophthalmia now for a number of years, and I have certainly not had occasion to regret having made the change. I am sure I get just as good results as I ever did, if not better. We know that protargol and argyrol are less irritating and if we obtain even equally good results it is certainly well to use them. I have had more experience with protargol, and only recently have tried argyrol. As to

protargol, I have no more doubt as to its efficacy than I have as to the efficacy of quinine in malarial fever. The other treatment I employ is hourly cleansing of the eye with a saturated solution of boracic acid, and in the adult cases ice cloths. Atropin is used when the cornea is involved. I have heretofore pointed out the unwisdom of postponing the use of silver as writers commonly advise, until the purulent stage of the disease has become established. I have never lost the second eye in gonorrhœal ophthalmia, and the explanation to my mind is that I knew what to anticipate, and the moment there was evidence of infection of this eye I began the use of silver nitrate. Now I begin with protargol, under similar circumstances. It is a mistake to wait, and let the disease become fully established before beginning the use of the silver salt.

Dr. S. D. Risley, Philadelphia. I am reminded by this discussion of a paper presented before this society by some gentleman whose name I do not recall, in which he said he had found a panacea in constantly filling the conjunctival sac with vaseline. Dr. Wilson, of Bridgeport, I think it was, and he was very enthusiastic. It may be therefore that the constant application of this solution of high specific gravity may act very much in the same way as the vaseline and I am sure that the vaseline is very often useful and soothing.

My own feeling has been exactly expressed by my fellow townsman, Dr. de Schweinitz. I have long since abandoned the use of the newer salts of silver. It seems to me it is one of the methods by which silver costing about 48½ cents is sold for $2.48. I have no doubt that the results set forth by Dr. Bruns are true, but many other things would be efficacious when used with the same technique. To keep the sac clean is the sine qua non.

I was struck, however, with one remark of Dr. Bruns', that is that it should be stopped when the purulent secretion ceased. Now I have a suspicion, and I would insist upon the word "suspicion," that we are getting a new group of corneal and conjunctival diseases that does not quite fit into any of our classifications, since the use of these salts, a thickened conjunctiva and cornea that does not pacify readily, extremely chronic and difficult to manage, and it has seemed to me that in all these cases the eyes have been subjected to the prolonged use of one or more of the new silver salts. My suspicion in this respect was first aroused by a private patient with a small corneal ulcer. I hesi-

tated about cauterizing it, and as I had in my office some little discs saturated with one of these salts I used them. The suppuration in the ulcer ceased, but there was a circular area around the ulcer, which was in the lower temporal quadrant of the cornea, which had a peculiar appearance and which when studied with the loupe presented very much the same appearance that we see with the naked eye in looking at a piece of tanned hog skin, a peculiar elevation over the surface. In Philadelphia there have been a number of cases of curious corneal disease reported under various designations of late and I have had a large group of these in my service at the Wills Eye Hospital, cases that I did not see in former years, and it has occurred to me that there might be some truth in the claim that these salts do penetrate more deeply than nitrate of silver, which protects the cells, and a slight eschar forms over the surface. The deeper cells in the conjunctiva or cornea may be changed by the penetration of this chemical, and, with this suspicion, I would hesitate to use it.

BOSTON MEDICAL LIBRARY JAN 26 1907

Dr. D. B. St. John Roosa, New York. I rise to strengthen, if possible, two points, one brought out by Dr. Theobald, and the other by another speaker, as to the use of nitrate of silver. It happens to me at times to have charge of nurses who are exposed, in spite of every care, to infection from the vaginal discharges of children in the hospitals, and I would no more dare, once certain of the infection, to omit the immediate use of silver nitrate, than I would dare to omit stopping a severe and acute pain in the ear at the very first moment. It has been demonstrated to the minds of perhaps all of us that we have in the early use of silver nitrate an assurance that we will carry such a case to a successful termination.

The other point Dr. de Schweinitz made, but passed over rather lightly, I think should be impressed upon the minds especially of the younger men and students. It is a pity that we should ever be obliged to treat a case of purulent conjunctivitis as an ambulant case, but from want of money we cannot treat them all in a hospital ward, and that is the proper use of nitrate of silver. As long ago as my attendance upon Graefe's clinic, when he was so determined in the use of the mitigated stick (and I saw so much of that in the hands of his assistant, Dr. Arndt), I got a terror of the man who did not know how to use nitrate of silver. It is an art to know how properly to employ nitrate of silver and sulphate of copper.

In regard to the vaseline treatment, Dr. Wilson should have the credit for that. I have myself discarded it entirely even as a dressing after treatment.

DR. G. C. HARLAN, Philadelphia. Some years ago some one proposed as a sure cure the constant use of glycerine. It seems to be generally admitted that strong solutions of argyrol are harmless, unirritating and dense, and it therefore offers a good means of cleansing the eye. Glycerine certainly has all these properties and would probably answer as well.

As to the immediate application of strong solutions of nitrate of silver, a case came under my observation some years ago that might have some bearing on that question; a case of violent conjunctivitis in which I intend to use a solution of 1:5,000 bichloride. By a mistake a cipher was dropped and a solution of 1:500 used, with the result that the disease was cut short at once.

DR. EMIL GRUENING, New York. As Dr. Roosa has said, it is an art to use the nitrate of silver, and I fear it is becoming one of the lost arts. Early in my career I also was taught how to use it by Von Graefe, but when protargol and argyrol were produced I had the solutions made of various strengths and used them. My results were not very satisfactory, and I returned to the use of silver nitrate. I left my office and went to Europe and when I returned I found that all the solutions of protargol and argyrol contained mold. Now it is quite possible that these substances which will cause mold and other saprophytes to grow, may produce also the diseases of the eye that Dr. Risley has spoken of. I always compare these salts to the new breakfast foods which are so extensively advertised, but we still have our standard, oat meal, to which we all recur. I have given up completely the use of protargol and argyrol.

DR. T. R. POOLEY, New York. If we can possibly divert some of these enthusiasts from what seems to me to be a very dangerous and inefficient plan of treatment it will be well. Together with my colleagues I have gone through the experiments and have returned to the use of nitrate of silver, and I am convinced of the inefficiency of the newer salts. I should classify those preparations as bland, harmless, and inefficient.

DR. CHARLES A. OLIVER, Philadelphia. I agree with Dr. Roosa in reference to the inadvisability of the ambulant method

of treatment, and the inefficiency, and in fact, the ofttimes dangerous uselessness of any other of the salts of silver than the nitrate. These beliefs are based upon an extended experience with the various nascent silver salts in the out-patient practice of Wills Hospital, and during my term of service in the ophthalmic wards of the Philadelphia Hospital, and the more recent findings of expert bacteriologists.

Fully ten years ago, I realized — though frequently continuing and trying other forms of treatment as they appeared — that freshly prepared weak solutions of nitrate of silver applied by careful patting with almost dry swabs of cotton, just often enough to keep a thin pellucid covering of albuminate of silver over the affected areas, gave the best and the quickest results, with the least amount of injury to the exposed tissues. Every case was subjected to bacterial study when first seen, and no case was admitted to the isolation wards unless so proved. The grading of the remedies and the applications was based upon the daily microscopic findings, and the general condition of the patient was brought to the best possible state, as so pertinently taught us several years ago by Dr. Randall. In brief, the local treatment resolved itself into repeated general cleaning of the parts with sterile water, or better, as suggested by Dr. Derby, common salt solution, by experienced nurses; the killing of the floral germ and of course, the enveloping or most closely surrounding faunal cell, with nitrate of silver applied by the attending surgeons; and the hibernation of the floral cells by the use of iced compresses to prevent rapid sporulation. Care was always taken in those cases in which the corneal tissues had been involved when first seen, or later — though fortunately, but very seldom, during treatment, to discontinue the cold, and even, in spite of ordinary contraindications, to substitute judiciously applied warmed compresses in order to keep up the vitality of the parts. Atropine, sufficient to get the iris out of the way, was always employed. The internal use of cubebs, copaiba, and oil of sandalwood, particularly in self-infected cases, was always resorted to; while rest in bed, with regular ingestion of sufficient quantities of easily digested food and large amounts of pure potable water, was insisted upon. As a result, based upon a great number of cases, by reason of the Philadelphia Hospital being almost the only one in the city of Philadelphia which will receive such cases, there have been but four losses of eyes which had not been admitted as practically lost ones, during a period of twelve years

in which, with the exception of one month, I have never been without such a type of case. The experience of one of my colleagues, Dr. Hansell, who has also written upon this subject, is, I feel sure, much the same.

As Dr. Verhoeff has mentioned, it is very greatly a question of leucocytosis: It is a question of soil, protector and invader. The germ being a metatrophic one, the serum-holding faunal cell should be protected by an artificial covering. In fact, I have long considered it as certain that a pathologic or accidental traumatism is in the main responsible for the entrance of the germ into the deeply seated and the ordinarily protected living cells. As previously noted by both Duane and myself, gonococcal conjunctivitis is most probably at times, the main resultant of a mixed infection, the paratrophic invaders having prepared the way for those giving the later gross clinical entity. So-called ophthalmia neonatorum, even when gonococci have been found present, is seldom if ever to be feared in sthenic cases; this probably by reason of the shallowness of the cul-de-sacs, the fewness of the rugæ, and the almost complete absence of underlying lymphatic tissue.

In regard to the studies of Dr. Randolph, it may be interesting to state that in a comparative study of the effects of the presence of the typhoid bacillus in the eyeball, which I have made in conjunction with Dr. Flexner (the partial results of which are to be found in the Transactions of this society), the presence of the offending germ in the affected tissues, as sometimes seen clinically expressed in the corneal structures and uveal tract of the human subject, was determined in every case in which a too gross protecting leucocytosis and lymphocytosis had not been provoked.

Dr. Herbert Harlan, Baltimore. Several of the gentlemen have alluded to serious results in the treatment of out-patients. I began my experience in 1880 at the Presbyterian Eye and Ear Hospital, where we have about 7,000 eye cases a year, and every case was treated as an out-patient. Each day they came to the clinic and were instructed as to the method of cleansing the eye, and solutions of nitrate of silver, 5 gr. to the ounce, were used. They were instructed to keep the eyes cleansed every fifteen minutes, and these instructions were made very emphatic. It was the rarest exception to lose one. I think I may say that we never lost one, except where the cornea was sloughing before the patient was brought in. I do not imagine for an instant that the

instructions about keeping the eyes cleansed at home were carried out in half the patients, but I always did believe the good results were due to the nitrate of silver. With that experience I cannot help but believe that nitrate of silver is very efficacious.

And though I have been using argyrol extensively and almost exclusively in these cases for several years, I admit that if I have a very serious case I usually put in nitrate of silver a few times.

Dr. W. T. Shoemaker, Philadelphia. Is there any danger of discoloration of the conjunctiva from argyrol? Last winter in Los Angeles I saw a patient who had had an injection of argyrol in whom there was pronounced discoloration.

Dr. Robert L. Randolph, Baltimore. I recall some observations made six or eight years ago by two Vienna opthalmologists in 300 cases of blenorrhœa of the conjunctiva, in both adults and infants, for the purpose of determining the relative value of these three salts of silver, and the conclusions they reached were that while the newer silver salts were very valuable in a certain number of cases, there were some cases where they had to resort to the nitrate of silver, particularly in cases where the individual was badly nourished — where there was evidence of general lowered vital resistance. The inference was that there are some cases in which nothing will take the place of nitrate of silver, and that is in accord with my own experience. When protargol made its appearance I had one of my students make repeated experiments in the clinic with this product, and I was decidedly disappointed with the results obtained.

Dr. Wm. H. Wilmer, Washington: The great advantage of argyrol is that it can do no harm when used by ignorant patients, therefore Dr. Bruns has had excellent results with it in his out service department. Nitrate of silver can do a great deal of harm, if not properly and carefully applied. I have never seen any harmful results from argyrol. I believe that nitrate of silver is absolutely necessary in some cases to save the eye. Where there is marked conjunctival involvement, one application of nitrate of silver is often very beneficial because of its marked astringent power. I think therefore that it is not well to rely entirely upon argyrol. Where there are corneal lesions, too, I think some bland substance should be used to protect the cornea. It is also very important to use irrigation to wash out the pus and gonococci

and strands of coagulated muco-pus in order to have a clean surface for the action of the drug. Adrenalin properly applied I think adds to the efficacy of argyrol or nitrate of silver. It acts as an adjuvant.

DR. JAMES THORINGTON, Philadelphia. From the excellent papers just read on the use of the silver salts, and the general discussions which have followed, and from personal experience in my private practice and my clinic at the Philadelphia Polyclinic, I wish to express my opinion of the comparative merits of the new or weaker silver salts with the old reliable nitrate of silver, by telling of a patient of mine who permits his wife to employ a homeopathic physician for the children when there is nothing very much the matter, but when a serious illness develops he insists upon calling for the "old reliable."

DR. H. D. BRUNS, New Orleans. (Closing discussion.) As few of you know me, permit me to say that I have practiced the art of ophthalmology for twenty-five years; I have lived through many and am not likely to be taken up with some new fad. Because a man urges his views with enthusiasm it does not necessarily mean that his judgment is carried away; he may be earnestly striving to contribute something to the advancement of science.

Let us in the first place eliminate a few facts on which time has been wasted. Ophthalmia neonatorum should not enter into the debate at all. We all know that these cases get well with simple, adequate cleansing. Therefore they should be set aside.

In the second place, let us grant that nitrate of silver is the most efficient germicide we can use in these cases. The point is how are you going to use the nitrate of silver, when, how often, and by what method. It is useless to make vague assertions about the art of applying nitrate of silver. It must be taken for granted that a well instructed ophthalmologist knows how to apply it. I was taught by a student of von Graefe myself. But, will you tell me how you are going to apply nitrate of silver when a man comes to the clinic with an eye as big and brawny as your fist? You can not; and you can apply argyrol.

In the next place, let us take out of the debate, if you please, the question of bactericidal effect; this constant washing with argyrol until the time of suppuration has passed removes all risk of trying to evert the lids; and it is a risk, gently and expertly

as you may do it, when a man has a swollen lid, an infiltrated conjunctiva, and the epithelium of the cornea ready to break down at any moment.

Now some one says anything will do. Yes, but name the anything. This particular thing is better adapted to washing out and keeping the eye clean and free from pus, especially when you can not get the services of skilled nurses, than anything else.

Another point: Dr. Standish and myself are dealing with actual cases that we present to your consideration, tabulated. I have kept tabulated records all my professional life. I know how fallacious any man's general impressions are about the cases he treats. Some isolated case makes an impression on his mind and he thinks all cases behave that way, but if he takes a hundred cases and tabulates them he discovers how fallacious his impressions may be. Let those who think that there is a better method, one which gives better results, is safer and more pleasant to the patient, tabulate their cases and bring them to proof in that way, but not oppose what has been tabulated and organized by mere general impressions. For my own part, if I have instructed myself in any one thing it is that a general impression is one of the most worthless things a man can be possessed of.

Dr. Miles Standish, Boston. Like Dr. Bruns, I have been very much interested in this discussion and think it has passed very wide of the mark. I brought here, as Dr. Bruns has said, statistics carefully compiled. It has been criticised that my cases were not severe ones; that, in my opinion, is due to the treatment. The eyes where the cornea was involved upon entrance were excluded because there was no means of classifying them as to whether they did better under this than under other methods of treatment. Now no one will disagree with the gentleman who, if he had a squirt of gonorrhœal pus in his eye, would prefer to use nitrate of silver at once. I believe it is the most efficient bactericide for gonococci in the eye lying on the surface, and if that is all you want to do, it is the best agent possible, but it is the danger of applying nitrate of silver in gonorrhœal ophthalmia that is the objection. Undoubtedly in Philadelphia they have very great skill. But in the days when we used nitrate of silver in our wards accidents did happen. We had abrasions of the cornea due to the unskillfulness of ourselves, our house officers and our nurses. If these eminent gentlemen from Philadelphia will come and take care of my eye when I happen to get a squirt

of gonorrhœal pus in it they are at liberty to use nitrate of silver if they will guarantee not to injure the eye making the applications.

I have brought here statistics of an entire staff using argyrol, the statistics and the results. I am absolutely delighted to know that there are other great institutions in which the nitrate of silver is still used and I herewith invite their statistics.

DR. GEORGE S. DERBY, Boston. I would call attention to one or two points. In regard to the remark that was made as to the use sterile water, I would suggest the use of isotonic saline solution instead. I would also mention, in connection with the remark about argyrol remaining in the sac a long time, that it is very strong in pigment. The nitrate of silver is especially valuable in cases of lowered nutrition, as has been suggested.

OPERATION FOR REMOVAL OF NASAL EPITHELIOMA FOLLOWED BY PANOPHTHALMITIS.

BY PETER A. CALLAN, M.D.,

NEW YORK CITY, N. Y.

M. C. M. 70.

The following history was furnished me by the patient's physician, Dr. Thomas Kelly.

Patient for the past six years had suffered from enlarged prostate — cystitis — and interstitial nephritis. He had sought the doctor's advice quite recently on account of a small epithelioma on the nose which had developed on the right ala. It had been there about six weeks, and of late it had increased rather rapidly. The growth was circular in outline, with raised indurated edges; the center was granular, and bled at times. Dr. Kelly advised its removal by a surgeon. Operation was performed April 28th, 1904, at 1 p. m., under the local injection of cocaine. During the injection of the cocaine, the patient complained of pain in right eye. At 9 p. m., eight hours after

operation, he was semi-comatose — temperature 104° and pulse 100. It appears that he had neglected to use the catheter during the day. When the patient was catherized and twelve ounces of urine withdrawn the untoward symptoms disappeared. When seen by the surgeon on the following morning, the general condition was good, but he complained of pain in the right eye. During the day the pain grew gradually more severe and especially as the night advanced it became intolerable. At midnight he discovered that the eye was blind.

I was called in consultation in regard to the condition of the right eye, fifty hours after the operation, and found as follows:

Eyelids were swollen and tense, right eye was protuberant. It was only with difficulty that the tense swollen eyelids could be separated, causing the patient great pain. The chemosis was very pronounced. There was a yellowish white reflex from anterior chamber due to a thin layer of hypopyon which partially covered the iris. Pupil was contracted and immobile to light. There was slight light perception. Tension +3.

Close examination of the cornea showed cross hatching of the deeper layers. Panophthalmitis.

For seven days the tension and inflammation remained about the same. On the eighth day the tension was less and the inflammation gradually subsided, due to spontaneous rupture of globe.

I did not see the patient again for eight weeks, when I found the eyeball shrunken to one-third its normal size. About one month later there developed a tumor attached to the spinal column in the lumbar region. This growth grew to a very large size and he soon showed evidence of a general carcinomatous cachexia from which he died one year after the attack of panophthalmitis.

Metastatic inflammation of the eye is not so rare, especially where there is a general sepsis.

When it follows operations the cases are fortunately not often seen.

Operations on the uterus, especially curettage—paraffin injections into the nose for cosmetic purposes; and operations on the face have been followed by metastatic inflammation of the eye. Nagel,[1] in 1860, published in the *Archiv für Ophthalmologie* an article on fatty degeneration of the retina. He refers to an operation for Struma Cystica of the Thyroid, followed by embolic Retinitis, promised later to give full details, and in the article gives the results of an elaborate microscopic examination which he made on the enucleated eye.

During the past four years six cases of sudden monocular blindness have been placed on record. These cases were operated on by hypodermic injections of liquid paraffin to remedy "saddle" deformity of the nose.

Leisser,[2] January 24th, 1902. After the third hypodermic injection of paraffin, the patient collapsed, but recovered after the injection of ether and artificial respiration, although he continued to vomit for hours. On recovering consciousness patient found left eye totally blind. Dr. Rischmuller examined the eye on the following day. The upper lid was œdematous, globe injected, pupil non-responsive to light, aqueous cloudy. Ophthalmoscopic examination difficult. Optic pupilla unchanged; surrounding retina œdematous. Mobility of globe limited down and outward. Tension — 1.

January 26th, '02. Hyperæmia of the globe increased. Cloudiness of aqueous humor more pronounced.

January 27th, '02. Œdema of lids — lachrymation. Hemorrhage into iris tissue.

January 28th, '02. Media clearer. Optic disc red. Veins well filled. No retinal hemorrhage.

February 2d, '02. Beginning pallor of optic nerve head.

Dr. Hurd,[3] April 24th, 1903.

Patient an Italian, 32 years, had received on two previous occasions paraffin injections for the repair of saddle nose. At

[1] Archiv für Ophthalmologie, V. I: 1860, p. 200.
[2] Vereinsbeilage der deutschen Md. Wochenschrift, April 3, 1902, p. 210.
[3] Medical Record, July 11th, 1903.

patient's solicitations a third was given. During the last injection patient rubbed his eye and complained of not being able to see. When, twenty-five minutes after the operation, Dr. Ward A. Holden saw him —" Eye blind — pupil dilated — not responsive to direct light rays. Ophthalmoscope showed main inferior branch of central artery and its subdivisions empty. The main superior branch contained some blood."

Mintz.[1] September 2d, 1904.

Patient (25 years) had two injections of paraffin at intervals of a year. The second hypodermic injection was made September 2d, 1904. Three minutes after injection patient complained of pain in left eye, could not count fingers, and in a short time blindness was total. Vomiting, pulse 48. Ophthalmoscopic examination showed no defect in fundus — eye ground normal — no embolism nor thrombus. Paresis of internus and inferior rectus and inferior oblique. Pupil somewhat enlarged.

September 3, 1904. Œdema of eyelid; exophthalmus. Some mobility up and outward of the globe; pulse 48 to 56.

September 4th, 1904. Increase in the œdema of lids. Chemosis; hazy cornea.

September 5th, 1904. Immobile globe; cornea more opaque.

September 6th, 1904. Slight pain in eye; opacity of cornea more pronounced.

September 10th, 1904. Slight movement of globe; cornea less opaque.

September 13th, 1904. Iritis.

October 10th, 1904. Some pericorneal infection. Cornea clear. Whitish exudate on anterior capsule; post synechiæ hyperæmia of fundus.

Oct 20th, 1904. Vessels can be distinguished.

November 16th, 1904. Atrophy of optic nerve.

Patient had a gangrenous spot on nose near point of injection.

Moll,[2] at a society meeting, reported a case of blindness following paraffin injection for the repair of saddle nose, which

[1] Centralblatt für Chururgie, Jan. 14th, 1904, p. 47.

[2] Ann. des mal de l'oreille, du larynx, du nez et du pharynx, 1902, p. 520.

had been published in an Edinburgh medical journal. No further details were given by Moll, other than that the blindness was due to an embolism of the central artery.

Rohmer[1] gives in detail a case which he examined fifteen months after the onset of blindness following a paraffin injection. The patient, a female aged forty-two, had between five and six injections by an inexperienced surgeon, all within three weeks. During the last injection the patient experienced great pain in the left eye and at the same time discovered that the eye was blind. The eyelid became red and swollen and the patient suffered pain for several days. An oculist, who examined the patient on the following day, diagnosed it as embolism of the central artery. When Rohmer saw the patient, fifteen months later, there was no question in his mind but that the blindness was due to thrombosis of the central vein.

Uhthoff[2] reports a case of a woman, aged forty-five, who had paraffin injections for the repair of saddle nose. Three injections had been made within a space of eight months, and during the last paraffin injection the patient complained of sudden blindness of the left eye. She experienced no pain, but had some lachrymation. On her way home from the surgeon's office had slight vertigo. The left eye was examined on the following day by an oculist, who discovered that the blindness was due to an embolism of the central artery. Œdema of retina, cherry-red mac. lutea and small vessels. Patient's eye was examined one week later, by another oculist, who coincided with the former diagnosis. Uhthoff saw patient two weeks following the last injection and onset of the blindness. He found the case was then typical of embolism of the central artery. The pupilla had commenced to show signs of pallor, and had fuzzy edges. The retinal arteries were hardly visible and no amount of pressure of the globe could cause pulsation. The pupil did not react to direct rays of light, but did consensually.

The seven cases of monocular blindness included in this re-

[1] Ann. d'Oculistique, Sept., 1905, p. 163.
[2] Berliner Md. Wochenschrift, Nov. 20, 1905.

port were due to nasal injections; six were due to paraffin and one to cocaine.

The injections of paraffin were given to repair saddle nose deformity, and the cocaine was used as a local anesthetic for the removal of an epithelioma of the nose.

The monocular blindness in two of these cases was undoubtedly caused by embolism of the central artery, viz.: Hurd's and Uhthoff's.

In regard to the case referred to by Moll as having occurred in Edinburgh, there are no details; so we must place that in the doubtful column.

In the cases of Leisser, Mintz, Rohmer, and my own, these certainly were not due to embolism of the central artery.

My case might be due to an infected embolic chorio-retinitis or embolic retinitis.

The history of the other three points more to thrombosis.

The cases of Hurd and Uhthoff were caused by the entrance of paraffin into the general circulation; but in the cases of Leisser, Mintz, and Rohmer, the natural presumption is that we have to do with local transit of the paraffin from the veins of the nose to the ophthalmic and not through the general circulation.

PRELIMINARY NOTE ON ENUCLEATION OF EYEBALL UNDER LOCAL ANESTHESIA.

BY H. DICKSON BRUNS, M.D., AND ERNEST A. ROBIN, M.D.

Chief of Clinic Eye Department of the E. E. N. & T. Hospital.

Since October 12th, 1905, my associate and chief of clinic at the Eye, Ear, Nose, and Throat Hospital has been experimenting with a method of local anesthesia in enucleation of the eyeball. We have used it with success now in twenty cases, both in private and hospital practice. The mixture used, in all cases, consists of ten drops of a 4% solution of cocaine, ten drops of adrenalin chloride 1-1000, and twenty drops of normal salt solution, making forty drops, containing altogether 2/5 of a grain of cocaine.

With a hypodermic syringe, ten drops of this mixture are injected along each rectus muscle deeply, behind the equator of the eye, and after a five minute wait the operation is performed in the usual way. Our observation so far has been that the method is thoroughly practicable, though not entirely devoid of pain.

Three cases gave no evidence of suffering throughout the entire operation. Those who complained of pain always referred to it to the last stage of the operation, that of cutting the optic and ciliary nerves, the stages of dividing the conjunctiva and tendons being particularly free from pain. Those who suffered most in the last stage compare the pain to having a tooth drawn. Generally speaking we have noticed that robust and full-blooded men, above the average in weight, complain more of pain than the frail and delicate. This would seem to suggest the use of a larger amount of the mixture in the former cases. A few of the advantages of the method of local over general anesthesia are:

The patient is conscious, and by that fact stands warder against the awful error of removing the wrong eye. The amount of cocaine used (2/5 of a grain) is almost insignificant, and certainly incomparably safer to life than any form of general anesthesia. Finally, the patient seems to prefer it, for we have, since our first case, of October 12th, had no trouble in inducing all patients upon whom the operation had to be done, to select this method.

UNILATERAL ROTARY NYSTAGMUS.

BY ALEXANDER DUANE, M.D.,
NEW YORK CITY, N. Y.

The following case is reported on account of its rarity:

Mrs. O. B. A., aged 24; first seen May 10th, 1906. For several years, but especially during the past few months, has noticed that at times she sees double (one object rising vertically out of the other) and that the objects she is looking at appear to dance

up and down. Has also noticed when looking in a glass that the left eye oscillates. Six years ago had a suppurating gland in the neck, which was removed two years later. Typhoid fever three years ago. Has otherwise been perfectly well.

Both eyes normal exteriorly. Fundi normal, except that in both, but especially in the left eye, are groups of punctate brown or blackish dots in close relation with the retinal vessels. No atrophy of adjoining choroid or retina and interior otherwise normal, although details of left fundus are somewhat blurred by the nystagmus.

Vision 15/15 — each; under homatropine shows for far distance:

R. + 0.50 + 0.25 cyl. 155°

L. + 0.50 + 0.25 cyl. 40°

Fields and color fields, pupils and pupillary reactions normal.

Excursions of eyes normal in all directions, but converging power is weak (convergence nearpoint 6″ from root of nose). Tendency to slight vertical diplopia in various parts of the field of fixation, but this is evidently due, not to paresis of any of the ocular muscles, but to the nystagmus. That is, the only way in which she sees double is that an object looked at will suddenly separate into two images, which then rhythmically unite and separate again.

In the right eye no trace of nystagmus; not the slightest oscillation being detected even with the ophthalmoscope. In the left eye at times no vibration, at times true nystagmus, consisting of rapidly repeated, short, quick, to-and-fro oscillations. In the primary position the nystagmus seems to be sometimes mixed (vertical and rotary), at other times purely rotary (opposite to the hands of the clock). When the eyes are directed to the right the nystagmus is largely vertical; when they are directed to the left, the nystagmus is slow and mainly rotary. Nystagmus is present also when the eyes are directed up or down. If the head is tilted to right shoulder, marked rotary nystagmus; when head is tilted to left shoulder, slow rotary or more marked verti-

cal nystagmus. Nystagmus not arrested by covering either eye, and seems rather more marked when the left eye alone is used for fixing. It is also somewhat greater in forced convergence.

No evidence of ear disease beyond a slight catarrhal otitis media.

Careful examination by Dr. Joseph Collins shows absolutely no evidence of organic nerve disease, nor of disease of any of the organs. Examination of the urine shows no abnormality. No evidence of digestive toxæmia.

The patient was directed to wear constantly the glasses fully correcting her astigmatism and hyperopia; to practice convergence by looking sharply at a pinhead gradually approximated to the eye, and to exercise regularly with a stereoscope (Wells' diagrams).

The case is interesting on several accounts.

1. It is an instance of *unilateral rotary nystagmus.* Unilateral nystagmus itself is rare, only some 50 or 60 cases having been reported. Of these the large majority are vertical. In my summary of 52 cases, published a year ago, I found that 34 were vertical, 11 horizontal, 5 rotary, and 2 mixed. Of the 5 cases of rotary nystagmus noted in this summary, one occurred in my own practice and was described in the article. It seemed there to form one of the initial symptoms of a general paresis.

2. *The symptoms:* These were,

(a) Apparent oscillating movement of objects looked at. This is frequently present in acquired nystagmus and particularly in the unilateral form.

(b) A peculiar oscillating diplopia. This could occur only in a unilateral, or at least an asymmetrical nystagmus.

(c) The fact that the patient herself could see her own eye oscillate when she looked in a glass. This also, as Alfred Graefe points out, can occur only in the unilateral form.

3. *The Causation.* As pointed out in the article referred to, unilateral nystagmus, when developed after the age of infancy, is due to

(a) Unilateral amblyopia or squint,

(b) Unilateral opacity of the media,

(c) Unilateral astigmatism,

(d) Nervous disease, especially multiple sclerosis.

In the large majority of cases squint, or some other one-sided muscular anomaly is present.

In this case no one of these features was found. There was no anisometropia, no ametropia of any amount, no unilateral amblyopia except such as was due to the nystagmus itself, no squint or other muscular deviation except a slight convergence insufficiency, and no evidence of nerve or ear disease.

4. *Treatment:* Treatment has helped in a few cases of nystagmus. Such treatment has consisted in correction of the astigmatism or other refractive errors, relief of the muscular abnormality by tenotomy or advancement, removal of cataract or other opacity causing amblyopia, exercises with the stereoscope, practice in reading with a perforated diaphragm, and exercises in maintaining fixation in different positions of the gaze.

In the present case the refraction was fully corrected. Convergence exercises seemed indicated on account of the convergence insufficiency and it was thought that systematic practice with the stereoscope would, especially in a case of unilateral nystagmus, facilitate the restitution of a perfectly co-ordinated movement.

REMARKS AS TO THE NOMENCLATURE OF NYSTAGMUS.

Distinction between Nystagmus and Pseudo-nystagmus: In closing, I would like to emphasize a point that seems to me of distinct practical importance. Many, especially among the neurologists, group under the head of nystagmus, two sorts of tremor, viz:

(a) The short, usually rapid, rhythmical and effortless, to-and-fro oscillations which in many cases occur when the eyes are in the primary position, and which, even when they occur in secondary positions of the gaze, never have a jerking character.

This is true nystagmus. It is not necessarily or indeed usually associated with defects of the eye muscles per se.

(b) Jerking, rather extensive oscillations, expressive of effort and not always rhythmical, which occur only when the eyes are carried toward the end of their excursion in some special direction. In my belief such oscillations always indicate deficient power or at least exhaustion or irregular action of the muscles themselves. It is properly denoted nystagmic twitching or pseudo-nystagmus.

Now, as Uhthoff, who has insisted upon this distinction, shows, pseudo-nystagmus occurs in a great variety of nervous diseases, and indeed, often occurs in persons who are quite healthy. It has, therefore, very little diagnostic significance. On the other hand, true nystagmus, not due to optical defect nor dating from childhood, and not traceable to occupation, as in miners' nystagmus, nor to ear disease, is a characteristic sign of multiple sclerosis and cellular disease, and also occurs in syringomyelia, but in other nerve diseases is rare. Hence, as a sign of nerve disease, it is of considerable diagnostic significance. It seems, therefore, important that the distinction between these two forms of tremor should be carefully observed.

A TANGENT-PLANE FOR ACCURATELY MAPPING SCOTOMATA AND THE FIELDS OF FIXATION AND SINGLE VISION, AND FOR INDICATING THE PRECISE POSITION OF DOUBLE IMAGES IN PARALYSIS.

BY ALEXANDER DUANE, M.D.,
NEW YORK CITY, N. Y.

The apparatus which I exhibit here was first shown before the New York Academy of Medicine in January, 1906. It was therefore projected and in use before I had the opportunity of

learning of a very similar device which Syms and Sinclair have employed and which they described in the *Ophthalmic Review* of the following May. There is, in fact, nothing specially original in the idea underlying the apparatus, but the application of the idea in its present form offers certain features which experience has shown to be of considerable practical utility.

The apparatus consists of a curtain, black on one side and white on the other. On the white side is drawn a perimetric chart consisting of a series of concentric circles and radiating lines. The concentric circles represent arcs of 5°, 10°, 15°, etc., calculated for a radius of 30 inches, and projected on the tangent plane. By a simple device the curtain can be raised or lowered so that the common center of the system of circles can be placed directly opposite the patient's eye. The radiating lines represent the projections of the meridians (horizontal, oblique, and vertical) taken for each 15°. The white surface is also covered with a checker-board of a foot and two inch squares.

The black surface is marked only by a white pin in the middle, indicating the center of the perimeter chart, and by white pins around the edge, indicating the termini of the different meridians. This last feature I have borrowed from Syms and Sinclair.

The frame is strong, light and portable, so as to be readily shifted from one part of the room to the other. It can also be taken apart for transportation.

The curtain is 5 feet high and 4 feet 5 inches wide, giving a lateral range of 40°, an upward range of 35°, and a downward range of 52°. The lateral range can be extended to 55° or 60° by a tape attached to either vertical arm of the frame and marked with a tangent scale of degrees.

USES OF THE APPARATUS.

A. *To Plot Central and Paracentral Scotomata:* The patient is seated facing the black side of the curtain and exactly 30 inches from it, and the curtain is raised until the white pin is just op-

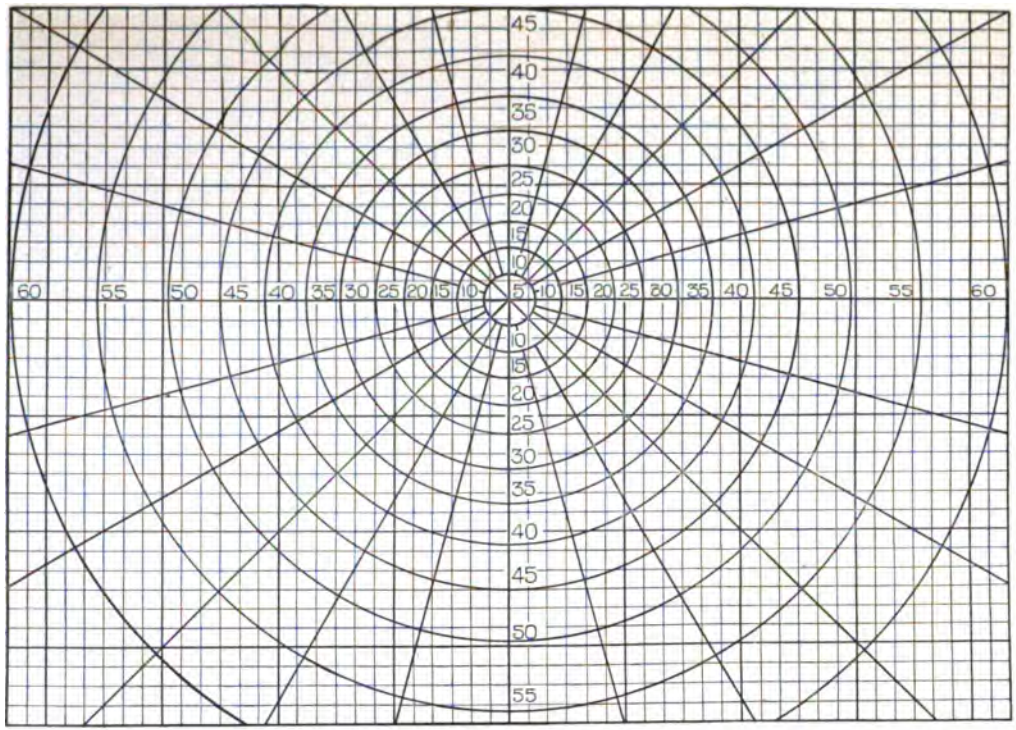

FIG. I.

Chart used in plotting the field of double vision and the position of double images. It is a precise reproduction of the diagram on the white surface (back) of the tangent plane, reduced one-twentieth. The small squares denote intervals of two inches, the larger squares intervals of one foot.

posite the eye to be tested. Directing him to fix the pinhead steadily, we carry the test-object (white pin, square of white paper, electric light, etc.) in from periphery to center, along each of the meridians in succession, i. e., we carry it from each marginal white pin in turn toward the white pin in the middle. The points where the test-object enters the scotoma and where it emerges from it in each meridian, are marked by thrusting black pins through the curtain. The plot of the scotoma thus outlined can then be taken off from the reverse side of the curtain, where the pins stick thro· gh, and can be transferred to a perimeter chart.

In some cases it will be advisable to plot scotomata on a larger scale than that here indicated, i. e., using a radius of one or even two meters instead of 30 inches. In such cases, of course, the perimeter chart on the reverse side is no longer applicable. We then must use the plan suggested by Syms and Sinclair, of measuring off the distance between each inserted black pin and the central white pin, using for this purpose a yardstick or tape marked with a tangent-scale calculated for the given radius. Such a tape I show here, marked on one side for a radius of 30 inches, on the other for a radius of 2 meters.

Not only scotomata, but also the limits of the field, when moderately contracted, and in any case, the limits of the color field, can be plotted with this apparatus, and that too very quickly.

B. *To Plot the Field of Fixation:* The field of fixation is plotted in a very similar way. For this purpose the patient's head is fixed and in such a way that the eye in the primary position is directed precisely at the central white pin. The eye is then made to follow the test-object as far as it can along each meridian, the limit of its excursion in each case being marked by a pin thrust through the curtain. The test-object in this case consists preferably of a pair of fine parallel lines on a small white card.

C. *To Mark Out the Field of Diplopia:* The line separating the fields of single and double vision is similarly plotted. The test-object in this case is a small electric light. The patient faces the screen as before, but with both eyes open and with a red glass before one eye. With his head fixed he follows the light until it

appears double. The point where this occurs on each meridian in succession is indicated by a pin inserted into the curtain.

By carrying the light on into the field of double vision the kind and amount of diplopia can be graphically shown. This is done by marking the situation of the light itself with a black pin and the situation of the double image (in this case the false image) with a white one. In this way we not only record the exact distance and relative disposition of the double images, but also show which is the fixing eye. For if with the red glass before the right eye, the patient sees that the point where we have actually placed the electric light looks red, it is evident that the right eye is fixing, while if it looks white the left eye is fixing.

For certain purposes, particularly for making out slight abducens paralysis and for differentiating this from a paralysis of divergence, the tangent plane is better used in another way, i. e., by placing the light on the center pin of the curtain and making the patient rotate his head to the right and left, keeping his eyes all the time fixed on the light. Double images thus evoked may still be plotted on the diagram. If, for example, the patient turns his head so as to face the right edge of the curtain, we know that the eye which fixes the light on the center pin is rotated 42° to the left. If then the false image is 10° to the left of the center pin, we should plot the diplopia by placing one mark representing the true image at 42° to the left and a mark representing the false image at 52° to the left.

In plotting the position of the double images, the checkerboard of two inch squares on the back of the curtain is a considerable help, especially if, as in the specimen here shown, a chart is used that is similarly checkered. (See Figure 1.)

In general I use this kind of chart for plotting double images and a chart drawn on double the scale for plotting scotomata. A specimen of the latter also is here exhibited. (See Figure 2.)

If the plot is made from the outline made by the pins on the reverse side of the curtain, we must remember to reverse it in the diagram, putting right for left and vice versa. After a little practice this is easy.

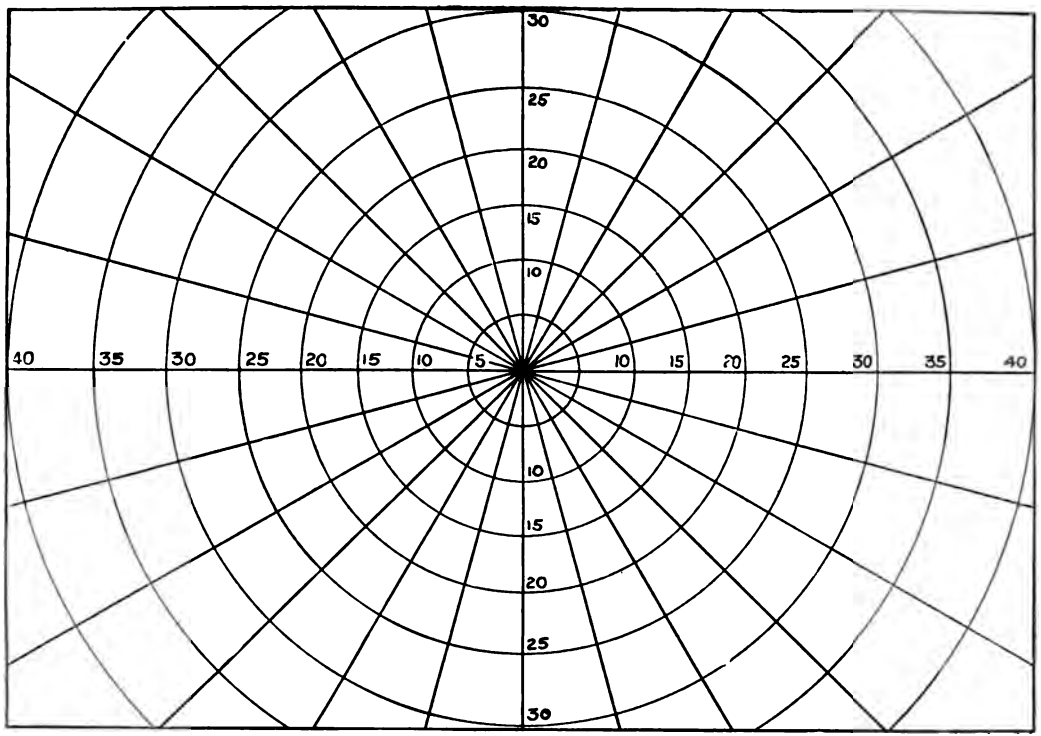

FIG. II.

Chart used in plotting central and paracentral scotomata. It is on double the scale of the chart shown in Fig. 1, i. e., represents the diagram on the back of the tangent plane, reduced one-tenth.

ADVANTAGES OF THE METHOD.

The advantages of the method are:

1. *Accuracy:* In this regard it is vastly superior to the ordinary perimeter for plotting scotomata; and for indicating the double images in paralysis it excels any other plan that I know of.
2. Simplicity.
3. Thoroughness.
4. Rapidity.

THE OCULAR SYMPTOMS IN A CASE OF TUMOR OF THE PITUITARY BODY.

BY HOWARD F. HANSELL, M.D.,
PHILADELPHIA, PA.

The following brief description of the anatomy of the pituitary body is taken from the second edition of Holden's Anatomy, edited by Hewson:—" The pituitary body or hypophisis occupies the sella Turcica and is of a reddish-brown color and consists of two lobes. Of its two lobes the anterior and larger is concave posteriorly to receive the posterior lobe and weighs from five to ten grains. The two lobes consist of different structure and differ in their development. The posterior is developed downwards from the third ventricle and is hollow; subsequently there is a large increase of connective-tissue structure and blood vessels in it, so that the cavity is usually obliterated. The anterior is darker and is surrounded by a connective-tissue capsule; on section it resembles in structure the thyroid gland, being composed of reticular tissue, with numerous cavities filled with nuclear cells and granular matter; it is originally developed as a prolongation from the ectoderm of the buccal cavity, from which it soon becomes isolated."

The optic tracts, originating posteriorly in the corpora quadragemina, corpora geniculata and the optic thalamus, wind around

the crura and meet anteriorly in the middle line to form the commissure which rests upon the sphenoid bone in front of the sella Turcica. Therefore it will be seen that enlargements of the pituitary body or growths springing from it and encroaching upon adjoining tissues should involve first of all the anterior termination of the tracts just as they are about to form the commissure, one or both, according to size and direction of growth. The third, fourth, the ophthalmic division of the fifth, and the sixth, nerves pass into the orbit through the sphenoidal fissure, and by reason of their course at the base of the brain are not compressed or directly implicated. The function of the pituitary body is unknown. That it is in some way connected with the function of the glands of the body, particularly the thyroid, is the common belief, because in abnormal states of the pituitary body, other than tumors, the symptoms point less to central lesions than to those of general nutrition or to disease of the general nervous system.

The ocular symptoms are probably not due to extension of the disease of the pituitary body to the eye structures themselves, but the latter are involved because of the anatomical relation of the body to the chiasm, and this is true whether the enlargement of the pituitary body be due to disease of its own tissues primarily, or the seat of a new growth by which the anatomical features of the body are deranged or destroyed. Hypertrophy or tumor, too limited in its lateral extensions to compress the tracts, would probably give rise to no ocular symptoms whatever unless the vertical growth should be exceptionally great and displace the structures comprising the floor of the third ventricle. A growth of this size and form originating in the pituitary body is rare.

The ophthalmoscopic findings relate exclusively to the condition of the optic-nerve head and the retina immediately adjacent to it. The remainder of the retina and the entire uveal tract seem to be free from involvement. The most common finding is optic nerve atrophy. Early in the course of the disease the nerve head may in no wise differ from the normal or there may be papillitis

to the degree of choking of the disk. This great variation may be attributed, to the time when the patient first comes under observation, to the size attained by the tumor and the amount of pressure exerted upon the optic tracts, and to the degree of interference with the circulation in the optic chiasm and nerves. Choking of the disk is not common. In 38 cases collected from the literature by Rath (Archiv. für. Ophth., Bd. 34, 1888) five only are reported to have had choking of the disk. Heusser (Path. Inst. zu Heidelberg), who studied twenty cases, noticed the same comparative infrequency and ascribed the rareness of choked disk to two causes; first, while the tumor is moderate in size it is positively separated from the rest of the brain by reason of the strongly-stretched dura and it is not able to raise the intra-cranial pressure to the desired degree; second, by its position it may so compress the optic nerve sheathes that the cerebrospinal fluids may not enter. That optic nerve atrophy is common is shown by its presence in most of the published cases. In Rath's 38 cases, five had no symptoms and the tumor was found accidentally at the post-mortem examination. Thirty were studied ophthalmoscopically. Of these, five had choked disks (which, no doubt, would have been atrophied nerves had the patients survived) and 25 had atrophy, either partial or complete. It is not improbable that some of the cases of so-called idiopathic atrophy so often unexplainable are cases of tumors of the pituitary body, for such tumors may exist for a long time without other symptoms than deterioration of vision through optic nerve atrophy. They may have spinal diseases, particularly post sclerosis, as a cause, for it is well known that degeneration of the optic nerves may precede for years the appearance of the characteristic symptoms of tabes, but it is well to remember in guessing at the causative lesion to consider the possibility of tumor of the pituitary body. The latter diagnosis would be naturally strengthened by signs of acromegaly or evidence of disease of the thyroid or other ductless glands.

The symptoms are modified according to the size attained by the tumor, according to the rapidity of its growth, and possibly

according to its nature. The most important symptom and the one to which attention is usually drawn first is the reduction of vision. This is of various kinds and includes the loss of central acuity or alteration in the size and form of the field. Bitemporal hemianopsia is common at some stage of the disease, although this defect is not always well-marked nor permanent. Disproportionate lateral growth of the tumor might lead to complete blindness in one eye and hemianopsic field in the other. Eventually the hemianopsic character of the field is lost by the advance of the optic nerve atrophy and gradual encroachment of the blind field upon the seeing field. During this process scotomas of irregular form and shape and subject to change may be found by careful perimetric measurements. The central fixation point is often excepted for a long time from the hemianopsia or other forms of loss of field. This "overshot field of vision," as it has been called (to quote from de Schweinitz and Carpenter, J. A. M. A., Jan. 14, '05), suggests the supply of the macula with a double set of nerves, one from each hemisphere, and has been explained by Schmidt-Rimpler by assuming anastomoses of the fibres in the optic nerves and chiasm. The field defects in chiasm lesions are explained by Wilbrand and Saenger, Bd. III, Abth. I, to which classical work the reader is referred for an exhaustive study of the subject. Rath studied the reports of cases of tumor up to 1888 and gives the symptoms most frequently manifested. Pain in forehead and temple radiating into the orbits, early amblyopia with temporal hemianopsia. In the beginning negative ophthalmoscopic findings, later, simple (not preceded by papillitis) optic nerve atrophy. Sometimes paralytic strabismus, drowsiness, weakness in the legs, a peculiar form of dementia and simultaneous diabetes mellitus or insipidis, vomiting, dizziness, and epileptiform convulsions all noted. Müller (Arch. f. Oph., Bd. 8, 1861) described a case in which the principal symptom was alternating blindness and bitemporal hemianopsia. Takaloff, Virchow's Arch., Bd. 43, 1898, reported a case of gumma,

"large as a walnut and cheesy" in a woman of 44 in which the only cerebral symptom was dilatation of the right pupil.

Case. S. L., male, aged 53, sent to me for examination of his eyes by Dr. J. K. Crawford of Philadelphia, Nov. 11, 1901. The patient complained of a veil over the left eye that had existed for some time, and of the inability to see clearly to read. He had no pain, no photopsia. Pupils equal in size and react. He has been for the past 3 months drowsy and during sleep was given to talking and dreaming. L. lens opaque in cortex, nerve pale, vessels small, no preceding neuritis. White field concentrically and decidedly limited, small negative central scotoma. No color perception. V=20/200. R. nerve pale and field concentrically contracted for white and colors, but both changes less marked than in L. V=20/40 pt. Momentary diplopia in extreme right field probably commencing paralysis of external rectus of R. June 12, '02. Pain in eyeballs. Vision reduced to R. 20/100 L. 10/200, central scotoma in left unchanged. Fields increasingly limited, nerves white, and becoming cupped. 3.2.03 fields are now smaller and are irregularly bitemporally hemianopsic. Dr. Crawford stated that during the early part of his sickness insomnia was the principal symptom. For 22 days he averaged 22 hours sleep each day. In the last 18 months of his life he became totally blind on four distinct occasions lasting in each instance about 6 weeks. From every attack except the last he slowly recovered perception of light. During the past two years he was subject to terrible attacks of temper and became while raging almost cyanotic. He never complained of headache or vomiting. Station good, slight atheroma, no glycosuria at any time. Dr. Crawford believed the bones of the nose and orbit were slightly enlarged. The post-mortem examination was confined to the contents of the cranium. A dark brown tumor was found occupying the site of the pituitary body and measuring 4 cm. horizontally by 1 cm. anteroposteriorly. No sign of inflammation of the adjoining tissues could be found. The optic chiasm and tracts were compressed and atrophic. The nature of the tumor is not definitely known for the report of the micro-

scopic examination has been lost. Adenoma, sarcoma, cysts, carcinoma, tubercle, and gummata have been found post-mortem and their growth is said to be generally toward the orbit rather than toward the brain. The prognosis both for sight and for life is most unfavorable.

DISCUSSION.

DR. J. A. LIPPINCOTT, Pittsburg, Pa.: I have seen but one case of this kind. In this case the temporal field of the right eye was completely abolished. The field for form in the left eye was intact, but there was a large scotoma for blue and also for red on the temporal side of the centre; so that the growth involved all of the crossed fibres of the right side and affected those of the left side only enough to produce the color scotoma. V'n. R.E. 20/CC, corrected 20/C. V'n. L.E. 20/C, corrected 20/xxx.

The face and hands showed the enlargement characteristic of acromegaly. The lower extremities were normal. The ophthalmoscope showed grayish atrophy with lessened calibre of the arteries and dilatation of the veins. I intend to report the case more in detail.

DR. G. E. DE SCHWEINITZ, Philadelphia: One point, I think, should be emphasized, namely, Dr. Hansell's observation that in all probability certain unexplained cases of optic nerve atrophy are attributable to lesions of the pituitary body. Of particular interest is the presence of the scotoma which I understand was demonstrable in one of the visual fields. The importance of these scotomas as a symptom of brain tumor has, as we know, been emphasized by Nettleship, especially in so far as they concern lesions of the optic chiasm and therefore probably of the pituitary body under title of "chiasmal central amblyopia." In the words of this author, the loss of the central field in the earlier stages is more rapidly defined than in tobacco amblyopia and the symmetry less precise, both in time and degree, than in the latter disease. In one such case the chiasm was involved by a cyst. We are accustomed to expect to find bitemporal hemianopsia as a symptom of pituitary body disease and are accustomed to regard this defect of the visual field as pathognomonic of chiasmal lesion, forming, to use the language of Griffith, the localizing form of hemianopsia. But we should remember that even when the chiasm is involved, for example, in pituitary body

disease, we do not necessarily have in the earliest stages a bitemporal hemianopsia. Sometimes there is a period simply of partial contraction of the visual field before the real bitemporal defect develops. Indeed, it may be present at first for colors alone before the loss for white is manifest. Not only that, the process may begin with a paracentral or a bitemporal hemiopic scotoma which gradually broadens into bitemporal hemianopsia. Such cases have been reported by Beer, Foerster, and Vossius. In the last named author's case the condition began with bitemporal contraction of the visual fields and paracentral scotomas, and was followed by sharply limited bitemporal hemianopsia. It is also true that the original condition of bitemporal hemianopsia may change and result in symmetrical paracentral hemiopic scotomas, as in Treitel's well-known case. As Dr. Hansell has well pointed out, and as I have already stated in the beginning of this discussion, in cases of otherwise unexplained optic nerve atrophy the presence of tumor or other lesion of the pituitary body should be suspected.

DR. ALLEN GREENWOOD, Boston: I recently saw a case of pharyngeal tumor involving the pituitary body in which the bitemporal hemianopsia was very marked.

DR. WARD HOLDEN, New York: In regard to the early eye symptoms of acromegaly I should like to say that several years ago I saw in the Montefiore home two or three patients who complained of visual disturbance, in whom I found optic nerve affections and contraction of the fields and where the only other evidence of the disease was a broadening of the bony portion of the nose. They were followed up and each developed other characteristic symptoms of acromegaly.

DR. H. F. HANSEL, Philadelphia: The principal mental symptom of this patient was drowsiness. For 22 days he slept 22 hours each day. This symptom has been noted by other observers and seems to have some diagnostic value.

KERATITIS TUBERCULOSA, RELIEVED BY TUBERCULIN INJECTIONS.

REPORT OF A CASE

BY DR. S. LEWIS ZIEGLER,
PHILADELPHIA, PA.

While tuberculous lesions of the various ocular structures have been recorded in considerable numbers covering a long period of years, disturbances of the cornea have been infrequently reported. These cases are either unusually rare, or owing to their great resemblance to interstitial keratitis are confounded with that disease. We have all seen atypical examples of corneal disease, which were recorded as parenchymatous in character, when further study might have demonstrated their tuberculous nature. The nebulous haze of the cornea, the rapid vascularization of the area of deposit, and the intense pericorneal injection, with photophobia and lacrymation, present a clinical picture which may easily be mistaken for interstitial keratitis. The differential diagnosis must therefore be made on other evidence than that furnished by the macroscopic appearance of the eye.

Prior to 1890 two methods only were open to us for confirmatory evidence of a correct diagnosis, as was carefully shown in Dr. Posey's paper on Intraocular Tuberculosis[1] presented before this society two years ago, (1) by bacteriological examination, and (2) by inoculation tests on rabbits. To this should, of course, be added (3) confirmatory signs of systemic involvement, if any such are present. In the majority of these cases, however, no such signs are present, the infected foci being wholly local in character. We cannot, however, always have the privilege of confirming our diagnosis by an ocular post-mortem, following enucleation of the eyeball; and as Dr. Hansell[2] pointed out in

[1] Trans. Amn. Oph. Soc., 1904, p. 244.
[2] Trans. Amn. Oph. Soc., 1904, p. 263.

discussing the papers presented in 1904, his case showed macroscopic signs of ocular tubercle, but gave no evidence by the microscope or inoculation tests of its tuberculous character, although the diagnosis of tuberculosis was confirmed by the general physical condition.

As a natural sequence of the announcement of Koch's method, in 1890, the use of tuberculin as a diagnostic agent has become wellnigh universal, and to this we must look for our simplest and surest diagnostic test. The reaction following its application gives us not only a reliable systemic sign in the general febrile disturbance, but points unerringly to the infected foci by the evidence of local pain and congestion. While the local disturbance resembles an aggravation of the disease, as viewed by the patient, the prompt and decided improvement which follows its use gives ample evidence of the benign and healing action of the injected lymph.

The claims of tuberculin as a distinctive therapeutic agent were tentatively put forth by a number of early observers but failed to secure general recognition by the internists, many of whom are still skeptical as to the possible benefits to be obtained from its use. The especial advantages of studying the effects of tuberculin on ocular lesions occurred to Albrand[3] in 1891, in a case of conjunctival nodes previously confirmed by inoculation and microscopical study, and to Von Hipple[4], who reported two cases of intractable corneal disease, which showed systemic reaction to the lymph, and in which rapid convalescence followed its use. Since then many cases of ocular tuberculosis have been placed on record in which Koch's tuberculin has been administered both as a diagnostic and a therapeutic agent. The literature of the subject has been carefully collated by Gamble and Brown[5] in a monograph presented to the Ophthalmic Section of the American Medical Association last year.

The history of the writer's case is briefly as follows: Miss A., white, aged 24, seamstress, was referred to me October 7,

[3] Klin. Monat. f. Augen, I, p. 160.
[4] Klin. Jahr. (erganzungband), p. 682.
[5] Jour. A. M. A., Oct. 14, 1905.

1905, suffering from what appeared to be phlyctenular keratitis and conjunctivitis, which had persisted for two months. O. D. vision reduced to 20/200. There was considerable epiphora, eczema of the nostril and acne of the lips. There was some lacrymal obstruction for which rapid dilatation was performed. All of the superficial lesions cleared up rapidly under the usual treatment, leaving only a slight nebulous haze of the cornea.

In a few weeks, however, these nebulae began to vascularize and increase in area until the vision was again markedly obscured, being reduced to 2/200. The appearance at this time very much resembled interstitial keratitis. There was marked blepharospasm, photophobia, and lacrymation. A course of mild chloride of mercury was given, and later of bichloride. Positive galvanism was instituted, and applied religiously, but with slight improvement. The pericorneal injection persisting, leeching was resorted to. The symptoms became very much worse for several days after this, and then subsided somewhat. A week later the leeching was repeated, when the eye again flared up. The effect was so unusual, and the ocular inflammation was so sluggish that I began to suspect that we had a tubercular lesion to deal with. Repeated careful examinations with oblique illumination from the head mirror finally revealed considerable depth to the corneal opacities, which later developed into yellowish-white nodular deposits on Descemet's membrane, and gradually separated into three distinct island-like masses. A minute nodule also appeared on the iris, at the angle, on the nasal side. The eye now presented the typical picture (Fig. 1) so admirably depicted by the artist, Louis Schmidt.

Close questioning elicited a previous history of ulcerative keratitis three years before, accompanied by enlarged cervical glands on the left side, and that the right cervical glands had been enlarged eight years previously, without any ocular or other noticeable symptoms. Although there was now no apparent enlargement of the cervical lymphatics, her previous attacks and her present condition created a suspicion of recurrent tubercular infection, and I decided to try Koch's tuberculin, as prepared by

Fig 1.

Keratitis Tuberculosa.

Miss A., Nov. 26, 1905.

Fig. 2.

Nebulous corneal haze.

Sequela of tubercular deposits on Descemet's membrane.

Mulford & Co. Examination of the sputum and urine for tubercle bacilli gave negative results. The pulmonary signs were normal, and there were no enlarged glands.

For three days a record of the pulse and temperature was carefully made.

Nov. 24, 1905. The thermometer revealed a temperature of 100°. Pulse 90.

Nov. 25. Temperature 99.5°. Pulse 80.

Nov. 26. Temperature 100.2°. Pulse 90. An injection of two minims of tuberculin, well diluted with water, was made into the right forearm. Eight hours later there was a pronounced systemic reaction, with a temperature of 103°, headache, malaise, marked aching between the shoulders and in the limbs. The head and skin felt hot, the hands and feet cold. The cervical glands on both sides became greatly swollen and did not subside to normal for several days. The local symptoms were all exaggerated; the eye became sore and painful, lacrymation was more pronounced, and pericorneal injection was greatly increased.

On Nov. 28th, the temperature had fallen to 101°, pulse 105.

On Dec. 1st, temperature was down to 99°, pulse 80, and the eye showed the first signs of genuine improvement.

On Dec. 11th, the temperature was 99.5°, pulse 76. A second injection of 3 minims of tuberculin was made. Five hours later she had a pronounced chill lasting for one hour, temperature rose to 104°, subsiding the next day to 101°. The eye again became painful, with marked injection and lacrymation. The limbs ached and the joints became sore. The cervical glands gave no further signs of reaction.

On Dec. 13th, or two days later, the eye was much improved, pain, redness and lacrymation being greatly diminished. Temperature 101°. Pulse 114.

The patient at this point became greatly discouraged by the apparent severity of the treatment, as manifested by the marked systemic reaction, and did not report again until Dec. 26th, when she was much improved as to condition of the eye and general

health. Temperature 99°. Pulse 65. A third injection of 2 minims of T. was made. No chill and no aching of joints followed. The temperature rose to 102°. Some headache; fever broke suddenly, followed by profuse perspiration. Cervical glands did not swell. The eye was again painful, red and watery.

Dec. 29, 1905. Temperature 99.5°. Pulse 100. Eye is better.

Jan. 2, 1906. Eye looks greatly improved. Very little pericorneal injection, no pain or lacrymation. Temperature 99°. Pulse 80. Fourth injection, 3 minims of T. Temperature did not go beyond 102°. Some headache, stiffness of joints, and nausea.

Jan. 3d. Temperature 100°. Pulse 80.

Jan. 5th. Temperature 99°. Pulse 76.

Jan. 9th. Temperature 99°. Pulse 76. Fifth injection, 3 minims of T. Temperature rose to 101°, slight headache, eye slightly reddened. Limbs ached, slight nausea and anorexia.

Jan. 13th. Temperature normal. Pulse 80. Eye shows but little redness. The areas of interstitial haze are growing less, iris free, vision about the same.

Jan. 23d. Temperature 100°. Pulse 86. Sixth injection, 4 minims of T. Temperature rose to 103°. No pain or redness in the eye, cervical glands quiet, no headache or nausea. Had sharp pain in left side, left ankle swollen and painful.

Jan. 30th. Temperature normal. Eye looks fine. Seventh injection, 5 minims of T. Temperature rose to 101°. No systemic disturbance, but left ankle and knee were swollen and painful.

Feb. 6th. Temperature normal. Eighth injection, 5 minims of T. Temperature rose to 102° but dropped next day to 101°. Slight redness of the eye, and a little pain in left knee and ankle.

Feb. 13th. Temperature normal. Eye quiet and clearing. The ninth injection of 5 minims of T. was made. Very little systemic reaction. No pain and no rise of temperature. This was the last injection administered.

Mar. 24th. Eye has been quiet and clearing for the past five weeks. Two days ago a small phlyctenular ulcer developed at

the sclero-corneal junction. This yielded promptly to mild local treatment.

June 17, 1906. Patient has not been seen for past three months. Returns now at my request to have the artist depict the present condition of the eye. (Fig. 2.) The corneal haze has lessened in density, but still shows marked interference with the transparency of Descemet's membrane. Central vision is still reduced to O. D. 8/200, but there is considerable clear cornea in the periphery. Eye is perfectly quiet, but flushes slightly on handling. Patient has lost flesh, but thinks this is caused by her work, as she feels perfectly well.

Here then we have a well marked case of parenchymatous keratitis from tubercular deposit on Descemet's membrane, in which a series of tuberculin injections (9 in number) administered at intervals of from seven to ten days, gave pronounced local and systemic reaction, with thermic rise and swelling of the cervical glands. This was followed by decided local improvement, which was steadily progressive up to complete convalescence. The non-yielding to a varied therapy covering a long period, and the prompt and progressive recovery under these injections gives us a clinical demonstration of the fact that tuberculin has a distinct curative value.

To show the decided action of tuberculin in these cases of non-ulcerative corneal tuberculosis a brief résumé of such cases reported is herewith appended. Examples of the ulcerative variety have been purposely omitted owing to the possible presence of a mixed infection.

Von Hipple[4] reports two cases (already referred to), one of chronic inflammation of the cornea and lids, and another of eczematous disease of the cornea, each relieved by a few injections. In 1904 he reported[6] two other cases of corneal nodes cured by T. injections.

Cohn[7] used three injections in two cases of interstitial keratitis associated with phlyctenular lesions.

[6] Arch. f. Ophth., lix, I, pp. 1-30.
[7] Berlin Klin. Woch., 1891, No. 7, p. 175.

Koenigshoefer and Maschke[8] report a case of interstitial keratitis cleared up in six days by two injections of ½ mg.

Uhthoff[9] reports a case of vascular keratitis, resembling interstitial, which responded to 1/1000 mg. injections of T.

Gradle[10] refers to four cases of atypical scrofulous keratitis which responded to tuberculin injections.

Schieck[11] reports a mixed case of iris and corneal nodes which yielded to 24 injections of T., but strangely without reaction.

Morax and Chaillous[12] report two cases of corneal nodes absorbed after one injection of T. which gave both local and general reaction.

Enslin[13] records eight cases of supposed interstitial keratitis with typical reaction after injection of 1/10 to 3 mg. of T. He differentiates in this way between syphilis and tubercle.[14] Out of 24 cases tested 5 gave the typical reaction.

Darier[15] has used T. in a case of supposed interstitial keratitis with marked reaction and curative results.

Stanculeano[16] reports five cases of typical reaction in corneal infiltration, with and without iritic lesions.

Gamble's[17] case was one of iritic nodes, but with pin head sized thin yellowish-white masses deposited on Descemet's membrane, which makes this a mixed corneal case. The lesion was relieved by repeated T. injections.

In conclusion I desire to emphasize a few salient points:

1. Keratitis tuberculosa closely resembles interstitial keratitis in its clinical manifestations.

2. The use of tuberculin injections is our most efficient method of making a differential diagnosis.

---

[8] Deutsch. Med. Woch., 1891, No. 2, p. 72.
[9] Berlin Klin. Woch., 1891, No. 7, p. 1722.
[10] Trans. Oph. Sect. A. M. A., 1900, p. 44.
[11] Arch. f. Oph., 1900, 1 & 2, pp. 247-359.
[12] Annal. d'Ocul., 1901, cxxvi, pp. 119-132.
[13] Allgem. Med. Cent. Zeit., 1902, No. 94, p. 1115.
[14] Deutsch. Med. Woch., 1903, Nos. 8 & 9.
[15] Brit. Med. Jour., Sept. 26, 1903, p. 721.
[16] Annal. d'Ocul., cxxxii, 1904, p. 340.
[17] Jour. A. M. A., Oct. 14, 1905.

3. Confirmatory evidence should be gathered from bacteriological examinations, inoculation tests, and the study of systemic signs.

4. Tuberculin injections have an undoubted therapeutic value in tuberculous lesions of the eye.

5. Two minims of Koch's tuberculin (Mulford) is sufficient for a diagnostic test, while from two to five minims may be injected for therapeutic effects.

DISCUSSION.

DR. P. A. CALLAN, New York: About three years ago I systematically during the winter used Koch's tuberculin as a diagnostic test. As regards the therapeutic value I can not speak. In all I have had 40 cases. I first commenced on interstitial keratitis, cases due to inherited syphilis. In all those cases, without exception, I got a reaction, which would vary from 1 degree to 3 or 4 degrees. We commenced with 1 mg. of tuberculin. I looked the matter up and found that my experience was not unique in this matter by any means. Therefore I have concluded that as a diagnostic sign it is uncertain. Sometimes I would wait a few days and give from 3 to 5 mg., and would always get a reaction. In looking up the subject I found that the Surgeon-General of the Austrian (Bosnian) Army used tuberculin in the cases of all recruits and had a reaction in 60%.

As to its therapeutic value I had a similar case to that of the doctor's, which improved while she stayed in the hospital, but in the course of six months she came back quite bad. I think there must be a mistake somewhere about tuberculin for you can get a reaction in almost every case if you persist. I have gotten it even in cases of phlyctenular keratitis. The reaction in the eye was very often quite marked.

In a few cases there was a subnormal temperature after the injection which in due course of time was followed by the usual increase of temperature.

DR. WM. H. WILDER, Chicago: I am inclined to agree with the last speaker as to the unreliability of tuberculin as a diagnostic measure and yet the evidence seems to be growing, evidence of a very positive kind, that we have in this agent a means of combatting some of the peculiar interstitial keratitis cases which

we can not classify. I had the fortune of seeing the case to which Dr. Ziegler alluded, that of Gamble and Brown. It seemed to present all the clinical features of tuberculosis of the iris and certainly responded to this test and the cure seemed to be complete under the administration of tuberculin. The interesting reports of Hipple and others who have been using this remedy more generally than it has been used in this country would seem to encourage us in the idea that we should use it more frequently as a means of diagnosis than we commonly do.

I have recently had two interesting cases that did not seem to get well—ordinary cases of interstitial keratitis—one of which I would relate briefly. A young woman, twenty years of age, in excellent health and we had no idea she was tuberculous; no history of inherited syphilis. She suddenly developed interstitial keratitis that looked like that of inherited syphilis and I used the ordinary remedies and got no response. After seeing this interesting case of Gamble and Brown's I decided to make the test with tuberculin. I got a well marked general reaction and in a second test some time later was also fortunate enough to get a local reaction. Then I began treatment with tuberculin and had as favorable a case as Dr. Ziegler has just reported, the case clearing up completely. The infiltration in the cornea was so dense that vision was reduced to fingers at 2 or 3 feet. The result was most satisfactory and she has now vision of 20/20 and that was accomplished with doses of tuberculin. I did not rely on my own experience but had her under the charge of Dr. Evans, whose experience along this line is of considerable value.

The other case was somewhat similar, but I was not so fortunate in getting such clearing up of the cornea, though there was a well marked response to the tuberculin. In this individual there were tubercle bacilli in the sputum.

It must be borne in mind that unquestionably a great many more individuals have latent tuberculosis than has been commonly supposed. Eighty per cent. of autopsies show lesions of tuberculosis and it may be that an injection at any time would cause a general reaction. I am inclined to believe that we can not place very much reliance in it as a diagnostic measure for this reason.

Dr. S. L. Ziegler, Philadelphia: Dr. Wilder has called attention to the very things I was about to say in answer to Dr.

Callan. Perhaps the larger percentage of those being drafted as soldiers in the Austrian army have some form of latent tuberculosis in the system; hence the reaction to tuberculin. Anyone who has visited the clinics in Vienna must have been impressed with the great number of localized and isolated tuberculous lesions seen there. It is a well-known fact that a very large number of post-mortem examinations reveal localized tuberculosis that has been unsuspected during life. However, there is no question that in these particular cases tuberculin has a real diagnostic value, and is a most efficient therapeutic agent.

CONCERNING THE SIGNS IN THE RETINA OF PERSISTENT HIGH ARTERIAL TENSION AND THEIR DIAGNOSTIC AND PROGNOSTIC IMPORT.

By G. E. de SCHWEINITZ, M.D.,

Philadelphia, Pa.

The eyeground lesions of persistent high arterial tension, when this is a symptom of arterio-sclerosis, may conveniently be divided into those which are *suggestive* and those which are *pathognomonic.*

The suggestive signs include uneven caliber and undue tortuosity of the retinal arteries, increased distinctness of the central light streak, an unusually light color of the breadth of the artery, and alterations in the course and caliber of the veins.

The pathognomonic signs include changes in the size and breadth of the retinal arteries, of such character that a beaded appearance is produced, distinct loss of translucency; decided lesions in the arterial walls, consisting of white stripes in the form of perivasculitis; alternate contractions and dilatations of the veins, and particularly, and this is the most important of the signs, indentation of the veins by the stiffened arteries in the same manner as a solid rod would indent a rubber tube when lying across it. Sometimes the vein is simply flattened slightly at the point of crossing, or merely pushed aside, or its caliber is

contracted, so that beyond the point of crossing there is an ampulliform dilatation. In addition to these well-known signs, there may be changes in the venous walls, so that they are bordered with white stripes, and the veins may be exceedingly tortuous and contain varicosities. Finally, there are œdema of the retina in the form of gray opacity around the disc or following the course of the vessels, hemorrhages manifesting themselves as linear extravasations, or roundish infiltrations, or sometimes assuming a drop-like form.

1. *The Age at Which These Signs may Occur.* As Mr. Marcus Gunn[1] has well said, and we are much indebted to him for the best study of this subject, old age alone does not produce these changes. All can substantiate his statement that perfectly healthy retinal vessels are often seen in persons who have reached old age, even seventy or eighty years of life. Doubtless the visible changes, again to quote Mr. Gunn, usually begin between forty and fifty. I have seen them, however, at an earlier age, one of the most pronounced examples being a man aged 37. In other words, if the cause of persistent high arterial tension is sufficiently prolonged, these alterations will occur at any age at which the pathological condition to excite them arises.

2. *The Earliest Indications.* As has been stated in the beginning of this communication, certain of these signs are only suggestive, and they have already been enumerated and must not be disregarded if they are associated with other symptoms of the disease. According to my experience, three signs may be seen very early, as follows:

(a) A markedly corkscrew appearance of certain arterial twigs, either of those which skirt the macula, or, more significantly, of one or more small branches which arise from the larger vessels of the main distribution, which themselves are apparently normal. In other words, and this has been noted many times before and is also referred to by Mr. Gunn, the whole artery is not affected. This is a particularly striking feature if, as is frequently the case, a single twig descends ver-

[1] Trans. Ophth. Soc. U. K., xviii, 1898.

tically from a transverse branch and assumes this corkscrew condition.

(b) A flattening of a vein where it is in contact with an artery, and at this spot it has somewhat the appearance that a strap would have if laid across a solid tube, provided the vein passes over the artery. If the artery passes over the vein, the appearance is analogous to that which would be produced if the strap were placed across the lower surface of the tube. The vein is only slightly compressed at this stage, but is not yet indented sufficiently to produce an ampulliform dilatation of the vein beyond the point of crossing. It has seemed to me that this appearance is a little more frequent in the inferior temporal retinal vessel distribution than elsewhere, or perhaps, to speak more accurately, appears there first.

(c) The nerve-head has an appearance often loosely described as "congested." But this appearance differs from that presented by the so-called streaked hyperopic disc; it is unlike the flannel-red surface of the papilla which merges into an equally flannel-red eyeground, so commonly the result of prolonged eye-strain, exposure to bright light and intense heat, or seen in certain constitutional conditions; and, finally, may be distinguished from the early stage of neuritis, with the somewhat juicy red aspect of the disc. It is a dull red appearance which is presented and differs somewhat from the franker congestions, as the unhealthy flush of a cheek differs from the brighter color of a normal blush. Subsequently the later signs develop: marked indentation of veins, with ampulliform dilatation beyond the point of pressure; varicosities, "silver-wire" arteries and perivasculitis, hemorrhages, etc.

3. *Significance of the Signs.* The facts just detailed and the appearances described are well known, and hence we may consider them immediately from the *diagnostic standpoint.* It is undoubted that these retinal vessel changes have not merely a local significance; but are one of the important indications of that condition to which the term arterio-sclerosis is usually given.

As Alfred Stengel[1] has well said, "Arterio-sclerosis in its fully developed stage can be recognized with no great difficulty in most instances, but a positive determination of the existence of the earlier stages is extremely difficult, but most essential, if we are to accomplish anything in the way of controlling the progress of the disease." Hence we welcome aid from all sources.

It is not the province of the present paper to discuss the causes which lead to arterio-sclerosis — laborious work, nervous strain, abuse of alcohol, overfeeding, infectious diseases, notably syphilis, certain metallic poisonings, and heredity.

We are concerned here with its early recognition, and particularly with the help which ocular examination can give us in this respect. The general clinician interests himself especially for the purpose of diagnosis, to quote from Stengel's analysis, with a study of the pulse by palpation, with the character of the first heart sound at the apex and the second sound at the aortic area, with the sphygmogram, and with the results obtained by instrumental measurement of arterial tension. Because I shall wish to refer to the last method of diagnostic precision in the subsequent pages, and because it seems to me that we, as oculists, should be familiar with the technique, I have asked Dr. George Norris, one of our most accomplished young clinicians, who has much concerned himself with such investigations, to write the following brief account:

"The necessity of accurate instrumental measurement of the arterial tension is no longer questioned. Cases which owing to obesity or vascular rigidity give an entirely erroneous impression even to the *tactus eruditus* can be satisfactorily gauged by means of the sphygmanometer. Not only should we ascertain the systolic pressure, but also the diastolic tension, which is of equal and sometimes of greater importance, to say nothing of the fact that by knowing both of them we are possessed of the mean pressure.

"There are two instruments upon the market with which the systolic and the diastolic pressures may be measured with sufficient accuracy to be clinically reliable, and which are also

[1] American Medicine, January 2, 1904.

compact enough for practical utility, the Stanton and the Janeway sphygmanometers. Of these the former is preferable because it is of more substantial construction, less troublesome to transport, more quickly set up, and because it gives more constant and satisfactory readings of the diastolic pressure.

"The Stanton apparatus is a modification of the Riva-Rocci instrument, and consists of a hollow rubber bag closed at both ends, which is connected at its middle by means of a rubber tube with a mercury manometer, to which is attached a scale graded in millimeters. The rubber bag, which is applied around the patient's arm, is held in place and rendered externally indistensible by an adjustable canvas cuff. To determine the systolic pressure the bag is inflated by means of a syringe bulb, thus expanding the arm-encircling bag, until the pulse disappears at the wrist, or, better, by noting the point on the manometer scale where the pulse reappears after it has been obliterated. The diastolic pressure is obtained by observing the point at which the greatest oscillation of the mercury occurs when the air is being allowed gradually to leak out.

"Blood pressure varies considerably within physiological limits. In healthy young adults the systolic pressure varies between 100 and 140 mm., the diastolic between 80 and 90. In children the figures are somewhat lower, and in advancing years they tend to gradually increase. Practically a systolic pressure above 160 and a diastolic above 130 are the extreme upper limits of what can be considered physiological, even in advanced life. During bodily exertion or mental excitement these figures may be reached or exceeded, but such conditions are merely transient. In women the pressures are generally about 10 mm. lower than in men of a similar age.

"Clinically, hypertension is of greater importance and frequency than hypotension. It not infrequently happens that the former is the first sign of beginning renal or vascular degeneration which is detected. Janeway in a careful study of 130 cases found that in ten per cent. abnormalities of tension would have been entirely overlooked but for the employment of the sphyg-

manometer. In cases with marked hypertension, in which the superficial arteries fail to show any important sclerosis, we may confidently assume that we have to do either with splanchnic sclerosis or with spastic hypertonus of the smaller arteries or arterioles, either with or without renal changes. Such conditions may often be noted during the early and still remediable stages of the morbid process. In such cases the systolic pressure is generally more increased than the diastolic."

To the four diagnostic indices of the persisting high arterial tension[1] as an early condition of arterio-sclerosis, namely, the condition of the pulse, the character of the heart sounds, the tracings on the sphygmogram, and the readings of the sphygmanometer, it would seem, on the authority of the studies made by Preston, Friedenwald, Hirschberg, Gunn, Raehlmann, Bull, Alleman, Woodruff, myself, and others, that the ophthalmoscopic signs already detailed should be added.

That this important aid has not escaped the attention of general clinicians is evident from what follows. Thus Stengel[2] writes: "The ophthalmoscope may reveal the positive evidences of vascular disease before the disease (arterio-sclerosis) has become marked." And again,[3] "Finally, I wish to call attention to the possibility of an early diagnosis by ophthalmoscopic examination."

But the value of the ophthalmoscope does not end here. To elucidate what is meant I quote once more from Stengel: "If the four symptoms I have named (the condition of the pulse, the character of the heart sounds, the increased tidal wave on the sphygmogram, and the elevation of tension recorded by the sphygmanometer) were found in arterio-sclerosis *alone,* the problem of diagnosis would be greatly simplified, but this is not the case. There are numerous and varied conditions of the system, organic and nervous in origin, that elevate pressure

[1] It is possible that in the very early stages of arterio-sclerosis the blood pressure may be lowered instead of raised, but, as Stengel points out, such preliminary lowering of blood pressure is probably quite temporary and rather occasional than constant during the brief period of its existence.

[2] Pennsylvania Medical Journal, August, 1904.

[3] American Medicine, vol. II, No. 1, p. 191, 1904.

nearly constantly, and in which arterio-sclerosis has no part, except, perhaps, as a consequence. Any one of these conditions may occasion the four signs I have discussed."

So far as I am aware, the ophthalmoscopic signs which have been detailed are produced by no other condition except the persisting high arterial tension of arterio-sclerosis, and therefore eyeground examination is of paramount importance in the early recognition of vascular disease, and may render signal aid in the interpretation of symptoms caused by the derangement of the functions of important organs, which in their turn are dependent upon sclerotic changes in their smaller vessels, although there is as yet no decided alteration in the general circulation.

But does the ophthalmoscope at this early stage show the lesions which have been reported? In so far as the early stages of arterio-sclerosis of the so-called cerebral type are concerned I believe it does, and believe, moreover, that it is not alone with these types that the retinal lesions are found. Of course sometimes examination is negative, and it would require a large amount of research and careful ophthalmoscopic examination in connection with clinical investigation, and also, when opportunity afforded, with post-mortem examination, accurately to determine the comparative frequency of retinal changes in the various groups of arterio-sclerosis exclusive of the cerebral types. Evidently, however, the ophthalmoscopic examination should never be omitted as part of the investigation of any suspected case of early arterio-sclerosis, and if indented veins and other ocular signs are present, then its findings are positive and in a certain sense more valuable than the four symptoms now so many times described. Certainly we may say with Marcus Gunn[1] "ophthalmoscopic examination is one of the most ready clinical means for the early detection of important arterial changes," and I think we may go further and say if the findings are positive they are diagnostic.

Reverting next to the question of *prognosis,* this naturally divides itself into that which is related to the eye and its functions

[1] Trans. Ophth. Soc., U. K., xviii, 1898.

and that which concerns the general economy, in other words, the prognosis *quoad visum* and *quoad vitam.*

1. *The Hemorrhages and Their Results.* These naturally depend upon the size and situation of the extravasations, which if small and scattered may not at all or only slightly interfere with vision, while if they are large and centrally placed they greatly disturb direct vision. But we know their mischief-making qualities do not end here, as they may (a) break through the hyaloid and invade the vitreous (vitreous hemorrhages); (b) result in proliferating retinitis; (c) cause glaucoma, and (d) if extensive, detach the retina and create a loss of function in such areas of the retina which are deprived of nutrition by their presence and the diseased vessel from which they have proceeded.

In illustration of some of these complications the following cases may be quoted:

Case 1. *Large subhyaloid hemorrhage bursting in the vitreous; complete recovery.* Miss W., aged 55, plethoric, but in apparently good health with the exception of an attack of brachial neuritis, had sudden failure of vision of the left eye on February 20, 1902. Ophthalmoscopic examination revealed a disc, moderately congested, large, uneven, deeply indented veins, and on the nasal side of the disc a huge, sheet-like hemorrhage, spreading away into the far periphery, and along the upper temporal vein a number of small round hemorrhages. The situation of the hemorrhage was apparently subhyaloid. On the following day the hemorrhage burst through into the vitreous, which was so completely filled that no reflex was obtainable and vision was reduced to light perception. The right eye possessed normal vision and there were early signs of arterial degeneration in the retinal vessels. The treatment consisted in absolute rest, systematic diaphoresis by means of cabinet baths and the internal administration of alteratives. Slowly the hemorrhage disappeared, and in two months vision rose to 6/12. Six months later it was 6/6 and no trace of the hemorrhage except a few fine vitreous flakes was discoverable. Since that date until the present time the patient has retained good health and there has been no

recurrence of hemorrhage in the eyes, in spite of the fact that she has submitted to a serious pelvic operation. She has, however, led the most careful life and the vascular tension has been kept normal with suitable remedies and dietetic measures.

Case 2. *Sclerosis of the retinal vessels; retinal hemorrhages; obstruction of the upper temporal artery; later typical proliferating retinitis.* Mr. M. H., aged 55, six weeks prior to his examination on December 4, 1900, experienced sudden depreciation of vision of the left eye, which, without correction, was 6/45, the vision of the opposite eye being 6/6. Ophthalmoscopic examination revealed in O. S. numerous round, striated, and sheet-like hemorrhages and spots of white exudate in the macula. The vessels were sclerosed, and the veins typically pressed and indented. In the right eye there were no hemorrhages; moderate sclerosis of the arteries was visible, with distinct indentation of underlying veins. The systolic tension was 180 and the diastolic tension 130. The urine contained a trace of albumin and a few hyalin casts. There was marked evident arterio-sclerosis of the superficial vessels, the temporals standing out almost like whip-cords. The patient was placed upon the strictest treatment, Dr. H. A. Hare being called in consultation, with gradual improvement in general health and in the ocular conditions until the 9th of October, 1901, when evident obstruction of the upper temporal artery of the left eye was visible. Gradually this vessel was converted into a white cord, and on the 4th of June, 1902, the earliest stages of proliferating retinitis were evident. A vascular veil began to form over the disc, which gradually pushed its way forward into the vitreous, which is at the present time largely filled with vessel-bearing veils of whitish connective tissue which have arisen from the retinal hemorrhages previously described. In the right eye, while now and then a small hemorrhage has appeared, and while the evident arterio-sclerosis and indenting of the veins are most marked, there has been no large extravasation and vision has remained normal. The case has been a triumph, in so far as the right eye is concerned, of careful systematic treatment, chiefly with iodides

and nitroglycerin. The arterial tension in this case is notable. The systolic pressure has been as high as 190 and the diastolic 140. It has been influenced by remedies so as to go as low as 160 systolic, and 125 diastolic.

Case 3. *Retinal hemorrhage; glaucoma passing into absolute glaucoma.* Miss E. K., of gouty ancestry and gouty habit, with albuminuria and occasional attacks of hematuria, one month prior to her examination became conscious of dim vision of the right eye. When examined in consultation with Dr. Horatio C. Wood on the 23d of May, 1903, vision was reduced to counting fingers, there were marked low-grade neuritis with slight swelling of the disc, numerous streaked and plaque-like hemorrhages, and distended and distorted veins, particularly the inferior temporal vein, which was thrombosed and covered and surrounded by numerous hemorrhages. The vision of the left eye was normal; it showed also the marked signs of arterio-sclerosis. The patient continued to do fairly well, until the spring of 1904, or about eight or nine months after her attack, when glaucoma developed. She was not under expert observation at the time, and when she arrived and again came under my care the tension was + 3, the anterior chamber almost obliterated and the lens so hazy that fundus examination was impossible and vision was entirely obliterated. Slowly the ordinary appearances of absolute glaucoma with obliteration of the chamber and discoloration of the iris and chalky whiteness of the lens supervened. At one time enucleation was deemed necessary but was declined. Slowly the pain of the glaucoma subsided, until the eye at the present time represents the late stage of that disease, but is free from congestion and from pain. The left eye has retained its normal vision and there never have been hemorrhages in it, although the well marked early signs of arterio-sclerosis are present. The treatment has been systematic and careful since the attack of glaucoma.

Case 4. *Extensive arterio-sclerosis of the retinal vessels, with perivasculitis, hemorrhages and exudates; large detachment of the upper and outer portion of the retina.* Mrs. X, aged 65, presented herself for examination with the typical signs of arterio-sclerosis.

The details of the case are omitted, except to say that a large detachment of the upper and outer portion of the retina took place in the area of the greatest vascular lesions. The appearances of the retina were exactly those produced by growth, and apparently depended upon an exudate which had formed between the choroid and the retina. The subsequent history of the case is unknown.

Two other ocular conditions deserve mention in connection with the present discussion, and these are referred to especially by Mr. Marcus Gunn in his well-known paper.

He points out that in certain cases of retrobulbar neuritis irregularity in the caliber of the retinal artery may be observed, and suggests that the small artery which passes from the central artery of the retina and supplies the axial fibers of the optic nerve may be subject to such a degeneration and therefore create disturbance in the nutrition of the axial fibers and the symptoms of a retro-ocular neuritis.

He has also noted, as must all of us, the frequency with which lenticular opacities appear in eyes the retinal arteries of which show the signs of degeneration that have been observed, and suggests that the ciliary arteries may be similarly affected and therefore the nutrition of the lens suffer.

Reference has already been made to the association of glaucoma with retinal hemorrhages, and, as Mr. Gunn points out, it is not improbable that arterial degeneration of this character may be responsible for the so-called hemorrhagic forms of this disease. Another point worth mentioning in connection with the prognosis is that high grades of arterial degeneration in glaucoma, as one frequently sees them, particularly silver-wire arteries and indented veins, would render the prognosis of operative interference unfavorable, and it is not improbable that they may be responsible for the hemorrhages and other complications which have occurred after well placed iridectomies in conditions of this kind.

I come now to refer to a matter which has interested me very

much, and which all of us must have seen many times, namely, a *persisting asthenopia* in patients, frequently women, in the late forties, after presbyopia has been established or is already well marked, an asthenopia which yields not to optical therapeutics. Often these patients present the ordinary symptoms of neurasthenia, which in their turn are unquestionably the outcome of a general arterio-sclerosis, and I have found that the asthenopia not infrequently disappears, or is materially modified, if high arterial tension is reduced to the normal by means of proper dietetic measures, and particularly by the use of nitroglycerin.

We come, finally, to take up the question of a *general prognosis,* and the most important relationship is, to use the words of Mr. Gunn, the intimate connection between these ophthalmoscopic changes and the later evidences of cerebral vascular disease. Any one going over his case books would surely find, as Mr. Gunn has, a number of cases which have within comparatively short periods after discovery of these retinal vessel changes suffered from cerebral apoplexy, and the paper need not be burdened with case histories, although many examples have occurred in my practice. But these retinal vessel changes are not only indicative of arterio-sclerosis and especially of endarterial disease in the cerebrum, but are most interesting in the study of chronic nephritis and are important from the diagnostic standpoint, because, as has been well stated, they are often obvious in cases in which the usual retinitis has not developed. In other words, they are part of the symptomatology of arterio-sclerosis, which may be associated with or eventuate in renal sclerosis, and as clinicians of note have stated that fully ninety per cent. of the cases of chronic interstitial nephritis are primarily arterial in causation, this relationship becomes the more important. Furthermore, these retinal vessel changes may be evident where the usual retinitis may not supervene, because they are significant of a process which may terminate fatally before the development of a fully established nephritis.

I come finally to say a word in regard to the duty of the ophthalmologist when he discovers, as he not infrequently does,

the early signs of arterial degeneration in the retinal vessels, notably, the *first indications* which have already been described. Many of these patients are entirely unconscious of the state of their vessels, and often, indeed, they are without symptoms or discomfort. We see these patients when they come for presbyopic correction, or for alteration of glasses; we find the lesions, in other words, casually. Naturally, I do not refer to advanced cases, with hemorrhages, exudates and grave visual disturbances, but to the early lesions, beginning increase in the light-streak and flattening or indentation of underlying veins by rigid arteries. If a patient presents himself with a retinal hemorrhage, or an exudate, or a retinitis, we promptly have him thoroughly examined. How often do we see these early changes and say nothing more about it? To illustrate what I mean I will quote two cases:

Case 1. Mrs. H., aged 58, presented herself on the 21st of November, 1905, for the purpose of having her refractive error corrected, having no other symptoms except some inconvenience in reading. After the correction of a moderate hypermetropic astigmatism, vision rose to 6/5 sharp; with the proper sphericals added the reading point was normal. The media were clear, the retinas free from hemorrhage, but there were well marked signs of beginning arterial sclerosis, the pressure on the veins being most marked, as I think it usually is, in the inferior distribution. One month later the patient began to suffer from slight indigestion, so-called, and again a month later presented herself because of a blur before the left eye. There were now, in addition to the signs already described, large hemorrhages in the inferior portion of the eyeground and small round and dotted hemorrhages scattered elsewhere. A few small hemorrhages were also found in the right eye. The veins were more irregular than at the last visit and their indentation greater. The systolic pressure was 190, the diastolic 130. The urine contained the following ingredients: A slight amount of albumin and a few hyalin casts.

She was immediately placed at rest and the usual treatment instituted, with marked improvement at the end of three months.

The question which I have often asked myself is if I had measured her arterial pressure at the time she was in my office, or caused it to be measured for me, and had I instituted treatment immediately to reduce the high arterial tension, would she not in all probability have been spared the retinal hemorrhages which subsequently appeared. And yet there was nothing in the eyeground, other than a slight indentation of the veins, and she had no symptom of discomfort.

A second case is even more striking.

Mr. L., aged 48, the principal of an important school, applied for a change in glasses which he had been wearing for about three years. Vision was perfectly normal after the correction of a hypermetropic astigmatism, and suitable presbyopic lenses were given. It was noted that the veins were somewhat uneven and distinctly pressed upon, and there was a little brick-red congestion of each disc. The patient was apparently in perfect health, and had no thought of doing anything except the arduous work which his duties entailed. Within two weeks after his visit, he was suddenly seized in the night with a large cerebral apoplexy, and died without returning to consciousness.

Again, except for a little indentation of the veins, there was nothing to indicate any elaborate general examination, and yet, had the arterial tension been measured, and had the man been taken from his active and arduous duties and at once been placed on a rigorous dietetic and medicinal regimen, is it not likely that the apoplexy might have been averted?

It is not necessary to elaborate this side of the discussion by the recitation of more case histories. Evidently the plain duty of the oculist is to search carefully throughout the eyegrounds of his middle-aged patients for any indications of sclerosis of the retinal vessels, and if they are present, even though the patient may be unconscious of any signs of arterio-sclerosis, he should be recommended to thorough general examination and notably to such which includes estimation of the systolic and diastolic blood pressures. If the eyeground examinations are confirmed, suitable treatment may prevent disastrous general

consequences, and perhaps, the serious ocular lesions which later might otherwise arise. It should not be forgotten that where ophthalmoscopic examination reveals positive signs of sclerosis of the retinal vessels, these assume, with comparatively few exceptions, a position of diagnostic importance in the study of arterio-sclerosis which equals, if it does not exceed, certainly in so far as cerebral arterio-sclerosis is concerned, that furnished by the four important clinical symptoms of the disease. Hence the necessity of ophthalmoscopic examination in the study of any set of obscure symptoms which may be connected with early arterio-sclerosis.

A CASE OF RETINITIS PROLIFERANS, WITH DEVELOPMENT OF A SYSTEM OF BLOOD VESSELS UPON THE OPTIC NERVE.

BY WILBUR B. MARPLE, M.D.,
NEW YORK CITY.

In 1901 the writer presented the report of a case of this description to this Society. In the Fall of that same year, Nov. 11, 1901, a second case came under his care, in which a similar vascular system developed gradually under his observation, a brief history of which is herewith presented. The points of special interest in the case are, first, the fact that the very gradual development of the condition was observed by the writer himself, and, secondly, the fact that it seems very likely that the condition will cure itself by a process of slow strangulation of the vascular network. The first trace of any vessels on the disc was observed in November, 1902, and in December, 1903, the vascular network had attained its maximum growth, so that about thirteen months were occupied in its development. The illustrations presented were made by Mr. Louis Schmidt, of Philadelphia; all except the last one are copies of sketches made by myself on the occasion of the patient's visits. I tried for nearly two years to obtain the patient's consent to have the artist draw the fundus,

but only succeeded in securing it about two months ago. The last drawing has been made from life by Mr. Schmidt. I wish to express my sincere thanks to this artist for his extreme patience and care in doing this work. Had he seen the fundus himself, at the commencement, his task would have been relatively easy; but, as it was, many revisions had to be made, under my direction. I was especially glad, therefore, that he finally got an opportunity to draw the condition from life. This enabled him to better comprehend the features of the case, and more intelligently make slight corrections to his previous drawings. So that, as they are now presented, it is difficult to see how they could be improved upon.

The patient, a married lady, aged 63, first consulted me on Nov. 11th, 1901, on account of impaired vision of the right eye, which she had noticed for four or five days. Her left vision is, and has always been since she has been under my observation, 20/20 with normal reading with presbyopic correction. When first seen her right vision was 20/70, unimproved. Field normal. With the ophthalmoscope the nerve appears almost normal; possibly a little fuzzy at lower nasal quadrant. Just below the macula are two very minute hemorrhages, seen only with great difficulty after using a mydriatic; there is a small area of retinal œdema just above. There is nothing abnormal about the heart, and the urine shows no evidence of renal disease. (The patient says that she had antrum trouble three years ago, for which she was operated on by a prominent laryngologist of this city, following which there was a discharge for some months.) A week later the ophthalmoscopic appearance was considerably changed. There was more fuzziness of the lower nasal edge of the nerve and downward and outward from the latter there is a considerable area of exudation with hemorrhages. From now on the hemorrhages became more numerous, and were scattered all over lower and temporal half of the fundus.

Dec. 5, 1901. Right vision was 20/200; looking a little above (eccentric) it was 20/100. The ophthalmoscopic appearance is shown in Fig. 1. There is a subhyaloid hemorrhage below the

FIG. 1 December 5, 1901.

Subhyaloid hemorrhage below macula. Numerous hemorrhages below and to the right, also one or two apparently exudations. Below a large vein branches which is quite white, with retinal œdema in the vicinity. V = 20/200. If patient looks a little above, V = 20/100.

FIG 2. January 14, 1903.

There is a formation of connective tissue on the disc (the apex is seen with + 6 D. sph.), like two fingers (one above and the other below) filled with fine vessels. Two or three exceedingly minute vessels can be seen branching from the apex toward the right. There are one or two small extravasations in the vitreous in the vicinity of the apex. Passing down from the disc is an apparently obliterated vein, and off to the right and below are several very fine branching white lines. R. V. = 20/200.

FIG. 3. April 6, 1903.

The growth has developed downwards considerably. Apex seen with + 8 D sph. V = 20/30.

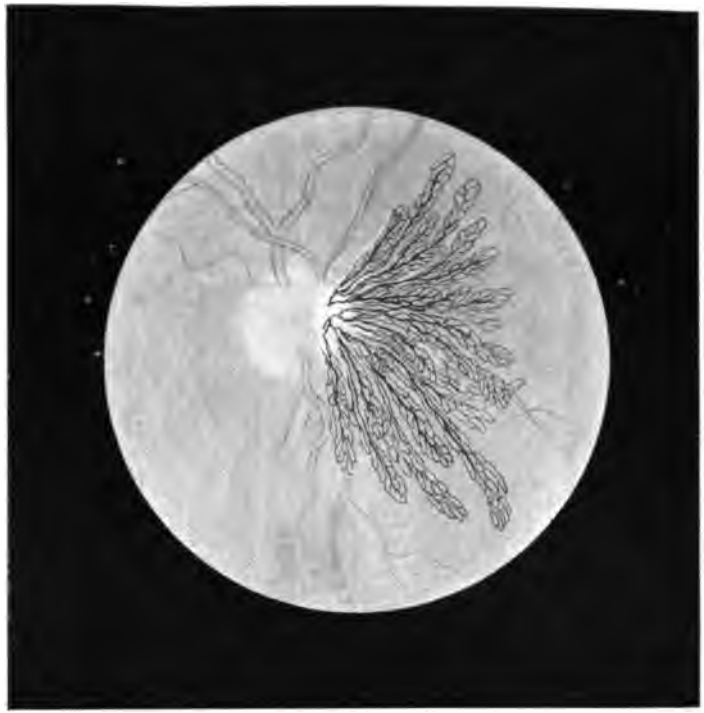

FIG. 4. July 1, 1903.

Growth is developing upwards also. Apex seen with + 3 D sph. R V = 20/30. The connective tissue is very white and conspicuous.

macula, with a considerable area of retinal œdema below where one of the veins branching is perfectly white. There is a scotoma just above the fixing point corresponding to the sub-hyaloid hemorrhage. Two weeks later the hemorrhages in lower temporal quadrant were more numerous, and in several places the vessels were merely white lines. A month later there was marked œdema surrounding the infero-temporal artery.

Jan. 31, '02, there was a little connective tissue following a vessel below. The vision had improved to 20/40.

Mar. 22, '02. Most of the œdema had disappeared, though there were a few scattered hemorrhages below and to the temporal side of the disc, and one vessel has a white appearance. Vision 20/30— and there is micropsia. There was no especial change noted until Nov. 4, 1902, a year after the patient was first seen, when some shreds of connective tissue were seen passing into the vitreous above the disc, and two weeks later (Nov. 17, 1902) in the connective tissue on the disc there was an appearance like a blood vessel passing above and below; the apex was seen with + 4 D. sph.

Two months later, Jan. 14, 1903, the appearance was as shown in Fig. 2. The vascular system, the beginning of which was made out Nov. 17, '02, has increased in size; its apex can be seen with + 6 D. sph., and is like a branched finger filled with fine vessels. Two or three very fine vessels can be seen branching from the apex and passing a little towards the right. There are two or three small blood clots in the vitreous in the vicinity of the apex. Passing down from the disc is an obliterated blood vessel and off to the right are several very fine branching white lines, like the terminal filaments of an obliterated blood vessel.

April 6, '03. Growth extends much further down, and the apex can now be seen with + 8 D. s. (Fig. 3).

May 18th. The vascular system is spreading around to the nasal side of the disc, and on July 1, 1903, presented the appearance shown in Fig. 4, and the apex was still seen with + 8 D. sph.

The patient went abroad immediately after this, and I did not

see her again till Nov. 6, 1903, when the vascular growth occupied the whole nasal half of the disc as shown in Fig. 5, and the apex was seen with + 12 D. s. There was a small scotoma just above the fixing point, and the vision was 20/30.

Dec. 14, 1903. The growth extended 3 n.D. above the disc; 2 n.D. to nasal side and 4 n.D. below. When the patient moved the eye the terminal fringes moved back and forth in the vitreous. There was an extravasation near the upper periphery of the vascular network.

April 30, '04. Several very fine vessels could be made out, passing from the upper part of the system horizontally towards and above the macula.

Oct. 13, 1904. Right vision = 10/200. There is a little band of the finest vessels passing through the vitreous towards and below the macula.

Two weeks later the vitreous was somewhat hazy and there were a few vessels below the macula. A little below the latter is a very fine connective tissue filament with a round white end, the latter reflecting the light most beautifully. This also moves back and forward with the movements of the eye.

Jan. 17, '05. There are a few vessels passing from the disc above the macula. Vision 20/50+. Has been taking iodide of potassium, 30 grains daily, for some weeks past.

A period of thirteen months now elapsed before I saw the patient again, and I had given a bad visual prognosis to her family physician. The case was so exactly similar to the one which I reported to this Society in 1901, where the sight was lost by an intraocular hemorrhage, that I quite anticipated a similar *denouement,* especially as on several occasions I had made out some extravasations at the periphery of the vascular fringe. So that I considered it extremely probable that some of the large loops would rupture some day, and fill the eye with blood. I was therefore quite unprepared for the surprising change in the ophthalmoscopic picture which I discovered when I next saw the patient, Feb. 9, 1906. This picture was practically the same as

FIG. 5. November 6, 1903.

The vascular growth occupies the whole nasal side of the disc, and the apex is seen with + 12 D. sph., extending upwards about 3 n. d.; to nasal side 2 n. d; and below about 4 n. d. As the patient moves the eye the terminal fringes move back and forth. The whitish connective tissue on the disc is very bright. There is a small scotoma just above the fixing point. R. V. = 20/30.

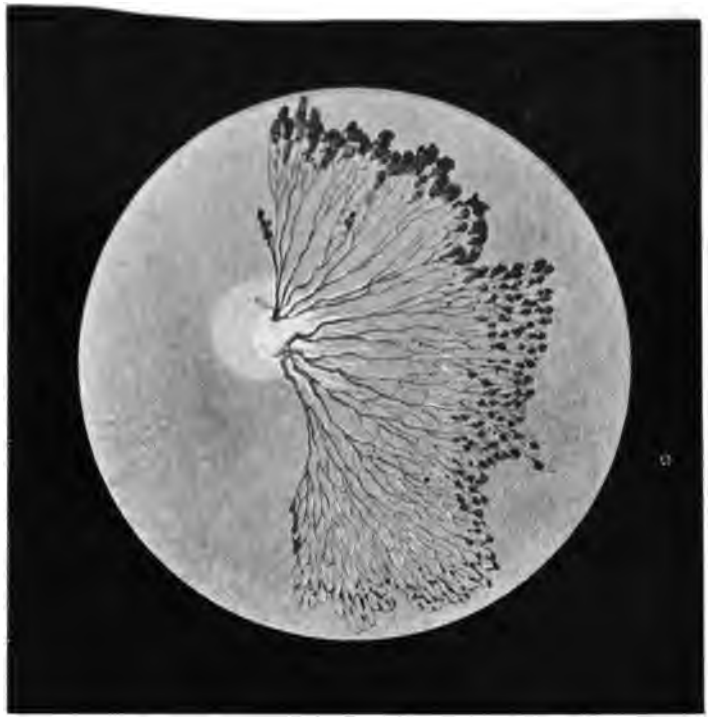

FIG. 6. April 16, 1906.

The main filaments seem to contain blood, apparently not circulating, while the fine network is entirely empty. At various points, especially above and in periphery are numerous dilatations or ectasiae of the blood vessels. There are also breaks in the blood columns at some points. The connective tissue on the disc is greater in amount, and apparently the growth of this latter has shut off the vascular supply. R. V. = 20/30.

is shown in Fig. 6, drawn from life by Mr. Schmidt two months later, April 16, '06.

The following notes, descriptive of the appearance, were made at the time: The main vascular filaments seem to contain blood, apparently not in circulation, while the finer network between the larger vessels is entirely empty, and looks white as the light is thrown on it. At various points, especially above and in the periphery, are numerous dilatations or ectasiæ of the blood vessels never seen before. There are also breaks in the columns at several points, and it is evident that there is no circulation any longer in the vascular system, and the whole formation presents a wholly different appearance from what it ever did before, and is evidently retrograding. The connective tissue on the disc is much greater in amount and apparently the growth of this and its contraction had shut off the vascular supply. So that I felt in all probability the danger to the vision was past, and that the vessels in time would become quite empty, leaving merely a connective tissue network, which, located as it is on the nasal side of the disc, offers very little obstruction to vision. This anticipation has been confirmed by my last observation of the patient, June 15, '06, when I found the system mostly empty. The dilatations shown in Fig. 6, which in February were quite dark, are now so thin that when the light is thrown on them they seem translucent, and almost of the same pink color as the rest of the fundus. The vision is 20/30.

I feel confident that there is nothing further to fear in this case, as far as the vision is concerned; a result I had not anticipated at all eighteen months ago.

A CASE OF CONGENITAL CYST OF THE ORBIT WITH MICROPHTHALMOS.

BY ALEX. QUACKENBOSS, M.D.,

BOSTON, MASS.

PATHOLOGICAL EXAMINATION BY F. H. VERHOEFF, M.D.

In 1893, at a meeting of this Society, Dr. George C. Harlan reported "a case of congenital cyst of the orbit with anophthalmos," again in 1902, "a case of congenital orbital cyst with microphthalmos"; to these I would like to add the following case.

Walter S., 14 years of age, born in Massachusetts, presented himself at the Massachusetts Charitable Eye and Ear Infirmary, November 28, 1905, to see if something could be done to the left eye so that he might wear an artificial one. He stated that the left eye had been defective from birth and that so far as he knew there had been no change in the eye. He had never seen out of the eye, and for a number of years the lower lid had turned out.

The boy is well developed for his age and shows no other congenital defects. The right eye is normal in every way, vision 20/20. The left palpebral fissure is shorter than the right by 1/4 inch, the lower lid is turned out and shows the effect of long exposures. Examination reveals what appears to be a very small eye situated in the usual position in the orbit; it moves in conjunction with the other eye, although motion is greatly limited. Through the lower lid is felt a well rounded elastic tumor, not adherent to the orbit.

Operation, ether. The conjunctiva was cut around the globe as for the ordinary enucleation, the muscles were apparently present and were divided, but in attempting to cut the nerve the cyst was punctured and its contents, a thin watery fluid, escaped. After the eye was removed it was seen that the cyst was attached to the globe in the vicinity of the nerve. The cyst

was then easily dissected out; it extended deep into the orbit but was not adherent to the walls. The orbit was irrigated out with corrosive 1-5000, and a purse string suture was applied to the conjunctiva. Healing uneventful; discharged from the Infirmary in five days.

Pathological Examination. The specimens submitted for examination consist of an eye and a large cyst which was separated from it at operation. Diameters of globe: Antero-posterior, 14 mm.; horizontal, 13.5 mm.; vertical 13 mm. The globe was hardened in formalin, frozen, and sectioned horizontally.

The globe is regular in shape anteriorly, but posteriorly it is slightly distorted and takes on a conical form with apex at entrance of the optic nerve. The insertions of the four recti muscles are readily made out, but those of the two obliques cannot certainly be distinguished from the fibrous tissue attached to the globe. The tendon of the internal rectus is 7 mm. wide and inserted 4 mm. from the limbus, while the other tendons are narrower and inserted farther back. The cornea is situated eccentrically downward and its normal elliptical shape is much exaggerated, its vertical diameter being 3 mm. and its horizontal 5.5 mm. It is .8 mm. thick, bluish in color, and translucent. The iris is represented by a narrow rim .5 mm. wide and .4 mm. thick, projecting from the ciliary body. At the pupillary margin the iris is folded sharply back upon itself all around. The folded part is not continued backwards very far except below where it takes the form of a triangular flap 3 mm. long with a base 2.5 mm. broad, firmly united to the posterior surface of the iris and ciliary body. The pupil is 3 mm. wide and nearly round. The ciliary body is represented by a thickening of the choroid beginning at the ora serrata 8 mm. behind the limbus. It reaches a thickness of .4 mm. Anteriorly there are no signs of ciliary processes, but near the ora serrata these occur as small ridges about 5 mm. apart. Connected with the surface of the ciliary body below there is a

small, perfectly black, globular body, 1.25 mm. in diameter, evidently a cyst.

The lens is situated 5 mm. behind the cornea, leaving a space filled with clear fluid, the largest chamber in the eye. The lens is held in place by a delicate zonule attached at the ora serrata. It is also anchored at its posterior pole by a strand of tissue which connects it with the optic nerve entrance or the entrance into the cyst. The greatest horizontal diameter of the lens is 5.5 mm., vertical 4 mm., antero-posterior 4.5 mm. In a general way its shape may be described as pyramidal with apex behind. On section it shows a narrow rim of comparatively clear cortex .5 mm. wide then an opaque zone of equal width surrounding a central clearer nucleus. The vitreous humor consists of a thin layer not more than 2 mm. in thickness, normal in consistency, which separates the lens from the retina. The choroid is apparently normal, as is also the retina except that on one side it is separated from the choroid by a coagulum. The sclera is .2 mm. thick anteriorly and .5 mm. thick posteriorly.

The optic nerve enters the globe at a point much lower than normally would be expected. Near the point of entrance it is 1 mm. in diameter. Its sectioned surface is translucent and shows no striae. Sections made in suitable directions, show that the nerve merges below with a mass of tissue, somewhat larger in diameter than the nerve itself, which accompanies the nerve through the sclera into the retina. The sheath of the nerve is formed by a continuation of the sclera and near the globe surrounds both the nerve and the tissue beneath it. There is no subdural space visible. By comparing the cut surface of the cyst at the point it was severed from the globe, with the posterior aspect of the latter, it is apparent that the sheath of the nerve was continuous below with the wall of the cyst. The defect in the sclera, including the space occupied by the optic nerve, is 4 mm. in greatest diameter and is completely filled up with tissue derived from the retina, which can also be traced into the cyst.

The cyst is approximately 18 mm. in diameter and shows a solid mass of tissue where it was connected with the globe. Its

wall varies from .1 mm. to 2 mm. in thickness, and has a perfectly smooth inner surface. The fluid contained in the cyst was lost at the operation.

Histological examination. The posterior half of the cornea presents a normal appearance. Both Descemet's membrane and the endothelium are intact and normal. Anteriorly the corneal stroma passes rather abruptly into a layer of vascularized loose fibrous tissue and reticulum similar to the sub-epithelial connective tissue of the bulbar conjunctiva, with which it is continuous. This layer is covered with epithelium which bears little resemblance to that of a normal cornea. It is thicker and sends down deep interpapillary down growths, thus resembling normal skin. Bowman's membrane is absent.

The ligamentum pectinatum is easily recognizable as such, but is composed of much coarser trabeculae than is normal. The canal of Schlemm is often well seen. The ciliary muscle is connected with the ligament in a normal manner and is fairly well developed, but shows few circular fibres. Below, the muscle fibres can be traced as far as the opening in the sclera, where they become lost in the connective tissue. Elsewhere they extend backward no farther than usual. The ciliary body shows no ciliary processes anteriorly, but these are developed far back near the ora serrata.

The iris arises from the ciliary body in a comparatively normal manner and histologically presents a normal structure. The iris stroma shows no departure from the normal. The anterior boundary layer is deeply pigmented. At a short distance from the ciliary body the iris is folded back upon itself, that is, is retroverted. Above, the folded part is very short and in some sections the pigment layer is not involved, the stroma alone being prolonged and folded. Below, on the other hand, the iris corresponds in width to a normal one. The folded portion is almost everywhere fused with the ciliary body, a line of pigmented cells here and there being left to represent the pigment epithelium. Some of the sections show, however, where the fusion has been incomplete, a fairly large cystic space lined by pigment epithelium.

The sphincter pupillae is shown in most of the sections well developed, and is usually situated at the point where the pigment epithelium ceases, though this relationship is sometimes obscured. The dilatator pupillae can also often be seen beneath the pigment layer.

The choroid in places is apparently normal, in other places, notably in the region of the ciliary processes, it is thicker, more coarsely fibrous than normal, and the membrane of Bruch as well as the chorio-capillaris fails. Posteriorly it ends more or less abruptly at the margins of the scleral opening.

The pars ciliaris retinae consists of two layers of cells, both deeply pigmented, similar to the pars iridis retinae. This condition usually obtains until the choroid is reached, when the outer layer loses its pigment. The ciliary processes are as a rule smaller than normal but otherwise display a normal structure. The stroma is hyaline and they are covered with an inner pigmented and an outer unpigmented layer of epithelium. The fibres of the zonule of Zinn can be plainly seen attached to their surfaces. Near the ora serrata the cells of the unpigmented layer of the pars ciliaris retinae are elongated as usual, and become rather abruptly continuous with the pars optica retinae. The latter for the most part presents the typical picture of gliosis retinae, the gliosis becoming more and more marked as the scleral opening is approached. Above, however, there is a considerable stretch of retina that shows scarcely any gliosis in which all the retinal layers are intact except the layer of multipolar ganglion cells. Here, as well as in some places where the gliosis is far advanced, the rods and cones are fully differentiated. Directly below, neither the choroid nor the pars optica retinae has developed and the pars ciliaris retinae extends all the way to the scleral opening. Near the latter the two layers display the most marked hyperplasia, the unpigmented layer forming numerous tubular and rosette-like structures which project into the vitreous chamber, and both layers growing downward, together or separately, into the underlying tissue. The wall of the small cyst attached to the surface of the ciliary

body, is formed by two layers of pigmented epithelium arising from the pars ciliaris retinae. Where the pars optica retinae has developed the pigment layer is normal, showing only here and there a small colloid excrescence.

The little vitreous humor within the eye appears normal. Near the scleral opening it is continuous with vascularized connective tissue connected with the posterior pole of the lens, which no doubt represents the remains of the mesenchymal tissue that accompanied the hyaloid artery. Beginning at the ciliary processes the retina is lined by a hyaloid membrane which is occasionally accompanied by blood vessels, as in an embryonic eye, some of which still contain blood.

The lens shows advanced cataractous changes throughout, associated with deposits of lime salts. The changes are most marked, however, in the perinuclear zone, which accounts for the macroscopic appearance of a lamellar cataract. The capsule is normal and the capsular epithelium shows no proliferation.

At the margin of the scleral opening (coloboma) the choroid ceases, but the retina follows the sclera into the cyst cavity. At this point the retina is thrown in folds which are forced into the opening, thus completely blocking it. Into this mass of retinal tissue, septa penetrate from the sclera and unite with the connective tissue accompanying the retinal vessels, which is here much increased. There is thus formed a sort of a typical cribriform plate. The tissue spaces in these septa are frequently lined with pigmented or unpigmented epithelium arising from proliferation of the pars ciliaris retinae below.

After the retina passes through the opening its folds become fused into a uniform mass of neuroglia permeated by blood vessels. The walls of the latter show hyaline and often calcareous degeneration. This mass of neuroglia is also continuous above with the optic nerve. A cross section of the nerve shows that the nerve fibres have been completely replaced by neuroglia, though the normal structure of an optic nerve is to a certain extent still preserved. Sections of a portion of the nerve treated with osmic acid show no fat or myelin.

As just explained, the cyst cavity is not in free communication with the interior of the globe, the passage through the sclera having been occluded by the proliferation of neuroglia from the retina. The wall of the cyst is composed of dense hyaline connective tissue continuous with the sclera, in which occur areas of neuroglia whose retinal origin is easily recognized. It is not as a rule lined by epithelium, but here and there a thin layer of low unpigmented epithelial cells may be seen for a short distance. Often this layer can be traced into a crevice in the wall filled with neuroglia. Connected with the cyst wall near its union with the globe there is a considerable amount of smooth muscle.

Remarks.

It is evident in this case that the microphthalmos was dependent upon the extra-ocular cyst and that the latter in turn resulted from a defect in the sclera in the region of the ocular cleft. Probably the sequence of events was somewhat as follows: Owing to an incomplete closure of the cleft in the secondary optic vesicle, the choroid and sclera, lacking the normal stimulus, failed to develop properly behind the cleft. As a result a defect was left in the ocular wall which involved the optic nerve and extended as far forward as the ora serrata. As the eye enlarged the ocular wall became ectatic at this point, a cyst was formed, and the retain was forced into its cavity. At the same time the hyaloid artery accompanied by its mesenchymal tissue was also carried into the coloboma, thus dragging the lens backward. The retroversion of the iris was due no doubt to its adherence for a time to the tunica vasculosa lentis as the lens receded. The failure of the ciliary processes to develop in their normal situation would seem to accord with the observation of Treacher Collins.* For since the lens was held back and prevented from coming in contact with the anterior part of the ciliary body, no ciliary processes or zonular fibres could develop here. On the other hand, the zonular fibres from the ora serrata were probably formed at the usual time and in the normal

* E. Treacher Collins, on the development of the accommodative power of the human lens. The Royal London Ophthalmic Hospital Reports, 1905, vol. xvi, p. 123.

way. The formation of the ciliary processes at this unusual situation can perhaps be explained by the fact that the contact of the lens with the ora serrata must have been unduly prolonged, owing partly to the traction exerted on the lens by the hyaloid artery. In this case it is impossible to determine whether the cyst was originally lined with retinal elements derived from the inner or the outer layer of the secondary optic vesicle. The presence of neuroglia in the walls of the cyst would seem to indicate that it was lined by the inner layer.

DISCUSSION.

Dr. G. C. Harlan, Philadelphia: I reported two of these curious cases of what are usually termed lower lid cyst with anophthalmos and microphthalmos, one in 1893 and one in 1902. In studying the literature I found the pathology extremely obscure reading, and was inclined to agree with Panas who considers this the most obscure chapter in ocular pathology. Most authorities agree that these cysts are formed of embryonic elements intended for the development of the eye, and on the result of an imperfect closure of the fœtal fissure, though a few insist that they have no necessary connection with the globe, when development is prevented by their presence.

MULTIPLE MYELOMA WITH INVOLVEMENT OF THE ORBIT.

BY ALEX. QUACKENBOSS, A.M., M.D.

BOSTON, MASS.

PATHOLOGICAL EXAMINATION BY F. H. VERHOEFF, A.M., M.D.

A. S., male, 58 years of age, born in Canada, was admitted to the Massachusetts Charitable Eye and Ear Infirmary on November 13, 1905. His parents lived to an old age, one brother died of a tumor, another brother is living at the age of fifty, but in poor health. Mr. S. has always been well up to the

present illness; two years ago had nasal polypus removed. Six months before entrance to the hospital he complained of seeing double, and shortly after, noticed that the left eye was more prominent than the right, this has gradually increased up to the present time. Two months ago noticed swelling at the upper part of the sternum. Has been hoarse for the past few months.

Physical Examination: Fairly well developed and nourished —anaemic. Over sterno-clavicular articulation is a smooth rounded tumor 6½ x 8½ cm. in size. Lungs normal — heart and arteries show signs of arterio-sclerosis. Abdomen negative.

Eyes: right, vision normal, few fine opacities in lens, fundus normal. Left, vision 1/10, not improved with glass, fine diffuse opacities in lens, optic neuritis. At the upper and outer half of the orbit, is felt a hard bone-like mass, in shape and size resembling somewhat the lachrymal gland, firmly attached to the orbit wall. Toward the nasal side, another tumor is felt, but more elastic to the touch and situated deeper in the orbit.

Naso-pharynx negative.

Examination of the blood showed nothing remarkable. The first routine examination of the urine, made upon entrance to the Infirmary, showed the presence of albumen.

An exploratory operation was advised, and on November 20th, an incision was made along the upper, outer, edge of the orbit, and a hard cartilaginous tumor was found, firmly attached to the bone. In attempting to remove this tumor, considerable force was employed, and it collapsed, the contents, a gelatinous material, escaping. Part of the bony wall or shell of the tumor, with quite an amount of its contents were secured for pathological examination. At the same time a piece from the growth over the sternum was removed.

Following the operation on the eye there was marked swelling of the upper lid and exophthalmos, the eye being pushed forward so that it was impossible to keep the cornea protected, and a superficial ulceration resulted. This swelling gradually disappeared, the eye fell back into place, and the ulcer on the cornea healed. The wound along the orbit healed nicely.

After Dr. Verhoeff examined the specimens sent to the pathological laboratory, he suggested the examination of the urine for albumose, and it was found to be present.

Dr. L. J. Henderson of the department of biological chemistry, Harvard University, looked the urine over and reported as follows: "The urine which you ask about contained on my first examination of it at the Eye and Ear Infirmary, a considerable quantity of a proteid substance which precipitated, on warming to fifty or sixty degrees, redissolved on boiling and reprecipitated on cooling. The later specimen of urine which I received here, contains a trace only of this proteid, so that a careful characterization of it is impossible with the material on hand. However I think that it may be regarded as the "Bence Jones'" body or an allied substance."

The use of Çoley's serum was advised but after the eye quieted down the patient wished to go home.

Mr. S. was in the hospital five weeks, during this time there was a gradual loss of strength, but at no time did he complain of pain. There was more or less digestive disturbance, and several attacks of nose bleed.

Through the kindness of Dr. A. J. Gallison of Franklin, Mass., I was able to follow the case. He writes that S. failed steadily after leaving the Infirmary, the growths in the orbit and sternum increased, and in addition four new growths appeared over the right thigh. There was considerable hemorrhage from the nose, towards the end, but the patient kept up and about until twenty-four hours before death which occurred January 16, 1906. No autopsy.

Duration of Disease: From the time he first noticed trouble with his eye, eight months.

The etiology of this disease is obscure, the cases reported have been mostly among the laboring classes. Heredity and trauma have been suggested as possible causes. By some it has been considered an infective process. Syphilis has no bearing. It is more common in males than females, and usually occurs in the middle or later part of life.

The characteristics of the disease are pathological changes in the bone marrow, found in connection with a peculiar proteid body (Bence Jones') in the urine. The disease seems to be closely allied to sarcoma, but differs from it, in that several parts of the body are attacked at the same time, and that there is no tendency to invade other organs by metastasis. It is confined to the skeleton; the ribs, sternum, and vertebræ being a favorite seat; the pelvis, skull, and long bones may be involved; few, if any, cases affecting the orbit have been reported. The new growth is soft and gelatinous, and may be confined to the interior of the bone, or break through and form a tumor of considerable size.

The symptoms vary greatly according to the location of the disease. In some cases pain is the predominant feature, while in others it is entirely absent; marked deformity of the skeleton is reported in certain cases, in others nothing abnormal is to be seen. Spontaneous fracture of the long bones may occur. Bone symptoms may be slight or absent, and the nervous system show signs of marked disturbance. Anaemia and increasing weakness are constant.

Urine: Most cases of multiple myeloma show the presence of albumose in the urine. The amount present in any given case is not constant, and may vary during the course of the disease. May consider as albumose, all proteids in the urine which dissolve on heating, to reappear on cooling, in the presence of certain reagents. Albumosuria shows that a destructive process is going on in some part of the body, and may be found in multiple myeloma and in some forms or stages of tuberculosis — lobar-pneumonia — septicaemia — pyemia — sarcoma and carcinoma. Aside from the presence of albumose, the urine shows no special characteristics: the amount may be normal, increased or diminished. The condition is not necessarily associated with pathological changes in the kidneys; some examinations have showed that the kidneys were normal, while in others interstitial nephritis was found to be present.

Prognosis is bad, the disease usually ends fatally inside of two years: one case is reported to have lived seven years.

Treatment is of little avail; arsenic, X-ray and Coley's serum have been advised.

Pathological Examination.

The material submitted for examination consists of tissue removed from the orbital growth, some of which contained bone broken from the margin of the orbit, and also tissues from the growth over the sternum. Macroscopically the tissue from both situations is soft, translucent, and slightly yellow in color, somewhat resembling adipose tissue, and its cut surface is more or less distinctly lobulated. Fixation in Zenker's fluid.

On microscopic examination, the tumor presents much the same appearance throughout, having in a general way the structure of a small round cell sarcoma. The individual cells of the parenchyma are loosely packed together in a uniform mass through which run septa of connective tissue carrying the blood vessels. At the advancing margins of the growth it makes use of the invaded connective tissue for its stroma. The tumor cells are remarkably uniform in size and appearance and when stained by hematoxylin and eosin are indistinguishable from plasma cells. They are round or ovoid in shape, their cytoplasm is strongly basophilic, and their nuclei have the eccentric situation seen in plasma cells. The chromatin in the nuclei shows the arrangement characteristic of plasma and lymphoid cells, presenting coarse granules attached to the thick nuclear membrane. Most of the cells are mononuclear but occasionally a cell contains two to four nuclei.

Special staining[1] brings out in each nucleus a perfectly definite nucleolus which in the alum hematoxylin specimens is masked by a deeply staining chromatin. In sections stained in Mallory's phosphotungstic acid hematoxylin[2] each cell shows in its

[1] Celloidin sections are stained for twenty-four hours in a two per cent. solution of eosin in eighty per cent. alcohol. Water. Potassium permanganate 1:300, thirty seconds. Water. Oxalic acid 1:1000 until color of eosin returns, 1-3 minutes. Water, alcohol, etc.

[2] Before staining in this fluid the sections should be treated as follows: Potassium permanganate 1:300, 15 minutes. Water. Oxalic acid 1:1000 until yellow color is removed. This differentiates both the centrosomes and the fibroglia fibrils.

cytoplasm contiguous with the nucleus, an ill defined round area paler than the rest of the cytoplasm which contains in its center two deeply staining blue dots (centrosomes). Sometimes there seems to be one dot only, but careful focusing usually shows that this is due to one dot hiding the other from view. Where two nuclei occur in a cell, four dots are usually to be made out, although only one pale body is present. Mitotic figures are abundant in the tumor of the sternum but are not found in the orbital growth. Shrunken nuclei with deeply staining chromatin are frequently seen, but these are no doubt simply degenerated. The cytoplasm of some of the cells with degenerated nuclei has taken on a hyaline appearance and stains intensely in eosin, so that the cells closely resemble nucleated red blood corpuscles. Hyaline globules of the same size as these cells, and evidently of the same nature, from which the nuclei have disappeared, are also not infrequently encountered. A much more common form of degeneration, however, if such it is, consists in the occurrence of numerous minute vacuoles at the periphery of the cytoplasm, giving the cell a frayed out appearance. Often this change is so marked that by a coalescence of the vacuoles a clear peripheral zone is produced which separates the cytoplasm from the cell membrane.

The stroma of the tumor consists of delicate fibrillar connective tissue which marks it off into more or less distinct alveoli, and of reticulum. The latter cannot be made out everywhere, owing, probably, to the rapid growth of the tumor. It is brought out best by Mallory's connective tissue stain. Accompanying the stroma there are an unusual number of Mallory's fibroglia fibrils. These are apt to be extremely long and can often be traced into relationship with flat cells having elongated nuclei in the manner described by Mallory for normal tissues. The fibroglia fibrils are best seen in sections stained in phosphotungstic acid hematoxylin but are also well brought out by the acid fuchsin in the connective tissue stain. The fibrils are also found in great numbers running between the individual tumor cells, although no doubt in every case they originate in the connective tissue stroma.

FIG. 1.

2

3

4

The growth is well supplied with blood vessels. Some of the smaller vessels have very thin walls and are immediately surrounded by the tumor cells, as is usually the case in sarcomata. There are no areas of complete necrosis or hemorrhage and the tumor is nowhere infiltrated with chronic inflammatory cells. There are also no phagocytic epitheloid cells such as are seen in typical lymphoid tissue. Except for the slight but distinct difference in the character of the cells, the appearance presented at the margin of the growth resembles that of a chronic inflammatory infiltration. The tissue removed from the margin of the orbit shows extensive invasion of the medullary spaces by the tumor, but the bony lamellae are not directly attacked.

Diagnosis: Myeloma of sternum and orbital wall.

Remarks.

The character of the tumor cells in this case, and the occurrence of nodules in two situations, leave no doubt that the growths belong to the type of tumors classed as multiple myelomata. In fact, the morphology of the cells is alone sufficient for the diagnosis, since so far as is known such cells are peculiar to myelomata. The exact nature of these cells has not yet been definitely determined. All that is certainly known about them is that they arise in the bone marrow. Most observers* have regarded them as allied to myelocytes, though attempts to demonstrate neutrophile granules in them have practically always failed. Wright has advanced the view, recently supported by Hoffman, that the cells are plasma cells. This view seems to accord best with the findings in the present case. The only difference that could be made out here between the tumor cells and plasma cells was the presence of fully differentiated nucleoli in the former, and this probably could be accounted for by the rapid proliferation of the tumor cells. The finding by special staining of centrosomes in the cells of this case is also in favor of the plasma cell theory. Plasma cells found in chronic inflammatory conditions, which

* The complete literature on myeloma has been collected by Menne, Zür Kenntnis des Myelomzellen, Virchow's Archives, 1906, Bd. 183, p. 115.

were subjected to the same staining method, showed centrosomes having exactly the same situation and appearance as those in the tumor. However, it must be noted that this method shows centrosomes in a variety of other cells.

Ribbert has recently reported a case in which he believed he was able to demonstrate a transition of tumor cells into nucleated red blood corpuscles. He therefore took the view that the tumor cells in his case were the anlages of red blood corpuscles. In the present case cells similar to nucleated red blood corpuscles were also found, but they were regarded as degenerated plasma cells. Such cells are often formed by the degeneration of plasma cells in many pathological conditions and hence their occurrence in the tumors would seem to support the view that the cells of the latter are plasma cells rather than that they are nucleated red blood corpuscles. It does not seem impossible, however, that red blood corpuscles are normally formed by a degeneration of this kind and that the similarly degenerated plasma cells found in chronic inflammatory conditions really represent a typical nucleated or even non-nucleated red blood corpuscles. An attempt to reconcile the different views in regard to the nature of the cells of myelomata has been made by Scheele and Herxheimer, who assume that the cells arise from undifferentiated elements of the bone marrow and thus may at times become differentiated into myelocytes, plasma cells, or erythroblasts.

TRANSIENT MYOPIA DUE TO TRAUMA.*

By THOMAS R. POOLEY, M.D.,

NEW YORK CITY.

The following case, in which temporary myopia developed, as the direct result of an injury, is so unique in my experience, that I have thought it worth while to bring it to the attention of the Society.

* Read by title at the Meeting of the American Ophthalmological Society, June 28, 1906, New York City.

On April 26th, 1906, Robert Holson, aged 34, consulted me at my clinic, on account of an injury to his left eye. The day before I saw him, while chopping a piece of steel plate, he was struck on the eye. According to his statement, the fragment which struck the eye was ½″ x ¼″ in size. The force of the blow felled him to the ground, causing nausea and temporary unconsciousness. He says that as an immediate result, there was a loss of vision, which, however, soon returned, to some extent.

Examination of the patient's eye showed a widely dilated pupil, in a vertical-oval direction. Atropine had been used. There was slight hyphaemia, but positively no evidence of a penetrating wound. Pain on pressure over the ciliary region; shallow anterior chamber; slight ciliary injection. V=20/100. The ophthalmoscope showed the following condition: A hemorrhage from the principal upper vein near the optic disc; the outer and lower part of the retina was hazy.

The patient was admitted to the hospital, treated by rest in the recumbent posture, the application of a pressure bandage, and atropine. He was discharged May 1st. The blood had disappeared from the anterior chamber; the hemorrhage from the vein was still visible; the retina had entirely regained its normal transparency. It was now noticed, for the first time, that he had a myopia of 4D. and V=20/40.

On the 3d of May he came to the office for a more careful examination. The fact of his myopia was confirmed. His right (good) eye was hyperopic (1 D.), the left, the injured one, with — 5 D., V=20/20, and although the eye was still under atropine, his near point was at 4″. On May 5th, his condition was unchanged. The ophthalmoscope showed only a small hemorrhage, as first seen. On Wednesday, May 9th, he noticed, after feeling some symptoms of irritation in the eye, that a clock in the office in which he was employed, and which he formerly could only see with the good eye at the distance at which he stood, 30′, he was now able to see distinctly with the bad one.

The final examination of this patient's eye, made on May 13th, showed that the pupil was still slightly dilated. There was

a slight corneal opacity at the outer margin. The ophthalmoscopic appearances were normal, except for a small remnant of the hemorrhage from the vein still noticeable. Vision was now 20/20, and with + 1 D., it was 20/15. His near point, although the pupil was still under atropine, same as the right eye, in which there was also a hypermetropia of 1 D.

In the great majority of cases, according to Gruening (Chapter on Wounds and Injuries of the Eyeball and its Appendages*) the principal etiological factor which causes traumatic cataract in contusion of the eye, is the laceration of the lens capsule. The flattening of the cornea at the moment of injury, the coincident increase in the circumference of the ciliary ring, producing sudden, forcible tension of the zonule at its attachment to the lens capsule, probably constitutes the mechanism of rupture.

A. Lenz,† however, thinks that the momentary compression of the lens in its antero-posterior direction, followed by an increase of intracapsular pressure, causes the rupture of the capsule.

Opacity of the lens, without rupture of the capsule, if it occurs at all, is less frequent.

I have quoted these views, as to the cause of traumatic cataract, in simple contusions of the eye, because it seems to me we may deduce therefrom an explanation of the occurrence of the temporary myopia observed in my case. The anterior chamber seemed, at the first examination, to be shallow, as though there had been a flattening of the cornea at the time of the injury. In the same way that momentary compression of the lens, in its antero-posterior diameter, — not sufficient, however, to produce a rupture of its capsule — and thus cause cataract, but by swelling, produced increase in its antero-posterior diameter sufficient to cause the temporary myopia, which disappeared when the swelling subsided under the influence of atropine, rest in bed, and a pressure bandage.

We have omitted, in our attempt to explain the appearance of myopia, any reference to dislocation of the lens, as there were no evidences of such a condition. At the same time, it is to be

* "System of Diseases of the Eye," Norris and Oliver.

† Hirschberg, Centralblatt für Praktische Augenheilkunde, 1887. S. 15.

borne in mind that the zonule is elastic, and when gradually stretched, will allow of an axial displacement of the lens, of several millimeters. So here again, may have been a possible explanation of the myopia. At all events, such are the explanations which I offer as sufficiently plausible, and I should be glad to hear in discussion, the opinion of others. The changes observed in the retina, as well as the hemorrhage, were plainly due to a contusion, as shown by the transitory disturbance of vision and the restoration to its normal acuity.

107 Madison Avenue,
New York.

A STUDY OF THE NATIVITY, SEX AND AGE, OCCUPATION, AND SOCIAL CONDITION OF THREE THOUSAND FOUR HUNDRED AND THIRTY-SIX CASES OF SENILE CATARACT OPERATED UPON AT THE WILLS' HOSPITAL IN PHILADELPHIA.

BY CHARLES A. OLIVER, A.M., M.D.,
PHILADELPHIA, PA.

The results given in this communication are based upon the findings which have been obtained in an extended study of three thousand four hundred and thirty-six cases of so-called ordinary mature senile cataract operated upon by different methods of extraction by the various members of the Attending Staff of Wills' Hospital in Philadelphia, during the past thirty-five years.

All of the records of the cases from which the data have been obtained, have been personally searched by the writer and four of his immediate assistants,[1] during a period of several months' time.

Lenticular disturbances of both primary and secondary types from coarse traumatism, and gross associated and causative local

[1] Drs. Albert J. Britt, I. Louise Haverstick, Mary H. Thompson, and Miss Gulielma F. Alsop, to whom thanks are here given for their generous help in the research work.

and general disease, have been excluded from the lists; while secondary cataract (not infrequently found as the result of imperfect and faulty operative methods) has not been used. The cases employed have been limited as far as possible, to those in which the usual clinical appearances of so-called senile cataract have not been complicated by any other demonstrable expressions of cause and effect than those which are significant of the gradual retrograde changes of more or less active life denominated as senility: a mere local condition representative of one of the usual degeneration signs of "wear" (and necessarily "tear") of tissue: a true senile metamorphosis.

Throughout the search among the original records, — which fortunately have been made by some of the most competent and best known ophthalmic observers in the country — due consideration has been given to avoid anything which might be considered in the least as uncertain. Thus separated from nearly twenty-eight hundred additional cases of congenital, and acquired complicated and gross secondary forms of lenticular disturbance (aggregating, as shown by the annual reports of the hospital — to more than six thousand cases which have been operated upon in the institution during that period of time,[1] and confined to a minimum time-limit of forty years for each subject, an age limit, which, as proved by a personal careful revisional study of the entire series of cases here given, made for both forty-five years and fifty years as the youngest age, has not practically altered the results herewith offered in any other way than to add respectively some one and three years to the average findings).

In order that the results here given might not be considered uncertain through preconception, the compilation of the variously related tables, which in some instances assumed vast proportions, were relegated to special ophthalmic assistants who had been

[1] A carefully made study of the entire number of cases operated upon at the hospital during the years named in this paper, shows that the proportion of the operations to the total number of new cases seen, was about one to four (77,378 operations upon 318,924 patients), and that the proportion of all cataracts operated upon to the total number of operations, was about one to twelve (6,190 cataract operations).

trained for particular types of work by the writer — so that in no manner was there any accidental or intentional collusion: this done, all of the obtained data were retabulated into briefer and less complex forms by the writer, and the findings were arranged logically into a series of, at first, self-evident resultants, which, in order to avoid the getting of much useless time-consuming and undue space-taking detail in such a communication as this, are here expressed in the briefest way.

(1) Nativity: As might be expected from the generally known and historically well understood several great influxes of foreign national element (particularly the Welsh, the English, the German, the Irish, the Italian, the Austrian, and the Russian — in the order here given) into this part of the United States of America, nativity has exerted a marked influence upon the obtained results. To such a degree has this affected the entire question, that it has been found necessary to separate all of the cases into two great groupings — the foreign and the native born, — each of which has been subdivided into country and state.

Primarily, and based upon sufficiently broad evidences in every class that has been used, it has been found: that there were fifteen hundred and thirty-five foreign born cases, and nineteen hundred and one native born ones: a rough ratio of three (+) cases to four (—) cases. Of the foreign born groupings, Ireland furnished the greatest number throughout the three and a half decades; actually rising to some fifty-five per cent.: this was closely followed by Germany with thirty some per cent., England with ten per cent., and Wales and Scotland with three and two per cents., respectively.[1]

Among the native born, Pennsylvania, with its preponderant sixty-five per cent., naturally gave a long lead; followed by fifteen per cent. for New Jersey; ten per cent. for Delaware, and five

[1] The representatives of other nations found in the lists, such as from Belgium, Finland, France, Holland, Sweden, and the West Indies, were comparatively so few (some eighty cases), as to be considered practically worthless for accurate statistical work; so too with the races, — which question, however, will receive consideration in a later paper bearing upon a similar subject.

with a remarkable jump to 73 years as the final for the latter. All the representatives of the other nations, among whom there was sufficient material for proper averaging, showed a decided betterment in the ratios that were obtained.

(3) Occupation: It was soon realized that as occupation among the male subject played such an important part in regard to the maturity, and even causation of the cataractous condition, it was necessary to divide the patient's vocations into four classes: (a), the unskilled laborer with his comparatively unused-for-near-work eyes; (b), the skilled workman, whose eyes are incessantly exposed to bright glares of light and high temperatures of heat; (c), the high grade artisan, who requires accurate eyesight for proper manipulative procedures; and (d), the brain-worker, whose entire time is sedentarily occupied with efforts at close vision.[1]

The first great class (a), composed principally of out-of-door laborers, such as boatmen, drivers, farmers, hostlers, miners, porters, stevedores, and watchmen, although by far the greatest in number, gave the highest operative age average — sixty-six years — throughout the entire three and a half decades; the average practically remaining the same.

The second class (b), made up of blacksmiths, glass blowers, puddlers, and other workers in superheated materials, gave by far the lowest age for the operative procedure[2] (fifty-eight years).

The third class (c), composed of those in such employments as book-binders, compositors, edge-tool makers, engravers, jewelers, shoemakers (particularly), and tailors, showed the lenticular condition fit for removal at an average age of sixty-three years.

The fourth class (d), made up of those in avocations such as agents, clerks, and professional men, most probably, by reason of

1 A large proportion of the men, 347 cases (about 16 per cent.), and 445 cases (about 33 per cent.) of the women, had passed their lives of usefulness, and their occupation had to be regarded as "nil."

2 It is interesting in this connection, as long known by the writer, and elsewhere noted by him, that the eye which is the one that is usually directed towards the heated mass is the one which is generally the only one, or the first one which is affected: this type of cases — a pure occupation one — appears very early in life.

better hygiene, etc., gave a very high operative age (sixty-five years), as the average.

In regard to the women, there were but few active ones who were registered otherwise than housekeepers; this no doubt was owing to the fact of the limitation of means of livelihood for women which was existent at the time of the early life of the subjects in question.[1] The average operative age for the women, without regard to nationality, was, as has been elsewhere alluded to, about sixty-three years; this time ratio being somewhat earlier among the foreign born cases.

(4) Social Condition: Commencing with foreign born married men as the highest at about thirty-three per cent. of the nineteen hundred and eighty-four males (with a slight difference in favor of the native born — thirty-one per cent.), the foreign born widowers fell to twelve per cent., and the native born widowers to thirteen per cent. Of the single men, six per cent. were natives, and five per cent. were foreigners. The women, on the contrary, gave their greatest showing of twenty-seven per cent. for native born widows, and twenty-four per cent. for native married women; with twenty-two per cent. for foreign born widows, and nine per cent. for foreign born married women. The ratio for single women, though the same in favor of the foreign born, gave the degree of per cent. lower — respectively five and three.

As might be expected from the ordinary course of things, some sixty-five per cent. of the male cases were married, thirty per cent. had been married, and the few remaining five per cent. were single. Fifty per cent. of the female cases were widows, forty per cent. were married, and ten per cent. were single. These results, as is well known in other similar statistical work, showed a slight disproportion in favor of the married male and the widowed female.

[1] It will be instructive to recompare, and in fact, contrast, this work with a similar one made after a lapse of another third of a century. Particularly is this so in reference to the part bearing upon the occupations of women.

PATHOLOGICAL REPORT ON DR. MAY'S CASE OF MICROPHTHALMOS WITH UPPER LID CYST.

BY WARD A. HOLDEN, M.D.,
NEW YORK CITY.

There was a small eyeball without coloboma of the iris and with a cataractous lens. From a point on its upper surface, just behind the equator, issued a narrow stalk which expanded into a large tumor lying behind the upper lid (Figs. 1 and 2). This tumor was removed by Dr. May from the patient, a boy of six months, and since then the eyeball has grown until a year after the operation it is nearly normal in size. Lower lid tumors are common enough, but the upper lid tumors have been seen only a few times. (Purtscher, Snell, Parsons.)

Development.—Evidently a knuckle of the secondary optic vesicle forced its way upward into the overlying mesoblast and continuing to develop in extent formed a mass of folded rudimentary retina which is surrounded by a fibrous sheath continuous with the sclera. The stalk is a tube of retina with a narrow lumen connecting the cleft-like cavities of the tumor with the vitreous chamber of the eyeball (Fig. 3). The lumen surface corresponds to the inner surface of the retina within the eye. The stalk is surrounded by a layer of pigment continuous with the pigment epithelium and is enclosed in a fibrous sheath continuous with the sclera.

On passing from the stalk into the tumor proper the relations of retina, pigment epithelium and outer fibrous coat are modified. There has been an invagination and folding up of the retina, so that what corresponds to the outer surface of the retina lines many of the clefts in the tumor as if it were the inner surface of the retina (Fig. 4). The pigment epithelium surrounding the outer surface of the retina has mostly

FIG. 1. Head of the child, with the cyst in the left upper lid.

FIG. 2. Upper-lid cyst. Natural size.

FIG. 3. The pedicle of the tumor, showing proliferating large cells at various points on its outer surface and numerous rosettes near these points ; Nissl stain.

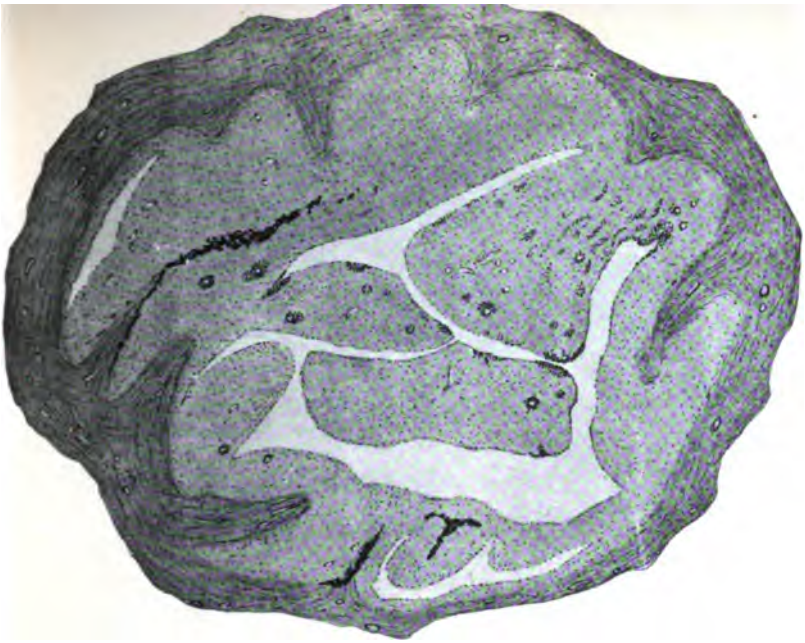

FIG. 4. A section through the middle of the tumor. The outer portion connective tissue, the inner rudimentary retina.

FIG. 5. Large cells growing inward from the outer surface of the retina to form a rosette.

disappeared, and the fibrous coat and the retina pass one into the other without any line of demarcation.

But where a fold in the retina has allowed the fibrous sheath to pass into the central portion of the tumor, pigment epithelium has in several places been carried in also; and it now lies in an anomalous position as regards the retina.

The rudimentary retina in this case is composed simply of a network of glia fibres and scattered nuclei, enclosing numbers of ganglion cells, large and small. There is no division into layers and there are no distinct outer and inner limiting membranes.

The feature of this case to which I wish to call attention is the presence of numbers of the rosette formations which are found in some gliomas and in some retinæ of arrested development, which were considered neuro-epithelial formations analogous to the rods and cones by Flexner and by Wintersteiner, who first independently described them. Since then Ginsberg, Brown, Pusey, and Verhoeff, among others, have studied these rosette formations. There has been considerable discussion as to the nature of their component cells. Their genesis and development are well shown in this case. Here the primitive neuro-epithelial cells which compose the inner layer of the secondary optic vesicle, have become differentiated into spongioblasts and neuroblasts which, attaining their full development, have formed on the one hand glia cells and fibres, and on the other ganglion cells. Of these elements, jumbled together without definite arrangement, this rudimentary retina is chiefly made up. But here and there along the margins of the retina are single cells, or groups of cells, with large nuclei and large bodies which are to be considered embryonic retinal cells which have not yet developed. Now at various points on the outer surface of the retina these cells have proliferated, and assuming a spindle form, have pushed perpendicularly into the retina like ependyma cells and then have formed what in sections appear as spirals or as circles with a fine basal membrane through which the large basal cells

send filaments into the cavity (Figs. 5 & 6). Rows of smaller cells, gradually assuming the characteristics of ordinary glia cells surround the large basal cells and the rosette is formed. The larger cells push into the neuroglia tissue without being directly connected with it, but the smaller peripheral cells in the rosettes send their processes out into the neuroglia with which they are in intimate connection.

The principal cells in these rosettes are seen to develop atypically from embryonic cells which in their natural course would become rods and cones.

DISCUSSION.

DR. F. H. VERHOEFF.— The view which Dr. Holden attributes to me regarding the nature of the rosettes in glioma retinae, is contrary to that expressed in my papers on the subject. I have brought forward evidence which I believe to be conclusive, that these structures correspond to embryonic rods and cones as first maintained by Flexner. However, I do not think that the tumors themselves are properly spoken of as neuro-epitheliomata, because the rosettes form such a small part of them and are often altogether absent. The tumors never contain differentiated neuroglia. I have also brought forward evidence to show that the tumors are composed chiefly of cells which correspond to those in the internal nuclear layer of the retina. The observations of Dr. Brown Pusey, as I have already pointed out, are not valid because he was clearly not dealing with a tumor at all, but with one of the cases of old metastatic ophthalmitis.

CONCERNING SIDEROSIS BULBI.

BY CHARLES J. KIPP, M.D.,
NEWARK, N. J.

The fact that eyes harboring fragments of iron do sometimes after a varying length of time show discoloration of the iris, a brownish staining of the cornea, yellowish brown dots arranged

in the form of a wreath under the capsule of the lens, brownish staining of the lens and cataract, has been known for a long time. V. Graefe (1) seems to have been the first to call attention to the yellowish brown spots in or under the anterior capsule of the lens in an eye, which, according to the history of the case, had been struck by a fragment of a gun cap. The eye was enucleated and on examination a splinter of metal was found in its interior. Since then Leber (2), Samelsohn (3), Landmann (4), Voscius (5), E. v. Hippel (6), Eisenberg (7), Natanson (15), Barkan (16), and others have reported cases in which these rust spots were present, and in which fragments of iron were found in the eye.

The appropriate term siderosis bulbi seems to have been first used by Bunge (8) in a paper giving his views as to the manner in which iron was disseminated in the eye. Leber holds the view that the iron is dissolved by the carbonic acid of the tissue, the solution in this form of bicarbonate of iron is diffused through the tissue, and precipitated by the oxygen of the arteries in an insoluble form.

The most complete anatomical examination of cases of siderosis bulbi has been made by E. v. Hippel; Bunge and Bednarski (9) have also examined a number of eyes with siderosis of xenogenic origin.

My own interest in the subject was aroused by cases which I saw long before the sideroscope was invented and the Roentgen ray was made available for the location of foreign bodies in the eye. Since then I have been constantly on the lookout for such cases and it has been my fortune to see a good many of them.

I have seen a number of cases on which the cornea was stained brownish for some distance around a fragment of iron which has been lodged in it for weeks, but I have never seen staining of this membrane from iron located in the lens or deeper in the eye. Bunge has reported two cases of siderosis corneæ. The fragment of iron was situated in the nasal ora serrata. Hirschberg (10) saw 2½ years after a fragment of iron had entered the eye, a deposit of yellow dots on the posterior surface of the cornea. Praun (11) has reported a case in which a large splinter of

iron had remained for a year in the center of the cornea causing a ring of rust-brown color 2 mm. in diameter which was surrounded by a somewhat lighter ring of 5 mm. in diameter.

The change in the color of the iris mentioned by other observers I have seen only in cases in which the yellowish brown dots arranged in the form of a wreath under the anterior capsules of the lens, were present at the same time. I have seen both a yellowish brown and a greenish yellow discoloration, but the first most frequently. The eyes showing this discoloration of the iris had in all my cases harbored the fragment of iron more than six months. I might say right here that in all of the cases on which these remarks are founded the fragment of iron was either extracted by means of the magnet or the iron was found in the enucleated eyeball. The discoloration of the iris due to xenogenous siderosis has been seen to disappear again and the original color restored after the removal of the iron (Hirschberg, 12), and even in cases in which the iron remained in the eye (Vossius, 13). In my own cases the discoloration remained in all cases after the extraction of the iron as long as they were under observation. It is well known that a similar discoloration of the iris follows extensive hemorrhage in the vitreous and sometimes in the anterior chamber, and so far as I have been able to discover there is no difference whatever in the discoloration caused by either. Hirschberg thinks that the discoloration due to iron in the eye is permanent, while that caused by hemorrhage may disappear.

The change which I regard as of greatest practical importance, is the appearance of the yellowish brown spots under the capsule, to which already repeated reference has been made. Anyone who has seen them once will always recognize them thereafter. These spots are of a round form, less than ½ a mm. in diameter, are of a yellowish brown color, and appear at regular intervals of about a mm. or two, in a circle, in or under the capsule of the lens, about midway between the anterior pole and equator of the lens. In addition to these spots there often also are spots on the anterior capsule, also of a yellowish brown color but situated much nearer to the anterior pole,— the remains of broken posterior synechiæ.

The spots behind the capsule are only seen after nearly ad maximum dilatation of the pupil. I have seen these spots repeatedly in eyes in which the lens was still transparent and in which the capsule had not been ruptured. In all the cases in which they were present the fragment of iron was found back of the lens. In former years, before we had the sideroscope I have repeatedly cut open the eye and extracted the fragments of iron by means of the small electro-magnet, on no other evidence of the presence of iron in the eye, than the spots here described. Even now I should not hesitate to proceed to operate, if both the Roentgen ray picture and the sideroscope failed to reveal the presence of iron in the eye, and the spots here described together with the discoloration of the iris were present.

The lenses in which these spots are seen are in most cases opaque as in the following case.

Case 1. F. D., 30 years of age, was seen by me for the first time February 2, 1906. He came to have a cataract removed from left eye. I learned from him that two years ago he was struck on the left eye by a piece of iron, that he did not think that the iron penetrated the eye, as he had but little pain at the time, and his vision remained good for some time after the injury. He did not consult a surgeon about the injury as he considered it trifling. About six months after the injury his left eye became suddenly much inflamed; it was very red and somewhat painful and a few days later he noticed that the eye was practically blind. The inflammation gradually passed away, but the vision has not improved. The examination showed the right eye to be perfectly normal in every respect. With a — 0.5 D. glass the vision was 6/5. The *left eye* was free from injection; the cornea was perfectly clear, no scar was visible in it or in the sclera; the anterior chamber was very shallow, the iris was discolored brownish (the iris of the other eye was blue). The pupil was of medium size and active; the lens was opaque and on its anterior capsule in its pupillary area were three dark brownish spots of irregular form. The pupil dilated readily ad maximum after the instillation of a one per cent. solution of sulphate of atropin. At the margin of

the dilated pupil was now seen a wreath of yellowish brown round spots, each about 0.5 mm. in diameter. They were arranged at regular intervals of about 1.5 mm. and formed a complete ring. They were apparently situated in or under the capsule. The eye had perception of light only. From the appearance of the eye, I felt confident that it harbored a fragment of iron and advised the patient to go to the hospital, where I would try to remove the fragment with the electro-magnet. This attempt was made on March 27, 1906, after the sideroscope had confirmed my suspicion of the presence of iron in the eye. It failed, however, to indicate the part of the eye in which the fragment was located. The eye was placed before the pole of the large, or giant, electro-magnet and kept there till the magnet got so hot that it was thought best to cut off the current for fear of destroying the apparatus. The magnet produced neither pain in the eye nor any change whatever in the appearance of the eye. Several other attempts lasting as long as the first one were made on the next day, but all with the same result. Although the eye was free from all symptoms of irritation, the patient fearing that the other eye would become sympathetically affected, I consented to enucleate the eye and did this under local anæsthesia on the following day. The wound healed in a few days and he was discharged on the sixth day after the operation.

Immediately after the enucleation I opened the eye and found the following condition: The iris was almost in contact with the cornea. The lens was much swollen and opaque and pushed the iris forward. The vitreous chamber was filled with a watery fluid. Of the vitreous body only a small quantity remained; it was condensed and extended from the ciliary process in the form of a strand to the retina between the equator and the posterior pole in the temporal half; at this point was found a large foreign body, partly black, partly of color of iron rust and covered with a thick whitish membrane. On looking more closely at the beginning of the condensed remains of the vitreous body it was found to be adherent to the orbiculus ciliaris on the temporal side, where a long slit or opening in this structure could be distinctly seen. It

was evidently at this point where the foreign body had entered and that the strand of vitreous represented the track of the iron. The foreign body was 7 to 8 mm. in length, about 4 mm. in width, and 2 to 3 mm. in thickness. The major part was lying on the retina, but its inner end had penetrated the retina, the choroid and the sclera. The end of it was very sharp pointed and could be seen and felt on the outside of the sclera. The retina was evidently thickened throughout and of decidedly brownish color, the retinal vessels were unusually distinct and of an almost black hue. The papilla was flat but also brownish in color. Over the entire retina were strewn innumerable very minute elevations also of a dark color; they looked like very fine sand. I do not think that the retina was detached in any part when the globe was opened, but shortly after it had been placed in a solution of 3% formalin, I noticed several folds in it near the foreign body. I removed a part of the retina and placed it in a solution of ferro cyanide of potassium (2%) and afterwards in weak hydrochloric acid. This treatment changed its color from brownish to a beautiful blue. Under a low power, the surface of the retina was found to be covered with dark blue minute elevations which were especially abundant on the sides of the vessels, which also were of a blue color. The eye was then put in a 3% solution of formalin. I may here mention that to convince myself that the foreign body was iron, I held the bottle containing the globe with the foreign body in it, at some distance from the pole of the large Haab electro magnet and that before one side of the bottle came in contact with the magnet, the eye, which was at the other side of the bottle measuring about 3 inches across, began to move toward the pole of the magnet and in a few seconds had reached the other side of the bottle. Later I held the globe itself with the cornea in front against the pole of the magnet for many minutes without producing the slightest movement in the foreign body. I submitted the globe for further micro-chemical examination to Dr. Dixon, whose report is as follows:

My Dear Dr. Kipp: — As you know, the eye was exceed-

ingly brown, — a shade not attributable to the presence of ordinary pigment, nor yet *ordinary* siderosis, hence I felt that the iron reaction should be very marked; but ordinarily applied it was not.

I send you four slides. The two stained after Van Giesen show the corneal epithelium intact; Bowman's membrane poorly marked; circumcorneal injection; a few wandering cells in the cornea propria; Descemet's membrane intact, and Schlemm's canal open.

The iris is rather densely pigmented, vessel walls somewhat thick, but otherwise normal.

The lens is in a condition of Morgagnian cataract well advanced, with pigment deposits under the anterior capsule.

The ciliary processes and body in good condition, but the choroid atrophied.

The retina is somewhat degenerated and the inner layers beginning with the external reticular layer loaded with pigment principally granular in character, particularly in the vicinity of the vessels, but a few chromatophores are to be seen.

The nerve and sclera appear to be normal, except that the latter presents collections of pigment in a few of the lymph spaces.

The other two sections are stained after Perl's method for iron reaction, — Berlin blue. You will notice that one is very blue, and the other is a yellowish green. The first owes its color to prolonged action of the reagent, the other to the usual length of time. In the first specimen the iron appears to have been dissolved out and then reabsorbed, thus diffusely staining the entire section. The other was not allowed to remain in the reagent sufficiently long to set free so much Berlin blue, and hence is of a yellowish green color.

In these Berlin blue specimens you will find particles of iron somewhat diffusely located, no particular set of cells appearing to be implicated in the dissemination of the iron; for instance the particles will be found in the lens substance and about the capsule, in the iris stroma, the cornea propria, in the retina,

and the nerve, but not to the extent that would be anticipated from the brown discoloration of the different parts of the globe.

This dusky brown color appears to be due more to the deposit of hæmosiderin than true siderosis. You will observe that some of the new formed retinal pigment reacts as iron, and some does not, which corresponds with the change which would be expected to take place in deposits of hæmosiderin, — that is, after a time it is likely to fail to respond to tests for iron, — further that it is principally granular, is in and about the blood vessels, is of a color entirely different from the neighboring autochthonous pigment and is of the same character as the pigment under the anterior capsule of the lens.

I would further call attention to the fact that the greater part of the Berlin blue will be found on the surface of the specimens, showing that it has been washed out in considerable quantities and evidently came from the adventitious retinal pigment.

Very respectfully,

GEO. H. DIXON.

June 18, 1906.

But as I have already stated I have seen the wreath of yellowish brown spots also in a few cases before the lens became cataractous, as the following cases show.

Case No. II. J. C., 27 years of age, consulted me for first time January 10th. He stated that about a year ago his left eye was struck by a piece of steel and that under treatment the eye had healed and had given him no trouble since. He came now because he had a severe pain over this eye. I found that the left eye was free from evidences of inflammation. The cornea was clear: the anterior chamber of normal dimensions; the aqueous was clear. The iris was discolored yellowish brown (the other iris was brown); the media perfectly clear. The optic papilla was very red. No disease of retina or choroid. No scar was visible outside or inside the eye. I have no notes

of the vision of this eye at this time and I did not dilate the pupil. Under quinin the pain passed away in a few days.

The other eye was perfectly normal.

The patient was not seen again till August 10th, six months after his first visit. He told me that since his visit to me, he had had many attacks of inflammation in the left eye for which he had been treated by well known ophthalmologists in another city. One of them had told him that he had a foreign body in his eye while others equally experienced had advised him against enucleation which the others had proposed. The eye was now blind. There was severe iritis, many posterior synechiae which were mostly broken up by instillation of atropin. In or under the anterior capsule was a wreath of yellowish brown small dots, placed at regular intervals on a line with the dilated pupil. The lens was clear. The vitreous opaque. No red reflex could be obtained. On the strength of the rust spots in the capsule, the discoloration of the iris and the condition of the vitreous together with the history of the case, I diagnosed the presence of a fragment of iron in the vitreous chamber or in the membranes of the eye and asked the patient to let me try to extract it with the small electro-magnet. His consent having been given I made an incision through the coats of the eye, between the insertion of the tendons of the external rectus and inferior rectus muscles, and then introduced the tip of the magnet about 5 mm. in the vitreous chamber. I felt the well known click at once and on withdrawing the magnet found the fragment of iron hanging to it. The fragment measured about 3 mm. in length and was very slender. The operation was not followed by any marked reaction. Later on he had an atropin conjunctivitis which subsided under sulphate of zinc solution. The eye was free from inflammation for about six months after the operation, then he had another attack of irido choroiditis. Since then I have not seen him.

Case No. III. J. B. D., 49 years of age, states that two days before he was struck on the right eye by a piece of metal. I found a linear wound about 2 mm. in length in the sclera, close

to upper margin of cornea. There was not much injection of ocular conjunctiva, the cornea was clear, the anterior chamber of normal dimensions. the aqueous clear; the iris of normal appearance; pupil active, lens clear; the vitreous was very cloudy; the optic papilla seemed normal; in the upper part of the fundus was seen a white spot a little less than a disc's diameter in size and surrounded by an extensive extravasation of blood, apparently in retina. His vision was reduced to 6/10. As the eye gave him no pain he refused to enter hospital and was not seen again for 8 months. At this second visit he told me that the injured eye had given him no pain and that vision had been good up to a month ago, when his sight failed rapidly. Last night he had much pain in the eye. The eye was now much injected around the cornea, which was clear. The iris was discolored brownish yellow (the iris of the other eye was brown); pupil was now dilated by atropin. In or under anterior capsule of lens was a wreath of small round yellowish-brown spots, at regular intervals about midway between center and periphery. The lens was clear. The vitreous was full of large floating opacities. The white spot in upper part of fundus was now surrounded by a broad ring of pigment. No foreign body could be found. S. 5/24. Two days later I made an incision through sclera, choroid and retina between insertions of tendons of external rectus and inferior rectus muscles about 10 mm. back of corneal margin, and through this opening introduced the tip of a hand electro-magnet several times to various depths, but without bringing out a foreign body. The wound healed in a few days. S. 5/24 after the operation. A month after this operation the eye was free from injection and was painless. S. 5/24. Shortly after this last visit the eye became again painful and much inflamed and vision failed very rapidly. Seven weeks after the attempt at extraction with magnet and 10 months after the receipt of the injury the eye was totally blind and as the pain was very great I enucleated the eye. An examination of the eye made immediately after the enucleation showed the presence

of a fragment of iron about 4 mm. in length and 1 mm. thick, covered by a thin membrane on lower part of ciliary body.

I have seen spots of almost the same color as those due to the presence of iron also arranged in a circle at the same place but situated on the capsule in a case of intraocular hemorrhage followed by severe irido cyclitis with hemorrhage in the anterior chamber.

Case No. IV. The case is that of a man 40 years of age who is otherwise in good health, denies having had syphilis, is of good habits and so far as I can find out is free from disease of any other organ. He came to me with the symptoms of a severe seroplastic iritis of one eye. He told me that he had consulted an oculist for failing vision of this eye a month before and that the oculist had told him that no local application was required and had prescribed potassium iodide in 10 grain doses. A week later this eye began to pain him and he was induced to place himself under the treatment of a "magnetic" physician. As no improvement followed this treatment he came to me. I found the pupils bound down by many posterior synechiae, and the aqueous very turbid. Under leeches to the temple, instillation of sulphate of atropin and cocain solution the posterior synechiae were broken up completely. The vitreous humor was found to be so opaque that the fundus could not be seen. A few days later, a clot of blood was seen in the lower part of the anterior chamber, and a few vessels entered the cornea from below. The clot was absorbed in a few days, but an opacity of the size of a pea has developed in the cornea adjoining lower margin; in this area of opacity are several small dots of denser opacity. Used dionin solution (10%) once daily in addition to atropin. The globe is now white, but many fine precipitates are now seen on Descemet's membrane, especially in lower half. During the following two weeks, the deposit on Descemet's membrane became more dense and was seen in all but the uppermost quarter of the cornea. The pupil is widely dilated and he is entirely free from pain. Two and a half months after his first

visit to me he had a relapse of the acute symptoms with another somewhat larger hemorrhage in the anterior chamber. He recovered from this attack in the course of two weeks. There is now in the lower part of the cornea, a dense opacity of a somewhat pyramidal shape, base downwards, evidently on Descemet's membrane; there are also a few discrete spots all over other parts of Descemet's membrane. The aqueous is perfectly clear. There is now a wreath of yellowish-brown spots, at regular intervals, on the anterior capsule. They are of the size and color seen in eyes containing iron, but are somewhat irregular in outline, not perfectly round. They are connected by a thin, thread-like opacity. Their situation is on a plane corresponding to the edge of a pupil of medium size. The pupil is now so widely dilated that a ring of not more than 2 mm. in width of the iris is visible. There are other spots of a darker color near the center, the remains of the posterior synechiae. The vitreous is still so opaque that no details of fundus can be made out.

The patient is a merchant, has never, so far as he knows, been anywhere where particles of iron were flying about, and it is seen that this eye has never sustained an accidental injury. I think we safely assume that a hemorrhage in the vitreous body is accountable for its dense opacity.

From this case it is apparent that only on very close examination a differential diagnosis can be made.

These spots under the capsule were found only in connection with cataracts in all the recorded cases. Hirschberg says, however, that he has seen them in lenses the capsules of which had not been broken, and E. v. Hippel (14), who in previous papers stated that he had never seen them in other than cataractous lenses, in his last statement on this subject admits that they are also found in clear lenses. He says, moreover, that he has never seen them except in eyes containing fragments of iron.

Among other symptoms of siderosis bulbi, Hirschberg (10) mentions the ochre color of adhesions between the iris and lens capsule. I have also noticed the same, but have never attached much value to this particular color of posterior synechia.

Spontaneous mydriasis in cases of siderosis bulbi was observed in four cases out of fourteen seen by Vossius (13), and his examination of the literature of this subject has revealed a few similar cases observed by Mayweg, Wingenroth, and Hirschberg. He attributes the mydriasis to irritation of the fibres of the sympathetic nerve which supply the dilatator of the iris. Following this mydriasis after a year he has observed a miosis which would not yield to the application of atropin. Atrophy of the musculature of the iris is regarded as the cause of this condition. The mydriasis as well as the miosis must be a comparatively rare condition, as I do not remember to have seen it in any of my cases.

Spontaneous subluxation of the lens has also been observed by Vossius (13). Spontaneous resorption of the lens has been observed by both E. v. Hippel and Voscius. This I think is not a very rare event. I have seen this cataract disappear entirely, leaving only the capsule, in a number of cases, especially in young persons.

Torpor of the retina, concentric contraction of the visual field, and defective color perception have been frequently observed in cases of siderosis bulbi by the writers already referred to.

E. v. Hippel (6), who has investigated the subject of siderosis exhaustively, by examining human eyes which contained fragments of iron, and has studied the effect of iron placed in the anterior chamber and in the vitreous body of rabbits and studied the effects of injections of blood in the anterior chamber and in the vitreous of rabbits, gives the following as the result of his investigations.

I. The iron reaction with ferrocyanide of potassium and hydrochloric acid succeeds without exception even in preparations which have been kept in Müller's fluid for years, if the action of the reagent is continuous for a sufficiently long period (12-24 hours).

A subsequent diffusion of the Berlin blue does not take place either in fresh preparations which are examined in acidulated water, nor in sections which, with the avoidance of distilled water,

are enclosed in Canada balsam in the usual manner. All the pigment which gives the iron reaction may be decolorized by exposing it to the action of hydrochloric acid for 24 hours.

II. The Berlin blue reactions give exactly the same results as Quinke's method with sulphur ammonium, but it is immeasurably more effective, inasmuch as it brings out very distinctly faint colorations in preparations which normally contain pigment.

III. There exists a true siderosis bulbi which may originate in a two-fold manner, firstly direct from the foreign body (xenogenous siderosis), and secondly from the blood (haemotogenous siderosis). Siderosis consists of the deposit of oxide of iron combined with organic substance in certain cell groups.

IV. The haemotogenous siderosis is entirely independent of haemotogenous pigment; on the other hand "Haemosideria" is a haemotogenous pigment to which split off iron is adherent. The color of the same is not dependent on iron.

V. The siderosis appears predominately in specific cell groups, more particularly in the epithelium of the ciliary processes, the pars ciliaris retinae, the retina, and the epithelium of the lens capsule. The siderosis of these parts may be a xenogenous or a haemotogenous. The possibility of a genuine siderosis corneæ can not be absolutely denied, its occurrence has not, however, been positively proved. It is probable that the brownish discoloration is due to the deposit of hæmosiderin.

VI. The "xenogenous siderosis" is produced in such a way that the iron is dissolved by the carbonic acid of the tissues, the solution is diffused and becomes fixed by entering into an insoluble combination with a substance in the protoplasm and becomes gradually oxidized in cell groups which have a specific affinity for the iron. The accumulation of these cells makes micro-chemical authentication possible (distant effect or indirect siderosis). The great concentration of the solution in the immediate neighborhood of the foreign body is the cause of the great deposition of the iron in the form of an oxide at this place. In the haemotogenous siderosis the iron becomes free in the dis-

solved state and is then subject to the same conditions as that derived from the foreign body.

VII. Neither the greenish nor the greenish-brown nor the rust-colored discoloration of the iris and the cornea enable us to say positively that a piece of iron is in the bulb, as the same discoloration may be produced by the coloring matter of the blood.

VIII. The characteristic wreath of brown spots beneath the capsule of the lens, in the presence of a foreign body in the eye, is the result of the deposition of iron in circumscript collections of proliferating epithelial cells of the capsule.

IX. The introduction of a fragment of iron in the vitreous body is followed by a high degree of degeneration of the retina (Leber). The large peculiar granular cells which are seen in this condition are derived largely from the pigment epithelium of the retina. The cells of the same have the faculty to proliferate upon certain irritations, to change their form and to actively wander.

X. Exactly the same alterations which the retina of the rabbit undergoes, may appear in the undetached retina of man.

XI. After injection of blood in the vitreous, detachment of the retina may occur (Pröbsting); in addition there appear in the retina degenerative changes which have great similarity to the degeneration in its first stage, produced by the introduction of a fragment of iron in the eye.

XII. Injection of blood in the vitreous following the evacuation of the anterior chamber may cause rupture of the lens capsule; a satisfactory explanation for this phenomenon is still wanting.

Bednarski (9), who has had the opportunity of examining eyes containing fragments of iron, could demonstrate the iron reaction of Perl, chiefly in the proliferating cells; the epithelial cells of the iris and ciliary body did not turn blue, and the epithelium of the retina showed only a partial reaction. His examination does not confirm the assertion of E. v. Hippel that

the epithelial cells of the ciliary processes, the pars ciliaris retina and the retina as a whole, have a specific affinity for iron.

The question why the rust spots under the lens capsule are almost uniformly found in the same region and of the same form, has as yet not been satisfactorily answered.

Samelsohn's (3) view that the spots represent pores in the capsule through which the fluid containing the insoluble particles of iron passes out of the capsule and on which the iron is deposited, cannot be correct, as no one has as yet seen such pores.

Another question which remains to be answered is, why do not all eyes containing fragments of iron give outward evidence of its presence? I have seen a number of eyes which had harbored a fragment of iron for more than six months, and I have very recently examined one in which according to the patient's statements, the fragment of iron had entered the globe twenty-five years before I enucleated it and found the iron imbedded in a coating and resting on the retina, which showed none of the signs of siderosis. The thickness of the coating of the iron can have nothing to do with it, as is shown by Case I. In this case a very thick layer covered the iron, while in the eye in which the iron had been lodged for twenty-five years, the coating was so thin that the iron showed through it. The dimensions of the fragment were about the same.

The length of time intervening between the entrance of the foreign body and the first appearance of outward signs of siderosis seems to vary considerably. In all of my cases the iron had entered at least six months before I saw the patient. Natanson (15) has observed signs of siderosis as early as two months after the foreign body had entered the eye.

REFERENCES.

(1) Von Graefe's Archiv, Bd. VI, 1, p. 134.
(2) Leber, Transactions of the International Medical Congress, London, 1881.
(3) Samelsohn, Zehender's Monatsblätter, 1881, p. 265.
(4) Von Graefe's Archiv, Bd. XXVIII, 2, 1882, p. 150.
(5) Vossius, Deutsche Med. Wochenschrift, 1891, No. 51, p. 1385.

(6) E. von Hippel, Von Graefe's Archiv, Bd. XL, Abteilung I, 123.
(7) Eisenberg, Inaug. Diss. Giesen, 1901, cited from Nagel's Jahresberichte, 1901, p. 680.
(8) Ueber die Siderosis bulbi. Verhandlungen des X Internationalen medicinischen Congresses, Berlin, 1890, Bd. IV, p. 151.
(9) Bednarski, Polnish, Przelad lekarski, No. 7, 8, 9, 10, quoted in Nagel's Jahresberichte, 1901, p. 190.
(10) Hirschberg, Von Graefe's Archiv, Bd. XXXVI, 3, p. 37.
(11) Praun, Die Verletzungen des Auges, 1899, p. 203.
(12) Hirschberg, Einführung in die Augenheilkunde 2te Hälfte, p. 131.
(13) Vossius, Bericht über die 29ste Versammlung der Ophthalmologischen Gesellschaft, Heidelberg, 1901.
(14) Same as 13.
(15) Natanson, A. Bericht über die 31 Versammlung der Ophthalmologischen Gesellschaft, Heidelberg, 1903.
(16) Barkan, Ophthalmic Record, 1903, p. 115.

DISCUSSION.

Dr. C. W. Cutler, New York: This specimen and chart, made most accurately by Dr. Dixon, will show the exact localization of a foreign body that remained in the eye thirty-five years. The eye was blind, but the patient states that he was practically free from any severe inflammatory symptoms for thirty-four years and refused enucleation. There must have been slight attacks of glaucoma during that time. Finally two months ago the patient developed a corneal ulcer and the eye had to be removed. There was no siderosis.

Another case that I would allude to I saw two years ago: Injury by a piece of steel which I removed through an incision in the sclera. It resisted the Haab magnet used in the ordinary way and a piece of wire was attached to the end of the magnet and inserted into the wound. Before the operation there was beginning siderosis and a good deal of iritis and afterward exudate formed in the pupil. The main point is that *after* the removal of the foreign body a more marked siderosis developed. The exudate on the anterior capsule was a yellowish-brown and the points of synechia were brown. The iris and the sclera were also discolored. Dr. Dixon made an X-ray picture with the idea that there might be a second foreign body, or remains of the original one, but nothing was found. Gradually the pupil was dilated and the inflammatory symptoms subsided, leaving a normal fundus and vitreous.

The anterior capsular cataract and points where the iris was

attached, which had been orange color, became white, and now vision is 20/100.

DR. F. H. VERHOEFF, Boston: In connection with this subject I would point out the fact that the dilator muscle of the iris has a decided tendency to take up the iron pigment, and in certain cases takes it up so abundantly that the muscle is brought out in a manner far superior to that in which it can be demonstrated by any staining method. The demonstration is still more striking if the pigment epithelium of the iris is bleached by the method of Alfieri.

A CASE OF INVAGINATION CYST OF THE CORNEA AND OF THE ANTERIOR CHAMBER.

BY CHAS. J. KIPP, M.D.,

NEWARK, N. J.

F. B., 17 years of age, was first seen by me on February 6, 1883 (twenty-two years ago). His right eye had been struck by a piece of iron same day. I found a linear wound about 6 mm. in length, in lower sclero-corneal junction a little to nasal side of vertical meridian, with prolapse of iris. The wound extended about 7 mm. in clear cornea. The anterior chamber was nearly filled with blood. The eye had good perception of light and projection was satisfactory in all directions. I abscissed the prolapse. The patient was kept in bed, cold applications were made to the eye and a 1% solution of atropin was instilled every 3 hours. Under this treatment the eye became quiet in a few days. After the blood in the anterior chamber had been absorbed it was found that the lens was becoming opaque, the opacity being chiefly at posterior pole. The patient was discharged from hospital about two weeks after admission and was not seen again till July of same year (5 months after injury). At this

visit the eye, which had been quiet up to this time, was very irritable and painful. On examination a transparent cyst was found on lower half of iris. It was about the size of a small pea. There was iritis, the pupil was very small, the lens was a little more opaque. Tn. He was ordered frequent instillations of atropin solution, and warm compresses to the eye. Under this treatment the eye soon became white and the pain subsided.

On the 22d of October he presented himself again and stated that since a few days, the eye was again red and painful. There was much ciliary injection. The cyst which had previously been found in lower part of anterior chamber had disappeared; the iris at former site of cyst was atrophic and pushed forward by a circumscribed collection of yellowish matter. The pupillary margin of the iris at this point was adherent to the lens capsule and immediately behind the bulged iris was a yellowish spot in the lens. The pupil was very small but gradually dilated after repeated instillation of a 1% solution of atropin. At this visit vision was 5/36. V. F. intact. During the following twenty-two years the eye was quiet, but vision was gradually lost entirely. He had no pain up to September, 1905, but since this time the pain has gradually increased to such an extent as to deprive him of sleep.

On September 15, 1905, I saw him again; there was intense ciliary injection. The lower half of the cornea was very hazy, the upper half clear. In the upper half the iris was in its normal plane and its pupillary margin firmly bound down to what seemed to be a remnant of the lens capsule, the whole lower half of the iris was bulged to such an extent as to bring it in contact with the posterior surface of the cornea (bombé iris), except at a place a little to the nasal side of the vertical meridian, where for a space of about 5 mm. no iris tissue was seen resting against the cornea; on either side of the vacancy, the bulging extended up to the horizontal meridian. The pupil was completely closed. As the eye was completely blind and all remedies used failed to give relief from the pain

FIG. 1.

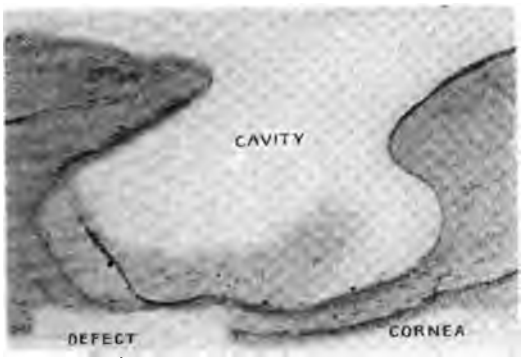

FIG. 2.

(including dionin locally and salicylate of sodium internally) I advised enucleation. The eye was removed on October 13, 1905, and seven days later he was discharged from the hospital.

ANATOMICAL EXAMINATION OF THE EYE.

After hardening in formalin an antero-posterior section was made (see Fig. 1). The examination showed a small cavity in the lower half of the cornea; this communicated with a cyst which filled the lower half of the anterior chamber. The lower half of the cornea was very hazy, and in front of the cavity in this membrane, the epithelium and Bowman's layer were wanting over a space about 2 square mm. This defect was not noticed at the time of the enucleation and is probably the result of handling the eye after hardening in formalin. Between this defect and the cavity there is remaining in some sections only a thin layer of the substantia propria. A direct continuation of the epithelium from the surface of the cornea to the cavity within it could not be seen in any section. The cavity in the cornea is small, not more than 1 mm. in diameter, and about the center of its inner wall is an opening which communicates with the cyst in the anterior chamber. (See Fig. 2.) The cavity is lined with epithelium which in appearance corresponds pretty closely to that of the cornea. In some parts the lining consists of four layers of cells, in other parts of only two to one. (See Fig. 3.) This epithelial lining is continuous with that of the cyst. The remainder of the lower half of the cornea is changed to cicatricial tissue. The upper half of the cornea is about normal in structure. The wall of the cyst in the anterior chamber is made up in front and below mostly of the atrophic iris tissue and a fibrous membrane filling the coloboma of the iris; above by atrophic iris tissue and the fibrous membrane, and behind of atrophic ciliary processes, anterior capsule of the lens and a cyclitic membrane. (See Fig. 4.) The cyst is lined throughout with the same form of epithelium as that which lines the cavity in

the cornea. Here too it is seen in parts to be composed of three and four layers of cells, in other parts only by two. (See Fig. 5.) The contents of the cyst consisted of a watery fluid.

The upper half of the iris was atrophic and behind it were found the remains of the crystalline lens, undergoing calcareous degeneration. The ciliary body in the lower half of the eye was atrophic. The choroid and retina were atrophic; the optic papilla was deeply excavated as in extreme cases of simple glaucoma.

It seems most probable that the wound in the cornea, made twenty-five years before the eye was enucleated, through which the iris prolapsed, did not close at once, although the prolapse was promptly abscissed, and that the margin of the coloboma became attached to the posterior surface of the cornea; that the epithelium of the cornea grew over the walls of the wound canal throughout its length. Subsequently the outer portion of the wound closed, while the epithelium continued to proliferate and eventually spread over the posterior surface of what remained of the lower half of the iris, the anterior capsule and the organized inflammatory tissue, uniting these with the ciliary body. Later or after filling this space, pressure upon the central walls probably caused their breaking down and liquefaction.

A somewhat similar case but without a cavity in the cornea has been described by E. T. Collins under the title, "Localized condition of bombé iris, simulating a cyst of iris," in an article entitled, " On the pathology of intra-ocular cyst," in the Royal London Ophthalmic Hospital Reports, 1903, p. 41.

Another, also without cavity in the cornea, by S. D. Risley and A. B. Randall, is reported in the Transactions of the American Ophthalmological Society, Volume V, p. 718.

DISCUSSION.

DR. S. D. RISLEY, Philadelphia.— Dr. Kipp will find a case reported by me in the Transactions of this Society of a few years back, of a cyst of the iris.

FIG. 3.

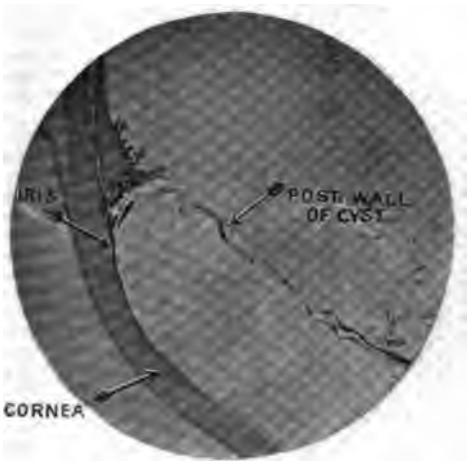

FIG. 4.

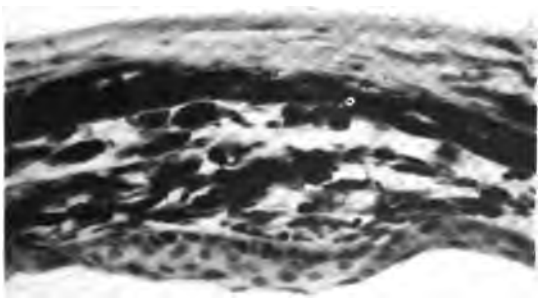

FIG. 5.

EXTRACTION OF CATARACT IN THE CAPSULE,

With Report of ten cases.

BY FREDERICK E. CHENEY, M.D.,

BOSTON, MASS.

The two papers on "Extraction of Cataract in the Capsule" by Major Henry Smith of India, the first published in the British Medical Journal of September 26, 1903, and the second in the last number of the Archives of Ophthalmology for 1905, have naturally and deservedly attracted more than ordinary attention. That one man should have operated on 2,767 cases of cataract in a year is in itself a matter of interest. That of 2,616 cases selected for removal in capsule, the capsule was unruptured in 2,494; that vitreous was lost in but 6.8%, in spite of the fact that 75 cases of lenses previously couched, were included in these statistics; that iritis occurred but twice in the 2,494 cases where the lens was delivered entire (capsule unruptured); and that 99.27% of this long series (2,616) were first-class results, is nearly as difficult to sense and comprehend as space and eternity. It cannot be doubted that a man must acquire an extraordinary and exceptional skill who averages more than seven cataract extractions a day for every day in the year, and an opportunity for such an experience is not, of course, to be looked for by the American or European oculist. I am probably one of many in this country who have extracted a few cataracts in capsule during the last year or two. Although I have but ten cases to report, the careful recording of even a limited number by various operators, and the expression of opinion favorable or unfavorable to the operation, should soon determine whether or no this operation is generally applicable to cases in this country,

if it is desirable in a few selected cases, or if it should be discarded altogether.

Major Smith's papers are so recent that a general review is unnecessary. I will, however, quote the technique of his operation in order that my variation from it may be noted. After deciding that the case is suitable for extraction in the capsule, he says:

"I make a liberal-sized upper incision, inserting the knife at the sclero-corneal junction, just as deep as anatomy and experience teach us will avoid wounding the dangerous area, and cut out in the cornea with a sweep half-way between a normal pupil and the sclero-corneal junction. I then take out the speculum, and my assistant hooks up the upper eyelid on an ordinary large-sized strabismus hook, and draws down the lower lid by placing the ball of his thumb on the skin of the face, close to the lower eyelid. He lifts the upper lid well up with the strabismus hook, and relaxes his hold on neither the upper nor the lower lid until the operation is finished. It is important that he should lift the upper lid well up and retain the lower one so well down that the orbicularis muscle cannot be brought into action by the patient until the operation is finished. The importance of a thoroughly competent and reliable assistant in this matter cannot be overestimated. Assuming that the operator is skilled in ophthalmic manipulation, it is the free action of the orbicularis muscle in almost all cases which causes escape of vitreous. I consider it of supreme importance to impress this fact upon anyone attempting the operation. I then place the curve of a strabismus hook over the cornea, about the junction of the lower with the middle third of the lens, and a spoon just above the upper lip of the wound. I press the strabismus hook down neither toward the wound nor from it, and do not alter its position until the lens is nearly out, all the time making slow, steady, and uninterrupted pressure and counterpressure. When the lens is more that half-way out, I, while keeping up the tension with the spoon in its original position, shift the strabismus hook forward and gently tilt the lens by getting the edge of it in the concavity of the strabismus hook. If this latter manoeuvre be done with the spoon, or other comparatively sharp instrument, or with the slightest roughness or jerk, the capsule will give way and allow the body of the lens to escape,

and, if the operator be not dextrous, will itself retract with some contained lens matter, and, being in part dislocated, will give trouble in its removal."

My principal variations from the foregoing procedure are: 1st. In not removing my speculum until the operation is completed. If a speculum is properly placed, it is exceptional, in my experience, to have a serious contraction of the orbicularis, and in no one of the three cases in which vitreous was lost was the speculum or contraction of the lids accountable for it.

2d. In two eyes, as a result of pressure with the strabismus hook, the epithelial layer of the cornea became bruised over the area of contact and a temporary swelling and haze was the result. This is probably accounted for by the fact that our hooks are flattened from side to side on the curve, so that the convexity is not well rounded. To obviate this, I selected a narrow, dull-edged spatula, and bent it so that it corresponded in curve to the strabismus hook. There was no epithelial haze in the cases where this was used.

3d. My cut in some cases was not completed as far forward as suggested by Major Smith.

So far as I can judge, these variations in no way influenced the results.

CASE I. S. D., female, aet. 72. Cataract mature o. d., failure of vision two years. Functions normal; anterior chamber of good depth. This case was operated upon April 4th, 1904, not long after I had read a review of Major Smith's first paper. The extraction was a simple one, and there was a moderate loss of vitreous. The records of the case are not complete, but I remember the case well and I am confident that there was no rupture of the capsule. The anterior chamber was re-established two days later. April 11th the pupil was recorded as round, central and slightly dilated. April 16th. The eye was white and quiet, the pupil clear, and there were some floating opacities in the vitreous. April 21st.

At the time of discharge, 17 days after the operation, the vision $\overline{c} + .75 \supset + 3$ cyl. axis $175^\circ = 20/40$.

CASE II. W. C., male, aet. 75, cataract mature o. d. Vision has failed gradually for a number of years. Functions normal; anterior chamber of good depth, iris very slightly tremulous, January 25, 1906, extraction with iridectomy. The cut was one of good size and completed not far in front of upper corneal border. The lens was delivered in capsule after about one minute's pressure with strabismus hook. No vitreous escaped or presented in wound; no indication of fluid vitreous. The eye made a perfect recovery, and the vision, February 8th, $\overline{c} + 8 \supset + 3$ cyl. axis $0^\circ = 20/20 +$. There were a few floating opacities in the vitreous, and a very delicate, slightly tremulous membrane noticed in the position usually occupied by the posterior capsule, or perhaps a little further back.

CASE III. C. W. M., male, aet. 71. Cataract mature o. u. Vision of the right eye began to fail three years ago and he has been unable to see objects for a year. Functions normal, anterior chamber of good depth, no lachrymal trouble. In the left eye, the one not operated upon, there was a slight drop of muco-pus expressed from the sac at one examination, but no further trouble was noted after the use of a 25% solution of argyrol for three days. April 5th, extraction o. d. with iridectomy. The incision was of good size and completed a little in front of the upper corneal border. The lens was removed in capsule after about two minutes' pressure. There was no escape of vitreous or even presentation of vitreous in the corneal wound. In every respect the operation was satisfactory. At the first dressing, on the following day, a slight superficial haze of the cornea was noted where pressure had been applied with the strabismus hook, but it disappeared after a few days. The anterior chamber was not re-established until the sixth day. The eye had been white and quiet until this date (April 11th) when a conjunctivitis of moderate severity developed and continued for about two weeks. The

edges of the corneal wound had never been in good apposition and there was at times a stringy mucous collection adherent to the wound. Argyrol was used constantly and there was no infection of the cornea. April 22d, when the conjunctivitis had practically subsided, a sub-acute iritis developed. At about this time, also, there was a slight separation of the corneal wound noticed along its entire length. The edges of the wound continued to separate for about twelve days. At the inner and outer angle iris-tissue was present, while the central portion was clear, suggesting in appearance a thin, transparent membrane with vitreous pressing behind it. At the end of this time cicatricial tissue began to form, the wound gradually contracted and the patient was discharged May 14th, thirty-nine days after the operation, with an irregular scar and an incarceration of the iris. The vision $\bar{0} + 9 \supset + 3$ cyl. axis 0° = 20/100 and later 20/50.

CASE IV. J. P. Mc., male, aet. 64. Cataract mature o. u. The vision in the left eye began to fail two years ago, and he has been unable to see objects for 8 months. Functions normal, anterior chamber of good depth — no lachrymal trouble. May 7th, five days after admission, extraction with iridectomy. The incision was larger than I should have made in the ordinary operation but not large enough for an easy exit of the lens, which was well sclerosed, in its capsule, but it was delivered entire after about 4 minutes' pressure with the strabismus hook. A small bead of vitreous presented when the lens was about half way out, and while my house-officer has recorded that it retracted again into the eye, I think this is a mistake and that a small amount escaped. Two days after operation the anterior chamber was re-established, but there was an epithelial haze at the point of pressure from the strabismus hook, as in the preceding case. This cleared up promptly, and the eye was almost perfectly free from injection until the 7th day, when a slight conjunctival discharge was noticed for the first time. On the following day the corneal wound was infiltrated and in spite of everything that could be done

there was a general infection and panophthalmitis. It is only fair to state that this patient's general condition was extremely poor, and the advisability of operation was considered for a number of days before it was performed.

CASE V. S. C., male, aet. 58. Cataract practically mature, o. u. Vision began to fail about 16 months ago, and he has seen very little for the last 10 months. At the time of admission, April 4th, v. o. d. = fingers at 1 foot. Functions normal, anterior chamber of good depth, iris slightly tremulous. The right eye was operated upon with an iridectomy April 7th. The incision was of good size and completed a little anterior to the sclero-corneal margin. The lens was delivered in capsule without difficulty after about one minute of moderate pressure, with the bent spatula. There was no loss of vitreous, no presentation of vitreous in the corneal wound or indication of fluid vitreous. The healing process was perfectly normal and the eye was but slightly injected from the beginning. May 25th, the vision $\bar{c} + 10 \supset + 1$ cyl. axis 15 = 20/20. There was a very thin membrane made out with the ophthalmoscope in the position usually occupied by the posterior capsule.

CASE VI. J. B. S., male, aet. 75. Cataract, mature o. s. The right eye shows evidences of old trachoma and there is extreme opacity of the cornea. The vision of the left eye began to fail 6 years ago and he has been unable to see objects for 9 months. The functions are normal. There has been an epiphora for some time due to a slight ectropion, but there is no disease of the sac. The extraction was with iridectomy, April 6th, four days after admission. I had intended doing the usual extraction in this case, but the anterior capsule was extremely tough, and not dividing with the cystotome, the lens was delivered in capsule after a very moderate pressure, and without loss or presentation of vitreous. The anterior chamber was re-established on the second day and the pupil was well dilated. There was a moderate conjunctival injection for a number of days. At the time of discharge, May

17th, the eye was perfectly white. There was a slight anterior synechia at the outer and inner angles of the wound. At the lower inner, also at the upper inner edge of pupil there was a little greyish, fibre-like mass, of just what nature I am unable to say. The vision + 8 ⊂ $\bar{c}$ + ·3 cyl. axis 15 = 20/50 + and later 20/40.

CASE VII. The second eye of S. C. (Case V). Cataract practically mature, vision, fingers 2 ft. Functions normal. Anterior chamber of good depth. Iris slightly tremulous. Extraction, May 10th, with iridectomy. There was no loss or even presentation of vitreous. The operation and healing process was as perfect and satisfactory as in the first eye. June 7th, the vision $\bar{c}$ + 9 ⊂ + 2 cyl. axis 0 = 20/20.

CASE VIII. M. D., female, aet. 65. Cataract mature o. d. Vision began to fail 6 or 7 years ago and has not seen objects for 2 years. Functions normal, anterior chamber of good depth. Extraction, April 21st, with iridectomy. The incision was of good size and completed a little in front of upper sclero-corneal margin. The lens was delivered in capsule, without difficulty, after about two minutes' pressure, but was followed by a moderate escape of vitreous. The anterior chamber was re-established and the edges of the wound in good apposition on the following day. The healing process was normal in every respect. The vision June 7th $\bar{c}$ + 9 ⊂ + 2.50 cyl. axis 0 = 20/20 —.

CASE IX. B. F., female, aet. 65. Cataract mature o. s. Failure of vision 3 years but has been able to distinguish objects until quite recently. Functions normal, anterior chamber of good depth. Opacity of cornea over inner half of pupil. May 17th extraction without iridectomy. The corneal incision was completed about 2½ to 3 mm. in front of upper sclero-corneal margin. The lens was delivered in capsule after moderate pressure, and there was no escape of vitreous or even presentation of vitreous in wound. The anterior chamber was re-established on the third day, and there was practically no injection during the entire healing process.

The iris was not prolapsed but was adherent along the entire extent of the wound. At the time of discharge, June 11th, the vision $\overline{c}$ + 12 ⊂ + 2.50 cyl. axis 0 = 20/70 (scar of cornea).

CASE X. S. E. A., female, aet. 74. Cataract mature o. d. Vision began to fail 4 years ago and has not seen objects for 6 months. Functions normal and anterior chamber of good depth. May 19th, extraction with iridectomy. The incision was of good size and completed 2½ to 3 mm. in front of upper sclero-corneal border. The lens was delivered in capsule without difficulty after moderate pressure, with no loss of vitreous and no appearance of vitreous in corneal wound. The anterior chamber was re-established on the following day, the edges of the wound were in good apposition, and the pupil well dilated. Until May 27th, seven days after the operation, aside from the fact that the anterior chamber had been shallow, the healing process had been absolutely normal. On that day it was noticed that the edges of the wound had separated slightly along its entire length. There was very little injection or other signs of irritation, but the edges of the wound continued to separate more and more from day to day, the iris tissue was forced into both the inner and outer angle of the cut, forming a bulging nodule at the former point. June 5th bands of cicatricial tissue were noticed at various points, the wound gradually contracted, with the result of an extreme incarceration of the iris, at the outer angle of the wound, with a moderate-sized prolapse at the inner angle that had not entirely flattened down at the time of the patient's discharge, June 11th. The vision at this date $\overline{c}$ + 5 ⊂ 8 cyl. axis 0 = 20/70.

There is one case that I have not included in this series for the reason that it would be an injustice to the operation. It was a traumatic case with a piece of steel in the posterior part of the lens. Vitreous presented early and a considerable amount was lost. The lens was removed without rupture of the capsule. It was found, however, upon examination, that the steel had perforated the posterior capsule, so it is probable

that the vitreous body was injured at the time of the accident and that the vitreous would have presented with the usual operation. The eye made a slow recovery and the vision with correcting glasses equaled 20/50.

To analyze briefly my cases.—In all of them with the exception of the eye lost from infection, the visual results are satisfactory and average better than would an equal number of ordinary extractions recorded as soon after operation. Good visions, however, do not of necessity mean good results from the standpoint of the operator. There were three eyes in which the results were ideal. I refer to the cases where the iris was slightly tremulous before extraction. There was no loss of vitreous, no anterior or posterior synechiae, the healing process was accompanied by almost no injection and the vision with correcting glasses equals 20/20. It is in cases of this nature where good results, it seems to me, might reasonably be expected. The suspensory ligament being very lax or partially ruptured, little pressure is required in making the lens present and the chances of a loss of vitreous are probably no greater, perhaps not as great as when the anterior capsule is divided. In one other case (Case VI) aside from the presence of an adhesion of the iris at both the inner and outer angle of the wound no exception could be taken to the result.

In the three cases where vitreous was lost (Cases I, IV, and VIII), the second became infected on the 7th day and ended in a panophthalmitis. I shall certainly not attribute this unfortunate occurrence to the character of the operation or to a loss of vitreous. It is the first case of infection I have had in three years, and an occasional suppuration is to be expected until we can obtain a sterile conjunctival sac. My other two cases in which the vitreous was lost made good recoveries, one with 20/20 and the other with 20/40 vision.

As to the gravity of vitreous losses in cataract extraction, a separation of the retina undoubtedly occurs sooner or later in a certain per cent. of the eyes, and though I cannot recall

any such case in my experience, it is probably not for the reason that I have been more fortunate than others, but rather that the patients have passed from observation. A loss of vitreous in an uncomplicated senile cataract is certainly not good surgery. In the majority of cases it should be classed as a surgical bungle. A new operation which adds to the per cent. of vitreous losses must offer very great advantages over the old to make its general application desirable.

Of the three remaining eyes the simple extraction in which the iris was adherent along the entire corneal wound is the least regrettable. It can be said that this condition might have resulted in any extraction without an iridectomy, but the chances are that it would not have occurred if I had made my usual incision along the limbus.

The conditions presented in Cases III and X are unique in my experience. I am, of course, familiar with anterior synechiae, incarceration and prolapse of the iris, but I can recall no case where the entire wound has separated so completely and extensively after it had apparently become united. In Case III I thought the result might be due to the fact that my cut was completed further back than Major Smith had recommended, or to a slight ulceration and consequent weakening of the corneal wound. In Case X, however, the cut was well forward, and the operation seemed to me perfect in every detail. The appearance in both of these cases suggested a displacement of the vitreous body forward and it seemed for a time that the wound would be forced open and the vitreous escape. The present conditions are,— in one case an extensive incarceration of the iris and in the other an incarceration of the iris at the outer and a prolapse at the inner angle of the wound.

My friend, Dr. E. E. Jack, kindly permits me to mention in this connection two of his extractions in capsule, both with an iridectomy. In the first the wound separated as in the two cases reported by me, and in the second the iris prolapsed both at the inner and the outer angle of the wound. A vision

of 20/50 and the iris in its normal plane is, I believe, preferable to a vision of 20/20 with a prolapse or incarceration.

From the standpoint of the American surgeon there are one or two points in connection with this operation as presented by Major Smith that it would be well to consider. In the first place the patients of India are an entirely different and distinct race of people from the patients which come under our care, and this difference is probably in some way accountable for the exceptionably favorable statistics as to suppuration and iritis. As proof that the removal of the lens in capsule is not the only factor in giving such brilliant results, the statistics furnished by Major H. Hubert of Bombay in his paper published in the March number of the Ophthalmoscope of this year, are important. His extractions were made in the usual way after the division of the anterior capsule, and I quote from his paper as follows:

"In the Bombay hospital both suppuration and severe iritis are extremely rare complications. I formerly reported 1,172 extractions with only one suppuration, and no iritis or irido-cyclitis severe enough to have resisted energetic treatment. Since returning from leave I have performed over 800 additional extractions with the result of no suppuration and only one case of closed pupil from iritis."

It may also be said that the value of Major Smith's papers would be greatly added to if there were more definite details as to the after-treatment and ultimate results. I fully appreciate the difficulty of keeping hospital patients under observation, but it is important to know, among other things, how long his cases remain in the hospital after the operation and if there is a tendency in a certain number to late separation of the wound with incarceration or prolapse of the iris. It is probable that a large per cent. of his patients are quickly lost sight of, and much ill luck may befall an eye six or more days after the extraction of a lens. It is worthy of note that my three most unfavorable cases, if discharged from the hospital on the sixth day, which is not earlier than some men send

their patients home, might have been classed as favorable results.

My present attitude as regards the extraction of cataract in the capsule may be stated briefly as follows: It is reasonable to suppose that with continued operating I should improve in technique and that my results would be more satisfactory in the future than they have been up to the present time. The question is, however, is it probable that they would be as satisfactory in a long series of cases as by the usual method of extraction followed by a secondary operation in a certain per cent. of the eyes? Major Smith has extracted 9,000 lenses in capsule and notwithstanding this exceptional experience his vitreous losses were 6.8% in the last reported series of cases. In my first hundred extractions from 12 to 15% of vitreous losses, at a low estimate, might reasonably be expected. The immediate visual results would undoubtedly average considerably better but incarcerations and prolapses of the iris would, I feel confident, be of more frequent occurrence than by the ordinary operation. On the other hand, my cataract extractions for the last few years have been very satisfactory. Vitreous has never been lost in a private case, and in the last one hundred cases operated upon at the Infirmary in but one. I have an occasional prolapse which is usually remedied at once and an occasional incarceration of the iris. Iritis, of any severity, is infrequent and is most often attributed to infection rather than to cortical. A secondary operation I have not regarded as of great seriousness. I have never had a suppuration in consequence, and with the exception of these cases of glaucoma, that made perfect recoveries without iridectomy, I can recall no other ill effects. Major Smith states that "when the capsule is removed, the patient can see well to do fine work, which is not the case when the capsule is left behind." With rare exceptions my private patients who are, of course, more easily kept under observation than the Infirmary cases, can read Sn. 0.5 three months or earlier after extraction, and if

they cannot a secondary operation is advised and usually accepted. My visual results are probably in no way exceptional nor better than those of the average American or European oculist of an equal experience whose patients are intelligent and carefully refracted. While I am inclined to believe that a small per cent. of lenses may, with advantage to the patient, be extracted in capsule I shall do very little more pioneer work in attempting to determine the cases best adapted to this operation. There is one sentiment of Major Smith's, in his article in the Archives of Ophthalmology, that expresses so admirably my feeling on this subject that although the application is a very different one, I will take the liberty of quoting it in concluding this paper. "There is virtue in knowing when to quit and in letting 'well enough' alone."

THE EXTRACTION OF THE LENS IN CAPSULE (EAST INDIAN OPERATION) AS A METHOD OF PROCEDURE IN CASES OF IMMATURE CATARACT.

BY MYLES STANDISH, M.D.,
BOSTON, MASS.

The extraction of an immature cataract is often desirable and always necessary when both eyes are involved so as to make the patient helpless.

When the opacity of the lens is nuclear in both eyes and of very slow growth, five to ten years of a patient's life may be wasted waiting for the lens to become hard and opaque.

To meet this situation the extraction of the immature lens has always been resorted to, and of late years a number of expedients have been advocated to increase the safety and success of the procedure.

Operations for the maturation of the lens by means of a preliminary iridectomy and trituration of the lens, either through the cornea or directly upon the lens capsule, have been resorted to with success in a fair proportion of the cases. In many cases,

however, the operation utterly failed to produce the effects desired.

The tendency in recent years has been to abandon operations to hasten the ripening of the lens and to extract the immature lens without preliminary treatment.

To this end the method of washing out the anterior chamber to remove soft and sticky lens material has been much used. The instruments devised by Drs. Lippincott and MacKeown have enabled us to effect this irrigation of the anterior chamber with a minimum amount of danger to the patient and anxiety to the operator.

These methods have given us better results than we had when we relied upon pressure alone to expel the broken lens fragments, yet all must recognize that after such operations a recovery without some inflammation of the iris and more or less opacity of the posterior capsule was rare.

This condition entailed subsequent operations upon the capsule with many uncertainties as to the operative results and a prolongation of the convalescence to such a length as sometimes to seriously threaten the health of aged or feeble patients.

I am sure I have seen the lives of feeble elderly people, when suffering from diabetes or nephritic disease, endangered and even lost from the prolonged confinement necessary when iritis has followed a cataract operation, tying down the iris and necessitating capsulotomies to stop the pain and suffering, or to give the necessary amount of vision.

These considerations induced me to turn to the new method of extraction devised and practiced by Dr. Smith in the East Indian Medical Service.

The dangers which are manifestly present of loss of the vitreous at the time of the operation did not seem to me so formidable as that from iritis and its sequelæ in the methods generally pursued at the present time.

It is true I have not had as yet opportunity to try the operation many times under the above conditions, but as this method of operating is at present under discussion, it seems an opportune

moment to suggest this phase of the matter for your consideration.

Each of the three cases which I have to present fairly represents in itself a group of cases which you will all recognize.

CASE I. A woman 65 years of age, always myopic with rather poor vision for many years — has been practically blind for several years in each eye. Has been seen a number of times and the operation postponed for five or six months each time.

At time of operation there was dense nuclear opacity, no light reflex through undilated pupil and a very deep iris shadow. Yielding to appeals for relief I determined upon an extraction of the lens in capsule (The East Indian Operation), according to the methods of Dr. Smith. Only my usual antiseptic and aseptic precautions were employed.

The incision was made in the clear cornea a little more than one millimeter from its margin. An iridectomy was done and the speculum removed. The upper lid was then raised by means of a lid elevator which was revolved in the fingers when necessary, so as to depress the upper edge of the wound with the vertical edge of the retractor. Pressure was made with the angle of the strabismus hook as recommended by Dr. Smith, at the lower edge of the cornea. Long, steady, and rather forcible pressure was necessary before the lens began to move. The tear of the suspensory ligament was distinctly felt, and by following up the lens as is ordinarily done in a simple extraction, the lens easily emerged from the wound without any loss of vitreous. During the emergence of the lens an interesting fact was observed: —

The clear lens material about the nucleus was so soft that when the lens presented through the wound it forced itself ahead of the nucleus into the protruding sac of the capsule, and when the nucleus followed, the antero-posterior diameter of the capsular sac had been very materially reduced.

The recovery was without incident. There was not the slightest iritic or conjunctival congestion at any time. The wound closed promptly and never gave any trouble. The vitreous contained old floating opacities which undoubtedly existed prior to the operation. The pupil and anterior chamber were absolutely

clear. The only record was vision taken 16 days after operation.

V. o. d. with Cyl. + 1.50 D a × 180° + 7.00 D = 20/70

CASE 2. A blacksmith 45 years of age, first seen by me four years and six months before date of the extraction. At that time there were some opacities in each lens, and a history of impairment of vision in the right eye for two and one-half years, and in the left eye for a year.

He was given a weak mydriatic solution which dilated the pupil sufficiently to enable him to attend to his affairs, but he was to delegate any of the work which bothered him to some of his employees. In October of last year he could no longer do any work and I found a large opaque nucleus in each lens with the rest of the lens absolutely clear. A preliminary iridectomy and trituration of the lens capsule with a spatula was advised, accepted, and performed. The patient resided several hundred miles away, but returned six months later with the lens unchanged from the previous visit, and an East Indian extraction was advised and accepted.

The operation was in all respects similar to that of Case 1. The only incident of interest was the fact that as the lens emerged from the wound a roll of vitreous presented the length of the incision, which, however, replaced itself when the extraction was effected. The pressing forward of the clear lens material in advance of the opaque nucleus was observed in this as in the first case. Recovery was without incident. The eye was not congested at any time. There was no hemorrhage or opacity in the vitreous. The last record of vision was 20 days after operation and without astigmatic correction it was,

V. o. d., $\bar{c}$ + 9.00 D = 20/50.

CASE 3. A lady 57 years of age with well-marked diabetes. Her vision had been so poor as to be troublesome for two and a half years. When first seen by me both lenses looked to focal light entirely opaque, but with the ophthalmoscope a faint glimmer of a red reflex could be everywhere observed. The patient was so blind that she could not find her way about the house.

Seen again three months later no change of conditions could

be observed, and after a fair statement of the situation to her son, who was a physician, the East Indian operation was decided upon. The incision was made as in the two previous cases, but when completed the tension of the eye was much less than it should have been. As a result, the expulsion of the lens by the method described above was very difficult, and a number of attempts were made before the procedure was successful. When the lens emerged there was the loss of a small bead of semi-fluid vitreous.

If the same amount of manipulation had been used in an ordinary extraction, it is probable that the loss of vitreous would have been as great. Some iritis after the traumatism of this operation was to be expected in a diabetic. The wound healed promptly and securely; there was only moderate conjunctival congestion. The iris became blurred with a slight exudate, and the pupil assumed a squarish shape, but it did not contract and the iritis promptly cleared up under the use of atropine.

The only record of vision as yet, was taken 12 days after the operation (the ophthalmometer showing 10 D. of astigmatism), which was corrected and combined with

$$\text{V. o. d.} + 5.00\,\text{D} = 20/\text{C} + 1.$$

I do not wish to maintain on the strength of an experience with three cases that the new operation is safe or always desirable, but I think it will be seen that these three cases each represent a group of cases ordinarily difficult to handle and in which there is always greater danger than in the ordinary case of cataract extraction. The results in these three cases were probably better and were achieved with less distress to the patient during convalescence than would have been accomplished by any other operative method.

DISCUSSION.

DR. H. HARLAN, Baltimore: I had my attention called to this operation by one of my assistants on his return from Boston and did two, and, I might mention one as illustrating what we might expect to occur. In expressing the lens, after having removed the speculum, the vitreous came out at one side, the ligament giving way there. That is a thing that I should think would be likely to occur in many instances.

THE COURSE AND TREATMENT OF SIMPLE CYCLITIS.

By EDGAR S. THOMSON, M.D.,
NEW YORK CITY.

Simple cyclitis, or "serous iritis" as it is frequently and incorrectly called, presents to us questions of great obscurity and difficulty in almost every case, and it is with the object of discussing some of these points that I bring the subject before you.

The clinical picture varies somewhat, but all cases begin with slight ciliary injection, slight turbidity of the aqueous, and the peculiar dotted deposits on the posterior surface of the cornea, known by the various designations, keratitis punctata, descemetitis, etc. The iris is involved secondarily, and the pupil will usually react for some days after the onset of the disease. Infiltration of the vitreous occurs in about half of the cases.

The disease occurs chiefly between the ages of twenty and forty-five, affects both sexes with about equal frequency, and always runs a relatively slow, chronic course. It attacks at times one eye alone, and relapsing attacks may occur for a period of years without involvement of the other eye. In other instances both eyes are attacked at the same time, though one is usually somewhat in advance of the other. The attacks vary greatly in severity, sometimes subsiding in a week or ten days, at other times going slowly but steadily on until iris and choroid are involved to a serious extent. All grades of severity have, however, this in common — they may at any time in a few days reach a point where the integrity of the whole globe is seriously imperiled.

One cannot fail to be impressed with the difficulties en-

countered in the treatment of this disease, and yet if allowed its own course the results are almost uniformly fatal to the eye. The complications that most frequently occur are extension of the inflammation to the iris and the anterior part of the choroid. The iris involvement is accompanied by increase of ciliary injection and engorgement of the ciliary circulation, and contraction of the pupil with change in the color of the iris. The choroidal infiltration also occurs synchronously with the increase of the congestion and can only be inferred to be present, as the vitreous opacities occur in any event. It is probably frequent, however, and occurs in the anterior part, at least in the majority of cases, that reach a certain intensity.

Following general involvement of the uvea, there is commonly an increase in the intra-ocular tension which comes on slowly and is not *per se* a serious danger to the eye, but is rather a symptom of general lymphatic and vascular disorder. Ultimately, however, the pressure effects on retina and nerve may come into play, though I myself have never seen a case of cupping of the optic nerve from this cause. Cases which reach this point and are not relieved go on to uveal atrophy with the sequelae of retinal detachment, cataract, and finally shrinkage of the globe.

The pathology of this condition is but imperfectly understood — the etiology, not at all. It is the rule in these cases to get no history of syphilis, rheumatism, or any general dyscrasia that seems to have any bearing on the subject. Many of the cases I have seen have not been excessive smokers or drinkers, and some — the women included — were clear of any suspicion of the sort. Urinalysis has generally been negative. Indican was found in a few cases, though in many others no special report was made on this point. Digestive disturbances —though we have every reason to look for them — have not been demonstrated in most of the cases though I have not by any means carefully studied this side of the question, and am inclined to think that we must look in detail into

the chemical process of digestion for a cause—probably through auto-intoxication, as has been suggested by de Schweinitz in a paper read at the recent meeting of the American Medical Association.

I have not been able to discover that normal action, or even cramp of the ciliary muscle, plays any important part in bringing on the attack, though I have in every case looked into this. Undoubtedly ciliary action will make worse an established inflammation, but I do not believe that it is an important causal factor.

Sympathetic inflammation frequently assumes the form of a simple cyclitis and runs the same course as a very severe idiopathic case, but obviously is not to be considered in the present connection.

The histological picture of cyclitis in its later stages is a familiar one, and it is only necessary to refer to the fibrinous exudates and atrophy of the muscular and connective tissue elements with the extensive leucocytic infiltration which characterizes all forms of cyclitis. With the changes in the beginning of the attack, on the other hand, we are more concerned, and naturally enough it is just at this stage that our histological data are limited. Fuchs has found the ciliary processes swollen and infiltrated with leucocytes arranged chiefly around the blood vessels and between the pigment epithelium and the muscle, and it seems fairly certain that an altered state of the blood and lymphatic fluids exists, which by its local action sets up the inflammatory changes in the delicately organized ciliary body. The aqueous is found to be richer in proteids than the normal (Parsons, Vol. 1, p. 352) as during the attack of glaucoma, though there is probably a similar change in any form of iritis. The connection between this and the increased tension is yet to be demonstrated, though it seems a very reasonable hypothesis that aqueous which is richer in solids should escape with greater difficulty than the normal aqueous.

One cannot fail to be struck by the signs of a disordered

lymph circulation, which come on early in simple cyclitis and are manifested by the tendency to increased tension, the sluggish ciliary circulation, and the slow rate of absorption of the vitreous exudates. It seems as if one attack was sufficient to leave the eye in a susceptible condition and predispose it to future attacks, and it is difficult to account for this unless by the supposition that the lymph circulation becomes impaired. It occurs at times in families with a hereditary predisposition to glaucoma, and it is impossible to avoid the idea that there may be at least some association between the two diseases. Both occur in persons of tense nervous temperament, and in each case a prolonged nerve strain or emotional disturbance is apt to bring on the attack. This is particularly true in glaucoma, as is well known, but in my experience it is also true to a lesser degree in simple cyclitis.

It cannot be said that we have any very rational or effective medicinal treatment for simple cyclitis. I always begin by giving small doses of calomel, and whether this acts by eliminating toxic products or simply by its determinative effect, it certainly seems to do good. After this I usually administer mercury, followed by ascending doses of potassium iodide, and at times salicylates, but I have never been able to satisfy myself that they have had anything to do with retarding a general uveitis or with clearing up the attack in those cases which recovered. Diaphoretics have been equally uncertain in my hands. I commonly use pilocarpin hypodermically, in doses of 1-12 to 1-6 of a grain. I have used Park, Davis & Co.'s fluid extract of jaborandi but have found the dosage very uncertain, though if increased sufficiently it has always produced diaphoresis. Local medicinal treatment is of limited value. I use atropin in the earlier stages, for I believe that if we keep the blood squeezed out of the iris it makes just so much less in the ciliary circulation. Later on when the engorgement of the vessels is more marked I believe, with Fuchs, that atropin should not be used on account of the danger of throwing the blood back into the ciliary body. At

this point I stop atropin and use pilocarpin, especially if the tension tends to rise.

Hot water locally is of some value in stimulating the lymph flow. The value of rest, both local and general, cannot be over-estimated. The general circulation should be kept as quiet as possible, and all use of the eye for near work must be at once stopped and dark glasses worn. If the ciliary circulation becomes more engorged the patient should be put to bed and kept there as long as any considerable hyperaemia exists.

All cases have a marked tendency to recurrence, and sooner or later another attack comes in the great majority of instances. While we cannot, perhaps, hope to alter the chemical processes of the patient so as to stop the attack, it is certain that by systematic exercise with regulated diet we can postpone the recurrence oftentimes for many months.

Operative measures, which are always required if increased tension becomes well established, are directed toward the reduction of the tension. Paracentesis has been done, but at present iridectomy is the established operation. We are as much in the dark as to how iridectomy relieves these cases as we are in glaucoma, but there are probably several effects to be considered.

1. Depletion of the iris and ciliary body. This is an important effect and occurs even where there is little iris haemorrhage. The aqueous escapes rapidly until the wound unites, and so depletes the lymph circulation and indirectly the vascular circulation.

2. Abolition of the action of the sphincter pupillæ. This must certainly lead to lessening of the iris hyperæmia, and withdraws a source of irritation to the ciliary body, even if it does not actually relieve the inflammatory process.

3. The freeing of the lymphatic circulation. This effect is well known both in glaucoma and in simple cyclitis, but the manner in which it occurs is problematical.

In four instances in which I have done an iridectomy for

this condition the results have been most satisfactory. In one case with increased tension for ten days and V = PL the vision was restored to 20/20, and there has been no attack for nearly six years. In the second eye of the same patient, iridectomy was done some three months later, as soon as the slightest tension manifested, with an equally satisfactory result. There was no disturbance of the first eye during the attack on the second. In two cases operated upon four months ago, one was a very old chronic case, with numerous posterior synechiæ. There has been no farther ciliary hyperæmia, although it was constant before the iridectomy. In the other, the inflammation was increasing steadily, the whole cornea was covered with precipitates which were increasing. the vitreous was full of exudates, and there was slight increase of tension. Recovery was uninterrupted after the operation, although the vitreous opacities are still numerous and the vision is therefore poor.

In what way does iridectomy prevent the recurrence of the attack?

I am very much inclined to believe that it has some effect on the lymph circulation which *does* prevent recurrences, and I think that we should certainly operate in cases that are steadily going on to general involvement of the uvea, even before the stage of increased tension, as the chances of recovery are so much better. In fact, hæmorrhage following iridectomy is almost unknown between the ages of twenty and forty, except in glaucomatous eyes, and the reaction following a properly done operation is so slight that we have much to gain and little to fear. Of course vascular degeneration from heart or kidney disease is a decided contra-indication, but practically such an unfavorable combination is not often met with. It goes without saying that the operation must be technically correct in every particular, the incision a smooth, clean one through the sclera at the root of the iris, the coloboma not too large but including the root of the iris clear back to its attachment to the ciliary body, and the pillars of

the iris absolutely free from inclusion in the wound. Whether to operate on an eye which recovers from the attacks, but in which the attacks are growing steadily more frequent and more severe in spite of treatment, is another qestion and one upon which I do not as yet feel qualified to express an opinion. It is an important matter, however, and one which well merits our most careful consideration.

DISCUSSION.

DR. H. D. BRUNS, New Orleans.— The paper the doctor has just read seems to me to be of great interest from the point of diagnosis. If I could feel as clear in my mind as the doctor that he can recognize a case early of simple cyclitis I would feel very much disembarrassed in many cases I have to deal with.

Some years ago I collected and published a number of cases showing that deposits on the posterior surface of the cornea may be present in almost all varieties of uveal trouble. It is by no means a unique thing for a patient to come to us in a very early stage of what proves to be a plastic choroiditis, presenting exactly the same appearance as the serous iritis or present day simple cyclitis. Now if one should hasten in such a case to do an iridectomy it would be a very serious mistake. This whole question is in a very unsatisfactory state. We see choroiditis so much in its later stages and so seldom in its earliest beginnings that the danger of confusing the first symptoms of a choroiditis that is going to be general, or is going to be posterior, with a "simple cyclitis," is great and can only be avoided by careful watching. What are we to do when the vitreous is opaque? When we see the patient for the first time and there is opacity of the vitreous, slight circumcorneal injection and Descemetitis; the media sufficiently muddy to prevent seeing the choroid itself? We see many cases presenting these appearances, that later on, when the eye clears up, show the atrophic remains of a posterior, plastic choroiditis. We see such cases again and when the eye clears up there are no such marks; so how are we to distinguish these so-called simple cyclites from general uveitis? Fuchs in treating of this subject and calling all these conditions simple cyclitis confesses that he was just saved by mere

accident from calling a case simple cyclitis by finding a plastic spot in the extreme periphery of the choroid. The difficulty, therefore, is in being cocksure that it is "simple cyclitis" and one should certainly be very cautious about advising operative interference too soon. These cases should be treated and watched, and if one sees that there is a glaucomatous element, that there is going to be a chronic trouble in the anterior part of the uvea, that is the time to do an iridectomy.

DR. EMIL GRUENING, New York.—We have here an inflammation of the uveal tract with tension and there are a number of cases in which even if there is extensive choroiditis it might go on and clear up. There are cases of serous iritis where iridectomy is advisable. Dr. Thomson does not say that he has not observed his cases carefully. He has used iodide of potassium and other agencies and in spite of that there was tension. In some of these cases if the tension is high I think operation is advisable. I have seen eyes lost by endless treatment and I have seen many eyes saved by operation. If we have a case in which atropia causes tension and eserine and pilocarpine cause iritis we have a vicious circle and do not know what to do. Iridectomy in some of these cases is the remedy.

DR. S. L. ZIEGLER, Philadelphia: Serous iritis is undoubtedly a very chronic disease and the therapeutics of it is not in a very satisfactory state. There is perhaps one of the older remedies that may be given internally with advantage in certain cases, and that is turpentine. I believe, however, that this disease is the one disease of all that yields best to electric treatment. The positive pole will shorten the course of serous iritis to from 3 to 6 weeks, when it would require from 3 to 6 months with any other form of treatment. The glaucomatous tendency would ordinarily require the negative pole; glaucoma always yields best to the negative pole and is made worse by the positive pole, but in the case of serous iritis the positive pole is the one to use. The action is an electrolytic and oxidizing one, with stimulation of lymphatic action.

DR. W. B. MARPLE, New York: It was the privilege of some of us a few weeks ago to listen to a paper by Dr. de Schweinitz on the relation of autointoxication to these cases. Just about the time I read the paper I had a patient who had a form of

uveitis of which it was difficult to decide the etiology. I had used iodide, mercury, and salicylate of soda in these cases, and in time, on account of or in spite of the treatment, they got well. This patient was otherwise perfectly well, but had a vision of 20/70. I had the urine examined. Dr. de Schweinitz says that even the presence of indicanuria does not necessarily indicate autointoxication, but that was the only indication in this case and I treated it on that theory. It takes more than one case of course to prove an etiological connection, but I never had a case clear up like this one. I saw her first on May 22d and the last time a few days ago. Her vision improved from 20/70 to 20/15 and I could not make out a single spot on the cornea. So I think that autointoxication in this case had something to do with the trouble in the uveal tract. The treatment was flushing out the intestinal tract and saline cathartics.

DR. E. S. THOMSON, New York.— In answer to Dr. Bruns' criticism as to diagnosis, it seems to me when we have these symptoms referred to we have a cyclitis. I am not advising operation until we have the indications spoken of, but when we have them I believe we should do an iridectomy without waiting for much increased tension. Of course I agree with the doctor about being conservative.

A CASE OF SECONDARY HYPERNEPHROMA OF THE IRIS AND CILIARY BODY.

By BURTON K. CHANCE, M.D.,
PHILADELPHIA, PA.

The man whose history is here detailed came under my observation first in the wards of the Germantown Hospital on October 11th, 1905. He had had hemorrhoids, and Dr. C. A. Whiting had operated recently for the removal of them. The House Surgeon, Dr. Markle, called my attention to the man because of there being, as he supposed, a growth in the left eye.

At the time of my examination the patient was in what he deemed his usual good health and suffered only from his rectal

disease. In the month past he had been annoyed by obscuration of his sight, especially of the left eye, though that eye was neither painful nor tender. I discovered on his body, beneath the skin, over the region of the costocartilaginous junctions on the thorax, several nodular enlargements. These masses were movable and reminded me of the enlargements of the cervical glands common in constitutional syphilis. In the left groin there was a large bubo.

Arising from the middle of the inner pillar of the iris of the left eye, and on the horizontal meridian, was a spherical tumor, mottled gray in color, approximately four millimeters in diameter. There were no signs of inflammation present. On the nasal side of the globe were several leashes of dilated blood vessels which were arranged triangularly with the base at the limbus. The tumor was flattened against the posterior membrane of the clear cornea. The iris presented no other abnormality. The pupil was round, of about four millimeters in diameter and changed freely to various stimuli. By oblique illumination no defects in the lens were noticed. The anterior chamber was of the depth of that of the fellow eye; the tension being only slightly raised above that of the right. No tenderness was elicited. The right eye presented no anomaly. Vision of the right equaled 6/6, of the left 6/30, Snellen.

The iris dilated when a solution of atropin was instilled, and the pupil was circular except at the site of the tumor. Here the curve was broken by the projection of the mass into the pupillary space.

The tumor appeared to rise from the radiating muscular fibers. There was but slight protrusion backwards, the base therefore was buried in the pigment layers of the iris; the anterior surface was flattened against the endothelial membrane of the cornea. It was globular in outline though somewhat nodular in conformation and was attached to the iris by a short, broad pedicle. It resembled the small granulomata frequently seen in the conjunctiva at the apex of the socket remaining after an enucleation. The tumor was highly vascular, the fine loops giving a pink stippling to the

grayish-yellow color of the denser portions. The lens was clear; the vitreous had begun to disorganize, for there were large floating masses in it, while more deeply situated there was the semblance of "brick dust" deposit.

The optic disk was round; its upper border whole, while about the lower was a wide, sharply-cut conus. This conus I conceived to have been formed by an axial distension rather than to have been a part of a general inflammation of the choroid that was present in other parts of the fundus, and because the refraction of the eye was measured by a minus 4 D lens. The choroiditis was of comparatively recent origin. The macular region was not affected. The retinal epithelium was markedly absorbed; the outlines of the tortuous vessels were blurred, but no hemorrhages were noted.

The patient, aged about forty, stated that shortly before his admission to the hospital his attention had been called to the presence of a small lump in his eye. This lump, he was certain had increased in size rapidly, though it never had been painful, neither had the eye been inflamed. In the spring of 1903, this eye had been struck with a small stone. The man said that he applied for treatment at the Wills Hospital. The injury must have been slight and the symptoms transitory, because only a simple lotion was prescribed and he was advised to report again to be fitted for glasses. His recollections of the examinations made of his eye at that time were not strong, yet he remembered that his condition was such as to occasion comments from the surgeon in charge and his staff to several visitors present in the clinic. It may be presumed, however, that there was no unusual growth perceptible then, for the man would have had the recollection of an allusion having been made to it had such a thing been noticed. I have not been able to find any record of such a case as this at the Wills Hospital; therefore the antecedent history is uncertain.

The man was a carpenter. He was married and had three children. His childhood had been healthy; in adolescence he had a simple attack of typhoid fever. In 1902 he became infected with syphilis. He was not treated for this disease, for, shortly

after noticing the initial lesion of it, he was arrested for drunkenness and loafing and was committed to one of the penitentiaries. He declared to me that he was refused treatment by the resident medical officer of that institution. After serving his term he returned to his work, but even then he had had only the most irregular kind of treatment. No member of his rather large family had a history of consumption or of tumors.

I suspected this to be a case of sarcoma of the iris, yet in view of the general history, I did not forget to consider the probability of there being a specific element in the genesis of the tumor. Accordingly, for five days, the ointment of mercury was vigorously applied thrice daily. At the end of this course there was a perceptible softening of the subcutaneous tumors, but that of the iris remained unaffected.

A few days later, when the eyes were examined again, there were evidences of cyclitis in the left. The sclera was faintly injected and numerous precipitates were lodged on Descemet's membrane. In the right eye were signs of active chorioretinitis, though the blue iris was healthy. By October 20, the ciliary injection had increased considerably, while the tumor appeared to have spread out slightly, and to be less closely applied to the cornea. Also, it had become distinctly lobulated and irregular in outline. I believed that I had to deal with a very active and malignant process. The patient refused to have the eyeball removed, but on October 23, after inventing many pleas by which to escape from the hospital, he at last consented to allow an operation for the removal of the tumor. I removed the tumor by a wide iridectomy.

The incision was made with a broad keratome in the nasal limbus. As the space between the limbus and the tumor was small, and as I feared to lacerate the tumor, I withdrew this knife and lengthened the incision by lateral strokes with a narrow, angular blade. This part of the operation was prolonged by a very annoying hemorrhage. With a many-toothed capsule forceps, I caught up as much of the surrounding iris as could be grasped, and withdrew the entire mass with the tumor and ex-

cised it with spring scissors. Great and prolonged hemorrhage followed. Much of the effused blood escaped from the anterior chamber after the wound was flushed with boracic acid solution. The toilet of the wound, however, was performed satisfactorily, after which I applied a light compress over each eye and then bandaged both.

Seven hours later the patient was resting comfortably, and when the dressings were removed early the next morning only a slight operative reaction was present. The wound had closed and the chamber had reformed. Atropin was instilled and the bandages were reapplied. The eye soon healed. The edges of the coloboma were adherent to the lens capsule. This synechial attachment in all probability had existed prior to the operation, for it was with difficulty that the iris could be caught into the jaws of the forceps, and doubtless this lack of resiliency occasioned the profuse hemorrhage that followed at the excision of the iris. The lens was clear, though there were several clumps of pigment on the capsule. In about two weeks the patient was discharged from the hospital.

In order to study the histology of the tumor the specimen was intrusted to Dr. C. M. Hosmer, of the Medical Laboratories of the University of Pennsylvania, who prepared for me many beautiful sections from almost the entire tumor, which he has stained by a variety of methods.

The tumor springs from the anterior surface of the iris, and the site of it occupies the middle portion of the section which was excised. The normal tissues about the base of the tumor are destroyed by the infiltration of the tumor cells. The outer portion of the iris is apparently uninvolved and the sphincter remains intact. (Figure 1.)

The tumor is without a capsule or other limiting membrane. The substance of it is composed of numerous thin-walled blood-vessels and spaces which branch in many directions in the midst of cellular elements. In the iris stroma are a few vessels having normal coats, yet elsewhere, the vessels or spaces are formed by

SECTION OF IRIS TUMOR. FIGURE 1 . x 50

SECTION OF IRIS TUMOR. FIGURE 2 x 120

SECONDARY HYPERNEPHROMA OF IRIS AND CILIARY BODY

channels, with thin coats of fibrous connective tissue, lined with endothelial cells which are in the process of proliferation. (Figure 2.)

The cells are arranged in layers. They are large and present a variety of shapes, passing from the columnar, when next the blood vessels, to the polyhedral, oval or round, according to the pressure made upon them as the periphery of the tumor is approached. In the iris stroma the cells are not clustered about the vessels, but are more generally distributed.

The individual cell is composed of fine granular protoplasm and a large nucleus with a distinct nucleolus. The cells are evidently multiplying rapidly, for, in many of those lying nearest to the vessels, there is more than one nucleus, each with its own nucleolus, though no karyokinetic figures are discerned. At a distance away from the vessels, too, this nucleolation is seen, yet here the protoplasm has become vacuolated as though degenerative processes had set in.

At that time, judging from the character of the cells, and of their arrangement about the vessels, the growth was regarded as a perithelial sarcoma by Professor Allen J. Smith, of the University of Pennsylvania, to whom I showed the slides.

I saw the patient at various times after he left the hospital. Within the week of his discharge he was committed to the House of Correction on the charge of vagrancy. This was early in November. He was released on December 22. I visited him there. During his confinement specific remedies were administered to him and he soon gained in weight. In the week following his release from the hospital, my records show that the cornea continued clear; the sclera was without injection; the cicatrix was absorbing; the anterior chamber deep and the aqueous free from precipitates. The iris coloboma had become quadrate rather than triangular because of the adhesion of the pillars to the lens capsule. The remaining portion of the iris was healthy and responded to the action of atropin. The lens was unclouded and the state of the vitreous unaltered. The nerve head had become

swollen and it was impossible to study its features in detail. The choroidal inflammation was extending in all directions. The condition of the right eye remained unchanged.

Early in January, 1906, the man's testicles had become somewhat enlarged, and he complained of pain and heaviness. I referred him to Dr. Hilary M. Christian. Later, he turned up in Dr. Christian's ward at the Philadelphia General Hospital, where he was treated with antisyphilitic remedies. While there, a number of small nodes were noticed lying beneath the skin on his thorax, like those I had discovered while he was under my care. These softened and became smaller when mercury was pushed, in the same manner as those which I have already described. Several of them were excised, and pronounced sarcomata by Dr. Rosenberger, the pathologist of the hospital.

On January 26th, the man was anxious for me to see his eyes, and he asked to be allowed to come to me. To all appearances the ocular conditions had not changed; but on February 1st, he came again, complaining of intense pain in the left eye. There was a small foreign body on the cornea, but in addition, the cornea was steamy and surrounded by a ring of ciliary injection, while the iris was obscured by the turbid aqueous. The tension was not elevated. I removed the foreign body and bandaged the eye after instilling solutions of cocain, dionin, and atropin. Four hours later the symptoms had not abated.

A day or two later I was informed that he had returned to Blockley, but this time he entered the Eye Wards. On February 7th, I was invited to visit the patient through the courtesy of Dr. John Welsh Croskey, the alternate of Dr. Charles A. Oliver, who was unable to serve at the hospital because of an illness.

The patient's ocular symptoms had become more profound. There was greater injection, greater cyclitis, haziness of the lens, a more clouded vitreous, and an indistinct fundus. The intraocular tension was elevated, and yet the tension of the right eyeball was equal to that of the left. The man lay curled up in his bed; he had lost weight and presented signs of cachexia. In the days following, the pain increased so greatly that he begged

for the removal of the eye, fearing that the right eye might become similarly diseased. On Saturday, February 17th, Dr. Croskey removed the eye, and the large inguinal gland also; he most kindly gave the specimens to me.

The globe measured 25 mm. in the anteroposterior diameter, 23.5 mm. in the vertical, and 23 mm. in the transverse. It had been most cleanly dissected from the socket; the sclera being smooth, and the attached nerve, which measured 6 mm. in length, appeared healthy. No tumor was detected in the globe by transillumination, and on section of the globe no evidences of a neoplasm were apparent. The vitreous chamber contained a shrunken mass of vitreous, the retina had been detached pathologically, and the nerve was swollen. The cornea had become clouded; the anterior layers of the iris were covered with a grayish exudate and the lens had become cataractous and was dislocated towards the nasal side.

Dr. Harold Goldberg, the pathologist of the Wills Hospital, prepared the globe and stained several sections in the usual double stains. The globe had been divided horizontally, in order that the region of the coloboma might be included in each of the sections, which were taken from the upper half of the globe.

The study of these sections elicited the following details:

Except at the sclerocorneal junction, where there is a moderate leucocytic infiltration, the cornea is not affected; and polymorphonuclear leucocytes occupy the angles of the anterior chamber and extend over the surface of the iris. Newly proliferated connective tissue cells have invaded the stroma of the iris. The lens is dislocated, its capsule is separated, its fibers shrunken and opaque. The ciliary body is atrophic; the inner surface is covered with a leucocytic exudation; the pigmentation is excessive and the endothelial cells have proliferated greatly. (Figure 3.)

In addition to the changes described above, the processes have been destroyed by a papillary new growth, composed of small round cells with deeply stained nuclei. The growth extends out into the vitreous chamber; some of the cells have escaped and have been caught in the shrunken and degenerated vitreous.

There are no signs of the new cells having invaded the choroid, which has become atrophic while the pigmentary elements are prolific. The fiber layer of the retina is thick. The retinal vessels are greatly enlarged and engorged with blood and leucocytes. The nerve head is swollen; the fibers have become atrophic from the leucocytic infiltration, and the endothelial cells are increasing.

In Dr. Goldberg's opinion this ciliary neoplasm is a small round-celled sarcoma, in which there are signs of melanotic changes.

Late in March the patient returned to the Germantown Hospital. He was emaciated and weak. The orbital socket had remained healthy. The right eye showed evidences of advancing choroiditis.

On April 17th, he showed violent symptoms of acute intestinal obstruction. Dr. Francis Stewart opened the abdomen and discovered a long intussusception in the ileum, which he reduced. The abdominal viscera were studded with neoplastic formations. The position of one of these tumors was such as to effect an invagination of the intestinal tube. The patient rallied from this shock. About May 10, the abdominal wound burst; a day or two after, the intestinal wall ruptured and a fecal fistula became established.

In the second week in May I took all of my preparations to Professor Smith; he had not seen the sections of the subcutaneous nodules. These nodules have a distinct and fatty capsule. The growth is made up of large flat cells in which are large nuclei, though many contain nucleoli and some are multinucleated. The cells are divided into masses by dilated alveolar walls. These walls are almost completely made up of capillary blood vessels. Dr. Smith thought this tumor resembled the tumor found in the iris and he believed it to be an endothelioma.

A day or two later, however, while studying the three different specimens, and comparing them in detail, a diagnosis of hypernephroma was made, and Dr. Smith urged that in the event of an autopsy, special care should be given to the examination of the kidneys and neighboring structures, with the expectation of finding such a primary growth.

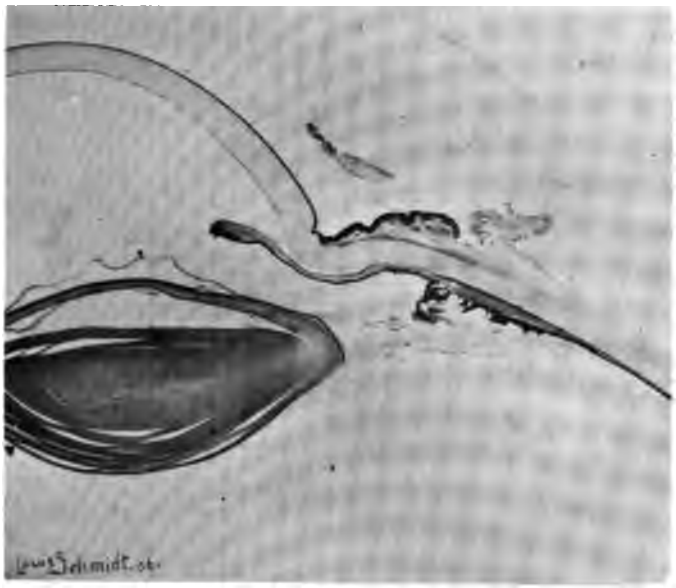

SHOWS INVOLVEMENT OF THE CILIARY PROCESSES. FIGURE 3 x 09

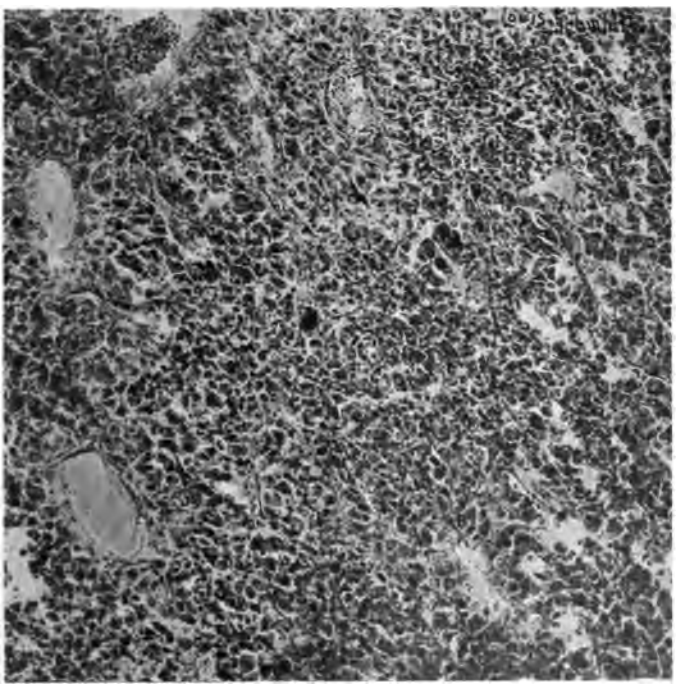

ORIGINAL TUMOR—FROM KIDNEY. FIGURE 4 x 120

SECONDARY HYPERNEPHROMA OF IRIS AND CILIARY BODY

On Monday, May 21st, the patient died.

Thus ends the clinical history. I believed that I had been dealing with a case of primary tumor of the eye. The diagnosis has been reversed completely by the findings just indicated, and in the examination of the tissues after death.

I do not intend to enter into a tedious detail. Death was caused by an intussusception of the ileum. This intussusception is a double one; a portion is directed upwards and a portion is directed downwards. The apices of the two intussuscepta meet in the lower part of the mass. Each apex is formed by a tumor, the larger being 3.5 cm. by 3 cm. in size, sufficient to have caused a partial obstruction in the intestine, and thus to have facilitated the invagination of the gut. On the inner surface of the intestine are many tumors, in size varying from 1 mm. to 2 cm. In the mesentery are a number of enlarged glands and tumor nodules, ranging up to within one centimeter in diameter.

None of the abdominal organs contained these nodules except the left kidney. In the envelope of this kidney are eight or ten small tumors, the largest about a centimeter in diameter. Most of these masses are nodular, reddish-gray in color, and very much resemble the appearance of the tumor found in the iris.

At the lower pole of the kidney, and protruding from it, is a rounded tumor, from three to four centimeters in diameter. This tumor involves the kidney, though it is surrounded by a distinct capsule; the gross appearance is like that of the other tumors already noted. At the upper end of the pelvis, in the substance of the kidney, is a smaller mass resembling the larger one, though it has not so definite a capsule. The right kidney is not involved, except in the perirenal fatty envelope where there are a few small secondary nodules.

The suprarenal bodies are not affected. The portions of the lungs removed from the thorax do not contain any neoplastic formations; neither were any found in the heart.

After a brief description of the primary renal tumor, and the other secondary growths, the ocular tissues must be reviewed in the new light that can now be thrown upon them. The sections

from the kidney show that organ to have been changed but little. (Figure 4.) The tumor is divided into long, narrow alveoli by delicate fibers and branching blood vessels. In some fields the blood vessels or spaces seem to be the only marks of division. This alveolar arrangement strongly suggests the fascicular zone of the suprarenal gland. The cells, which are epitheloid in type, vary much in size and shape, being polyhedral, oval or rounded, according to the pressure made upon them; and they seem to spring from the septa, forming distinct mantles about the blood vessels. The cells have much homogeneous protoplasm and a large nucleolated nucleus. Neither here nor in any of the sections examined subsequently, were there seen any of the coarse granules commonly met with in functionating adrenal tissue. The size of the nuclei is irregular; in several instances the nuclei occupy nearly the entire cell, and in others, the cells are polynucleated.

In Professor Smith's opinion, "the general appearance of the specimen corresponds with that of a hypernephroma."

The intestinal growth involves the submucosa. Its histologic appearance is exactly like that of the renal tumor. The basal cells are more densely packed than are those at the periphery, where also the mantles about the vessels are pronounced.

A section from the mesentery displays features common to the other nodules.

The sections of the subcutaneous nodules and of the inguinal gland have been prepared with less care than the others, and they present artefacts, yet, except for minor distinctions, their characteristics correspond to those of the structures already described.

The tumor of the ciliary body is regarded by Professor Smith as identical with the others. The cells spring directly from the surface of the processes. They are not supported by an intercellular stroma, but in several places there are seen delicate outgrowths of fibrous tissue in which are blood vessels about whose thin walls are grouped the tumor cells. The retina is involved near the equator, the cells being confined to the inner layers. They are closely packed about the narrow blood spaces, and they are

smaller and apparently younger than the cells found in the iris and the ciliary processes. In this specimen the polynucleation is marked.

The iris tumor bears a strong likeness to the gross structures of the other tumors. The central, basal part is dense, while the peripheral portions are loosely arranged in indefinite and coarse branches. Under higher powers the central portion is alveolated, while the peripheral is composed of thin-walled vessels surrounded by the layers of cells.

Having these sections before us one after another, we may safely declare that we are dealing with a case of hypernephroma. The primary tumor developed from an adrenal rest in the left kidney. The secondary metastasis has been conveyed by the blood, although the deposits in the mesentery might have been carried there by the lymph stream as well as by the blood.

The term, hypernephroma, is applied to tumors arising from suprarenal glandular tissue. It is of recent origin, and was used for the first time in 1896, by Birch-Hirschfeld.[1]

The genesis of these tumors was not understood before 1883, and they were called by many different names, as lipoma, sarcoma, adenoma, angioma, endothelioma, etc. In that year Grawitz,[2] in his paper, "So-called Lipoma of the Kidney," described their real character, as arising from the suprarenal tissue, whether in the normal position in the gland, or from aberrant fragments found in other organs and known as "adrenal rests." The term is not applied to growths in the suprarenal itself, but to those arising from the "rests" located elsewhere.

Notwithstanding the statement to the contrary, these tumors cannot be rare; the general surgeons are reporting hypernephromata with increasing frequency,— indeed, since the death of my patient I have learned of several recent cases, and in the literature of malignant tumors of the kidney they have been found to be very common.

---

1 *Birch-Hirschfeld*: Lehrbuch der Path. Anatomie, V. Aufl., Bd. I. S. 262, 1896.

2 *Grawitz*: Die Sogenannten Lipome der Nieren, Virchow's Archiv. f. Path. Anat., Bd. 93, S. 39, 1883.

The embryologic development of the suprarenals is in close relation to that of the primitive kidney and of the sexual organs; it is not to be wondered at, therefore, that particles of this glandular tissue should be found misplaced in the kidney, or elsewhere, having been located as " rests " in new situations.

The degree of their malignancy, from the onset of the symptoms to a fatal termination, is very great, and varies from six weeks to three years; although in some instances there has been no malignancy at all, and the tumors have been found only by accident in post mortem examination. The malignancy is shown by an invasion of the kidney and contiguous organs, or by more distant metastasis. The mode of metastasis is conceded to be by the venous circulation through the medium of the renal vein and the vena cava. Although the period between the death of the man and the presentation of this communication has been very brief, I have done all that I could to search through the literature on this subject. I have not been rewarded by finding the report of an instance where the metastasis has extended to the eye.

It is doubtful whether an accurate diagnosis of hypernephroma can be made before an exploratory operation. The most important symptoms are: hematuria, renal colic, and the detection of a tumor. All these may occur together, any one may occur alone, or, as in the case we are studying. they all may be absent. The general symptoms. consisting of asthenia, depression, and emaciation, were distinctly marked, however, in this case. I could not describe the rapid change in this man's health in other terms than by the comprehensive one of " cachectic."

It is quite impossible to guess how long the process had existed in this man. It is not unlikely that it was an hyphema that the surgeons noticed when the patient went to the Wills Hospital in 1903, and it is conceivable that such an effusion might have been caused by the lodgment of an embolus in an iridic vessel. Hypernephromata, in the sense of their being adrenal rests, may arise in early life, then lie dormant for years and develop rapidly with fatal effects after forty years of age.

The microscopic characters of the tumor and of the metastatic

deposits, described in this paper, are fairly representative of the histology of hypernephromata, and may not here enter into any discussion of the histogenesis of this class of tumors. For those who wish to investigate the subject, I will refer them to the singularly comprehensive studies of Aloysius Kelly,[3] and to the more recent contributions of Hoche,[4] Albarran and Imbert.[5] In a report of two cases by Keen, Pfahler, and Ellis,[6] a summary of the present status of the subject is given and a complete bibliography is appended to their paper.

It must be admitted that the opportunity to study this case is an unusual bit of good fortune. To all who have been associated with me in it I can only express my most sincere thanks for their courtesy to me, and for the pains they have taken in the preparation of the data. I must express my indebtedness to Professor Smith for his kindly interest and helpfulness, without which it would have been impossible to have completed this paper.

There has now been presented a complete history of a case which, at the beginning, appeared to be one of a primary tumor of the eye, with a probable convection to the internal organs. The examination after the death of the subject shows that the process was the reverse, and the further study showed that it was of unusual pathogeny, with manifestations in an organ not hitherto mentioned as having been the seat of a secondary invasion by such a tumor.

The result of this study leads me to wonder what a thorough examination of the internal organs in cases of ocular tumors with fatal metastasis might lead to if it were possible to follow the cases to necropsy. In analyzing the histories of primary tumors of the eye, the records show that it has not always been possible to do this. The relations, therefore, as to cause and effect, between the ocular tumors and the internal growths, have not in all cases been defined. May it not be true, then, that many instances

---

3 *Aloysius Kelly*: Phila. Med. Journal, July 30, 1898.
4 *Hoche*: Les Lesions Du Rein, Paris, 1904.
5 *Albarran and Imbert*: Les Tumeurs Du Rein, Paris, 1903.
6 *Keen, Pfahler, and Ellis*: Trans. Coll. of Phys., Phila., 1904, p. 251.

of so-called primary tumors of the eye, which come under the observation of the ophthalmic surgeon, and in which the opportunity for a confirmation by autopsy has been lost, are, in reality, secondary to some concealed primary growth?[7]

DISCUSSION.

DR. CLARENCE A. VEASEY, Philadelphia. I think Dr. Chance is to be congratulated upon having had the opportunity of following such an instructive case to its termination. His very excellent report seems to emphasize the importance of the question as to whether iridectomy or enucleation should be performed in cases of primary sarcoma of the iris. Some years ago I had the pleasure of studying a case of primary sarcoma of the iris which was afterward successfully removed by iridectomy, the patient maintaining 6/7 vision, and having had no recurrence ten years later. The literature of the previously reported cases was reviewed, and among them were six or eight upon whom iridectomy had been performed, with no recurrence noted in from one to six years. The conclusions were that in all small primary sarcoma of the iris, apparently involving only the iris tissue, an attempt at removal by iridectomy should first be made. Subsequently Wood and Pusey reviewed the literature and added fifteen or twenty cases. Their conclusions were that iridectomy should never be performed, but that enucleation should always be advised. In view of Dr. Chance's interesting experience it seems to me a very grave question as to whether or not the conclusions of Wood and Pusey are not correct — in other words, whether we should not always advise enucleation rather than iridectomy, because it is very difficult, and in some cases impossible, to know whether or not there is a deep-seated tumor or some secondary involvement.

---

7 Dr. Verhoeff has called my attention to the report of a case of epithelial tumor of the ciliary body, published by R. Schlipp, of Wiesbaden, in v. Graefe's Archives, 1899, vol. 48, p. 353. Schlipp presumed that he was dealing with an unusual form of endothelioma, but, studying his paper in the light of my own case, I am convinced that the tumor he described was an hypernephroma. The patient was a young girl.

A CASE OF SARCOMA OF THE CHOROID, PRESENTING SOME DIFFICULTIES OF DIAGNOSIS, TOGETHER WITH AN INTERESTING OBSERVATION UPON THE USE OF THE TRANSILLUMINATOR.

By WILBUR B. MARPLE, M.D.,
NEW YORK CITY.

The following case is reported on account of the many difficulties in the way of a positive diagnosis. A brief report of a second case is appended, showing the value of transillumination, as well as the care necessary in its employment.

The patient, Judge F., aet. 52, first consulted me on Dec. 5, 1904, and gave the following history: The vision of the right eye began to fail about a year and a half ago, and this visual impairment was accompanied by the development of senile cataract, which was mature when I first saw him. He never had any pain in the eye until four or five weeks ago, but since that time it has pained him very much,— at times, excruciatingly, so that opiates had to be given to relieve him. Since the onset of the pain, there has been no sight at all in this eye,— not even perception of light. The pain has gradually diminished during the last week, and for the last three days he has had hardly any pain, notwithstanding the fact that he has made a long railroad journey of five days from his home in Texas. There has also been now for some time a gradual diminution of vision in the left eye, which he first noticed about five months ago. For two months past he has been unable to read or write, and has had to dictate all his correspondence and papers. It was reported to me when I

first saw the patient that the ophthalmic surgeon at his home, who had had him under observation, had told him that there was a detachment of the retina in the right eye. Where it was, or how large it was, or when the diagnosis had been made, I did not know, and the total opacity of the lens, as well as the absence of any perception of light, rendered it impossible to formulate any opinion of my own as to any of these points. Having gotten this history from the patient, I proceeded to make an examination of the condition of his eyes, and found the following:

O. D. Anterior chamber shallow, cornea insensitive, pupil moderately dilated (4½ mm.), globe somewhat injected, tension + 2, at least, lens opaque, iris not atrophic. There was no perception of light, nor has there been any since the onset of the pain four or five weeks ago.

O. S. No details of the left fundus can be made out on account of the very small pupil (2 mm.) and lack of transparency of the lens. With the exception of the lens changes, the left eye presents in every way a normal appearance. Its vision is 15/200; with — 5.5 D. sph. 20/70, and the patient reads Jaeger No. 8 at 10 cm. with the naked eye which is not improved with any glass. He consulted me for two reasons; first, for the relief of the pain in the right eye, and second, to have the sight of the left eye improved. I gave him a solution containing 1 grain of eserine and 4 grains of cocaine to the ounce of water, a drop to be instilled into the right eye every two hours, and directed that hot applications be made, and that he return in twenty-four hours. The following morning the condition was unimproved, but the pain had returned and was excruciating, and I advised an immediate iridectomy.

On December 7, 1904, under ether anaesthesia, I did an iridectomy. On the following day the wound was found to be closed, though I was not quite sure whether the tension was not still somewhat increased, but he had had no more pain. The second day following the iridectomy, the tension was normal,

but the patient had had some pain during the previous night; atropine (½%) instilled. The following day the tension was normal, there had been no return of pain, though there was a small hyphaema, which was soon absorbed. There was no recurrence of pain or tension after this, and the appearance of the eye improved. Atropine was instilled daily. Examination of the left eye under cocaine mydriasis, showed a sclerosed lens, and vision the same as it was previous to the dilatation of the pupil, viz. 20/100 + with — 5.5 D. sph. The fundus was normal. I advised the extraction of the lens and he was now waiting for this operation.

The condition of the right eye, however, was not satisfactory. Notwithstanding the fact that the tension was now normal, and had been ever since the iridectomy, there was still no perception of light in this eye. Some days it would look quite white and free from irritation, but the next day it would flush up again, and there would be photophobia and lachrymation. After four weeks of such waiting,— during which time the eye would at times present almost a normal appearance, and then flush up again in a day or so,—I advised enucleation. This the patient was very loath to have done, so I sent him, with a full history of the case, to my friend Dr. D. W. Hunter, for an independent opinion. He also advised enucleation, which was done on January 10, 1905. The healing was prompt and uneventful. Subsequently (January 29th) the left lens was extracted with a small iridectomy. Later, March 15, 1905, a discission was done, and the resulting vision with correction (+ 11 D. sph. ⊂ + 3.50 D. c. 20) was 20/20 and he read with + 3 D. sph. added, No. 1 Jaeger at 30-40 cm. After the globe was hardened and divided, Dr. Dixon, the pathologist of the New York Eye and Ear Infirmary, reported that the eye contained a sarcoma of the choroid. Subsequently, sections of the optic nerve were made, and after careful microscopical examination by Dr. Dixon, it was reported that there were some cells in the sheath of the optic nerve which looked suspicious, in which opinion after

an examination, I concurred. I submitted the preparations also to my friend, Dr. F. P. Solley, one of the clinical pathologists to the Presbyterian Hospital. His report was as follows:

"The tumor is a mixed round-celled and small spindle-celled sarcoma of the choroid. The pigment is rather scanty, but some is contained in the cell-bodies as well as in the intercellular substance.

"The sclera shows no involvement. The retina is seen in contact with the surface of the tumor throughout.

"The pial sheath of the optic nerve shows in two or three situations infiltration with round and spindle-shaped cells, similar to those in the tumor. In some of these cells pigment is seen in the cell-bodies.

"In one or two places the arachnoid sheath also shows beginning involvement about the small blood-vessels.

"The foci in the pial sheath are represented in the same situations in five out of the six serial sections.

"These foci certainly seem to be metastatic deposits in the pial sheath.

"This sheath would naturally be the first to be involved, on account of its direct anatomic connection with the external layers of the choroid — from which layers sarcomata have their origin.

"The optic nerve shows congestion of the blood-vessels, proliferation of the connective tissue septa, and infiltration with leucocytes and red cells. The nerve fibres seem to be almost entirely destroyed.

"There are no deposits of new growth within the optic nerve."

The tumor springs from a broad pedicle attached between the equator of the globe and the optic nerve. Its elevation measures 12 mm. and its breadth in the broadest part, 14 mm. The iris angle is closed and the periphery of the iris is adherent to the cornea.

"The patient was informed as to the conditions present, and that all the contents of the orbit ought to be thoroughly removed. He consented to this, and on February 15th exenteration of the orbit was done, and the remnant of the nerve divided at the apex of the orbit as close to the bone as the scissors could cut. This piece of nerve, as well as the tissues of the orbit, were subsequently carefully examined by Dr. Dixon, but nothing of a pathological nature was discovered,

and he was discharged from the hospital on March 4, 1905. The orbital cavity was packed with iodoform gauze, with rubber tissue drain between the lids, and the dressing was changed every third day. When he left for his home, on March 20th, the depth of the orbital cavity had very materially diminished through the formation of granulations all over the bony surface of the orbital walls. I have heard from him this month (June, 1906); he is in perfect health, and there is no evidence of any recurrence.

REMARKS.

Whether or not one should have diagnosed a sarcoma when this patient first presented himself before me, I cannot say; I can only confess that I did not suspect a neoplasm at that time. Let us recall briefly his condition when I first saw him. There was acute glaucoma of six weeks' duration, with matured cataract, with a report that some one had once made out a detachment of the retina in this eye. But as to when this had appeared, where located, or how long, I had no information. Neither did I have any knowledge as to how much vision he had previous to the onset of the glaucoma. So far as I could make out from questioning the patient, this was about what it had been months before, or since the cataract had been mature. The fact that in his left eye he had myopia of several dioptres, made it seem not improbable that the detachment (if it really had existed in the right eye) might be due to the myopia. On the other hand, it might be argued that glaucoma in a myopic eye, unless due to a neoplasm, is infrequent. Nevertheless, I have seen one or two such cases. So far as the absence of any perception of light in the right eye was concerned, it seems to me that this phenomenon was of very little assistance, for after six weeks of acute glaucoma, with tension + 2, we would not expect any perception of light, whether there was or was not a sarcoma present. The occurrence of glaucoma in an eye, with detachment of the retina, I must confess, was the most suspicious feature of the case; but I had never seen the detachment. So that I think

that under the circumstances, even though one might suspect a sarcoma, which I did not at the time, an iridectomy was about as much as one would have been warranted in advising. As narrated, the operation put an end to the pain and restored the tension to the normal. But no perception of light returned, and the eye remained irritable and sensitive to light. So that after waiting four weeks, enucleation was performed.

I did not use transillumination in this case, and inasmuch as the growth was back of the equator of the eye, I am doubtful whether this method of examination would have given us any aid. Of course, the presence of a mature cataract makes no difference, so far as the use of the transilluminator is concerned. Lange (Zehender's Monatsbl., 1884, p. 410) was the first to suggest this method of diagnosis, though he used merely a beam of light focused on the sclera, as in oblique illumination. Then Van Reuss (Wien. Klin. Wochenschrift, 1888, No. 37) devised his lamp. Then Leber introduced his transilluminator (Heidelberg Congress, 1902, p. 319) and Sachs, a couple of years ago (Münch. Med. Wochenschrift, 1903) brought out his more powerful lamp. Last of all, Würdemann, of Milwaukee, at the recent meeting of the American Medical Association, in Boston, presented his transilluminator, and his instrument impresses me very favorably. The Sachs instrument, though very powerful, gets very warm and furthermore, is rather clumsy. Even Leber's small instrument, though much more handy, gets pretty hot. Würdemann's instrument, about the size of a lead pencil, is very handy, and does not get hot. I have tried these various instruments on a number of eyes, and have found that in the great majority of eyes, one cannot reach back of the equator. But I have found a few eyes in which I could direct the light considerably back of the equator. I have recently had a most instructive case, which has taught me that a too powerful light is sometimes a disadvantage. In fact, the powerful Sachs lamp was of no use at all. Even the Leber lamp, burning at its maximum, gave no help. Three weeks ago I saw a gentleman of this city, about 60 years

old who, on the occasion of his first visit, told me that for about a month past he had noticed that when he took his watch out of his pocket, he could not see it with his right eye as he was gazing straight forward. I found that his observation was correct, as the fields here shown will demonstrate. I found that he had a neoplasm in the upper part of the sagittal meridian of the globe. It was apparently non-pigmented or sparsely pigmented, for one could see some of the vascular-structure of the growth. Here then, thought I, is the case I have been looking for for a year past, to try the transilluminator on. The powerful Sachs instrument gave no clue at all; in other words, as the instrument was passed around the globe, back of the ciliary region, there was no difference in the brightness with which the interior of the eye was illuminated, wherever the light entered. This was a surprise to me, as was also the fact that with the Leber instrument the same state of affairs was found. However, when I pushed the slide of my rheostat back, so as to weaken the brightness of the Leber lamp more than one-half, then I found that the evidence of the instrument was most positive. That is, when the tip was brought in contact with the sclera, in the temporal or nasal region, or below, the interior of the eye was brightly illuminated, but when it was passed over the region of the neoplasm, the pupillary region at once became dark. While I was in no doubt at all as to the nature of the case with which I was dealing, it was most satisfactory to have this additional proof as to the correctness of the diagnosis. The vision of the eye was 20/15. At the time of the enucleation, June 15th, I could demonstrate to my assistants the uselessness of a very bright light, but the positive evidence which one obtained when the light was decreased more than one-half in brilliancy. So that this point it is very important to remember, viz., that a negative result with a very powerful light does not mean that there is no neoplasm; it signifies that the latter is non-pigmented or sparsely pigmented. Using a weak illumination in such a case, the testimony obtained from the instrument becomes

at once positive. After enucleation the shadow in the pupil was equally well shown when the transilluminator was passed over the seat of the neoplasm. I might say that the sarcoma in the first case was very sparsely pigmented, and would be called by some a leuco-sarcoma. While I have not yet cut the eye, I am quite certain that the neoplasm in the second case will be found to be of a similar character. (It was, W. B. M.)

DISCUSSION.

Dr. C. J. Kipp, Newark.—As of practical importance in the examination of these eyes, I would mention that when you cannot see the tumor under the detached retina I have found that direct sunlight, thrown in with a plane mirror, will often reveal it.

In regard to the enucleation in involvement of the optic nerve, in my early days in many cases I cut the nerve close and have never seen a local recurrence. I reported last year a case in which the sclera was perforated in two places and I did a simple enucleation 4 years ago; no return to date.

Dr. S. D. Risley, Philadelphia.—In view of the remark Dr. Kipp has just made, I know from a very sad experience that his fortunate result does not always follow in sarcomata. I have on two occasions, at least, seen its very rapid recurrence in the orbital tissues. While it had not perforated I found the extra-ocular tissues glued fast to the eyeball, and there was very rapid recurrence, so that the orbit had to be exenterated within a week after enucleation of the eyeball. I think we should be very careful in our prognosis where we find that there has been an extension of the growth outside the eyeball, or penetration of the sclera.

ULCERATION AND DESTRUCTION OF CORNEA CAUSED BY THE BACILLUS PYOCYANEUS.

By P. A. CALLAN, M.D.,

NEW YORK CITY.

Michael Scott, 38 years of age, came to the New York Eye and Ear Infirmary on November 3, 1905, on account of his right eye.

Patient is a boiler maker in the employ of the Standard Oil Company, and while hammering a boiler plate on November 1st, he was struck on the right eye with a small piece of the metal. Patient continued working the rest of the day, although the accident to his eye took place at 10 A. M. On the following morning, November 2d, he found the eye quite inflamed, and he sought advice at the Out-Door Department of St. Francis' Hospital, Jersey City, where a doctor removed the small foreign body from the cornea. During the day the eye became more inflamed and painful. November 3, 1905, he came to my clinic at 1.30 P. M.

Examination. Eyelids of right eye very much swollen; pus extruding between the closed lids as in gonorrhœal ophthalmia; eyeball injected, and marked chemosis. There was on the lower quadrant of the cornea a circular shaped ulceration, 3 mm. in diameter, involving the membrana propria. It was not possible to clean the ulcer, as the infiltration had already involved the surrounding unbroken cornea.

November 3, 1905. 4 P. M. Patient taken into the Infirmary and put to bed. Temperature 99.6° F. Electro-cautery applied to the ulceration. Patient not suffering much pain.

November 4, 1905. Temperature 100°. Electro-cautery

again used. Constant hot water bathing. 50% solution argyrol t. i. d. Sulph. atropine 1% t. i. d.

November 5th. Ulcus corneae spreading. Temperature 100°.

November 6th. Ulcus corneae spreading. Temperature 99.2°.

November 7th. Ulcus has practically involved entire cornea. Temperature 98.4°.

November 8th. Entire cornea sloughed except Descemet's membrane and that is ruptured at lower third. Began use of sol. dionin, 10%. Temperature normal.

November 9th
November 10th
November 11th
November 12th
} Eye becoming paler, with very little pus.

November 13th. The membrane of Descemet is quite clean. sol. dionin 10% used daily. Eye bandaged.

November 19th. Eye quiet. Scar tissue forming over Descemet's membrane.

November 21st. Eye quiet and clean. The scar tissue has formed rapidly during past week over Descemet's membrane. Quite white and opaque.

November 24th. Eye has light perception. Iris can be dimly seen at the corneal periphery, some anterior chamber.

December 4th, 1905. Patient discharged.

From the 13th of November, the eye was kept bandaged, except when sol. dionin was used twice daily. Up to the 13th, patient had constant hot bathing with atropine and argyrol used three times daily. Patient has been seen three times a week for the first two weeks after he was discharged, and the dionin and bandages used.

February 14, 1906. The cornea has not resumed its full convexity, but the clear space near the periphery is perceptibly growing larger. From week to week there is a decided rounding out of the opaque corneal tissue toward the normal form.

There are numerous fine vessels running over the scar tissue. The tension *of the globe* is the same as its fellow.

The smear taken from the ulcus corneae on his admission to the Infirmary was examined by Dr. George Sloan Dixon, who reported — Bacillus Pyocyaneus.

Dr. George Sloan Dixon, Pathologist at the Infirmary, made the following report:

"Michael Scott, ulcer of cornea. Laboratory No. 07191.

"Cultivations were begun November 9, 1905. The culture medium was agar-agar. Twenty-four hours after the first cultivation was made there appeared on the agar slant a dry growth, greenish-white in color, and the surrounding agar was pea green which in a few days changed to almost black.

"Bouillon presented a greenish tinge twelve hours after inoculation. Gelatine stab culture resulted in liquefaction.

"Cover glass preparations stained with aqueous solutions of gentian violet showed a slender bacillus singly, in pairs, sometimes threes, and in irregular masses. Other covers were stained from flagellæ by Löffler's method. Flagellæ were present.

"The bacilli were decolorized by Gram's method. No inoculation experiments were made. *Diagnosis*: Bacillus pyocyaneus."

In ophthalmology it is very seldom that the bacillus pyocyaneus is found as the cause of inflammation.

Since Ernest's[1] article in 1887, there have been but few cases recorded. Ferari[2] and Corsini. "Sur Bacillo piocianico" in 1889. Haab[3] in 1891. Sattler[4]. Report of two cases following traumatism. In both cases the cornea became necrotic, and sloughed away, resulting in panophthalmitis. In the anterior part of each vitreous chamber there was found, after enucleation, a circumscribed area of pus. Bretti reported a case with similar outcome. Herbert observed the bacillus in mild form of keratitis. McNab reports a case, and in a review of the cases

---

[1] Zeitschrift für Hygiene und Infections Krankheiten, 1887,

[2] Ferari and Corsini. Sur bacillo piocianico. Ateneo Medico Parmense. Anno 3d. Fasc. 2d, 1889.

reported casts doubt on Herbert's findings, and claims that it is highly probable that an intact cornea, or at most a very slight lesion, may result in destruction of the eye through the presence of the bacillus pyocyaneus.

It appears to me that there are too few cases on record to be absolutely sure that the bacillus means destruction of the globe even in the majority of cases. That the bacillus is very destructive to an injured eye, there can be no question. My case illustrates how an apparently trivial injury resulted in a rapid sloughing of the cornea.

BACILLUS PYOCYANEUS — ITS VIRULENCE IN THE EYE, ITS LONGEVITY, AND IMMUNITY FROM IT.

By ARTHUR E. EWING, M.D.,
St. Louis, Mo.

The first thorough investigation of the effect of bacillus pyocyaneus when introduced into the eye was reported by Sattler at the 21st meeting of the Ophthalmologischen Gesellschaft in Heidelberg, 1891. The original case was an abscess in the cornea of the right eye of a coal miner following a blow with a spall. The cornea went rapidly to destruction, panophthalmitis ensued and exenteratio bulbi was performed, the greatest care being exercised against foreign infection. In the anterior portion of the vitreous was found a small abscess from which cultures were taken that developed pure growths of b. pyocyaneus, which, when transferred to the eyes of rabbits, caused deep purulent infiltrations of the cornea in the course of twenty-four hours, the inflam-

mation reaching its height in about forty-eight hours and being followed by sloughing of the necrotic portions of the corneal tissue and by hypopyon, but not by perforation: when it was injected into the vitreous humor the result was purulent destruction of the globe. When used upon the cornea of a cat, it gave rise only to a circumscribed cloudiness.

A year later, at the 22d meeting, the same investigator gave an account of another case of injury to the eye with a flying splinter of wood, which caused no perceptible abrasion of either the cornea or the conjunctiva, but there followed an abscess of the cornea with hypopyon that half filled the anterior chamber within the next three days; on the fourth day there was incipient panophthalmitis. In the exenteration, after careful removal of the cornea, the lens was found to be intact, but in the medial anterior portion of the vitreous there was a small abscess, the contents of which yielded upon agar a pure growth of b. pyocyaneus.

Another case was reported by Dr. Bietti, Pavia, in 1899, also of injury without visible abrasion, on which was tried the sublimate sub-conjunctival injection, and later the corneal incision of Saemisch; panophthalmitis developed and the eye was lost. Herbert reported a case from Bombay in 1901 of mild keratitis in which this bacillus was found. He infected the human conjunctiva with a pure culture from the cornea with the result of small abscesses in the lids and a superficial keratitis.

In 1902 Schmidt examined 30 cases of corneal ulcer, finding in 18 of them the pneumococcus, in 2 pneumo- and diplo-bacilli, in 6 diplo-bacillus, 5 negative, and in one the b. pyocyaneus. This last was an injury by a particle from an emery wheel. When first seen there was a grayish ulcer in the lower outer portion of the cornea which measured 1.5 by 4 mm. in diameter and the iris was discolored and highly injected. The course of the ulcer, attended by the formation of hypopyon, was rapid, being in no wise checked by the galvano-cautery, the entire cornea soon becoming an opaque greenish mass. After several weeks of treatment the inflammation subsided, leaving the cornea a porce-

lain-white leucoma adherens, through which V=4/50 was obtained by means of an iridectomy. A rabbit's eye infected with cultures from the pus produced a similar ulcer.

From the University Clinic in Freiburg, McNab reports in 1903 a case in which there was no injury. Six days previous to presenting herself, the patient had noticed a slight failure in vision. At the time of the examination there was some swelling of the lids with moderate ptosis, the conjunctiva, particularly of the globe, was highly injected and oedematous, there was deep circumcorneal injection and a greenish purulent secretion; with the exception of a narrow crescent about its inner upper border 1.5 to 2 mm. wide, and this grayish, the whole cornea was involved in a yellowish-gray necrotic ulcer with deeply infiltrated margins; a hypopyon nearly filled the anterior chamber, obscuring the pupil, which was later rendered distinguishable by means of atropine. The following day the Saemisch incision was made by Dr. Stock, and a mass of thick pus evacuated, from which a rich growth of b. pyocyaneus was recovered on culture media. Further treatment in the case was steady moist compresses of oxycyanide of mercury 1-3000, and free use of scopolamin. Three days later, tenth day from the beginning of the infection, the invasion ceased and new vessels began to appear at the corneal margin; the bacilli, however, were found in cultures taken twenty-six days from the onset. After the twenty-eighth day the cornea cleared rapidly, was completely adherent to the iris and not staphylomatous. Because of increase in tension, iridectomy was performed, and motion of hand was the final visual result. A bouillon culture from the case injected into the abdomen of a guinea pig caused severe illness for four days; on the seventh day the pig was killed and a large abscess was discovered in the spleen, from which a pure culture of b. pyocyaneus was obtained. From an agar culture the cornea of one rabbit was infected, and from the same culture the anterior chamber of another, with the result that the latter eye went to destruction from panophthalmitis in forty-eight hours; in the first, the cornea became entirely necrotic in the same length of time.

Lately it has been my misfortune to meet with an example of this infection in a post office inspector who was injured by a particle flying into his left eye while on a railroad journey. The accident occurred Saturday afternoon and was followed by considerable pain through the night. The next day he consulted a physician in another city who, he states, removed the foreign body, but did no cleansing of the eye afterward. For a time there was relief from the pain. During the night it returned more violently. When first seen by me on Monday, about 42 hours from the original injury, the epithelium of the lower portion of the cornea was denuded over a space 4.5 by 5 mm., and in the center of the denuded region there was a ragged break in Bowman's membrane about 1 mm. in diameter, the edges of this break being discolored brownish, as is seen when the cornea has been burned by a spark of hot iron; about the lower margin of the denuded area there was a deep, crescentic, grayish infiltration 1.5 mm. in width; the remainder of the cornea was clear, the anterior chamber, iris and pupil were normal, and vision was normal; the lids were a little swollen, upon their conjunctival surface there was a delicate inflammatory membrane which could be wiped away readily without bleeding, and there was a moderate mucous discharge. A solution of quinia bisulphate 3% was used freely to the lids and the cornea, and this was followed by silver nitrate 0.5%, argyrol 25%, a thorough normal saline irrigation, again argyrol 25%, yolk from a fresh egg, atropine and cocaine oil solution 0.8% and externally upon the lids, ung. hydrg. amm. 4%, and a compress bandage. Excepting the silver nitrate and the quinia this treatment was repeated four times within the next six hours and every four hours during the night, almost entirely relieving the pain, but with no effect upon the spreading of the ulcer and very little effect upon the pupil, as it dilated to only 4.5 mm. during the twenty-four hours. The patient was at St. Luke's Hospital, where the service was in every respect ideally efficient. When he entered his temperature was 99°, pulse 70, respiration 26, urinalysis negative, blood examination negative, but the breath was foul and the tongue badly coated; calomel with sodium bi-

carbonate grains five each were given him. He stated that he had not been sick, in fact had been very well, but had taken more or less quinine recently because his work required him to travel in a malarious region; he was not addicted to intoxicants.

The following morning, September 26th, the lids were less swollen and there was very little discharge, but the cornea, anterior chamber and iris had become dull, the denuded epithelium extended over a space 7.5 by 8 mm. and was entirely surrounded by the gray infiltration; the vision had dropped to motion of the hand at one foot. That vision could decrease so rapidly in twenty-four hours seemed incredible until sections were made through a rabbit's eye after forty-eight hours infection; the accompanying illustration (Fig. 2) from one of these slides fully explains how easily such loss is produced. With the hope of determining the cause of the destruction, two agar cultures were taken from the secretion upon the surface of the ulcer. The quinia and silver nitrate were repeated and following them, by suggestion of Dr. Post, a 1-1000 solution of adrenalin; also the thermo-cautery was applied to the whole surface of the ulcer. The sodium chloride 0.4% irrigation, the argyrol, egg-yolk, atropia and cocaine oil and ung. hydrarg. ammoniatum applications were continued every three hours, in fact this was the routine treatment every three or four hours during the period of severe inflammation, the quinia and silver nitrate being used mornings and the adrenalin mornings and evenings. During the day the patient received thirteen grains of quinine, an effectual magnesium sulphate draught, and at night a saline enema. Slept well, no pain.

September 27th — Ulcer 10 mm. in diameter, whole anterior portion of the cornea grayish and in a sloughing condition, hypopyon 3 mm. in height. Repeated the thermo-cautery upon the newly infiltrated border. Cultures taken yesterday showed pure b. pyocyaneus. Quinine grains fifteen during the day, calomel and soda grains five each at bedtime. No pain. 28th — Entire cornea sloughing, hypopyon 3 mm. high, no pain. 29th — As yesterday, cornea yellowish-gray in color, the inflammatory mem-

brane has ceased to form on the conjunctival surface of the lids which are only moderately irritated, hypopyon 4.5 mm. high.

October 1st — Heretofore the circumcorneal injection has not been greater than that which accompanies an ordinary keratitis; today there is deep scleral injection, the hypopyon is 4.5 mm. high and does not change position. 2d — The cornea has sloughed evenly over its surface to half its thickness; about the margin there is a clear fibrinous secretion as if there were an attempt at regeneration; the hypopyon is 5 mm. high, elevated at the center and changes position; conjunctival discharge is watery, sclera more deeply injected, lids more swollen, no pain, acute perception of light. 3d — Cornea has perforated by a minute opening at the site of the injury; it is so opaque that neither the pupil nor the iris can be seen in a strong 16 candle power light focused by a 15 dioptric lens; does not flatten. 4th — Necrotic cornea remains elevated as if in a staphylomatous condition, deep scleral injection increased, in its lower outer portion the conjunctiva is moderately chemotic, moderate exophthalmos as if incipient panophthalmitis, small hernia of the iris at the lower corneal margin, acute perception of light. 5th — Hernia of the iris measures 3 by 7 mm., conjunctival chemosis less, acute perception of light. Until this morning patient's breath has been more or less foul and his tongue a little coated. He has at no time had temperature above 99.8 and usually it has been normal. 7th — No chemosis, no tendency to corneal regeneration. 8th — Necrotic cornea has nearly all come away; what remains is blackened by argyrol. 9th — Eye has been bandaged for 24 hours. The remaining trace of cornea has apparently become united with the iris and the whole has about the curvature of the normal cornea; globe more quiet, acute perception of light. 11th — No growth on yesterday's cultures. 12th — No growth on yesterday's cultures. Scarified the conjunctival surface of the upper lid with a sickle needle not everting the lid, the purpose being to obtain union of the lid with the cornea if possible, or at least to furnish nourishment to the cornea. This was done every 24th to 60th hour during the two

months that followed, and the eye was kept in a compress bandage. A very small pupil and a shallow, vesicle-like anterior chamber was obtained, and vision, 1/96. The cornea was so thin, however, and Fontana's space so thoroughly closed, that, with the repeated ruptures which took place, the anterior chamber was lost by union of the cornea with the iris, and the little pupil also became adherent. Later the iris protruded in two places, necessitating frequent tappings to coax the leucoma which was gradually forming to heal flat. In one of these tappings the lens was ruptured and came away in flocculent masses. The final result is a quiet globe with a leucoma adherens and vision motion of the hand. The accompanying illustration (Fig. 1) gives at a glance the various changes in the cornea.

My experience with the infection in trying it upon animals fully accords with that of other investigators, as may be seen from the following experiments, in the course of which something further may have been determined with regard to immunity and the length of its duration, and something also as to the life of the bacillus in its own filth. These experiments were conducted in the pathological laboratory of Washington University, where, in making them, I have been greatly aided by Professor Tiedeman and his assistant, Dr. Klenk, both of whom carefully followed and observed the work as it progressed.

Sept. 29th — Inoculated with the virus from the first culture of the 26th the eye of a guinea pig by lightly scratching the epithelium in the lower portion of the cornea. 30th — Small infected ulcer. Oct. 2d — Cornea necrotic apparently its entire thickness and over a space 3 mm. in diameter; no hypopyon. 3d — Tendency to heal. 6th — Infiltration decreasing, no hypopyon. 9th — Necrotic tissue has come away leaving the cornea deeply pitted over its centre; normal anterior chamber. 14th — Cornea very little flattened and hazy at its centre.

Also on Sept. 29th infected the eye of a rabbit by similarly abrading the epithelium of the cornea. 30th — Incipient ulcer. Oct. 2d — Superficial ulcer 3.5 mm. in diameter. 3d — Ulcer

Destruction of a human cornea by bacillus pyocyaneus following an injury.

The condition two days after the accident; the small point of injury, the area of denuded epithelium and the crescentic area of deep corneal infiltration about its lower border. Vision normal.

Third day, V—motion of hand at one foot; area of denuded epithelium increased in size and surrounded by deep corneal infiltration.

Fourth day, the destructive process advanced, extensive hypopyon.

Fifth day, the entire cornea in a necrotic condition, extensive hypopyon. On the tenth day spontaneous perforation at the site of the wound.

Eleventh day, cornea densely opaque, hernia of the iris at the lower margin.

Fifth week, small pupil connected with a shallow, bleb-like anterior chamber which did not extend to the corneal margin; elsewhere iris and cornea adherent; protrusion of the iris at either side and below. V—motion of hand at one foot.

5 mm. in diameter and deep in places, no hypopyon. 6th — Infiltration subsiding, no hypopyon. 9th — Moderate grayish infiltration. 16th — About well, region of the ulcer a little nebulous.

Oct. 6th — Infected the conjunctival sacs in the left eyes of six healthy rabbits by placing a large drop of the virus in each sac. 7th — No conjunctival irritation. 8th — One of the eyes shows a moderate conjunctivitis and a dirty yellowish infiltration of the upper portion of the cornea. 9th — With the exception of a narrow ring at the margin the whole cornea has become a yellowish mass and has broken down over the central portion, moderate hypopyon. 12th — Slough undermined and separating at the margin; cultures of the 10th show pure pyocyaneus. 16th — Cornea densely opaque. The eye later became glaucomatous due to a leucoma adherens and was enucleated.

Oct. 11th — The other conjunctival sacs of the five unaffected rabbits were smeared each with a drop of the green virus. 13th — Results entirely negative. Infected the eyes of two of the same rabbits by abrasion of the corneal epithelium over a space 1.5 by 3 mm. in the upper portion of each cornea and by injuring each upper cul-de-sac; also the conjunctival sacs of three others were freely smeared from a subculture taken Oct. 7th. 16th — Results negative. Again injured and infected two in the cornea. 19th — Results negative. Abraded the cornea of another and filled the conjunctival sac of still another. 23d — All results negative. Re-infected four of the animals, each in the cornea of one eye, by severely scratching the epithelium over a space of 1.5 by 3 mm., and the conjunctival sac of a fifth, two with the original culture of Sept. 26th, and the others with a sub-culture taken Oct. 16th. 24th — In two there was a small point of infiltration in the cornea in the region of the injury. Infected two other of the eyes in the cornea and also the cornea of a white rabbit not heretofore experimented upon, but which has been in the cage among the others.

26th — All results negative. Believing that the virus had become exhausted and needed to be rejuvenated, 1 c.cm. of a fresh

bouillon culture prepared yesterday was injected into the peritoneum of an active, healthy guinea pig. Twenty-four hours later, the pig, which had become desperately ill, and was apparently dying, was killed and examined. The peritoneum was overlaid with a thick fibrinous non-purulent membrane, at the point of the needle's entrance there were several small white nodules, the liver and lungs were highly injected and the left heart was filled with black, thickly coagulated blood. Numerous cultures were taken from the blood in the heart and from the peritoneum, and the conjunctival sac of one of the rabbits was filled with the fresh blood. This eye did not so much as become irritated. The cultures, however, were rich in their growth, and from them, two of the rabbits were freely infected in the upper portion of the cornea, and two others in their conjunctival sacs. 30th — A small central point of infection in the injured region on one of the eyes. Infected two other of the rabbits similarly in the cornea with the new virus. 31st — Ulcer of yesterday healing. One of the eyes infected yesterday moderately infiltrated. Nov. 1st — All the eyes healing. Re-infected the injured region in each eye with the new virus by pricking it thoroughly into the anterior limiting membrane. 2d — One cornea apparently deeply infected. 4th — All the eyes practically well.

Nov. 6th — With the thought that possibly a more powerful virus could be obtained from an infected rabbit, a c.cm. of rich active culture from the pig was injected into the peritoneum of the one which lost its eye on the first trial, Oct. 8th. Also infected two other of the rabbits in the cornea by severely scratching the poison in deeply. Twenty-four hours later the rabbit with the peritoneal injection was a little feverish; after forty-eight hours it was lively and active as though nothing had happened and lived for many months afterward until used for another experiment. The injured eyes of the other two were likewise practically healed. 13th — Injected into the peritoneal cavity of another of the first rabbits infected a c.cm. of a fresh bouillon culture with an entirely negative result, immediate or remote,

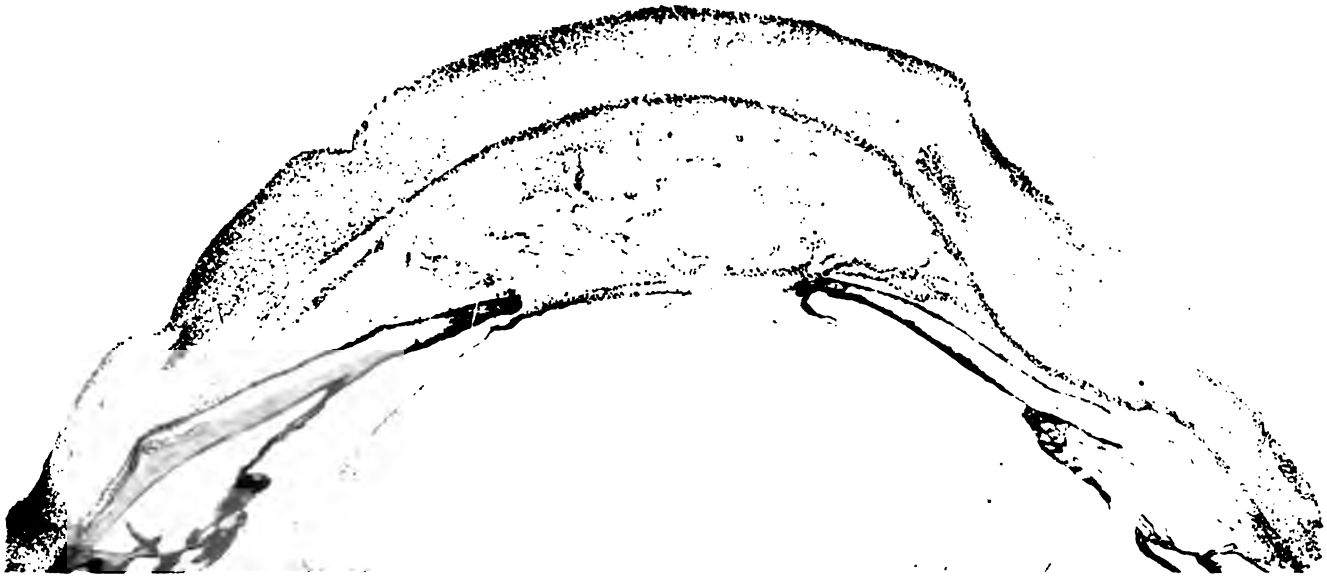

Condition of a rabbit's eye forty-eight hours after inoculation of the cornea with bacillus pyocyaneus: dense purulent infiltration of the cornea, anterior chamber filled with inflammatory exudate, iris adherent to the lens at the pupillary margin.

as the animal lived for a number of months. With the conviction that immunity had been established, it was decided to rest for a time from the experiments. Meanwhile the animals were kept well fed and in good condition.

Dec. 14th — In order to be sure that the virus was still alive and active, a twenty-four hour agar culture from a sub-culture of Nov. 4th, from the original of Sept. 26th was scratched into the upper portion of the cornea of an active, healthy rabbit not heretofore infected or exposed. Twenty-four hours later an extensive ulcer involved the whole upper portion of the cornea, which in forty-eight hours became a yellow necrotic mass and began to break down over its centre. The eye was enucleated and preserved in 10% formol. It is from this eye that the slide was prepared from which the accompanying illustration was photographed. The rapidity with which the toxine passes into the anterior part of the globe is clearly exhibited by the dense mass of fibrinous exudate which packs the anterior chamber. Cultures taken from the cornea immediately before the enucleation yielded pure b. pyocyaneus.

1906, Jan. 23d — Another trial was made upon four of the same animals by pricking into the right cornea of each of them a fresh subculture taken from the original culture. In two of these eyes there were severe ulcers within forty-eight hours, one with hypopyon, cultures from which yielded pure pyocyaneus; the other two were negative.

Except as it had been opened for making the above mentioned sub-cultures, the original tube had been sealed with paraffin and kept during the winter in an attic room where there was no heat. Cultures were again made from this tube on the thirty-first of May, 1906, which developed pure pyocyaneus, and from one of which four of the originally experimental animals were infected, each in the cornea, June the fifth. Two of these infections resulted in severe hypopyon ulcers, one in twenty-four, the other in forty-eight hours; in the third there was a marked grayish infiltration, the fourth was negative. The third day from the

inoculation, when this last one exhibited no evidence of being infected, the healing corneal wound was reopened and a fresh culture taken from the hypopyon ulcer of one of its fellows was thoroughly smeared into it; result entirely negative. June 14th — With a hypodermic needle again re-infected this eye by injecting the virus into the anterior chamber. Twenty-four hours later there was moderate haziness of the cornea, a yellowish track following the needle wound, and a flocculent grayish exudate in the lower third of the anterior chamber. A culture taken at the wound showed the following day pure pyocyaneus. At the close of forty-eight hours the cornea and anterior chamber began to clear, and, after the lapse of a week, the eye was practically well.

With regard to this bacillus these experiments seem to demonstrate upon the eyes of animals what has been shown in the cases reported by Sattler, Bietti, and McNab to have taken place in the human eye, namely, that the worst and most savage inflammation may occur in the cornea when an active culture has been placed in the conjunctival sac; such inflammation is much more likely to ensue if the cornea has been abraded. The poison is very rapid and destructive in the rabbit and the guinea pig, and probably more so in man, as all the cases in man so far reported, except those by Herbert, have ended practically in the loss of the cornea or of the globe.

Wasserman says that the bacillus yields a soluble toxine on media, and also an anti-toxine in the serum taken from animals infected with it which is effective by methods of subcutaneous injection. The above experiments indicate that placing it in the conjunctival sac may work an immunity which has a duration of six or eight weeks, and with no appreciable reaction in the animal from the inoculation.

It is recommended by the bacteriologists that cultures be renewed every two or three months in order to preserve them. The above experience is that if kept in a sealed tube at the ordinary temperature of the air, cultures taken from it may still be active and equally virulent at the end of eight months.

Surgically this has special weight in the matter of badly cleaned, or poorly sterilized instruments, when they have been used in wounds poisoned by this infection.

These results also support the idea that animals are rendered immune to infections by mild inoculations through the epithelium either of the skin or of the mucous membrane.

OPTIC NEURITIS AFTER INJURY OR DISEASE OF THE ANTERIOR HALF OF THE EYEBALL.

By ARNOLD KNAPP, M.D.,

NEW YORK CITY.

In the two following cases optic neuritis developed after a penetrating injury of the eyeball :

On July 4th, 1904, F. W., 8 years old, was struck in the eye with a blank cartridge cap. He came to the hospital one day later with a burn of the lid and a small irregular wound of the sclera in the anterior meridian about 6 mm. posterior to the margin of the cornea. The wound gapes and presents a bead of vitreous. The eye is slightly irritated. The vitreous is not quite clear. V=12/200 Sn. There is no evidence of a foreign body. The optic nerve is distinctly swollen, blurred, and the vessels are tortuous. The scleral wound gradually contracted and closed after two weeks, the eye at no time showing any pronounced signs of inflammation. The optic nerve remained about the same, then slowly returned to normal. On August 15th scar flat. Od. normal. V=20/20.

The second case was N. M., 8½ years old, seen on March 28, 1901, with a history that 3 weeks ago the right eye was injured with a stone. Ten days later a prolapse of the iris was excised. At present there is a linear scar in the lower and outer sclerocorneal junction. The iris is normal with good lustre. The media are transparent. The optic nerve is distinctly swollen and blurred and the vessels are congested. The patient was not seen again.

Optic neuritis after injury of the anterior segment of the eyeball has been repeatedly observed. One of the last cases was reported by Fehr,* who stated that this condition was first described by Hirschberg many years ago in the article on "Ophthalmoscopy" in Eulenberg's Encyclopedia, 2d edition, and was designated as "traumatic or perforative optic neuritis."

On looking over the collection of eyes which have been enucleated for traumatic cyclitis in the N. Y. Ophthalmic and Aural Institute, I was astonished to see how frequently the optic nerves were swollen.

It is moreover not unusual to find, after cataract extractions in eyes which are doing perfectly well, but remain somewhat congested (presumably moderate cyclitis), ophthalmoscopic changes in the appearance of the optic nerve indicative of optic neuritis. These changes later disappear completely.

The significance of "traumatic" optic neuritis is interesting from the following aspects. It can follow a trivial injury, that is one not associated with much inflammatory reaction. The prognosis is good as the optic nerve does not seem to suffer permanent changes. It seems in no way related to sympathetic inflammation or irritation.

As examples of optic neuritis occurring with non-traumatic iridocyclitis the two following cases may be cited:

F. E. P., 28 years of age, has been suffering from an inflammation of both eyes for some time, the left having been inflamed now for over a year and the right for five months. The patient presents the typical appearance of an iridocyclitis of a tuberculous character with exudates in the iris angles and deep corneal infiltrates. The vision is reduced in the right eye to 3/200; in the left 1/200. Right field normal, left contracted up and out. The tension is reduced in both. The right optic nerve is distinctly swollen; in the left eye no details are visible in the fundus. Under treatment the patient gradually improved and the swelling of the right optic nerve diminished. After 12 weeks the right eye was free from irritation, the exudates contracted, and the optic nerve

* Fehr, "Centralblatt für Praktische Augenheilkunde," 1903, cited by Elschnig p. 569, in "Klinische Monatsblätter für Augenheilkunde."

was practically normal. V=20/30, the left eye still affected. V=10/200.

Another case was that of C. S., age 14. Seen first on Dec. 8, 1903. 18 months ago suffered from tuberculous peritonitis. The left eye was red for a time. Improved, then became inflamed again 6 weeks ago. Now, eyeball soft and quadratic. V=3/200. Tn. There are several exudates in iris, posterior-corneal deposits, and behind iris a large exudate on the ciliary processes can be seen by oblique light. The other eye is normal. The eye was subsequently enucleated by Dr. John Dunn of Richmond, Va., to whom I am indebted for the opportunity of examining the eyeball. Microscopic examination showed in brief an active tuberculous inflammation of the ciliary processes in the inferior part of the eye with distinct tuberculous foci in the iris angle, pectinate ligament, and in the posterior layers of the cornea. The evidences of tuberculosis are limited to the anterior segment of the eye except for one minute area in the retina next to the blood vessel. The optic nerve head was very much swollen and presented the usual changes of choked disk and œdema with slight cell-proliferation in the connective-tissue septa of the optic nerve. The meningeal space is not distended; there is perhaps some cell proliferation.

Elschnig* in an article on the pathogenesis of optic neuritis in brain tumors, states that the optic disk apparently undergoes swelling on exposure to any inflammatory irritation. This is especially marked in those cases where optic neuritis follows an intra-ocular affection as an iridocyclitis, keratitis, and in the intra-ocular tumors. The only difference in the macroscopic condition between these cases and the optic neuritis occurring in brain tumor consists in the absence of the convex forward displacement of the scleral lamina which is found in the latter condition. He even states that the presence of optic neuritis is the rule in inflammatory affections of the anterior half of the eyeball.

The clinical course in the first case (the rapid recovery) and the anatomic examination of the second confirm the view that the optic neuritis is but a reaction to an inflammatory irritant (a toxin) and not an extension of the tuberculous inflammation from the

* Elschnig, "Wiener Klinische Rundschau," p. 43, 1901, No. 3.

anterior half of the eye. The importance of this both for prognosis and treatment is evident.

A CASE OF PRONOUNCED INWARD AND DOWNWARD SQUINT IN NEAR VISION, WITH BINOCULAR FIXATION AND NORMAL MUSCLE-BALANCE IN DISTANT VISION.

BY SAMUEL THEOBALD, M.D.,

BALTIMORE, MD.

Although I have for many years insisted upon the importance of testing the ocular muscle-balance for *near* as well as for distant vision, and have consistently practised what I preached, I do not recall an instance in which the results of such tests were as contradictory as in the case I am about to relate.

Miss S., a college student, 24 years of age, came to me for advice in January last. She was in a distinctly neurasthenic condition and was suffering with severe and persistent headache and asthenopia, although she was wearing, constantly, glasses which had been prescribed for the correction of her pronounced ametropic fault.

A careful test of her refraction led me to a conclusion which differed little from the finding of the physician she had previously consulted, except that I made out a somewhat greater amount of anisometropia.

The correction prescribed by me for distant vision was as follows:

L. eye — .50 s ⊂ + 2.62 c 85°.

R. eye + .62 s ⊂ + 1.75 c 85°.

The interest in the case centers in the unusual muscle-balance which the tests revealed with this correction, and, I

may add, it was practically the same with the glasses she had previously worn.

By the vertical diplopia test there was:

Exophoria at 20′ ⌒ 1½° to 0°.

Esophoria at 12″ ⌒ 8°.

By the Maddox-rod test:

Right hyperphoria at 20′ ⌒ ½° (scant).

Right hyperphoria at 12″ ⌒ 6° to 7°.

With Maddox's obtuse prism:

No hyperphoria at 20′.

The ease with which the diplopia tests were made, coupled with the existence of normal distance muscle-balance, completely misled me as to the real state of affairs in near vision. I neither suspected, nor tested for, the actual squint at the reading distance which I afterwards discovered. In consequence, I concluded that the chief source of her trouble was the remarkable heterophoric condition which the near tests revealed. I, therefore, prescribed lenses for the correction of this in short hook spectacle frames to be worn over the distance glasses in reading, writing, etc.

No benefit resulted from this, and at a subsequent examination I discovered that instead of a pronounced heterophoric condition, as I had supposed, there was, in near vision, an actual inward and downward squint of the left eye, which was in no way modified by the prismatic glasses given her.

In view of the orthophoria present in distant vision, no operative procedure seemed to me admissible. A slight modification was made in the lenses first prescribed; but, for some reason not apparent, my efforts to afford her relief were of little avail, and she was compelled to abandon her college work. So far as could be learned, her symptoms — the severe headache, neurasthenia, etc.,— could not be ascribed to any other cause than eye-strain.

REPORT OF CASES OF POLIOENCEPHALITIS SUPERIOR.

By WARD A. HOLDEN, M.D.,

NEW YORK CITY.

Three years ago I saw, with Dr. Alexander Lambert, a man of 28, weakened by alcoholic excesses, who was attacked suddenly by great weakness of the legs, a low, muttering delirium, squint, and a gradually increasing ptosis on each side. Ten days after the onset of the attack I found incomplete ptosis on each side and an inability to turn the eyes more than one cm. in any direction. The pupils, however, were of medium size and responsive, and accommodation was preserved. Three days later he died. This fatal case of bilateral ophthalmoplegia externa with weakness of the legs and delirium, seemed to be a typical case of acute alcoholic polioencephalitis superior as described by Wernicke, — an affection in which Wernicke found a hemorrhagic inflammation in the nuclear gray matter of the floor of the third ventricle and the aqueduct of Sylvius. Soon after Wernicke's first report, Wernicke, Strümpell, Oppenheim, Hoppe, Goldflam and others described cases of similar nature but chronic or stationary in course, and sometimes complicated with bulbar symptoms indicating an extension of the inflammation downward to the floor of the fourth ventricle (polioencephalitis inferior), and oculists recognized in some of these cases the condition described by Graefe in 1856, of complete paralysis of all the extrinsic muscles of each eye with preserved function of the intrinsic muscles,— a condition whose cause always remained inexplicable to Graefe, for at the autopsy made on one of his patients the expected basal tumor was not found.

There is still considerable confusion as to the classification of these cases and considerable difference of opinion as to the etiology. It is generally agreed, however, that influenza and

ptomaine poisoning often cause acute attacks which may end in recovery, and that cases of alcoholic causation are almost always fatal. But there are certainly many chronic cases in which alcohol, syphilis, and mineral poisons, the causes usually attributed, can be ruled out, and the etiology is entirely obscure.

The variations in course and symptomatology that may be found are fairly well exemplified in four cases which, through the kindness of friends, I have had the opportunity of studying recently. The simplest form of the affection from an ophthalmological standpoint is a bilateral third nerve palsy, but the complexus of symptoms in Wernicke's polioencephalitis superior is so well defined that the affection is readily distinguished from bilateral third nerve trunk involvement due to syphilitic exudation at the base, and from the nuclear palsy of tabes — the two conditions with which it might be confounded. In both these latter conditions the intrinsic musculature is involved as a rule, the fifth nerve is implicated rather than the sixth, and headache is a prominent symptom when the meninges are involved.

A summary of the four cases follows:

CASE I. M. J., a negress, aged 45, with evidences of late syphilis and a record of wood alcohol coma four years before, with a transitory left paralytic squint, was admitted to the New York Hospital, September 25, 1905, on the service of Dr. Lewis A. Conner. Two days before she felt queer and her legs became so weak that she could not stand. She had diplopia, and she talked in an excited and rambling manner. There was no vertigo or headache. The vascular tension was high and the arteries were hard. Ten days after the onset of the attack I found complete loss of mobility inward in each eye, slight limitation of mobility outward in each eye, and excessive vertical nystagmus-like twitching whenever the eyes were directed up or down. There was no ptosis and the pupils were responsive to light though slightly narrow. Accommodation, interior, and fields were normal. There was no

disturbance of sensation, no facial paralysis, no bulbar symptoms such as difficulty in speech or deglutition. The knee-jerks were exaggerated and there was a continued evening temperature of about 100°.

Two weeks after the first examination and 24 days after the onset of the attack, the condition had improved so that each eye could be turned in half way to the caruncle, mobility outward was still slightly limited, and there was still pronounced nystagmus in looking up or down. The fever and delirium continued. The ocular conditions improved slowly and two months after the onset the mobility of the eyes was normal again. The gait gradually lost its ataxic character and the mental condition improved.

In the meantime the patient had been transferred to the City Hospital and although she had apparently recovered, she was kept on Dr. Joseph Collins' service for observation. Six months after the onset of the attacks she had apoplectic attacks and died April 10, 1906, of hemorrhage from a rupture of an aneurysm of one anterior cerebral artery.

Sections through the mid-brain revealed a number of large fresh hemorrhages, but the condition of the nuclei of the third nerves has not yet been studied. This case will be reported later in greater detail by Dr. Collins and myself.

This case is to be regarded as one of subacute polioencephalitis superior in a patient having general arterial sclerosis with underlying syphilis and alcoholism. There were fever, delirium, ataxia, and paresis of all the ocular muscles except the levators, sphincters, and ciliary muscles. No other cranial nerves were involved. There was almost complete recovery and death occurred six months after the sudden onset from rupture of an aneurysm at the base of the brain.

CASE II. M. H., an unmarried woman aged 28, a servant of Irish birth, was referred to me by Dr. Joseph Collins, December 15, 1905. She was one of twelve children otherwise healthy, her mother had had no miscarriages and she had been well, except for an attack of measles, up to the time when

menstruation began. Since then she has been weak. At that time, about the age of fifteen, her upper lids began to droop and the eyeballs became immobile. At about the age of twenty-five she began to experience difficulty in swallowing and in talking. She now speaks in a whisper, is extremely diffident, unresponsive, and avoids people. Her replies are contradictory and there is such mental confusion that a clear account of her illness cannot be obtained.

There is almost complete bilateral ptosis and almost complete immobility of each eye but no anæsthesia. The pupils are of medium size, slightly unequal and irregular, and the light and convergence reflexes are very sluggish. The left knee-jerk is diminished. The fields and the optic discs are normal and there is sufficient astigmatism to account for a vision of 20/50 and Jaeger 2. each.

This then is a case of polioencephalitis superior stationary for thirteen years, to which was added three years ago a polioencephalitis inferior causing difficulty in speech and deglutition. There is almost complete paralysis of all the extrinsic muscles of the eye and glosso-pharyngeal disturbances, while the fifth and seventh nerves are not involved. No etiological moment could be discovered.

CASE III. M. A., a Hebrew tailor aged 27, was referred to the Vanderbilt Clinic, March 15, 1906, by Dr. Arnold Knapp. He was not alcoholic, he had healthy children and absolutely no signs of syphilis, but he was emaciated and anæmic and his circulation was poor. He had previously been well except for headaches toward evening, from which he had suffered for ten years,—a condition frequent enough among persons of his occupation with refractive errors. His memory is poor, his mind confused and sluggish. He had seen double for about a week. Mobility inward is wanting in each eye, mobility outward is wanting in the right and limited in the left, being accompanied here with nystagmus-like twitching. On the right side there is also slight limitation of mobility upward. There is no ptosis. The pupils are of medium size,

round and promptly responsive. Corrected vision is R. 20/20, L. 20/30, accommodation good. The left disc is pale. Shortly after the beginning of the diplopia he experienced difficulty in talking and in swallowing. On the right side there is a trace of facial paralysis. There is no disturbance of sensation. The knee-jerks are exaggerated, and there is some weakness of the legs but no Romberg. He was placed on mixed treatment. The condition changed slightly from time to time without any particular improvement. After a month he was put on tonic treatment. On May 10th his mental condition was much improved. There was no facial paralysis, no difficulty in swallowing, and the knee-jerks were normal. In the right eye there was normal mobility inward and slightly reduced mobility upward, downward, and outward. In the left eye mobility was slightly diminished upward and downward and outward. This then was a case of subacute polioencephalitis superior and inferior with normal pupils and without ptosis, proceeding to recovery. No etiological factor except anæmia could be discovered.

CASE IV. L. McC., a woman of 36, a machine operator, was referred to the Vanderbilt Clinic by Dr. Arnold Knapp, December 14, 1905. She denied syphilis and alcoholism, had no arterial sclerosis, and appeared well nourished. She had previously been healthy and recalled only a left facial paralysis twelve years before from which she recovered in a week under electric treatment. Four weeks before, the upper lids began to droop and she saw double. Soon after there was difficulty in swallowing and in talking. From the beginning she had been on mixed treatment but there had been no improvement. When examined there was incomplete ptosis on each side and loss of mobility in each eye inward, upward, and downward, with slight limitation of mobility outward and marked nystagmus-like twitching with efforts to turn either eye outward. There was no wheel rotation when an effort was made to look down, showing that the fourth nerves were affected. The pupils were of medium size, slightly irregular and slightly un-

equal. Light reaction was sluggish and convergence reaction was wanting. Vision for distance and near was practically normal. Fields and fundi were normal. There was no disturbance of sensibility, no tremor. The knee-jerks were exaggerated and there was some difficulty in walking, but no Romberg or Babinski symptoms. The patient talked in a rambling and silly manner, had no headache, and was singularly cheerful in regard to her condition. She was kept on mixed treatment for two weeks without any improvement and then passed from observation and I have been unable to trace her.

This, then, was a case of subacute polioencephalitis superior and inferior in which there were ptosis and diminished pupillary reaction although there was no paralysis of the sphincter or ciliary muscle.*

Of the etiology and treatment of this disease we have much to learn, and the careful recording of all cases of this nature by ophthalmologists who see them all sooner or later would seem to be desirable.

AN IMPROVED ELECTRIC OPHTHALMOSCOPE.

BY WILBUR B. MARPLE, M.D.,

NEW YORK CITY.

In presenting this model of an electric ophthalmoscope, I want to say that it is Dr. Dennett's ophthalmoscope with two or three modifications, but these modifications, at least, in my hands, make it a very much more useful instrument.

The difficulty I found in using Dr. Dennett's instrument, and

* Oct. 2, 1906. Seen again today there is slight nystagmus in all extreme directions and slight limitation of mobility inward in each eye. There is no ptosis. The pupils are 3.5 mm. each, round, and promptly responsive. The knee jerks are exaggerated but there is no Romberg. Vision, fields, and interior are normal. The patient has had electrical treatment and has made an almost complete recovery.

this is true also of De Zeng's, was that I did not seem to be able to direct the illumination always to that part of the fundus at which I wanted to look. Especially was this true if I endeavored to examine anything at the lower part of the fundus. I could always observe a horizontal line of shadow, beyond which I could not see, turn the instrument howsoever I might. For example, if I wanted to investigate the periphery of the lens below, to ascertain as to its transparency, I would invariably find this region in total shadow. I discovered, however, that if I held the ophthalmoscope with the handle directed horizontally to the side of the patient, then I could illuminate the lower part of the fundus all right. It was evident that the trouble was that the whole mirror was entirely below the line of vision when using it. I then began experimenting with various forms of mirror, the first shape being one with a round aperture, like the ordinary ophthalmoscope. But so much light was reflected into the observer's eye by such a mirror of the ordinary thickness, that a very unsatisfactory view of the fundus was obtained. My nephew, Professor of Physics in the University of Wisconsin, then sent me a very thin mirror, hoping that the reflection would be less from this, but I could see no practical difference. As the reflection was entirely from the upper edge of the aperture, I next cut this part of the mirror away, using a U-shaped piece of glass. With this there was no annoying reflection, and to my great satisfaction I now found that the whole fundus was illuminated, and also that I could control my illumination completely, investigating the lower part of the fundus as well as any other. To satisfy myself, I covered the two arms with blackened paper, and again found the bottom of the fundus in darkness. I then uncovered more and more of the two arms until I found just the length which gave me what I wanted, and the mirror seen in the instrument shown here is the one which gives me the best results.

There is one other feature to which I wish to call your attention, and that is the movable lamp. Dr. Dennett's latest modification has an arrangement by which you can use the lamp in two positions. But it occurred to me that it would be an improvement

if the position of the lamp could be controlled by the examiner while using the instrument. So I accordingly had an arm carried down with a small roughened knob at the end, by which the observer, when examining a patient, can slide the lamp up and down, and thus get just the kind of light which best brings out what he is looking for. One has only to use this modification once to appreciate what a great advantage it is.

It was my desire, in taking up this subject, to see if I could not get an instrument which I would use not merely when I could not use the ordinary instrument, but always. I can only say that I now rarely use anything else in my office. It is equally useful in the indirect as in the direct image. In the detection of fine opacities in the media, using the movable lamp, it is far better than the ordinary reflecting ophthalmoscope. I have had it put on my Morton ophthalmoscope, but it can be put on any instrument which any individual is accustomed to use. There is a slight defect in the illumination of the fundus corresponding to the small defect in the mirror above, but this is of very little importance, as a slight movement of the instrument brightly illuminates the part which was previously somewhat shadowed. I use the street current and a rheostat in my office, but when this is not present, this little dry cell battery is very satisfactory, and is one I have used for a couple of years, at the bedside of patients, at their homes. When working with the rheostat in my office, I can readily vary the intensity of the light while examining the patient, by pushing the rheostat slide in one or the other directions. This is a very great advantage.

As explained above, the lamp is moved up and down while using the instrument, by means of this little knob (see Figure), held between the thumb and index finger. I shall have the wires fastened to the body of the instrument, so that a pull on the wire, which sometimes occurs, will not move the lamp.

To change the lamp, if burned out, unscrew the small screw which you see, and the movable arm with lamp at the end can then be pulled clear out, when you can unscrew the burned-out lamp and put on a new one.

To use in the indirect image, hold at your usual distance for working with the inverted image; then move the rod with the lamp at end until the flame (or reflection of this) on the patient's forehead, is a long, narrow bar of light; then interpose your lens and a good inverted image of the fundus is obtained.

In the use of the ordinary reflecting ophthalmoscope, the most difficult thing to learn is the management of the illumination, and to master this thoroughly takes long practice. In my electric ophthalmoscope, the illumination takes care of itself, and this renders it especially useful to the medical man not an ophthalmologist who has occasion to use an ophthalmoscope. One of our most prominent neurologists, to whom I showed the instrument in my office, was so delighted at the facility with which he could use the instrument, that he has employed it in his office ever since.

We are, of course, partial to our own devices, but I have had several of my confrères here and in Philadelphia try my ophthalmoscope, and they are all as enthusiastic over the instrument as I am myself.

So that I am quite sure that if any one will give it a fair trial, they will appreciate its many advantages, and like myself will feel that it is something they cannot be without.

I am indebted to Mr. E. B. Meyrowitz, by whom the instrument is made, for many courtesies in carrying out my suggestions.

As stated above, my electric attachment can be put on any form of ophthalmoscope to which the individual is accustomed.

DISCUSSION.

DR. G. E. DE SCHWEINITZ, Philadelphia. By courtesy of Dr.

Marple I had an opportunity of using his ophthalmoscope for a short time in my office and in my service in one of my hospitals and all that he has said of it is in my opinion justified. I have never before used an electric ophthalmoscope that was so complete and satisfactory.

For the study of opacities in the media it is entirely satisfactory; but it has not seemed to me that with it indirect ophthalmoscopy was as readily employed as with the ordinary ophthalmoscope. Doubtless in the greater familiarity with the instrument I will secure better results. I desire to confirm what Dr. Marple has said and to congratulate him.

PRESENTATION OF A PATIENT WITH A PLEXIFORM NEUROMA OF THE ORBIT, WITH A SHORT HISTORY.*

BY HERMAN KNAPP, M.D.,
NEW YORK CITY.

The patient is eleven years old. You see extensive scars on the skin of the upper lid and the temple with slight ectropion on the right side, in consequence of two previous operations done in New York.

She came to me eighteen months ago. A soft, uneven tumor was felt under the upper wall of the orbit, encroaching somewhat on the right temple.

I opened the orbit on the inner side of the lid up to the orbital roof. An irregular convolution of white, soft cords, embedded in a viscid fluid, came forth. With a sharp spoon I scooped the whole growth *thoroughly* out. The cords looked like vermicelli. When all the tumor-mass was out I cleansed the cavity with a dentist's spiral probe, tipped with cotton wool, soaked in bichloride of hydrargyrum, 1/5000. Then I stitched the wound tight up, kept the patient in the hospital and discharged her on the fifth

* A somewhat more detailed history will be published in the *Archives of Ophthalmology.*

day, as there was no reaction at all. The fourth week after, she looked exactly as you see her now. There is no increase of scar or ectropium; the sight is not interfered with; it is normal. The eye-ball is in proper position, moves regularly with the other eye, and no diplopia has occurred.

I beg to show you the description of the plexiform neuroma in the excellent text-book on Ophthalmology by the late Prof. Panas, and the exhaustive work, in two large volumes, on the tumors of the eye, "Traité des Tumeurs de l'Oeil, de l'Orbite et des Annexes," by Dr. Felix Lagrange, Prof. agrégé d'opthalmologie à la Faculté de Bordeaux. G. Steinheil, Publisher, Paris. I brought these books here that you, with me, may by these two recent superior literary productions, acknowledge and admire not only the eminent talent, but also the phenomenal industry of the French nation, to which the world is so much indebted.

A CASE OF STEEL IN THE EYEBALL WHICH THE HAAB MAGNET FAILED TO REMOVE.

BY LEWIS H. TAYLOR, M.D.,
WILKES-BARRE, PA.

I desire to present, as briefly as possible, the history of a very interesting case of foreign body in the eye, in a patient whom I have recently seen, more than six years after the accident occurred.

A very interesting and valuable paper was read at a recent meeting of the American Medical Association, by Dr. William Sweet of Philadelphia, dealing with the final results of magnet operations in a large series of cases, and another interesting communication on the same subject by Dr. Knapp and Dr. Stoll has recently appeared in the Archives of Ophthalmology. Of this latter series my patient is No. 24. In view of these and numerous other articles it may seem a little out of place to give a history of merely one case of this nature, but I do so because of a number

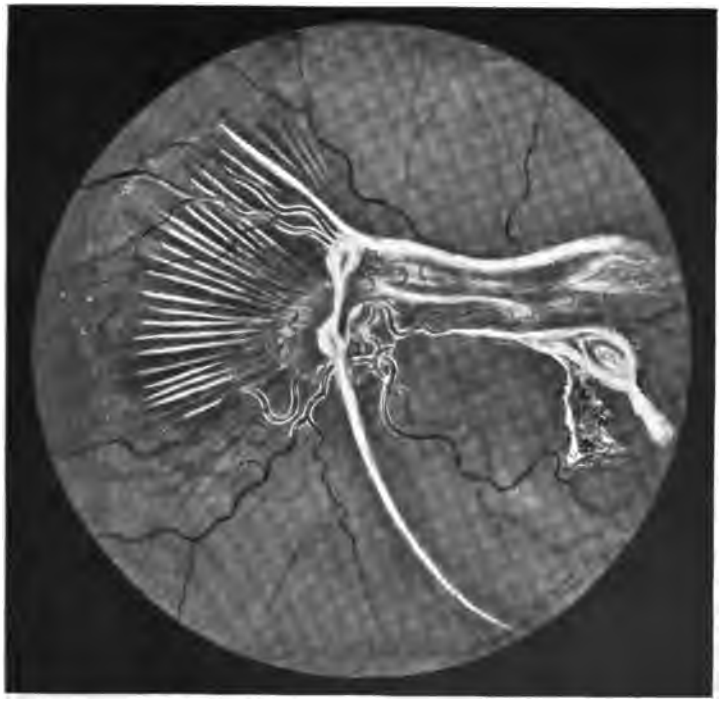

of interesting features which it presents, including a serious loss of vision and subsequent restoration of a large portion of the same, and because I am able to show you a sketch of the eye-ground as it appeared more than six years after the accident. I have recently seen a number of interesting magnet cases, but this paper deals only with the one.

H. G., aged 19, came to me December 8, 1899, with a vision of 20/XX in each eye. He was a worker in a shovel factory in a neighboring town, and had been struck in the right eye by a chip of steel a few hours before he came to my office. The steel had entered the eyeball about one-quarter of an inch to the nasal side of the cornea and near the equator. There was some subconjunctival hemorrhage and a considerable wound of the sclera. The ophthalmoscope showed that the foreign body had passed through the sclera, into the vitreous. There was some detachment of the retina, but no considerable hemorrhage, and the foreign body could be plainly seen in the back part of the eyeball. As I had no large magnet at that time I advised him to go to New York, to Dr. Knapp, in order that the Haab magnet might be used in extracting the steel. He went at once, was admitted to the New York Ophthalmic Institute the next day, December 9, and returned to Wilkes-Barre on December 15. Four trials were made with the Haab magnet to extract the steel, but without result. When the patient returned to me the vision was still 20/XX in the injured eye, though there was a considerable area of hemorrhage and detachment of retina at the nasal side. The external wound was healed. I received the following interesting letter from Dr. Knapp, under date of December 17, 1899:

"DEAR DR. TAYLOR:

Much to my regret I delayed writing you about the patient with an iron foreign body whom you were so kind as to send me. When he arrived I saw, besides the entrance wound at the inner side of the sclera on the nasal side of the background near the optic disc, an oblong shining white foreign body with sharp edges, about this apparent size and shape, in the inverted image of the ophthalmoscope. There were hemorrhages in patches and stripes in the vitreous and on the retina. I put him before a Haab magnet. He felt pain when the tip was held in contact with the nasal side of the holocainized sclerotic. The current directed to the cornea had no effect after the second application of the magnet. We

found with the ophthalmoscope that the foreign body had moved, it was still in its place in the sclera, but had turned on its axis, the slender end was sticking into the eye, and there was around the foreign body a considerable patch of fresh venous blood. A third application produced no further change. I let the patient go to bed. The next day the picture had changed. The seat of the foreign body was empty, only occupied by some coagulated blood. Supposing that it had fallen into the vitreous chamber, I looked for it all around without seeing it, then I applied the magnet. It produced no pain any more, in fact no sensation at all. With ophthalmoscope at the former seat of the foreign body there was a round perforation in the sclerotic, almost the size of the optic disc. I thought that the foreign body had been loosened by the magnet and fallen into the cellular tissue behind the eye, where it lay close to the posterior surface of the sclerotic. The magnet doubtless attracted it there too, but as it was drawn against the hard sclerotic, no pain was felt. I kept the patient in bed a few days. The conditions on inspection and magnetization were unchanged. The patient's sight was 20/XX, with a defect in the temp. side of F, from nasal detachment of the retina. The foreign body being out of harm's way, I abstained from further trials and sent the patient home. He, no doubt, has come to you. I should be greatly obliged to you for notes on his further history. The case is noteworthy and worth publishing. The statements in this letter are, of course, at your service. It would be quite interesting if the seat of the foreign body could be made out by the X-rays or sideroscope. I have the latter instrument but it is not yet put up. As to X-rays, I think Dr. William Sweet, Phila., is the man to apply to.

Yours sincerely,
H. KNAPP."

I saw the patient on December 20, and vision was still 20/XX in each eye. Following this he had a malarial attack and did not return to me until January 4, at which time vision had fallen to 20/XL and there had evidently been fresh hemorrhage. On January 16, V = 20/CC, the nerve could not be seen at all and there were large streaks of hemorrhage extending along the lower and outer part of the vitreous. On January 23, vision was only 10/CC. This gradually improved, and in the following November (19) he had vision of 20/L, at which point it has since remained. I saw the patient on the 17th of the present month (June, 1906) and find vision in OD. 20/L which is increased to 20/XL with correcting glass. He has divergent strabismus of 20° and ignores the right eye entirely in work; the left has vision of 20/XV? The fundus presents the appearance as shown in the accompanying sketch.

PLOTTING LOCATION OF FOREIGN BODIES IN THE EYE

Scale full size.

Name Harvey Garrison

Date June 27, 1906.

Size of body 4 by 1/2 by 1/2 mm.

Situation centre

24 mm. back of center of cornea.

12 mm. ~~below~~ above horizontal plane.

10 mm. to nasal side of vertical plane.

B-body

Body casts faint shadow on plate, showing that it is thin and light in weight

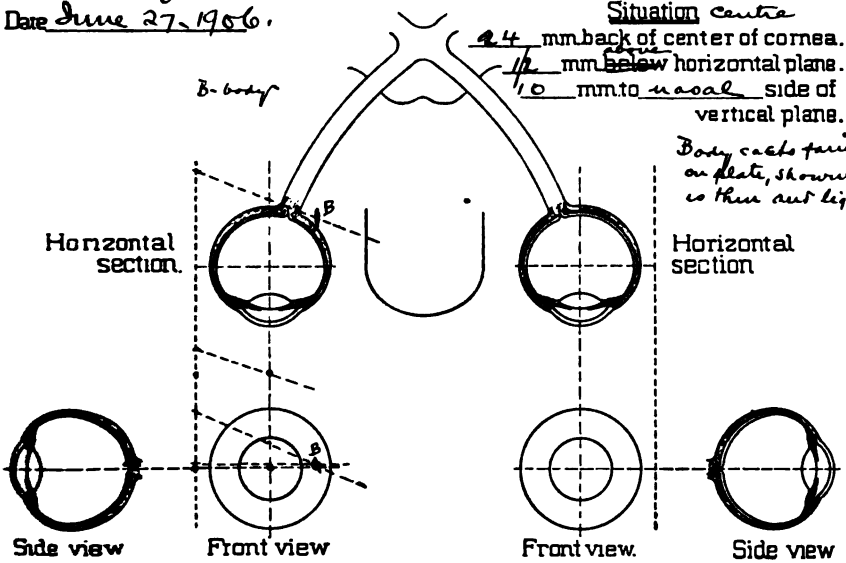

A CASE OF STEEL IN THE EYEBALL—DR. L. H. TAYLOR

This case is given as No. 24 in Knapp's Series, and the author concludes as follows:

"The three other cases, where the magnet was applied unsuccessfully, show better features. One (24) came the same day (should be the second day); the media being clear, the foreign body could be seen in the retina, surrounded by a hemorrhage. Under control of the ophthalmoscope the magnet was applied, the foreign body changed its location, could not be seen four days later, and did not produce any irritation. The eye became quiet. V = 20/XX."

This was true at the end of five days, but the subsequent history showed great loss of vision which was never fully restored, and emphasizes again the importance of later examination of these cases. What finally became of the foreign body I did not know until recently, but presumed that Dr. Knapp's surmise was correct, that it passed through the back part of the eye into the cellular tissue, where it remained quiet. Dr. Sweet of Philadelphia, has, during the present week, taken an X-ray picture and accurately located the foreign body, which, as you see in the accompanying diagram, which Dr. Sweet has kindly furnished, is just outside the sclera, where we will certainly permit it to remain.

DISCUSSION.

Dr. William M. Sweet, Philadelphia. As the foreign body was plainly seen by Dr. Knapp and Dr. Taylor near the optic nerve entrance the passage of the metal under the influence of the magnet from the background of the eye into the orbital structures close to the globe makes the case one of unusual interest. If the body, at the time of injury, had penetrated partly through the sclera, its change of position might be explained by the magnet attracting the orbital end of the metal, gradually loosening it from the sclera, and ultimately drawing it into the orbit. The point at which the tip of the magnet was applied, in contact with the nasal side of the sclera, favors this view. The radiographs show one

end of the body close to the posterior surface of the sclera, which accounts for the absence of pain upon subsequent applications of the magnet, as explained by Dr. Knapp in the report of the examination and treatment.

THE MODERN OPERATION IN FRONTAL SINUS DISEASE AFFECTING THE ORBIT, WITH TWO CASES AND TWO ILLUSTRATIONS.

BY EMIL GRUENING, M.D.,

NEW YORK CITY.

In presenting these two cases of frontal sinus disease, I would ask you to bear in mind that such cases come under the observation of the ophthalmologist when the orbit has been invaded and the disease has reached an advanced stage. The Killian operation was performed. In both, the anterior wall of the frontal sinus, the whole roof of the orbit, and the nasal process of the superior maxilla were removed; drainage was established into the nose at the time of operation through the naso-frontal duct. The wounds were closed by sutures. Healing by first intention was obtained within a week. In both cases the upper rim of the orbit was carefully preserved; this is important in order to avoid disfigurement. The photographs show that there is but a very slight depression in the forehead. The scar in the one case is merely indicated, while in the other it is scarcely visible.

It has been said that Killian's operation causes much deformity by depression of the brow, and annoying diplopia by displace-

FIG. I.

ment of the ocular muscles. Neither of these unpleasant results were observed in my cases.

CASE I. A. S., aged 18, was admitted to the Mount Sinai Hospital on February 1, 1906. His present illness began 8 days previously, with frontal headache. Two days later the left eye began to swell, and on the third day an operation was performed in one of our dispensaries, but the patient does not know exactly what was done. The eye continued to swell and the patient applied for admission to Mount Sinai Hospital.

Here it was found that the left eye was much swollen; the lid could not be raised voluntarily; the eyeball protruded and could not be moved. Ophthalmoscopic examination negative: vision good. Pus was found in the nose between the septum and the middle turbinal bone, a portion of which had evidently been removed. Examination of the pus showed streptococci present.

The operation on the frontal sinus was performed on February 2, under chloroform. An incision was made through the left brow, and down the side of the nose. The eyebrow was then shaved and the incision deepened to the bone. The periosteum was stripped back and the bone opened over the frontal sinus with the gouge. The anterior wall of the frontal sinus, excepting the rim of the orbit, was removed with a forceps. The periosteum of the roof of the orbit was carefully detached together with the trochlea, leaving the latter in place. A large quantity of pus was found in the frontal sinus. The mucous membrane was very much thickened. The diseased mucous membrane, and granulation tissue were removed. An opening was then made through the bone in the roof of the orbit, the orbital tissue being well protected with iodoform gauze. The whole orbital roof and the nasal process of the superior maxilla were then removed. Free communication was established between the nose and the naso-frontal duct. The skin was united by a number of interrupted sutures, and dry dressing applied.

At the first dressing, the next day, the wound was found clean,

with a slight discharge from the nose. The swelling of the upper lid was decidedly diminished and the eyeball was movable. Dry dressing was re-applied.

On February 4 the patient developed an erysipelas which spread over the face, but left the suture line intact, so that when the sutures were removed on the fifth day after the operation the wound was actually closed. The patient was discharged on February 12, with a satisfactory result. Photograph No. 1.

CASE II. W. E., aged 18, American, came to the New York Eye and Ear Infirmary on January 8, 1906. He suffered from intense frontal headache, and said that some operation had been performed on his nose a few days before, at some dispensary.

Examination showed that he had a large swelling extending over the whole of his forehead and involving the right eye. Palpation elicited a decided crepitation. The eyeball was inspected by lifting the lid, and ophthalmoscopic examination showed that the eye was intact, but that the motility was much impaired. A large septal perforation was found in the nose. It was impossible to decide whether this was due to an operation or to disease. There was no pus in the nose.

Operation in this case was done as in the previous one. In this instance, however, the eyebrow was shaved first and consequently there was some difficulty in following the line of the brow, and the incision was made too low.

It was found that the swelling was caused by air, and that we had to deal with a pneumatocele of the frontal sinus caused by caries sicca. The frontal bone was diseased by caries. Here, as in the other case, the rim of the orbit was preserved, but the whole anterior wall of the frontal sinus, the roof of the orbit, and the superior nasal process of the maxillary bone was removed, and the naso-frontal duct was sufficiently enlarged to establish free drainage. The mucous membrane in the frontal sinus was found everywhere detached, thickened, and rolled upon itself, the mass filling the naso-frontal duct. Final result shown in photograph No. 2.

Fig. II.

DISCUSSION.

DR. T. R. POOLEY, New York: I have done several operations of this sort and the only way in which my method differs from that of Dr. Gruening is that I introduced a drainage tube, after the curettement of the frontal and ethmoidal sinuses, into the nose and closed the wound completely, the drainage tube being subsequently removed through the nose. The cases did very well. I think the modification that Dr. Gruening thinks so good, the removal of the nasal process of the superior maxillary bone, may do away with the necessity for the drainage tube.

One thing I should like to ask Dr. Gruening; in cases of evident disease of these accessory sinuses, where the diagnosis can be made from the purulent discharge from the nose, but where there are not these eye symptoms, no diplopia, proptosis, etc., whether to relieve the headache we are warranted in making this external operation? I have seen it done in several instances and the results were not satisfactory in allaying the pain.

DR. C. J. KIPP, Newark: I have done the operation many times and have done it on both sinuses at the same time. I have left the septum between the sinuses standing to lessen deformity, but as long as the bony partition remained there is more or less discharge and now I remove it. There is always deformity in these cases.

We have tried to get radiographs in these cases in the hope of showing disease in the sinuses, and I have had a talk with the most expert men in New York and I am told that you can in many cases see at once whether there is disease or not, but that in others you can not.

DR. EMIL GRUENING, New York (closing discussion): As to Dr. Pooley's question, I have never performed this operation where there was no orbital implication. I think with the cavity washed from below, where the duct is open, there may be very often relief of the headache.

BACTERIOLOGICAL EXAMINATIONS OF THE CONJUNCTIVAL SAC IN TYPHOID FEVER AND IN PNEUMONIA.

(Based upon an examination of 100 cases of Typhoid Fever and 48 cases of Lobar Pneumonia occurring in the wards of the Johns Hopkins Hospital).

BY ROBERT L. RANDOLPH, M.D.,

BALTIMORE, MD.

The study of the bacterial flora of the conjunctival sac in health and in disease has been the subject of many investigations, but it has left still unsolved many problems of interest and importance. The nature and the mode of not a few conjunctival infections are unsettled. There are several ways by which micro-organisms can gain access to the conjunctiva, viz. (1) from the exterior either through air infection, through dust or droplets, or by direct contact. (2) from the throat and nose by way of the naso-lachrymal duct. (3) by the blood circulation either directly to the conjunctiva or by elimination of micro-organisms in the secretion of the lachrymal glands. (4) by the lymphatics, and (5) by direct extension from infection of neighboring parts. In many instances it is often difficult or impossible at present to determine by which of these various paths the infection has been conveyed.

We are also in some cases in doubt either as to the nature or the source of the specific organism concerned in the infection. Here a question of much interest relates to the relative frequency of conjunctival infections by the micro-organisms causing a primary infection elsewhere, or by secondary invaders. For a considerable number of diseases it has been demonstrated that the bac-

teria of the primary disease may cause also an associated conjunctival infection. This is true of gonorrhoea, cerebro-spinal meningitis, pneumonia, diphtheria, influenza, tuberculosis, erysipelas, pyæmia, septicæmia, bubonic plague, Malta fever, and leprosy, but in the case of some at least of these affections, a complicating conjunctivitis is due more frequently to secondary invaders than to the bacterium causing the primary disease. As regards the inflammations of mucous membranes, including the conjunctiva, which so often complicate scarlet fever, smallpox, measles and other exanthematous fevers, our inability to demonstrate satisfactorily the specific parasites of these diseases makes it impossible at present to state positively whether they are in any degree directly responsible for such inflammations. Without denying the possibility of the direct participation of these unknown micro-organisms in the complications in question, the existing evidence favors the view that secondary invaders are the chief excitants of this class of affections, streptococcus pyogenes being most frequently concerned. Other secondary invaders to be reckoned with in these cases of conjunctivitis are the pneumococcus, the pyogenic staphylococcus, the capsulated group of Friedländer, influenza and pseudo-influenza bacilli, xerosis and other pseudo-diphtheria bacilli.

It is probable in most instances that these bacteria were not at the time introduced from without, but being already present in the throat, nose or conjunctiva were enabled to multiply and produce their pathogenic effects in consequence of lowered resistance resulting from the primary infection. This latter interpretation of the facts, which is the one generally held, renders of especial interest the examination of the bacterial flora of the normal conjunctival sac.

Several years ago I reported the results of my bacterial examinations of the normal conjunctiva of one hundred persons. In 88% micrococcus albus, the ordinary skin coccus, was recovered in culture from the conjunctival sac, and subsequent examinations have convinced me that this organism is a regular inhabitant of

the normal conjunctiva. The genuine micrococcus aureus, which has been found frequently by some others in this situation I have encountered only in a small minority of cases, and I must believe that there has been some error in identification by those who claim that it is frequently present. The frequency with which certain other bacteria are found in the conjunctival sac, will doubtless depend upon the technique employed. This is true especially of influenza bacilli, the Koch-Weeks bacillus, the Morax-Axenfeld diplobacillus, certain pseudo-diphtheria bacilli and in a measure of the pneumococcus, which grow best upon media of special composition. In opposition to Gasparrini and more in accord with Oertzen, Axenfeld, Lawson and the majority of investigators, I have found the pneumococcus in only one or two per cent. of normal conjunctivæ.

As a small contribution to the solution of certain of the problems indicated I have undertaken the bacteriological examination of the conjunctival sac in a series of cases of typhoid fever and of pneumonia.

The occurrence of the typhoid bacillus in the blood, urine, sputum and fæces of patients with typhoid fever, in other words the wide distribution of this bacillus throughout the body in this disease, added to its resisting powers and ready adaptation to its environment, suggests the possibility of the occasional appearance of the bacillus also in the conjunctival sac. Conjunctivitis is a recognized complication of typhoid fever, but while the search for the typhoid bacillus is of especial interest in this complication it might readily be that the bacillus occasionally gained access to the conjunctiva without exerting any injurious effect. Although rare in contrast to otitis media, conjunctivitis is not an unknown complication of acute pneumonia.

The following method was employed in making the cultures. Through the cotton plug of a test tube containing one cubic centimeter of sterile bouillon ran a glass rod on which was tightly wrapped some cotton wool, thus making a swab. This rod with the plug was removed at the bedside and both conjunctival sacs

above and below were well swabbed, taking care not to touch the lashes and lids. Then with a pair of sterile forceps the lower end of the rod just above the swab was broken off and allowed to drop back into the bouillon at the bottom of the tube. It is hardly necessary for me to say that before the tube was opened everything within it had been thoroughly sterilized. The plug was replaced and the tube taken over to the laboratory. The usual quantity of fluid agar for a "plate culture" was poured into this tube and well shaken up and plate cultures made in Petri dishes and placed in the oven at a temperature of 35°C. to 37°C. The interval of time between inoculation of the broth and the pouring of the plates never exceeded fifteen minutes and was usually less.

In this manner inoculations were made from 100 cases of typhoid fever and 48 cases of lobar pneumonia. I might say that the cultures were never made from any but undoubted cases of typhoid, that is to say from individuals with continued fever, with "positive Widal" and with other characteristic signs and symptoms of this disease. Cases in any respect doubtful were not utilized. The predominant colony in the plates was almost always *micrococcus albus* and familiarity with its appearance obviated the necessity of making cover slips from each colony in the plate. Frequent examinations, however, were made even from these round white colonies to assure me that my interpretation was correct. Whenever a colony showed the slightest deviation from what I have learned to expect in the appearance of this organism in plate culture, cover slips were made and if necessary the organism was subjected to the proper cultural tests.

In glancing over the findings one must be surprised at the frequency with which *micrococcus albus* comes to the front. This organism occurred in the typhoid cases 59 times alone, in other words there was no other organism in the plate. It actually thus occurred oftener, for in Case 24 inoculations were made on nine different occasions and *micrococcus albus* was found 6 times while in the remaining 3 times it was found along with *micro-*

coccus aureus. The same should be said of Case 78, in which it was thought proper to make inoculations every day for three weeks. Inoculations were made from this patient 18 times and in only 4 instances did *micrococcus albus* fail to appear. Not counting these 2 cases *micrococcus albus* was found associated with bacteria in 23 cases, so that out of the 100 cases this organism was found 82 times. In 8 cases *micrococcus aureus* was found alone, while in 13 cases it was found associated with other bacteria, in 2 out of the 13 with *micrococcus albus. Streptococcus pyogenes* was found 3 times and in 2 of these cases along with *micrococcus albus.* The Morax-Axenfeld diplo-bacillus was found once and was associated with *micococcus albus.* The Xerosis bacillus was recovered 3 times and in 2 of these cases was associated with *M. albus. Bacillus pyocyaneus* occurred once. *Bacillus subtilis* occurred 4 times and in 3 of these along with *M. albus.* The plates were sterile in 2 cases and in 2 other cases impurities predominated to such an extent as to make the observation worthless. Out of the 100 cases then the conjunctival sac was found to contain bacteria in 96. What is remarkable is that the typhoid bacillus was absent throughout. There were 3 cases of conjunctivitis, and plates made from the conjunctiva showed in 2 instances *M. albus* and in the other case *M. albus* and *M. aureus.*

In the other series, 48 cases of lobar pneumonia were examined and in these cases *micrococcus albus* was found alone in 24 cases and along with other bacteria 14 times; in other words this organism was found in 38 out of 48 cases. The pneumococcus was found twice, once alone, and once along with *micrococcus albus.* Bacillus subtilis was found 3 times alone and once along with *M. albus. Micrococcus aureus* occurred 10 times, once alone and 9 times associated with *M. albus.* There were 3 sterile plates in this series. The Morax-Axenfeld diplo-bacillus was found once, and the Xerosis bacillus once. In 5 cases there was conjunctivitis, and inoculations from 3 of these 5 cases showed only *M. albus,* one showing *M. aureus,* and the remaining one the pneumococcus. In a few instances there appeared an occasional colony of some unidentified bacterium of no apparent significance.

The question naturally arose in the course of these observations whether the typhoid bacillus might not be found at some particular stage of the disease and this question was answered by making the inoculations at different stages of the fever. In one case (78) inoculations were made practically every day throughout the course of the disease, and even in convalescence, in several other cases attempts were repeatedly made to recover the organism from the conjunctival sac, but always with negative results. As regards the pneumonia cases the pneumococcus was found twice and in one of the patients its presence was associated with conjunctivitis. The conjunctival sac in pneumonia must be regarded then as a very unlikely place in which to find the pneumococcus.

My own investigations into the bacterial flora of the conjunctival sac not only in healthy individuals but in those under the influence of a general infection, as for instance typhoid, have resulted so consistently in the discovery of one organism that I am confirmed in the belief that this organism is an invariable inhabitant of the conjunctiva, and that among the defensive mechanisms either by its numerical superiority or by its products it may aid in rendering this part of the body a soil unfavorable for the growth and multiplication of those bacteria which are regarded as especially pathogenic for the eye, and which occasionally find their way into this location, oftener I believe than is generally thought. The possibility is suggested then that this organism, slightly pathogenic, and quite numerous in the conjunctival sac, gives rise to conditions which are antagonistic to such organisms, for instance, as bacillus diphtheriæ, the gonococcus, Koch-Weeks bacillus, and the organism of trachoma, whatever that may be. What a very common disease is gonorrhoea and how comparatively infrequent is gonorrhoeal ophthalmia. It can hardly be otherwise that the gonorrhoeal virus often gains access to the conjunctival sac without setting up inflammation, and it must happen that in cases of highly infectious inflammation of one eye infectious germs are often conveyed to the other eye without resulting injury. It is true, as I have

shown elsewhere, that an intact epithelium is a great safeguard against infection of the conjunctiva, but the frequency with which *micrococcus albus is* found in the conjunctival sac leads me to think that this organism in this location plays the part of an enemy to many invaders. The antagonism which exists between certain organisms or the inhibitory influence which some bacteria exert upon the growth of others is a familiar and well established fact. In this connection I am reminded of the observations of Menge and Krönig (Bakteriologie des weiblichen Genitalkanales, S. 68), who introduced into the vagina 23 times *Bacillus pyocyaneus,* 30 times *micrococcus aureus,* and 27 times *Streptococcus pyogenes.* The staphylococcus was obtained from a breast abscess, the streptococcus came from the purulent exudate found in the abdominal cavity of a woman who had died of an acute septic peritonitis. *Bacillus pyocyaneus* was obtained from green pus. There was no doubt then that these various bacteria possessed virulence and freshness in a high degree. No trace of these organisms could be found in the vaginal tract after 26 hours. The conditions then in the normal vaginal canal for the development of pathogenic bacteria are unfavorable, conditions probably due to a considerable extent to the presence in the canal of *Bacillus vaginalis* Doederlein, which organism Doederlein holds is largely responsible for the peculiar reaction of the vaginal secretion, a reaction which helps to keep sterile this part of the genital apparatus, that is to say, sterile so far as its freedom from pathogenic bacteria is concerned.

It has been observed in large obstetric wards that in women in whom the effort was made to disinfect the vaginal canal by means of the so-called chemical disinfectants fever was more often seen than in women in whom no such attempt had been made. Efforts to disinfect the alimentary canal through the same means are equally futile and when made are frequently fol lowed by distressing symptoms, and so it is with the conjunc tiva, attempts to render it sterile have failed.

CONCLUSIONS.

The bacterial flora of the conjunctival sac in typhoid fever and in pneumonia shows practically no deviation from the conjunctival flora of individuals who are in perfect health.

It does not seem unreasonable to suggest that the exposed mucous surfaces throughout the body are inhabited by bacteria which perform for their resting place functions of a protective character by making the surroundings uncongenial for bacteria of other kinds.

A CASE OF CONGENITAL DISLOCATION OF BOTH LENSES — ATTEMPTED REMOVAL BY ABSORPTION RESULTING IN FAILURE FOLLOWED BY EXTRACTION — CARD ILLUSTRATION.

By S. D. RISLEY, M.D.,

PHILADELPHIA, PA.

David K., aged 20, was brought for consultation by Drs. Kistler and Marstellar on May 12, 1906, with dislocation of both lenses upward and outward. With normal pupils the lower and inner rim of the left lens left a narrow crescent through which the fundus could be observed. On the right side, however, the lower and outer rim of the pupil coincided so closely with the border of the lens that a mere rim of reflected light from the fundus could be observed. O. D. — 8.50 D., V. = 6/XX., O. S. —8.00 D. ⌒ — 1.00 cy. ax. 90° V=1/60. The irides were tremulous. With the indirect image through the dilated pupils two images of each fundus could be distinctly seen, as shown in Fig. 1. By oblique illumination the appearance presented is admirably shown in Fig. 2.

The young man was admitted to the Wills Hospital and the attempt made to cause a notch in the lower and inner border of the left lens by discission and solution.

No sooner, however, did the point of the knife touch the lens than it was found to have so little support that it floated away from the contact as though suspended in air, and the capsule was penetrated only by making pressure with the fixation forceps below and a quick plunge with the knife. A considerable rent was made in the capsule in this manner. The only ultimate result was a gray line representing the site of the capsular wound.

This procedure was repeated four times without effecting any opacity or swelling of the lens, the capsule each time healing promptly. The lens was obviously enveloped by the vitreous so that the aqueous humor could not penetrate through the capsular rent.

A Kalt's suture was then introduced at the base of the lower and inner quadrant of the cornea, a section made within the loop of the suture, and a silver wire vectis introduced and carried upward and backward until it embraced the globular transparent lens. It was pressed forward while corresponding pressure was made with a horn spatula at the upper and outer limbus of the cornea, and with gentle traction downward, the holding suspensory ligament above gave way and the lens was delivered without accident.

A mass of consistent vitreous presented at the corneal section, but as the suture was slowly drawn home it receded and with it the slightly prolapsed iris, leaving a central round pupil.

Convalescence was without incident. The suture was removed on the third day. At the close of the first week the eye was almost white, and only a faint gray line could be seen at the site of the suture. With + 11 D. V=20/100.

Oblique illumination showed in the lower angle of the anterior chamber, and apparently attached to the perfectly healed corneal section a ragged disc of transparent capsule, or suspensory ligament, which at the moment of delivering the lens had clung to it and was cut to free the lens, and allowed to re-enter the eye.

Fig. 1.

Congenital dislocation of both lenses, as seen with the ophthalmoscope (inverted image).



Fig. 2.

Left eye, as seen with oblique illumination.

DISCUSSION.

DR. G. C. HARLAN, Philadelphia: Many years ago I removed two congenital clear dislocated lenses that were floating about in the fluid vitreous like fish in water. They could only be seen by oblique illumination. I made the ordinary incision and slipped the wire loop behind them and extracted them. I have forgotten the amount of vision exactly, but it was very satisfactory.

TRANSACTIONS

OF THE

AMERICAN

OPHTHALMOLOGICAL SOCIETY.

Forty-third Annual Meeting.

WASHINGTON, D. C., 1907.

Vol. XI, Part II.

HARTFORD:
PUBLISHED BY THE SOCIETY
1907.

BOSTON MEDICAL
14
LIBRARY

THE CASE, LOCKWOOD & BRAINARD COMPANY, PRINTERS, HARTFORD, CONN.

CATALOGUED
DEC 14 1908
E. H. B.

TABLE OF CONTENTS

Members of the society, ... 253
Minutes of the forty-third annual meeting, ... 257
The value of systematic bacteriologic and microscopic study in the treatment of gonococcal conjunctivitis; Dr. C. A. Oliver, . 263
Perivasculitis retinae; Dr. C. A. Oliver, ... 265
Vasculitis and perivasculitis; Dr. G. E. de Schweinitz, . . . 270
Recurrent conjunctivitis produced by animals; Dr. S. D. Risley, . 279
Sarcoma of corneal limbus; Dr. C. A. Veasey, ... 282
Congenital inequality of the size of cornea in normal eyes; Dr. A. A. Hubbell, ... 290
Removal of lens in high myopia; Dr. W. E. Lambert, . . . 293
Post-operative history of sixty cases of simple chronic glaucoma; Dr. C. S. Bull, ... 300
Acute inflammatory glaucoma without excavation of the papilla; Dr. Brown Pusey, ... 309
Proliferative uveitis; Dr. W. Zentmayer, ... 313
Retinitis proliferans in a detached retina; Dr. W. T. Shoemaker, . 320
A simple method of representing ocular muscle imbalance by diagram; Dr. L. Howe, ... 326
Unusual form of hereditary congenital cataract in several members of a family; Dr. B. Chance, ... 334
Vascular changes in uveal tract, retina and optic nerve in quinine blindness, and in tobacco-alcohol amblyopia, etc.; Dr. G. E. de Schweinitz, ... 337
Affections of the optic nerve during pregnancy; Dr. A. Knapp, . 359
Chronic cyanotic polycythemia: Dr. E. Jackson, ... 363
Intra-ocular tuberculosis simulating glioma of retina; Dr. S. Theobald, ... 369
Two cases of supposed intra-ocular tuberculosis; Dr. C. W. Cutler, 371
Double perforation of the eyeball by iron and steel; Dr. Wm. M. Sweet, ... 388
Double perforation of eyeball by metallic foreign body, removal with preservation of normal vision; Dr. W. E. Lambert, . . 401
Foreign body in fundus — extraction by magnet — complete post-operative aniridia — recovery; Dr. H. Woods, ... 402
Interesting cases of eye-strain; Dr. J. A. Spalding, ... 406
Case of unilateral nystagmus; Dr. F. H. Verhoeff, ... 416
Position of the ophthalmologist in the treatment of diseases of the accessory sinuses of the nose; Dr. W. C. Posey, ... 421
Acquired cataract in childhood; Dr. H. F. Hansell, ... 430
Pulsating exophthalmus, ligation of common carotid — death; Dr. E. E. Jack, ... 439
Secondary glaucoma in a curious case of keratitis; Dr. S. D. Risley, 447
A new trial frame; Dr. W. H. Wilmer, ... 452

MEMBERS

OF THE

American Ophthalmological Society. 1907-1908.

ACTIVE MEMBERS.

The (*) indicates *Associates*.

NAME.	RESIDENCE.	PLACE.
Dr. A. E. ADAMS,	44 Grand Street,	Newburg, N. Y.
Dr. J. L. ADAMS,	38 East 51st Street,	New York, N. Y
Dr. L. A. W. ALLEMAN,	64 Montague Street,	Brooklyn, N. Y.
Dr. A. N. ALLING,	199 York Street,	New Haven, Conn
Dr. G. W. ALLYN,	Empire Building,	Pittsburg, Pa.
Dr. A. ALT,	3036 Locust Street,	St. Louis, Mo.
†Dr. J. A. ANDREWS,	107 Madison Avenue,	New York, N. Y
Dr. S. C. AYRES,	4 West 7th Street,	Cincinnati, Ohio.
*Dr. C. H. BEARD,	34 Washington Street,	Chicago, Ill.
*Dr. JAS. H. BELL,	Moore Building,	San Antonio, Texas.
Dr. H. W. BRADFORD,		Wolfboro, N. H.
*Dr. GUSTAVE E. BRUÈRE,	413 Oregonian Building,	Portland, Oregon.
*Dr. WM. E BRUNER,	New England Building,	Cleveland, Ohio.
*Dr. H. D. BRUNS,	211 Camp Street,	New Orleans, La.
Dr. CHARLES S. BULL,	47 West 36th Street,	New York, N. Y.
*Dr. W. K. BUTLER,	1207 M St. N. W.,	Washington, D. C.
*Dr. W. GORDON M. BYERS,	346 Mountain Street,	Montreal, Canada.
Dr. PETER A. CALLAN,	35 West 38th Street,	New York, N. Y.
Dr. F. P. CAPRON,	118 Angell Street,	Providence, R. I.
*Dr. W. M. CARHART,	252 Madison Avenue,	New York, N. Y.
Dr. W. H. CARMALT,	87 Elm Street,	New Haven, Conn.
Dr. JOHN T. CARPENTER, JR.,	1624 Walnut Street,	Philadelphia, Pa.
*Dr. BURTON K. CHANCE,	235 So. 13th Street,	Philadelphia, Pa.
Dr. H. B. CHANDLER,	34½ Beacon Street,	Boston, Mass.
Dr. J. W. CHARLES,	509 Humboldt Building,	St. Louis, Mo.
Dr. WM. CHEATHAM,	303 West Chestnut Street,	Louisville, Ky.
Dr. F. E. CHENEY,	126 Commonwealth Avenue,	Boston, Mass.
Dr. J. H. CLAIBORNE,	34 West 36th Street,	New York City.
Dr. C. F. CLARK,	188 East State Street,	Columbus, Ohio.
Dr. DAVID COGGIN,	7 Chestnut Street,	Salem, Mass.
Dr. WM. G. CRAIG,	15 Fuller Building,	Springfield, Mass.
Dr. C. M. CULVER,	36 Eagle Street,	Albany, N. Y.
*Dr. R. J. CURDY,	301 Keith & Perry Building,	Kansas City, Mo.
Dr. C. W. CUTLER,	52 West 53d Street,	New York, N. Y.
*Dr. A. E. DAVIS,	50 West 37th Street,	New York, N. Y.
Dr. W. S. DENNETT,	8 East 49th Street,	New York, N. Y

† Temporarily residing at Santa Barbara, Cal.

Name.	Residence.	Place.
Dr. Hasket Derby,	182 Marlborough Street,	Boston, Mass.
Dr. Richard H. Derby,	113 East 71st Street,	New York, N. Y.
Dr. Lewis S. Dixon,	232 Clarendon Street,	Boston, Mass.
Dr. Alexander Duane,	49 East 30th Street,	New York, N. Y.
Dr. J. B. Emerson,	20 East 30th Street,	New York, N. Y.
Dr. Arthur E. Ewing,	2670 Washington Avenue,	St. Louis, Mo.
Dr. T. H. Fenton,	1319 Spruce Street,	Philadelphia, Pa.
Dr. George F. Fiske,	100 State Street,	Chicago Ill.
*Dr. W. H. Fox,	1826 Jefferson Place,	Washington, D. C.
Dr. Percy Fridenberg,	60 East 58th Street,	New York, N. Y.
Dr. H. Friedenwald,	1029 Madison Ave.,	Baltimore, Md.
Dr. B. F. Fryer,	Cor. 9th and Cherry Streets,	Kansas City, Mo.
Dr. G. M. Gould,	1722 Walnut Street,	Philadelphia, Pa.
Dr. H. Y. Grant,	414 Delaware Avenue,	Buffalo, N. Y.
Dr. John Green,	2670 Washington Avenue,	St. Louis, Mo.
*Dr. Allen Greenwood,	101 Newbury Street,	Boston, Mass.
Dr. Emil Gruening,	36 East 57th Street,	New York, N. Y.
*Dr. C. W. Haddock,		Beverly, Mass.
Dr. G. W. Hale,	Wilcox Building,	Nashville, Tenn.
Dr. Wm. D. Hall,	138 Marlborough Street,	Boston, Mass.
Dr. H. F. Hansell,	1528 Walnut Street,	Philadelphia, Pa.
Dr. George C. Harlan,	1515 Walnut Street,	Philadelphia, Pa.
Dr. Herbert Harlan,	516 Cathedral Street,	Baltimore, Md.
Dr. David Harrower,	9 Elm Street,	Worcester, Mass.
Dr. N. D. Harvey,	262 Benefit Street,	Providence, R. I.
Dr. H. H. Haskell,	34 Commonwealth Avenue,	Boston, Mass.
Dr. Gustavus Hay,	1 Hathaway Street,	Jamaica Plains, Mass.
Dr. Neil J. Hepburn,	317 West 23d Street,	New York, N. Y.
Dr. Ward Holden,	43 West 48th Street,	New York, N. Y.
*Dr. C. R. Holmes,	8 East 8th Street,	Cincinnati, Ohio.
Dr. E. E. Holt,	723 Congress Street,	Portland, Me.
Dr. Lucien Howe,	87 West Huron Street,	Buffalo, N. Y.
Dr. A. A. Hubbell,	212 Franklin Street,	Buffalo, N. Y.
Dr. D. W. Hunter,	80 West 40th Street,	New York, N. Y.
Dr. J. W. Ingalls,	874 Lafayette Avenue,	Brooklyn, N. Y.
Dr. E. E. Jack,	215 Beacon Street,	Boston, Mass.
Dr. Edward Jackson,	1434 Glenarm Street,	Denver, Col.
Dr. B. Joy Jeffries,	15 Chestnut St., Beacon Hill,	Boston, Mass.
Dr. W. B. Johnson,	170 Broadway,	Paterson, N. J.
Dr. H. W. Kilburn,	192 Marlborough Street,	Boston, Mass.
Dr. Charles J. Kipp,	560 Broad Street,	Newark, N. J.
Dr. Arnold Knapp,	26 West 40th Street,	New York, N. Y.
Dr. H. Knapp,	26 West 40th Street,	New York, N. Y.
Dr. Carl Koller,	681 Madison Avenue,	New York, N. Y.
Dr. Chas. W. Kollock,	Cor. Wentworth & Com'g Sts.,	Charleston, S. C.
Dr. W. E. Lambert,	47 West 38th Street,	New York, N.
*Dr. W. B. Lancaster,		Amherst, Mass.
*Dr. J. C. Lester,	179 Schermerhorn Street,	Brooklyn, N. Y.
Dr. F. N. Lewis,	616 Madison Ave., Cor. 58th St.	New York City.
*Dr. G. F. Libby,	1434 Glenarm Street,	Denver, Col.

NAME.	RESIDENCE.	PLACE.
Dr. J. A. LIPPINCOTT,	Arrott Bdg., Wood St. & 4th Av.,	Pittsburg, Pa.
Dr. F. B. LORING,	1420 K Street,	Washington, D. C.
Dr. D. B. LOVELL,	32 Pearl Street,	Worcester, Mass.
Dr. F. W. MARLOW,	731 University Block,	Syracuse, N. Y.
Dr. W. V. MARMION,	1110 8th Street, N. W.,	Washington, D. C.
Dr. W. B. MARPLE,	46 W. 53d Street,	New York, N. Y.
Dr. ARTHUR MATHEWSON,	408 5th Street,	Washington, D. C.
Dr. CHAS. H. MCILWAINE,	264 Willis Avenue,	New York, N. Y.
Dr. JNO. R. MCINTOSH,	40 Coburg Street,	St. John, N. B.
*Dr. S. C. MAXSON,	225 Genesee Street,	Utica, N. Y.
*Dr. C. H. MAY,	698 Madison Avenue,	New York, N. Y.
Dr. C. S. MERRILL,	23 Washington Avenue,	Albany, N. Y.
Dr. B. L. MILLIKIN,	1110 Euclid Avenue,	Cleveland, Ohio.
Dr. HORACE GEO. MILLER,	189 Bowen Street,	Providence, R. I.
Dr. J. LANCELOT MINOR,	14 Randolph Building,	Memphis, Tenn.
Dr. W. F. MITTENDORF,	140 Madison Avenue,	New York, N. Y.
Dr. CHARLES A. OLIVER,	1507 Locust Street,	Philadelphia, Pa.
Dr. H. S. OPPENHEIMER,	741 Madison Avenue,	New York, N. Y.
Dr. R. J. PHILLIPS,	123 So. 39th Street,	Philadelphia, Pa.
Dr. THOMAS R. POOLEY,	107 Madison Avenue,	New York, N. Y.
Dr. WILLIAM C. POSEY,	1831 Chestnut Street,	Philadelphia, Pa.
Dr. M. H. POST,	Beaum't St., cor. Wash. Av.,	St. Louis, Mo.
Dr. H. R. PRICE,	435 Clinton Avenue,	Brooklyn, N. Y.
Dr. J. S. PROUT,	26 Schermerhorn Street,	Brooklyn, N. Y.
*Dr. BROWN PUSEY,	70 Madison Street,	Chicago, Ill.
Dr. WALTER L. PYLE,	1806 Chestnut Street,	Philadelphia, Pa.
Dr. ALEX. QUACKENBOSS,	277 Dartmouth Street,	Boston, Mass.
*Dr. MCCLUNY RADCLIFFE,	1812 Chestnut Street,	Philadelphia, Pa.
Dr. ALEX'R RANDALL,	1717 Locust Street,	Philadelphia, Pa.
Dr R. L. RANDOLPH,	816 Park Avenue,	Baltimore, Md.
Dr. J. M. RAY,	423 West Chestnut Street,	Louisville, Ky.
Dr. R. G. REESE,	58 East 25th Street,	New York, N. Y.
Dr. R. A. REEVE,	48 Bloor Street East,	Toronto, Canada.
Dr. H. O. REIK,	412 Cathedral Street,	Baltimore, Md.
Dr. STEPHEN O. RICHEY,	732 17th Street,	Washington, D. C.
Dr. CHARLES E. RIDER,	53 South Fitzhugh Street,	Rochester, N. Y.
Dr. WHEELOCK RIDER,	53 South Fitzhugh Street,	Rochester, N. Y.
*Dr. G. O. RING,	1900 Chestnut Street,	Philadelphia, Pa.
Dr. H. W. RING,	187 Church Street,	New Haven, Conn.
Dr. SAMUEL D. RISLEY,	1728 Chestnut Street,	Philadelphia, Pa.
Dr. EDMUND C. RIVERS,	1632 Welton Street,	Denver City, Col.
Dr. WM. K. ROGERS,	188 East State Street,	Columbus, Ohio.
Dr. D. B. ST. JOHN ROOSA,	20 East 30th Street,	New York, N. Y.
Dr. DUNBAR ROY,	Grand Opera House Block,	Atlanta, Ga.
Dr. JOHN D. RUSHMORE,	129 Montague Street,	Brooklyn, N. Y.
Dr. ROBERT SATTLER,	7th and Race Streets,	Cincinnati, Ohio.
Dr. T. B. SCHNEIDEMAN,	1831 Chestnut Street,	Philadelphia, Pa.
Dr. G. E. DE SCHWEINITZ,	1705 Walnut Street,	Philadelphia, Pa.
Dr. P. N. K. SCHWENK,	810 North 7th Street,	Philadelphia, Pa.
*Dr. JOHN R. SHANNON,	25 W. 36th Street,	New York, N. Y.

Name.	Residence.	Place.
Dr. Henry L. Shaw,	19 Commonwealth Avenue,	Boston, Mass.
*Dr. H. G. Sherman,	736 Rose Building,	Cleveland, Ohio.
Dr. Wm. T. Shoemaker,	2031 Chestnut Street,	Philadelphia, Pa.
Dr. Wm. A. Shoemaker,	1006 Carlton Building,	St. Louis, Mo.
*Dr. E. A. Shumway,	2007 Chestnut Street,	Philadelphia, Pa.
Dr. F. D. Skeel,	58 E. 25th Street,	New York, N. Y.
Dr. J. A. Spalding,	627 Congress Street,	Portland, Me.
Dr. Myles Standish,	6 St. James Avenue,	Boston, Mass.
*Dr. E. W. Stevens,	421 McPhee Building,	Denver, Col.
Dr. George T. Stevens,	22 East 46th Street,	New York, N. Y.
Dr. Edw. Stieren,	Westinghouse Building,	Pittsburg, Pa.
Dr. Samuel B. St. John,	68 Pratt Street,	Hartford, Conn.
Dr. Geo. Strawbridge,	202 So. 15th Street,	Philadelphia, Pa.
Dr. T. Y. Sutphen,	999 Broad Street,	Newark, N. J.
Dr. Wm. M. Sweet,	1205 Spruce Street,	Philadelphia, Pa.
Dr. Lewis H. Taylor,	83 South Franklin Street,	Wilkes-Barre, Pa.
Dr. Samuel Theobald,	304 West Monument Street,	Baltimore, Md.
Dr. Ch. Hermon Thomas,	3634 Chestnut Street,	Philadelphia, Pa.
Dr. A. G. Thomson,	1426 Walnut Street,	Philadelphia, Pa.
Dr. Edgar S. Thomson,	19 E. 44th Street,	New York, N. Y.
Dr. William Thomson,	1426 Walnut Street,	Philadelphia, Pa.
Dr. Jas. Thorington,	120 South 18th Street,	Philadelphia, Pa.
*Dr. H. H. Tyson,	47 West 51st Street,	New York, N. Y.
Dr. John Van Duyn,	318 James Street,	Syracuse, N. Y.
Dr. C. A. Veasey,	1833 Chestnut Street,	Philadelphia, Pa.
Dr. F. H. Verhoeff,	101 Newbury Street,	Boston, Mass.
Dr. O. F. Wadsworth,	526 Beacon Street,	Boston, Mass.
Dr. F. L. Waite,	68 Pratt Street,	Hartford, Conn.
Dr. David Webster,	308 Madison Avenue,	New York, N. Y.
Dr. J. E. Weeks,	46 East 57th Street,	New York, N. Y.
*Dr. Cassius D. Westcott,	31 Washington Street,	Chicago, Ill.
Dr. J. A. White,	200 E. Franklin Street,	Richmond, Va.
Dr. W. H. Wilder,	103 State Street,	Chicago, Ill.
Dr. Chas. H. Williams,	1069 Boylston Street,	Boston, Mass.
Dr. Wm. H. Wilmer,	1610 I Street N. W.,	Washington, D. C.
Dr. F. M. Wilson,	834 Myrtle Avenue,	Bridgeport, Conn.
*Dr. J. Scott Wood,	172 Sixth Avenue,	Brooklyn, N. Y.
*Dr. William L. Wood,	412 Oregonian Building,	Portland, Oregon.
Dr. Hiram Woods,	842 Park Ave.,	Baltimore, Md.
Dr. J. P. Worrell,	20 South 7th Street,	Terre Haute, Ind.
Dr. S. Lewis Ziegler,	1625 Walnut Street,	Philadelphia, Pa.
*Dr. Wm. Zentmayer,	1819 Spruce Street,	Philadelphia, Pa.
Total,	. . . . .	178

HONORARY MEMBERS.

Dr. F. P. Sprague, .	229 Commonwealth Avenue,	Boston, Mass.
Whole number,	. . . . .	179

MINUTES OF THE PROCEEDINGS.

FORTY-THIRD ANNUAL MEETING.

ARLINGTON HOUSE,
WASHINGTON, D. C., May 8, 1907.

The Forty-third Annual Meeting of the Society was called to order at 10 A. M. by President C. J. Kipp, who announced the following committees:

On Bulletin — Drs. C. W. CUTLER and A. KNAPP.

On Membership for next year — Drs. G. C. HARLAN, MYLES STANDISH, D. HARROWER, D. W. HUNTER, and E. GRUENING.

Auditing Committee — Dr. C. A. OLIVER.

The Committee on Bulletin reported and the following papers were read:

1. "The value of systematic bacteriologic and microscopic study in the treatment of gonococcal conjunctivitis," Dr. C. A. Oliver.

2. "A rare case of perivasculitis retinæ in a young woman — the subject of inherited syphilis," Dr. C. A. Oliver.

3. "Vasculitis and perivasculitis followed by proliferating retinitis," Dr. G. E. de Schweinitz.

4. "Two cases of recurrent conjunctivitis, one produced by exposure to the emanations of a horse, the other by a cat," Dr. S. D. Risley.

Discussed by Drs. Jackson, Pyle, and Posey.

5. "Melanotic sarcoma of limbus," Dr. C. A. Veasey.

Discussed by Drs. Jackson, Sutphen, Holmes, Allyn, Sherman, Marple, and Veasey.

6. "Cases of congenital inequality in size of the corneæ in normal eyes," Dr. A. A. Hubbell.

7. "Report of removal of lens in four cases of high myopia," Dr. W. E. Lambert.

Discussed by Drs. Wilmer, Jackson, and Risley.

8. "The post-operative history of sixty cases of simple chronic glaucoma" (second series), Dr. C. S. Bull.

Discussed by Drs. Risley, Jackson, de Schweinitz, Howe, Clark, Marple, and Bull.

9. "Glaucomatous excavation of the lamina cribrosa without excavation of the papilla and with marked papillitis in a case of acute glaucoma," Dr. Brown Pusey.

10. "Uveitis proliferativa (Fuchs)," Dr. Wm. Zentmayer.

Discussed by Dr. Pusey.

11. "Retinitis proliferating in character in a detached retina of traumatic origin," Dr. W. T. Shoemaker.

Adjourned for executive session.

May 9. Called to order at 10 A. M.

12. "A simple method of representing by diagrams, different forms of ocular muscle imbalance," Dr. L. Howe.

13. "An unsual form of hereditary congenital cataract," Dr. B. Chance.

14. "Concerning the vascular changes in the retina and optic nerve in the toxic amblyopias," Dr. G. E. de Schweinitz.

Discussed by Dr. Holden.

Dr. Eagerton of Newark was invited as guest of Society to take part in the discussions.

15. "Affections of the optic nerve during pregnancy, not dependent on nephritis," Dr. A. Knapp.

Discussed by Dr. Posey.

Drs. Chisholm of Baltimore, and M. B. Kelly of Wheeling, W. Va., were invited to sit as guests of the Society.

16. "Ocular lesions of cyanotic polycythæmia," Dr. Jackson.

Discussed by Drs. de Schweinitz and Holden.

Dr. N. B. Potter of New York City was invited to sit as guest of the Society.

17. "Case of intra-ocular tuberculosis closely simulating glioma of retina," Dr. S. Theobald.

18. "Preliminary report of two cases believed to be intra-ocular tuberculosis; 1st. Tumor of choroid; 2d. Relapsing plastic choroiditis," Dr. C. W. Cutler.

Discussed by Drs. Potter, Duane, Gruening, and Verhoeff.

Drs. F. Park Lewis of Buffalo and Andrew Timberman of Columbus, O., were invited to sit as guests of the Society.

19. "Double perforation of eyeball by metallic foreign bodies with report of cases," Dr. W. M. Sweet.

20. "Double perforation of eyeball by metallic foreign bodies with removal and preservation of normal vision," Dr. W. E. Lambert.

Discussed by Dr. Theobald.

21. Penetrating wound in ciliary region — magnet operation with total destruction of iris — vision preserved — exhibition of patient," Dr. H. Woods.

Discussed by Drs. Gruening, Johnson, Risley, and Maxson.

Dr. E. U. Buckman invited to sit as guest of the Society.

22. "Interesting cases of eyestrain," Dr. J. A. Spalding.

Discussed by Drs. Lambert, Allyn, and Posey.

23. "Case of unilateral nystagmus benefited by treatment," Dr. Verhoeff. (Read by title.)

24. "Position of the ophthalmologist in the treatment of diseases of the accessory sinuses," Dr. W. C. Posey.

Discussed by Drs. Gruening and Sherman.

25. "Pulsating exophthalmos—ligation of carotid — death," Dr. E. E. Jack.

26. "Acquired cataract in childhood," Dr. H. F. Hansell. (Read by title.)

27. "Pathological findings in a curious case of keratitis," Dr. S. D. Risley.

Adjourned to executive session.

Executive Session, Wednesday, May 8th.

Report of Treasurer, endorsed by the Auditing Committee as correct, was read, accepted, and ordered on file.

Voted, that the assessment for the ensuing year be $5.00.

The Secretary read letters of resignation from Drs. H. G. Miller, G. Hay, and Jno. Green. After some debate it was voted to lay the resignations on the table until some other motions were disposed of. The question of establishing a class of members emeritus was discussed and it was finally referred to the membership committee to report at the next session.

The Committee on Membership reported in favor of the election of the following candidates who were subsequently declared elected:

Dr. Wm. Evans Bruner, Dr. A. E. Davis, Dr. C. H. Beard, Dr. Geo. F. Libby, and Dr. C. H. May.

Several names previously proposed were referred to the Committee of 1908.

The Committee also presented the following nominations for officers for the ensuing year:

President — Dr. S. D. RISLEY, Philadelphia.

Vice-President — Dr. JNO. GREEN, St. Louis.

Recording Secretary and Treasurer — Dr. S. B. ST. JOHN, Hartford.

Corresponding Secretary — Dr. J. S. PROUT.

Publication Committee — Drs. W. S. DENNETT and D. W. HUNTER and the Secretary (ex officio).

Several names of candidates for membership were read by the Secretary and referred to the Membership Committee for 1908.

Dr. Howe presented a resolution regarding the control of blindness from ophthalmia neonatorum, and a committee consisting of Drs. Howe, Jackson, and Callan was appointed to consider the best form of action for the Society to take.

Voted, that the Secretary be empowered to collect the registration fee of the Congress ($5.00) from such members of the American Ophthalmological Society as may have attended the Congress and failed to register as members of the Congress.

The Secretary presented a resolution endorsing the establishment of a National Board of Health. Adopted.

Executive Session, May 9th.

The Executive Committee, to whom was referred the question of establishing a class of members emeritus reported in favor of such action, but on motion of Dr. Jackson the Society accepted the following as a substitute motion:

"All members of twenty years' standing shall be exempt from the action of the by-law requiring attendance at the meetings."

Dr. Howe offered an amendment to Standing Rule No. 3, omitting the final clause "so far as practicable." This was adopted, on motion of Dr. de Schweinitz.

Drs. Callan, Marple, and de Schweinitz were appointed a committee to confer with the committee from the Otological Society as to the time and place of the next meeting, and the committee was instructed to select some watering place or health resort as the place and a date either in the month of June, July, or August, and, if possible, in the same week selected by the Otological Society.

S. B. St. John, *Secretary,*
American Ophthalmological Society.

Members present at the Forty-third Annual Meeting:

Dr. Jno. C. Lester,
Dr. W. E. Lambert,
Dr. S. C. Maxson,
Dr. Allen Greenwood,
Dr. N. J. Hepburn,
Dr. Arnold Knapp,
Dr. F. B. Loring,
Dr. C. A. Oliver,
Dr. W. B. Johnson,
Dr. C. J. Kipp,
Dr. H. Friedenwald,
Dr. C. A. Holmes,
Dr. C. A. Veasey,
Dr. Geo. Strawbridge,
Dr. J. R. Shannon,
Dr. E. E. Jack,
Dr. C. S. Bull,
Dr. W. A. Shoemaker,
Dr. Edward Jackson,
Dr. W. G. M. Byers,
Dr. J. A. White,
Dr. A. A. Hubbell,
Dr. Myles Standish,
Dr. W. H. Fox,
Dr. W. C. Posey,
Dr. J. M. Ray,
Dr. G. W. Allyn,
Dr. W. L. Pyle,
Dr. W. B. Marple,
Dr. F. M. Wilson,
Dr. L. Howe,
Dr. L. H. Taylor,
Dr. G. W. Hale,
Dr. H. Harlan,
Dr. C. W. Cutler,
Dr. S. B. St. John,
Dr. G. E. de Schweinitz,
Dr. Wheelock Rider,
Dr. H. O. Reik,
Dr. A. Mathewson,
Dr. W. V. Marmion,
Dr. W. H. Wilmer,
Dr. Wm. M. Sweet,
Dr. S. D. Risley,
Dr. W. K. Butler,
Dr. T. Y. Sutphen,
Dr. H. R. Price,
Dr. R. J. Phillips,
Dr. R. A. Reeve,
Dr. J. W. Charles,
Dr. C. T. Clark,
Dr. A. G. Thomson,
Dr. H. F. Hansell,
Dr. J. Scott Wood,
Dr. J. W. Ingalls,
Dr. J. A. Spaulding,
Dr. Alex Duane,
Dr. J. L. Adams,
Dr. H. G. Sherman,
Dr. Wm. Zentmayer,
Dr. R. J. Curdy,
Dr. D. W. Hunter,
Dr. E. Gruening,
Dr. S. Theobald,
Dr. Wm. T. Shoemaker,
Dr. Geo. F. Fiske,
Dr. B. Alex Randall,
Dr. S. Lewis Ziegler,
Dr. H. W. Kilburn,
Dr. Burton Chance,
Dr. H. H. Haskell,
Dr. F. H. Verhoeff,
Dr. H. Woods,
Dr. E. A. Shumway,
Dr. H. H. Tyson,
Dr. W. H. Carmalt,
Dr. Brown Pusey,
Dr. W. A. Holden.

THE VALUE OF SYSTEMATIC BACTERIOLOGIC AND MICROSCOPIC STUDY IN THE TREATMENT OF GONOCOCCAL CONJUNCTIVITIS.

By CHARLES A. OLIVER, A.M., M.D.,
PHILADELPHIA, PA.

The object of this brief paper is to emphasize the value of bacteriologic study for the purpose of regulation of therapy during the treatment of gonococcal conjunctivitis.

For several years past I have had both rough smear and most careful stain studies made not only for the only certain diagnosis of the disease, but during the daily progress. As a result — early learned — it has been found that the most virulent types of cases can be governed more easily, the milder forms more speedily bettered and cured, and the apparently clinically insignificant ones quickly and permanently gotten rid of: thus in great measure, accounting for the good results which I have obtained in a great number of cases seen in the eye wards of the Philadelphia General Hospital during a period extending over ten years' time.* the special methods of treatment which I have employed have been so fully spoken of in the discussion upon "gonorrheal ophthalmia" at last year's meeting of the society † that they are omitted in this communication.

After many vexatious and apparently useless and time-consuming methods, the following plan was fully established, and at present, is enforced during my terms of service. Daily or triweekly studies are made by either the bacteriologists to the institution or competent residents, and written reports for inspection by those in medical attendance upon the cases are sent to the special wards devoted to the same. These results are daily

* The statistical results have been prepared by Dr. Froesceln, the assistant chief physician of the hospital, for publication by myself elsewhere.

† See 1906 "Transactions of the American Ophthalmological Society."

reported either to myself or to my assistant — Dr. Jay C. Knipe. From the findings we decide as to continuance or change of treatment. In dubious cases, the residents (who almost without exception, grow deeply interested in the daily results), bring the actual specimens to us for decisions as to condition and final provings.

As a routine the following rules are observed:

I. No case is considered specifically certain in character until bacteriologic study has proved the presence of the special type of offending germ life.

II. In each case, not only is the presence of the special form of floral cells considered, but their conditions and numbers, their relations to associated germs, and their exact and relative localities, are all taken into account.

III. In every instance, careful consideration is given to the character, the degree, and the amount of the protecting faunal cells, particularly in their relationships with all of the different forms of attacking cells.

IV. In every case possible, the state of the resultant débris is searchingly inquired into — both just before the use of the destructive therapeutic agents, and soon after.

V. No case is removed from isolation, no guard over treatment is discontinued, and no relinquishment of the measures which seem to be the most applicable in each individual instance is counterbalanced in any way, until, at least, three successive and simultaneous negative results as to the presence of gonococci in both eyes, have been obtained and decided upon by those who are competent to judge.

VI. Whenever possible, every purely local eye case is, even when apparently cured of the ocular expressions of all of the gross forms of dangerous mixed infections, strictly watched and kept in surveillance until every external evidence of the presence of any of the dangerous types of offending germ life with the microscope, has disappeared for a proper period of time (as a rule for about three or four weeks' time).

VII. Every self-infected case is sent to one of the other appropriate departments of the hospital for both general and special study, and is given treatment whenever necessary.

A RARE TYPE OF PERIVASCULITIS RETINAE IN A YOUNG WOMAN — THE SUBJECT OF INHERITED SYPHILIS.

BY CHARLES A. OLIVER, A.M., M.D.,
PHILADELPHIA, PA.

On the eleventh of April, 1898, through the kindness of Dr. George R. Rohrer, of Lancaster, Pennsylvania, I was permitted to study the eyes of C. M. M., a twenty-two year old single woman. Dr. Rohrer first saw the patient when she was eight years old. At that time, careful estimation of refraction with duboisia-cycloplegia gave normal vision in each eye.

Six years later he made note that the fundus of the right eye showed old spots of absorption due to retinitis. Three years after this, he found that corrected vision with the right eye had fallen to two-sevenths of normal, and that there were marks of old and new hemorrhages in the retina. In one year's time, the vision of the right eye had increased to one-half of normal; three years after this, it had receded to two-fifths. The left eye, which always had had good sight, never evidenced any local trouble.

At the time of my first examination of the case, I found the remarkable picture shown in Figure 1 which was carefully and accurately sketched for me by Miss Margaretta Washington. The left eyeground failed to exhibit anything abnormal except a slight thickening of the superficial layers of the retina in and around the macular region.

Dr. Rohrer informed me that the patient's father had had his eyes examined by Dr. Henry S. Schell, and that Dr. Schell had given him the following notes of the case: "O. S. vitreous full

of shreds; disc whitish, with remains of tissue proliferation at edges; eye becoming myopic. O. D. disc also ill-defined; hypermetropia." . . . . "Thinks there has been basilar meningitis." The man — who was a physician — "had had epileptic seizures for three or four years and was obliged to give up practice."

When I first saw the patient, she stated that twelve years before she saw me, her father had consulted Dr. William F. Norris for his eyes, and that a diagnosis of tumor of the brain was made. The patient was ill for four years, dying at thirty-five years of age. One year before death, Dr. Rohrer obtained similar findings. Both Dr. S. Weir Mitchell and Dr. William H. Hammond made an ante-mortem diagnosis of syphilitic brain tumor which was proved at autopsy.

Her mother, who was forty-six years of age and had always seemed healthy, wore glasses for presbyopia. The patient had two sisters — one older, and the other, younger; both of them wore glasses for farsightedness and astigmia. One brother, the youngest of the family, had never had any eye trouble. All of these cases had been examined by Dr. Rohrer, who did not find any specific stigmata.

The face, the skull, and the teeth (Hutchinsonian in character), of the patient, though not pronounced, were characteristic of hereditary syphilis. Careful correction of the total error of refraction with scopolamine-cycloplegia (O.D. + S. 2.25 D. ⌣ + C. 0.37½ D. ax. 150°. and O.S. + S. 1.75 D. ⌣ + C. 1. D. ax. 30°), gave a vision of one-half of normal with the right eye, and of normal with the left. These lenses constantly worn, quickly allowed binocular fusion and removed a medium grade of manifest exophoria and a slight left superior hyperphoria for both near and far, which had been previously corrected in measure by a tilting of the head and a tiresome twist of the right eye that had been empirically determined by the patient.

One year ago, during my summer vacation, the patient wrote to me for re-examination of her refraction error; I have not heard from her since.

PERIVASCULITIS RETINAE

REMARKS. The case is interesting from both its subjective and its objective standpoints.

SUBJECTIVE.

1. The nondisturbance of the central negative scotomata. This is probably due to their faintness and their relative inequalities in intensity; particularly when the best and the most comfortable binocular fusion could be obtained by throwing the least injured, slightly excentric, part of the right retina into simultaneous fixation with the relatively uninjured macular region of the left eye.

2. The nondisturbing qualities of the two physiologic blind spots in spite of their necessarily marked increases in size. (See figures 2 and 3, showing the right and the left fields of vision for red.)*

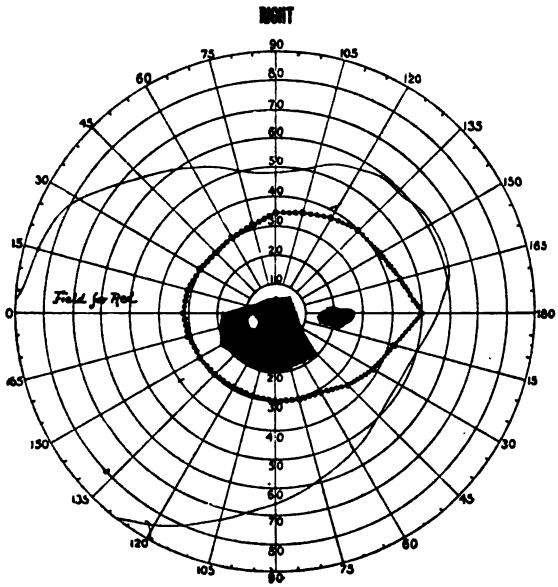

FIG. 2.

* The other color fields (green, blue, and yellow), have not been included in this report, as they practically were the same proportionately. There was a slight subnormality in central color perception: a mere lessening of degree of color saturation.

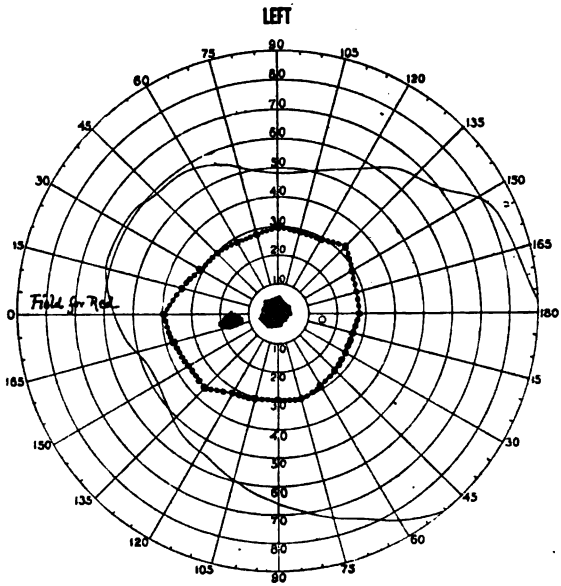

FIG. 3

OBJECTIVE.

3. The predominance of the main visible degeneration expressions to the lymph channel walls of the central retinal circulation.

4. The vast area over which the engorgements of the vascular channels of both series of the central retinal circulation extends.

5. The congeries, the false loops, and the curious twistings of the vascular currents in their dilated channels.

6. The characteristic tint of the venous obstruction columns, and the remarkably excellent tinting of the arterial currents.

7. The great irregularities of both the arterial and the venous currents, particularly those of the former.

8. The ophthalmoscopic appearance of some of the fine and ordinarily invisible vascular stems — necessarily with but little if any lymph — channel wall thickening and opacification.

9. The but one coarse degeneration area of the retinal fi-

bers — appearing on and in the nasal half of the optic disc and along the nasal borders of the disc, and extending inwards between the main nasal stems of the central retinal vessels.

10. The superficiality of the fresh hemorrhagic extravasations from both the smaller arteries and the finer veins; with the similar proximities of the pigment depositions of the older ones.

11. The remarkable preservation of the intervening retinal elements with the apparent noninvolvement of the underlying glandular functioning structures and material and the further removed choroidal membrane.

A most careful search throughout ophthalmic literature, with a close study of both the graphic and the written descriptions of at first sight, similar affections — particularly among the not few English, French, and German ones — for several years past, has failed to give me anything which can be considered the same throughout as in this case. Similar in one or more details, and dissimilar in many others; alike as to superficial extent, and unlike as to deep involvement; agreeing as to probable cause, and yet nonconforming as to ultimate effect; and existing as an isolated ocular stigma in a proved syphilitic's apparently otherwise healthy family — the case assumes an importance which is worthy of record.

The only prototype of this case — and one which is more grossly binocular in character — that has been brought to my personal knowledge, is that of an unpublished one studied by me through the kindness of Joseph Schoebl of Prague, Austria, who gave me not only a water-color sketch of the same, but presented me with a microscopic slide of an actual specimen of the conditions. He found it in a young girl; in the one affected daughter of a male nerve-syphilitic (as is mine) in whom (as in mine) it had probably arisen just before puberty. My examination of this, (his) single section — the details of which he never gave to the world — evidences anatomically the very points brought out in my study of the present case with the lower magnification of the ophthalmoscope, and proves the correctness of the significance of the above ophthalmoscopic statements.

EXTENSIVE DISEASE OF THE RETINAL VESSELS (VASCULITIS AND PERI-VASCULITIS FOLLOWED BY PROLIFERATING RETINITIS IN A YOUNG COLORED MAN.

By G. E. DE SCHWEINITZ, M.D.,

Philadelphia, Pa.

with

RESULTS OF SKIAGRAPHIC EXAMINATION OF THE HEAD
By HOWARD PANCOAST, M.D.,

Philadelphia, Pa.

The eyes of the patient whose clinical history and ocular examinations follow presented in such elaborate degree the lesions of disease of the retinal bloodvessels, retinal hemorrhages and later hemorrhages into the vitreous and so-called proliferating retinitis with the formation of vascular veils, that their record is justified, especially as a study of the naso-pharynx and of the accessory sinuses by means of the X-rays furnishes suggestions as to possible etiological relationships which are not without interest.

George Murray, aged 23, born in the United States, single, colored, bellman, applied for treatment in the Dispensary for Diseases of the Eye of the University Hospital on the seventh of September, 1905, and again, after a short period of treatment, one year later, namely, on the thirteenth of September, 1906.

Family History.— The patient's maternal grandmother is said to have lived to be 100 years old; his mother's sister died of phthisis; his father is living and well; his mother died at the age of 53 from paralysis, and prior to her death had some form of abdominal tumor the nature of which is not known. One sister is alive and well; another sister is subject to so-called sinking-spells, which from their description indicate that she has epilepsy; a third sister died of diabetes at the age of 14.

Patient's History.—In childhood the patient had measles and whooping-cough. Eight years ago he suffered from a moderately severe attack of influenza which lasted for three weeks. He has never had rheumatism, but as a boy caught cold readily, although in later years he has outgrown this tendency. He never had bone, joint or glandular disease during childhood, nor pulmonary or gastro-intestinal affections in later years. When about six years old he was thrown from a sled, striking his forehead on a step, and was unconscious for half an hour. When twelve years old he fell and injured the right side of his chin. A third fall occurred twelve years ago by which he sustained an injury in the occipital region, and again, four years later, he fell on the ice and struck his head on the same place. These four accidents have never given rise to any symptoms except those which surrounded their immediate occurrence. The patient has never used tobacco. Prior to the time that his ocular treatment was instituted, he averaged a few glasses of beer a week and an occasional glass of whisky. In 1893 he had gonorrhea, which lasted one month. There has been no recurrence of this disease and no apparent sequels. Syphilis is denied, and there are no evidences on his person of this infection. The ordinary stigmata of inherited syphilis are absent.

Past Ocular History.—Five years ago the patient was struck in the right eye by a crust of bread. Following this there was a moderate traumatic conjunctivitis, which lasted about three weeks and which was accompanied by pain and moderate discharge, but was unassociated with any failure in vision. On the 7th of September, 1905, he came to the Dispensary for the relief of fronto-occipital headache. The vision of the right eye was 6/5 and of the left eye 6/15. After the use of atropin the following glass was prescribed:

O. D. + .50 s ⊂ + .25 c axis 105, 6/5
O. S. + .50 s ⊂ + .50 c axis 75, 6/7.5

The ophthalmoscopic record is: Media clear; discs moderately vertically oval; refraction hyperopia. There is no note of any lesion in the fundus of either eye.

The patient was not again seen until one year later, namely, on the 13th of September, 1906, when the vision of the right eye was 6/15 and of the left eye 6/6. He sought relief from the sensation of a foreign body in the right eye which had lasted for about two months. The bulbar conjunctiva was hyperemic, and there were moderate pericorneal and conjunctival injection and a small marginal corneal ulcer on the nasal side of the right eye, for which boric acid and atropin drops were ordered. It was also noted that this eye was more prominent than the left. The development of a slight irido-cyclitis, associated with the small marginal ulcer, led to a more thorough examination than had previously been made, on September 27, 1906, with the following results:

Ocular and General Examination, 9.27.06.—Vision of O. D. 6/7.5; eye prominent as compared with the fellow eye, but no limitation of movement in any direction, and no diplopia; cornea slightly hazy in the neighborhood of the small corneal ulcer; a delicate band of ciliary injection, but pupil widely dilated and no synechiæ. The lens and the vitreous were clear, and the ophthalmoscope revealed the following conditions:

The optic disc was nearly round, and had a small central excavation. The veins were swollen, uneven and thickly coated with white tissue (periphlebitis). Between the branches of the upper and lower temporal veins and the upper nasal vein were extensive sheet-like hemorrhages and some areas of white exudate. The arteries in comparison with the veins were small, and were also lined with white tissue indicating infiltration of their walls. (Plate I.)

Examination of the left eye showed a precisely similar although less marked condition of affairs—widespread disease of the vessels, with hemorrhages and exudates along their distribution.

The patient was referred to the Medical Dispensary for general examination, and the following report obtained: "Nothing has developed in the physical examination of George Murray

Fig. 1. Extensive retinal vessel disease; periarteritis and periphlebitis. Right eye.

to account for his ocular conditions. Urine examination revealed no indications of kidney disease."

The patient was admitted to the wards of the University Hospital and thoroughly examined, without finding any constitutional disease. Urine and blood examinations, frequently repeated, yielded entirely normal findings. The blood pressure was normal. Not the slightest improvement took place after a thorough mercurial and iodid course; indeed, the patient was most susceptible to the influence of mercury and was quickly salivated, and at the expiration of two weeks the hemorrhages had greatly increased, so that vision of O. D. was reduced to hand movements and of O. S. to 6/150; also a fine punctate haze developed throughout the right vitreous.

11.15.06. Marked cyclitis of the right eye was evident, with soft synechiæ readily broken loose with atropin. Exophthalmos of the right eye was distinct.

The patient was referred to Dr. W. G. B. Harland for investigation of the rhino-pharynx, who submitted the following report: "An examination of the nose of George Murray showed some enlargement of the turbinates, especially of the lower turbinate on the right side. The lining mucous membrane of the nose was of a darker red than normal, due to chronic congestion. In the vault of the pharynx was discovered a large mass of adenoid tissue, not fibrous and pale with marked longitudinal furrows as is usually found, but soft with an even surface of a dusky red hue, due to chronic congestion. The faucial tonsils were very large and fibrous. The surface of the right one was traversed by dilated blood vessels. The pharyngeal and faucial tonsils were removed under cocaine without difficulty, one at a sitting, bleeding being rather free."

At my request Dr. Howard Pançoast made a stereoscopic skiagraphic examination of the patient's head, with the following results: The most prominent feature revealed by the X-ray examination is the abnormal development of the accessory sinuses of the respiratory passages. The frontal sinuses are enormous, and extend the entire width of the frontal region, and well around into

the temporal fossæ. Bony partitions are apparently lacking, and the walls are abnormally thin, particularly for a negro.

"The sphenoidal and the ethmoidal sinuses are similarly affected, the chambers appearing greatly enlarged, and the walls thin, except the anterior and inferior wall which apparently is decidedly thickened. Bony partitions are evidently present, but so thin as to make it appear that these two sets of sinuses merge one into the other." (Plate II.)

In December, in the center of the right cornea, a small, disc-like infiltrate formed, somewhat resembling that which is seen in keratitis disciformis, associated with increase of the cyclitis and the exophthalmos. These conditions were greatly relieved by the removal by Dr. Harland of the thick mass of adenoid tissue which has previously been described; but the retinal lesions remained unchanged.

From now on until February of 1907 there was a gradual increase in the hemorrhages and exudates, particularly upon the right side, and large glistening white veils began to push their way into the vitreous; in other words, the lesions of proliferating retinitis began to be evident.

In March the vision of the right eye was reduced to counting fingers at one foot, and that of the left to 2/45. Well-marked proliferating retinitis and the formation of large vessel-bearing masses of white tissue pressing forward into the vitreous were marked features.

On April 29th the following notes were made: Vision of O. D. hand movements. There is a small, central corneal scar, marking the position of the former disc-like infiltrate. Upon the surface of the lens are several clumps of iris pigment, but the pupil is widely dilated and there are no synechiæ. The vitreous is cloudy and the disc cannot be seen. From in front and above the position of the disc and passing upward and forward, there is a large veil of bluish-white tissue carrying upon its surface congeries of twisted vessels, the surface of which can be studied with + 23 D. Just below the disc there is a reddish mass indicating the presence of a hemorrhage, and also a large,

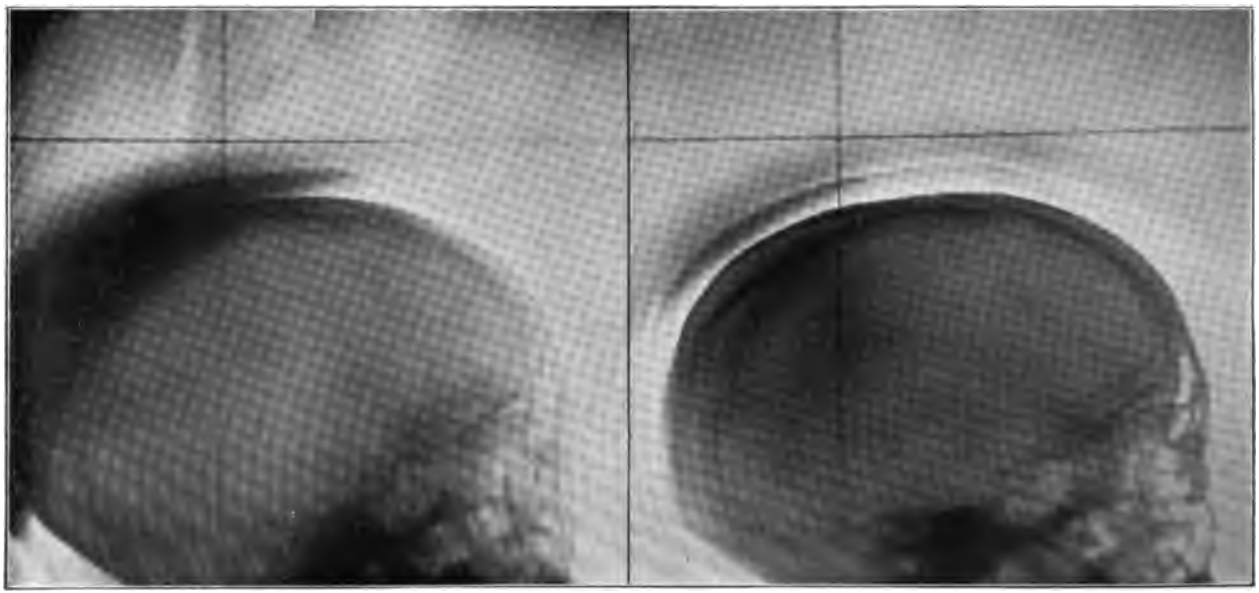

Fig. 2.—Stereoscopic skiagrams showing the thickening of the anterior wall of the sphenoid sinus and enlargement of the frontal sinuses. For description see text.

Fig. 3. Retinitis proliferans, with new vessel formation; beginning detachment of the retina. Right eye.

similar blood-carrying veil. On the nasal side, there are large, sheet-like veils carrying similar twisted vessels and pressing forward + 17 D. into the vitreous. Passing from the top to the bottom of the eyeground on the nasal side there is a falciform stripe of glistening tissue somewhat in advance of the veils just described. Partial detachment of the retina is evident. (Plate III.) Vision of O. S. 2/150; cornea clear; no synechiæ; no pigment on lens. Beginning at a point approximately corresponding to the disc and occupying an extensive area of somewhat triangular shape, passing outward and downward, is a huge mass of whitish connective tissue supporting congeries of vessels and numerous smaller and larger hemorrhages. It is bounded above by a glistening band of tissue midway between the disc and the periphery, best studied with + 9 D., which joins on its nasal end with a smaller band passing upward and inward, and also with a band of like tissue which bounds the lower portion of the mass and which moves gradually around to meet the upper margin of the lesion. In the lower and inner portion of the eyeground and also carrying numerous twisted vessels, are large glistening white masses, elevated + 9 D., and just to the nasal side of the disc and below are numerous sheet-like hemorrhages and large glistening veils which extend to the periphery of the eyeground; in fact, the only portion of the retina which seems at all free exists upward and inward.

A slight prominence of the right eye continues, but there are no faults in movement except imperfect convergence, and no failure in the correlation of the movements of the eyelids and the eyeball.

A second residence in the hospital for a few days during the month prior to the time of the record of the notes just given, and during which all examinations that had previously been made were repeated, failed entirely to reveal any physical disabilities other than those connected with the eye. A scar on the forehead beginning slightly to the right of the median line and sloping downward and to the left to one-fourth of an inch above the in-

ner end of the left eyebrow indicates the position of the wound received when a child, previously described, as does also a scar one and one-half inches long on the right side of the chin. In other respects no external lesions were discoverable.

REMARKS.— Although the clinical history and repeated examinations failed to prove that this patient was the subject of syphilis, either acquired or inherited, this taint, which is also not positively excluded, would best explain the extensive disease of the retinal vessels. Syphilitic arteritis and perivasculitis of the retina are well known conditions and a visible opacity of the walls of the arteries and more rarely of the veins, so that the blood columns of the diseased vessels are accompanied with lateral white lines, or covered with grayish-white opacities, or even at times completely obliterated, to quote the words of Haab, represents a familiar disease-picture.

It is notable in the present case that while the arteries were extensively diseased, the veins are even more involved, so that there is an elaborate peri-phlebitis. Such peri-phlebitis has more than once been described as the result of inherited syphilis, and in general terms, peri-vasculitis of the retina as a late manifestation of the acquired disease is well known. Microscopic investigations under these conditions are summarized by Parsons, and we know that the arteries are thickened, sometimes hyalin, and surrounded with deeply staining groups of cells, but as Uhthoff has shown, not only is such infiltration found in the arterial twigs, but also in the veins, and in some of his cases the aggregation of cells was so great that the lumen was invisible. Appel also has described endo- and peri-arteritis and infiltration of the coats of the veins, together with obliteration of the capillaries.

New vessel formation and the so-called retinitis proliferans take place more frequently after hemorrhages of syphilitic origin than those which are due to other causes, not only when the syphilis is an acquired infection, but when it is hereditary. It must be remembered, however, that in the present case anti-

syphilitic remedies were badly borne and salivation was induced by doses of mercury which ordinarily would not produce this effect in a syphilitic subject. At best the etiological factor is a matter of speculation, with the indications more strongly in favor of syphilis, in spite of the failure to prove its presence by clinical history, repeated examinations, and the therapeutic test, than of other causes of such a condition.

In that affection usually seen in young persons, commonly young men between the ages of 15 and 30, to which the name relapsing hemorrhage, or spontaneous hemorrhage into the vitreous, has been given, and for which the cause is not definitely known, Ammann and others have noted disease of the vessels. Some of these patients, as Eales has pointed out, are liable to constipation, irregularity of the circulation and repeated epistaxis, and in some gout has been believed to be a cause; in others hereditary and acquired syphilis. In some respects this case is allied to those which have just been described, although in the extensive development of the retinal vessel disease and the elaborate proliferating retinitis, it assumes a position quite apart from any others which I have had the opportunity of studying in a patient of this age and race.

Very interesting, it seems to me, are the results obtained by the X-ray examinations already described. Commenting on these studies Dr. Harland, who has given particular attention to the value of this method of investigation in sinus disease, writes me as follows: "A study of the skiagraphs shows the presence of very large frontal and sphenoidal sinuses and the separation of the ethmoidal cells by exceedingly thin walls. The antra and other sinuses appear clear. The walls separating the sphenoid sinuses from the nasal fossæ and the naso-pharynx appear greatly thickened in both of the pictures taken before and after the removal of the adenoid mass. Probably this increase in thickness is due to new bone formation from the congestion caused by the proximity of the large vascular adenoids, leading to hypernutrition. Bone hypertrophy shown in the inferior and an-

terior walls of the sphenoid is not found within the ethmoid labyrinth, for there the bony septa are thinner than usual, suggesting a rarefying osteitis. Very likely this process has so thinned the walls as to make the sphenoid and some of the posterior ethmoidal cells appear as one cavity in the picture. In proof of this view close scrutiny of the skiagraphs shows the outer ends of such a partition in the front part of the sphenoid sinus. There are no positive signs in the nose to indicate the primary cause of these changes unless they are due to syphilis. They cannot be explained by local nasal disease."

Dr. Pancoast writes as follows: "While the skiagraphs give no positive indication that the enormous development of the sinuses was a factor in the causation of this patient's symptoms, the value of stereoscopic skiagraphic examination is demonstrated in two ways: In the first place it renders possible the exact location and configuration of the entire osseous structure of this portion of the head. In the second place, it demonstrates the possibility, and in fact, the probability, of errors in localization and also in diagnosis which may result from an attempt to interpret skiagraphs made in the usual way. For example, comparative examinations of one of the negatives from each of the two sets, one made before and the other after the operation for the removal of the adenoids, gave an impression that the anterior and inferior wall of the sphenoidal sinus was thickened in the first place, but appeared much thinner in the second. This observation apparently indicated that the thicker shadow in the first place was due to the presence of the adenoid. The stereoscopic views, however, show that this bony wall is of the same thickness in each instance, and thicker, moreover, than it appears in the skull of a normal individual."

A matter of some interest is the prompt subsidence of the active irido-cyclitis, as well as a certain lessening of the exophthalmos which followed the removal of the adenoid mass. In this connection Dr. Shumway called my attention to the observations of Krauss on the relations of the orbit to the pterygo-palatin

fossa and his belief that at times most of the venous blood from the globe may pass through the inferior orbital fissure, and that this fossa and fissure may contribute the connecting link between disturbances of the naso-pharynx and those of the orbit. Vascular swellings situated in the pterygo-palatin fossa and secondarily invading the orbit may cause pulsation of the eyeball, exophthalmos, etc. It is possible, therefore, as Dr. Shumway has suggested to me, that the obstruction of the pharnyx by the adenoid tissue in this patient might by interference with the lymphatics and venous currents be responsible for some of the symptoms. This idea receives a certain amount of confirmation by reason of the rapid subsidence of the inflammatory symptoms and the lessening of the exophthalmos on the removal of the adenoid mass. It did not, however, influence in any way the retinal lesions.

TWO CASES OF RECURRENT CONJUNCTIVITIS PRODUCED IN ONE BY THE HORSE, IN THE OTHER BY CATS.

BY S. D. RISLEY, M.D.,

PHILADELPHIA, PA.

The following histories are deemed of sufficient interest to be placed on record in the annals of this Society. Both came under my notice during the past week and are briefly reported simply for the purpose of record in order that they may be added to the already published cases:

CASE I. Miss S, aged 25, relates that she is unable to come into the near vicinity of horses without being immediately attacked by uncontrollable sneezing, stuffed nostrils, and profuse lachrymation. The eyes become bright red from the intense injection of the conjunctiva. Even only after a few moments' exposure to the horse the symptoms persist for several hours, and

are followed by a longer period of discomfort during the gradual subsidence of the irritation and hyperæmia in eyes and nose.

The manifestation is so invariable that she prefers to walk from her home to the railroad station than to venture behind her father's horses even in a closed depot wagon.

She regards the advent of the automobile with peculiar delight.

I have never had the opportunity to study the eyes during one of these attacks and am therefore unable to describe with accuracy the condition of the mucous membranes.

CASE 2. Miss R., aged 17, relates that for a period extending over five or possibly six years, any attempt to fondle a cat brought on almost immediately profuse lachrymation. The tears would stream down the face and the eyes would become inflamed, i. e. bright red. The nostrils would also become involved but apparently secondarily, the primary attack falling upon the eyes and with greater severity. If the cat was taken into her lap and stroked persistently the symptoms would last an hour or longer, but if the cat were removed immediately the duration was much shorter. The presence of the cat moving about a room was not sufficient to produce the symptoms, but if she simply stooped over and stroked the cat the lachrymation came on immediately. After five or six years this peculiar susceptibility disappeared without treatment of any kind. Her health was good. She is not a victim of hayfever or rose cold, nor did the presence of any other animal produce the attacks of conjunctivitis.

DISCUSSION.

DR. W. C. POSEY of Philadelphia said that he believed that he had been the first to call attention to conjunctival irritation excited by proximity to a horse, in a paper which he read before the Section in ophthalmology of the College of Physicians, in Philadelphia, in 1905. Since that time he had received probably a dozen communications from other physicians, detailing similar cases. But a few days since, a medical friend had told him that his eyes became much injected when subjected to the irritation due to the proximity of bed bugs. While the irritation is probably

somewhat analogous to that of hay fever, there is no essential connection with it. Irritation of the mucous membrane of the naso-pharynx had been long recognized by rhinologists, and Dr. Posey referred to an interesting case in a man who had been unable to live in London on account of marked coryza arising from passing a horse in the street, who was subjected to the experiment of riding behind a horse that had been covered with vaseline, the symptoms under these circumstances not arising until an hour later. It is impossible at this time to designate the nature of the agents exciting the irritation, bacteriological study in his cases having been negative.

DR. WALTER L. PYLE, Philadelphia, Pa. In the compilation of a work on "Anomalies and Curiosities of Medicine" several years ago, I found scattered through medical literature numerous records of instances of phenomena caused by the presence of horses and other domestic animals similar to those mentioned by Dr. Risley. I recall several cases described as early as the sixteenth century. Although the ocular disturbances were noted, generally the symptoms were referred primarily to disturbance of the nasal mucous membrane — a condition somewhat analogous to our modern "hay-fever."

Dr. E. Jackson, Denver: Conjunctival hyperemia and irritation from exposure to the emanations of the horse cannot be very rare. I have encountered three cases of the kind since the publication of Dr. Posey's paper on the subject a few years ago; and each of these patients had known of other persons similarly affected. These were all young adults: two men, one woman. The irritation had been noted repeatedly for years. One of the men did not experience it from driving or riding horseback, but was seriously affected after spending a few minutes in the stable. The others suffered after riding or driving. They were not so affected from the rush of air or dust attending automobiling.

PRIMARY MELANOTIC SPINDLE-CELL SARCOMA OF THE CORNEAL LIMBUS.

By C. A. VEASEY, M.D.,

PHILADELPHIA, PA.

All tumors having their origin in the corneal limbus are of comparatively infrequent occurrence, but this is especially true of sarcomata. According to Parsons,[1] the first case of primary sarcoma of the limbus was reported by Baumgarten in 1852. In 1879 Noyes[2] collected "127 cases of tumors growing from the front of the globe and from the lids," a few being sarcomata of the limbus, but as pointed out by Wadsworth and Verhoeff,[3] no close distinction was drawn between the cases of sarcomata and epitheliomata.

Clegg and Hall[4] in discussing the rarity of this condition, state that only 3 cases were observed in an examination of 520,523 out-patients at the Manchester Royal Eye Clinic.

Recently Verhoeff and Loring[5] have discussed the matter at some length, reviewing and analyzing the previously recorded cases and arriving at conclusions somewhat different from many of the preceding writers. Altogether they found in the literature about 80 undoubted cases, and in searching the records of the Massachusetts Charitable Eye and Ear Infirmary they found only 2 cases among 44,719 patients. It is thus seen that the condition is quite rare; and inasmuch as there is still some question as to the manner of extension of these growths and as to their malignancy and consequent treatment, it is worth while to record each individual case.

---

[1] Pathology of the Eye, vol. I, p. 138.

[2] Archives of Ophthalmology, vol. VIII, 1879, p. 145.

[3] Trans. Amer. Oph. Soc., vol. IV, p. 281.

[4] Lancet, Sept. 10, 1904.

[5] Archives of Ophthalmology, vol. XXXII, 1903.

W. B., male, aged 47 years, presented himself at the dispensary of the Methodist Episcopal Hospital, October 23, 1906, for advice concerning a growth upon his left eyeball. According to his statement there had been a small brownish spot just to the temporal side of the corneo-scleral junction for about twelve years, but it had never given any trouble or increased in size until recently. Seven weeks before he came for advice it had commenced to grow, and the progress had been extremely rapid. At the time of the examination the following conditions were noted:

There were two growths, or one large growth with two lobules, covering about two-thirds of the corneal surface. The upper and larger, irregularly ovoid in shape, was 11 mm. long, 10 mm. wide, elevated 5 mm. above the normal corneal surface and extended 1½ mm. beyond the corneal limbus on the sclera. It was not mobile, was firmly attached to the underlying ocular structures and overlying conjunctiva, possessed no undermining edge, and was dark brown in color, some portions being more intensely pigmented than others. The lower and smaller growth, or lobule, was almost horizontally oval, 10 mm. long, 6 mm. wide, elevated above the corneal surface 5 mm. and its color a light pinkish hue. The apex was ulcerated and bled upon the least manipulation. Looking at it directly from in front the corneal limbus, if projected forward, would have divided it into two almost equal parts, about as much of the growth resting upon the cornea as upon the sclera. Like the upper portion, it was firmly attached and non-mobile. The ocular conjunctiva which passed in thickened folds to the point of juncture between the two lobules and completely covered the small intervening portion of the cornea, had apparently assumed this position as the growth had increased in size, thus putting the conjunctiva upon the stretch. A small portion of the pupil and approximately one-third of the cornea remained uncovered, the latter being clear and apparently unaffected in any way. The iris was of good color and appearance, the anterior chamber unaffected, the pupillary reactions prompt and the fundus normal so far as could be

ascertained through the small amount of pupillary space available. For a few weeks there had been some secretion and during the last few days some difficulty in closing the lids.

No family history of tumors of any kind could be elicited.

The growth was thought to be a melanotic sarcoma and enucleation was advised. The advice was accepted and the operation performed two days later, the eyeball being placed at once in a 2½% solution of formalin, and submitted to Dr. C. M. Hosmer for examination and report. There has been no recurrence up to the present time.

Macroscopic Examination:

Occupying the inferior temporal quadrant of the cornea is a deeply pigmented triangular wedge-shaped tumor. The base of this triangular growth lies upon the sclera, its apex being opposite the center of the pupil, upon the cornea. It is equilateral, the sides being 10 mm. in length. Slightly above its apex it is 5 mm., and at the limbus 1 mm. in thickness. The outer edge overlaps very slightly the corneal limbus. Occupying a portion of the lower half of the cornea is a flattened, ovoid, and, in the main, non-pigmented growth. Its long axis is 10 mm., and it is 5 mm. in width and 5 mm. in thickness. It is about equally situated upon the cornea and sclera. The upper and lower tumors are apparently in contact opposite the center of the cornea and at this point some pigmentation of the inferior growth is observed. The upper nasal quadrant of the cornea is clear, an apparently normal anterior chamber and iris being visible. The lower temporal quadrant upon which the two growths encroach to some extent is otherwise occupied by thickened conjunctival tissue. The measurements of the eyeball are normal and, excepting the portion described, no other part seems to be affected.

Histologic Examination:

After fixing in formalin the eye was frozen and bisected in a plane passing about 10° to the temporal side of the upper end of the vertical meridian, through the center of the base of the

Sarcoma of Limbus.

upper, and obliquely through the lower growth, and through the optic nerve posteriorly. The plane of bisection leaves a small pupil in the nasal half. The temporal half was embedded in celloidin for miscroscopic examination; the nasal preserved as a gross mount.

Examination of the sections shows the cornea to be overlaid by a superior pigmented and inferior relatively non-pigmented tumor, the two being in contact opposite the center of the cornea. The pericorneal tissues in the neighborhood of the upper growth (a space included between imaginary lines passing forward from the periphery of Bowman's membrane and from points opposite the root of the iris) are densely infiltrated with tumor and inflammatory cells — a condition believed to indicate an advancing local metastasis of the contiguous neoplasm. The advancing margin shows an attempted walling-off with lymphocytes. The foremost (possibly youngest) of the advancing neoplasmic cells in this location and as seen infiltrating the superficial corneal layers, have a relatively large, globular to ovoid, faintly staining nucleus with a prominent nucleolus, the protoplasm being finely granular and without distinct cell wall. The cells in the periphery of this infiltrating mass have a tendency to arrange themselves in solid globular or cylindrical masses in performed spaces or alveoli formed by older and more fully developed spindle cells. The more densely packed cells of the central portion are of a short spindle type. Within this mass three large islands of closely packed lymphocytes are seen, the largest being opposite the beginning of Bowman's membrane and apparently attempting to limit the extension of the more definitely structured superior tumor. The sub-epithelial layers of cells show collections of pigment, apparently within the cells — small or not fully pigmented chromatophores. The most superficial layers of the sclera at the beginning of Bowman's membrane are separated and carried forward into the growth. Over this portion, the epithelium, in the main, has disappeared; some remaining cells of the deeper layers show œdema, irregularity of placement, individual

degeneration and occasional infiltration with tumor cells and pigment. The episcleral tissues are œdematous and show a small number of inflammatory cells (lymphocytes must frequently) in and about the vessels, with quite numerous eosinophiles.

Sections of the superior tumor proper show an irregular reticular structure. Strands of large brown cells (not fully pigmented, swollen chromatophores) divide the surface into larger and smaller spaces. Assisting in the formation of, and further reduction of these spaces are interlacing strands of spindle tumor cells. Scattered throughout are small masses of dark pigment. A fairly broad arc of these brown cells with an inner layer of more deeply stained pigmented cells arches over the tumor and divides it, in a measure, from the above described pericorneal portion and from its lower end, which is in contact with the inferior growth. Sub-dividing this arc-enclosed area again into an upper and lower portion is a broad open-work band of deeply pigmented cells extending from the epithelium to Bowman's membrane. The lower part presents the reticular structure above referred to and the upper contains also islands of lymphocytic accumulations. The upper and lower extremities and the portion immediately overlying Bowman's membrane are deeply pigmented. Bowman's membrane at ts upper extremity is overlaid by a new formation of fully developed connective tissue. Below this point there are breaks in its continuity and numerous infiltrations and elevations by pigmented tumor cells. Overlying the tumor are seen remains of deeper epithelial cells much infiltrated with tumor cells. At its lower portion the upper tumor is flattened and is in contact with the inferior tumor, the latter being pigmented only at the place of contact.

The lower growth is composed of densely packed small spindle cells in its deeper portion overlying the cornea but showing a delicate lace-like structure beneath the epithelium. As stated above, it is non-pigmented except at the point of contact with the upper growth. It involves the periphery of the cornea somewhat more deeply than the upper tumor and is covered by a thinned,

in places necrotic, but apparently uninvolved epithelium. There is no infiltration of subepithelial tissues at its margin but a few small islands of lymphocytes are observed.

In the depth of the tumors, definite patulous blood vessels are infrequently observed. More are noted in the lower than in the upper growth, and here, also, we find occasionally blood vessels with coagulated contents. Thin-walled vessels in the periphery are fairly frequent in each.

On Descemet's membrane there is a small amount of finely granular matter, and in the interstices of the pectinate ligament free pigment granules and a few pigment bearing cells are observed. Some sections show a very slight round cell infiltration in the ciliary body near the root of the iris. In one section a localized collection of immature connective tissue cells is distinctly observed in the most anterior layers of the iris; and similarly situated; in several sections, are noted groups of closely massed pigmented cells — probably melanomata.

In other respects the eye appears to be normal.

It would seem, therefore, that the condition was undoubtedly spindle-cell sarcomata, with a secondary similar growth or a connective tissue rest in the iris, the upper growth being pigmented, the lower, in the main, non-pigmented.

REMARKS. Most ophthalmic surgeons who have recorded cases of sarcomata of the corneal limbus agree that they usually arise in the more exposed portion (palpebral aperture), are occasionally multiple, usually pigmented (according to Verhoeff and Loring 12 non-pigmented, 22 with small amount of pigment and 39 markedly pigmented) and are most frequently observed in patients past middle life (average 51 years).

The base of the growth is usually small even though the growth itself be quite large, so that it may overlie a large portion of the cornea without being adherent to it. This, however, was not true in the case just reported, the base being almost as large as the growth itself and firmly adherent to the underlying structures. As the tumor extends it does so superficially, having but

little tendency to invade the sclera or deeper layers of the cornea. It may, however, extend by way of the perivascular canals of the ciliary body or may even perforate the sclera directly. It takes about a year to become the size of a pea or bean (Parsons), though in my own case the growth did not seem to start to increase in size until a few weeks before the eye was enucleated. In many cases a small spot is present for years and suddenly undergrows rapid growth and extension.

Whether an attempt should be made to remove such tumors by abscission or to advise immediate enucleation is a question concerning which there is a difference of opinion. That some of the tumors grow slowly, that there is but little tendency to involve the sclera or deeper layers of the cornea, that when they recur they usually recur locally, that there is but little tendency to extend by metastasis are offered by some surgeons as reasons for an attempt at removal by abscission. On the other hand, as some cases do grow rapidly and involve the deeper layers of the cornea and sclera, even to perforation, as very many cases repeatedly recur, sometimes recurring at distant points, and finally have to be enucleated, as there are occasional metastases to other portions of the body, the patients' lives being lost, it is urged by other surgeons that enucleation should be advised as soon as the diagnosis is made. In discussing a case reported by Jessop[6] Tweedy stated that the earlier enucleation is performed the better. Nettleship believed first in cauterization with enucleation at the end of a fortnight if the wound assumed an equivocal appearance. According to Parsons, if the growth starts in a mole it is not so malignant as one which begins in the pigmented cells of the sub-epithelial tissue, and also that very rapid growths are of the latter type; therefore an examination of the tissues might modify the treatment as suggesting abscission rather than immediate enucleation.

Verhoeff and Loring,[7] however, after analyzing carefully all the recorded cases, concluded that immediate enucleation was ad-

[6] Trans. Oph. Soc., U. K., 1904.
[7] Loc. Cit.

visable; and unless the growth be seen at a very early stage when it is yet small and not firmly adherent, this seems to the writer the safest and best advice that can be offered the patient.

DISCUSSION.

DR. JACKSON: As bearing on the practical point how such cases should be treated, I would mention that about 15 months ago I saw a boy, 14 years of age, with a very dark, practically black, mass close to the limbus, which had not originated in the limbus but about 2 mm. outside, and which proved to be a melanotic sarcoma. It had been growing about 6 months and there was the history of an injury. The growth was adherent to the sclera, which was shaved away in removing it, leaving a black window about 3 by 4mm., as if the whole thickness of the sclera had been taken away. But the intraocular tension was not diminished either then or subsequently. The wound healed without difficulty, and there has been no recurrence of the growth. The window spot filled up with granulation tissue and left a very slight scar. Sight remains normal.

DR. SUTPHEN: Several years ago I had to enucleate an eye because of such a growth and there was no local recurrence for some years, but the man subsequently died of metastatic sarcoma.

DR. HOLMES: I have some drawings of two cases of similar tumors which were removed from the globe and enucleation was resorted to only after local recurrence, but in spite of that both patients subsequently died from metastases.

DR. ALLYN: I recall a case similar to those reported of a man about 50 years of age, whom I saw with Dr. Lippincott, and we decided not to attack the growth but to enucleate the eye. I examined it microscopically, as we did in those days, and found the growth not very deeply imbedded in the sclera and we have sometimes felt that we did wrong in not trying to save the eye, but we have the comforting knowledge that the man lived for many years without a recurrence.

DR. SHERMAN: Illustrative of the rapidity with which these growths recur, I beg leave to report a case coming under my observation some years ago: A farmer, aged 87, consulted me in regard to a small growth occurring at the over corneo scleral border of the right eye, which occasioned great pain. I excised the growth and cauterized base. I saw the patient six weeks later, at which time I removed the eye and all the tissues. The growth proved to be a melanotic sarcoma, having recurred with great rapidity, causing constant and severe pain which could not be relieved by opiates. A month later the man died from exhaustion due to great suffering. A post mortem examination revealed extensive invasion of the frontal brain tissues.

DR. MARPLE: Within the last three weeks I have seen a similar case to that reported by Dr. Jackson. While they are very small, there is a possibility of their returning, and though one naturally hesitates about removing the eye the microscope showed mine to be a melanotic sarcoma.

DR. VEASEY: I will simply add that this discussion goes to show what a change has taken place since the publication of Verhoeff and Loring's paper. Prior to that time the tendency seemed to be to temporize with these cases but, as they pointed out, so many cases died of metastases it seems wiser to enucleate early.

CASES OF CONGENITAL INEQUALITY OF THE SIZE OF THE CORNEÆ IN NORMAL EYES.

BY ALVIN A. HUBBELL, M.D.,

BUFFALO, N. Y.

I do not claim to have fully examined the literature on the subject of the dimensions of the cornea, but so far as my studies have extended, I have never found the record of any cases in which the diameter of the two corneæ in the same person were unequal. They certainly are rare, even if any have been published, and it is for this reason that I desire to put on record two

such cases that have come under my own observation. In both of these the patients were healthy, and of symmetrical bodily development. Neither eye, in either case, had ever been diseased, and other than the non-symmetry of size of the corneæ nothing could be detected that was structurally unusual or abnormal.

CASE I. Miss M. H., Titusville, Pa., eighteen years of age, visited my office on March 26, 1896, in company with her mother, who desired to consult me for some trouble with her eyes. I at once observed the lack of symmetry of the size of the two corneæ of the daughter, and, with her permission, I made notes to the following effect. She had never experienced any distress from the use of her eyes. The vision of the right eye equalled nearly all of 5/4, Snellen, also with + 0.50 D. Sph.; that of the left eye also equalled nearly all of 5/4, and the same with + 0.50 D. Sph. Maddox rod showed slight esophoria and very slight right hyperphoria. Both fundi were normal in every respect as shown by an ophthalmoscopic examination. Both irides were dark blue and were of the same tint. The pupils were the usual size of a healthy young woman of that age. They responded equally to light and their dimensions were the same. The Javal Ophthalmometer gave a reading for each cornea of + 0.50 D. Cyl. ax. 90. Each cornea was almost a perfect circle, with the usual variation of a slightly shorter diameter vertically than horizontally. Only the horizontal diameters were measured. The diameter of the right cornea was 10 mm., scant, and that of the left was 13mm., scant, measured to the extreme margin of the transparent portion.

The young lady's grandmother on her mother's side, according to the statement of herself and her mother, had eyes which appeared to be in the same condition, although they could not tell which cornea was the larger.

On examining her mother's eyes, I found the right defective in vision and with a large amount of comp. myopic astigmia. The left eye was emmetropic. The two corneæ were of equal size. The anisometropia of the mother's eyes did not, however,

have any hereditary relation to the condition of the daughter's eyes.

CASE 2. Miss C. B., age twelve, of Buffalo, N. Y., was sent to me by Dr. Francis J. Carr, of that city, for examination of her eyes for refractive error. She had been suffering from frequent and severe headaches which the doctor feared might be due to eye-strain. She is a well developed girl for her age, has a good family history, so far as I can learn, and aside from the headaches, has always been in good health. She has never had sore eyes or any weakness of vision in any way. She has full eyes and regular features, and the facial expression is rather pleasing, except for the peculiarity so apparent in the eyes. The family has noticed during all of her life that one pupil was a little larger than the other, and that the eyes were not exactly of the same color.

The visual test shows a manifest hypermetropia of 1.00 D. in the right eye and 0.50 D. in the left. Under homatropine solution (2 per cent.), however, the hypermetropia was 1.25 D. in each eye. Both with and without the homatropine, the vision in each eye was 5/5. Maddox rod showed seven degrees of esophoria and one-half degree of right hyperphoria. Each fundus with the ophthalmoscope was perfectly normal, the appearance being the same in both eyes. Before using the homatropine, the examination of the pupils showed the right a little smaller than the left in moderate light, and in bright light they both contracted to nearly the same size; but in deep shadow the left became dilated to almost twice the size of the right. In moderate light the right pupil was 2½ to 3mm. in diameter and the left was 4 to 4½ mm. Under homatropine the right pupil did not dilate quite as fully as the left. The color of the right iris was blue, and the left, while of a bluish cast, tended more towards a brownish color, the brown being especially distinct around the sphincter of the pupil.

Accompanying this difference in the size of the pupils and the color of the irides, was also a slight but very apparent difference in the size of the corneæ, the right having a less diameter than the

left. Both corneæ had the usual circular form. The measurement of the horizontal diameters were in the right 11½ mm. and in the left 13 mm.

So far as known, no such case of corneal asymmetry has occurred in either her father or mother's family.

I realize that these two cases have no special practical value, but I deem them of sufficient interest, anatomically, to place them before you.

REMOVAL OF THE LENS IN HIGH MYOPIA.

BY DR. W. E. LAMBERT,

NEW YORK, N. Y.

Since the revival of this operation by Fukala in 1889, the treatment of myopia of high degree by removal of the lens has been extensively practiced in Europe and to some extent in America, and is now generally accepted as a justifiable proceeding.

I have not had an opportunity to look up the statistics of this subject very carefully, but in a paper by Dr. Barnes, published in the "Medical Record," June 17, 1905, I find that he has gone over the literature on the subject with great care, and states that there have been 2500 operations reported from abroad and not quite fifty in America. While my own experience has not been extensive, it seems that the four operations that I have performed might well be added to the cases reported in America, especially as the results in all have been particularly satisfactory, and quite beyond our most sanguine expectations.

There still seems to be a great difference of opinion as to the best method of operating, and also the class of cases in which the operation is indicated or justified.

I shall not now occupy your time with a description of the various methods of operating, nor discuss the arguments for and

against the operation. With these you are, no doubt, quite familiar. I shall simply report the cases and from my experience, although it is quite limited, venture some conclusions.

The first case, Miss L. F., aged 16, studying stenography and typewriting. For ten years she had been wearing O.D. — 15; O.S. — 13. She had, however, been suffering a great deal of discomfort with her glasses, and found her vision extremely unsatisfactory; so unsatisfactory, indeed, as to lead her to conclude that she would be unable to pursue her vocation in life.

She applied to the Infirmary May 2, 1906, for treatment. The vision of her right eye was 5/200 and left eye 15/200. Under a mydriatic, skiascopy showed a myopia of 21 D. with a small amount of astigmatism in the right eye, and 18 D. in the left eye; vision with this correction was 20/70 in each eye. The fundus in each eye, excepting large staphyloma, was in a very good condition.

She consented to have the operation performed, and it was decided to do the needling with linear extraction, the Fukala method.

On May 3d, the lens of the right eye was needled under cocaine, the crucial incision being made in the anterior capsule with Knapp's knife needle, the lens substance being but very slightly disturbed.

On May 4th, there was some slight reaction, lens somewhat opaque, no very great pain, anterior chamber but partially restored. Hot bathing and atropine.

May 5th she complained of considerable pain in the eye. There was great circumcorneal injection, plus tension. Anterior chamber shallow, lens swollen. The afternoon of the same day a linear extraction was made, all soft lens matter removed, the anterior chamber irrigated freely with normal salt solution, atropine instilled, and the eye bandaged.

The following day the anterior chamber was restored, eye was comparatively quiet, tension normal and no pain. The patient made an uninterrupted recovery without any untoward

symptoms, the remaining soft lens matter gradually being absorbed, capsule alone remaining.

On May 15th (12 days after the first needling), a discission of the capsule was made and a clear black pupil obtained. The vision with + 1.50 cyl., 90° was 20/30+.

The left eye of the same patient was operated on June the 12th. The experience with that eye was practically the same as with the right, with the exception that there was little or no pain following the first needling, and but slight increase in tension.

The lens matter was removed by a linear extraction as in the first eye, forty-eight hours after the needling, and on the 17th day after the first needling a discission of the capsule was made, resulting in a clear pupil with a vision of 20/30+, with +1.50 ⌣ + 1.50 cyl. 490°. The patient soon overcame the diplopia which followed the operation, became accustomed to her glasses, and has been able to pursue her chosen vocation with comfort, using a + 3 S. in addition to the correction above mentioned for near work. The vision has improved somewhat, and when I saw her about ten months after the operation, she had practically 20/20 vision with both eyes.

The second patient, a young woman 31 years old, had been near-sighted from birth. Fifteen years ago, she was seen by one of the most eminent ophthalmologists of New York, who described her case as hopeless, and told her nothing more could be done.

I first saw her in October, 1904. She was then wearing —10 D. in each eye. The vision with this correction was O.D. 6/200, O.S. 12/200. With a —20 O.D., she then had 20/200 vision; O.S. with —16, 20/100 vision. There was large posterior staphyloma in both eyes, and most extensive changes in fundus of the right eye and thinning of the choroid in the left eye. There was also a small central opacity in the anterior capsule of each lens.

She was kept under observation until the spring of 1906, when an operation was advised, which, however, was deferred until the fall of 1906. A consultation was then held with Dr. Bull of New York, who agreed that an operation was justifiable, at any rate in the poorer eye to start with.

It seemed to me that the fundus conditions had progressed and also that the opacities on the lens had increased, although the vision was about the same.

Under homatropine the vision of the right eye on October 21, 1906, was 20/200 with —22 D.; left eye, 20/100 + with —20 D.

The patient was taken to the New York Eye and Ear Infirmary on December 4th, and on December 5th a discission of the lens of the right eye was made, the crucial incision being made in the anterior capsule. There was practically no reaction and little or no effect produced. On December 7th, a second discission was made a little more boldly. The result of this was equally unsatisfactory. On December 9th, two days later, the third discission was made, the capsule being thoroughly opened and the lens stirred up. The result of this was most satisfactory.

On the following day the lens was quite swollen and opaque, the tension, however, remained normal and very slight circumcorneal injection.

December 11th a linear extraction was made, all soft lens matter being removed by free irrigation with normal salts solution. Atropine and hot bathing was used, the eye rapidly quieting down.

The patient remained in the hospital until December 20th. The eye was then perfectly quiet. All soft lens matter had disappeared.

She then went to her home in Pennsylvania to return later for the needling of the capsule. She was instructed to use daily a weak solution of atropine and hot bathing during the interim. She returned January the 10th when a free discission of the capsule was made with a Knapp's knife needle, a satisfactory opening being obtained. She was kept in the hospital and atropine and hot bathing continued for several days.

The vision even at that early date was 20/50 with a —2 cyl., axis 90.

The success with this eye, the poorer one, encouraged us to proceed without delay with the other eye.

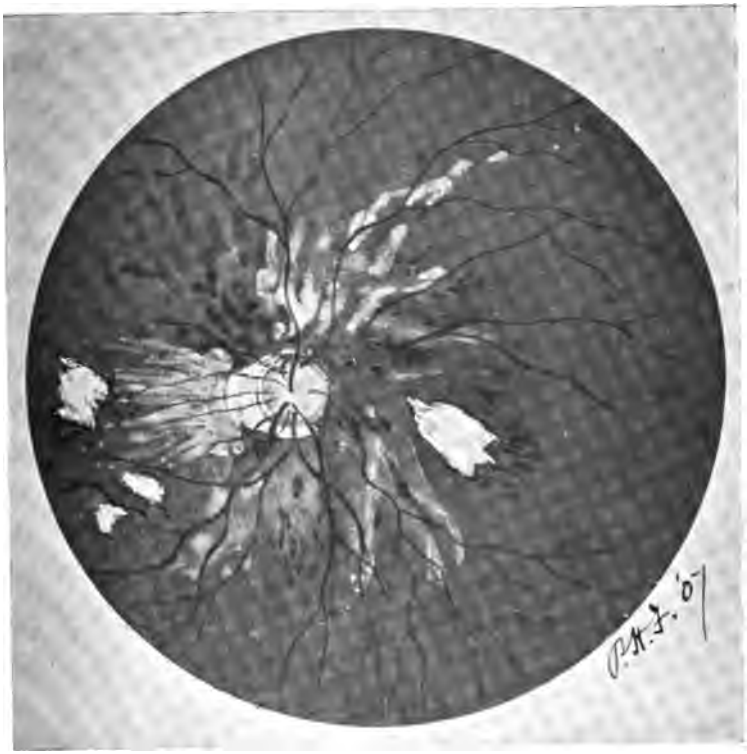
P.M.J. '07

P.M.J. '07

On January 29, 1907, the first needling was made. The reaction was very slight and little or no effect was produced. The second needling was made two days later. The result of this also was unsatisfactory. The third needling was made two days later (February 2d). This produced some slight reaction, but little or no opacity in the lens, except in the immediate line of incision.

On February 7th, five days after the third needling, the fourth was made, the lens matter being thoroughly stirred up. The following day the lens was quite swollen and quite opaque. The eye, however, was quiet, and there was little or no pain.

February 10th, three days later, a linear extraction was made and the soft lens matter washed out by free irrigation with a normal salt solution. She complained of considerable pain during the night, which was relieved, however, with some trional. The following day the anterior chamber was restored, the pupil well dilated, no adhesions, some soft lens matter remaining, treatment being hot bathing and atropine.

The improvement in the general condition of the eye was uninterrupted, and on February 22d, the patient left the hospital to return later for the discission of the capsule. The capsule in this eye was much more dense and the vision consequently very poor at that time. She returned March 17th, when an opening was made in the capsule with a knife needle on the 21st of March. The result was not satisfactory, and the second discission was made on March 26th, a good opening resulting.

The patient has been kept under observation since that time, atropine and hot bathing being moderately used, and practically all of the capsule had been absorbed, leaving a clear black, almost circular pupil.

The vision obtained and verified by the examination made first is O.D. 20/30+ with —2 cyl., axis 90; O.S. 20/30+ with — 1 1/2 S. ⊂ + 2 1/2 cyl., axis 165. With + 3 S. added to the above, she reads Jaeger No. 1.

The drawings made for me by Dr. Fridenberg very accurately represent the conditions of the fundus of each eye in the second case.

From experience gained in the four operations here reported, which, of course, is not very extensive, I should unhesitatingly recommend free discission with linear extraction.

It certainly seems to me that if a patient is kept under careful observation, it is a less dangerous proceeding than frequent discissions and allowing the lens to gradually absorb, and certainly has the great advantage as to the length of time occupied in bringing about the desired results.

It would seem to me also that the dangers of the operation have been somewhat exaggerated, and in view of the excellent result obtained in the second case reported, extensive fundus changes would not be a contra-indication for the operation.

DISCUSSION.

DR. JACKSON: My cases that have refused the operation and have gone along with the best obtainable results from glasses seem to have done about as well as those that were operated upon. I have done the operation three times and all of the cases continue in good condition. In the recording of these cases, it seems to me the corneal curvature should be carefully measured, for we have such a good chance to learn something of the dioptrics of the eye, especially as regards corneal astigmatism. The refraction after the operation or the effect produced depends so largely upon whether the condition is myopia of curvature or axial myopia. In the latter class of cases we expect a change of 18 or 20 diopters, whereas no such change will result if it is a myopia of curvature; only ten or twelve diopters will result in such cases. If there be rare cases in which the myopia is entirely due to increased curvature of the lens the eye would be left after operation with a hypermetropia of 10 or 11 diopters. For this practical reason the curvature of the cornea should be carefully recorded in all these cases.

DR. WILMER: I operated upon the first case ten years ago, and the patient is just as happy to-day as at the end of the operation. The operations have been done by needling, followed by

extraction of the lens, usually on the fourth day; in only one case was there any increase of tension after the needling; the second case was done nine years ago; the third case eight years ago; and the twelfth eye was operated on only two weeks ago.

DR. RISLEY. I would like to speak of two facts connected with this group of cases. The author of the paper mentioned that in one case there were serious changes in the bottom of the eye, but it nevertheless did well. I think we should bear in mind the actual condition of the eye at the time of the operation. A myopic eye with serious or extensive choroidal changes may, nevertheless, be for the time in a quiescent state; that is, the uveal tract is for the time being comparatively healthy and we are studying the scars of former disease. These highly myopic eyes are extremely prone to have exacerbations of choroiditis around the old scars left by former attacks of inflammation, or by hemorrhages. If the eye happens to be in one of the quiescent stages of its history the probabilities of favorable results from operation are good; whereas during an acute exacerbation any surgical interference would be perilous.

With reference to the changes in the lens that Dr. Jackson has just referred to I want to recall the history of one of three cases that I reported a few years ago to the College of Physicians in Philadelphia. In all of these three patients there was a hypermetropia of three diopters in each eye with some astigmatism. In each of them one eye had become suddenly myopic, in one case requiring a minus five diopter lens for correction, an apparent increase of 8 D. in the refraction. The lens became opaque. I have recently completed the successful extraction in this case. A preliminary iridectomy was done, an extraction and capsulotomy later. He now requires + 12 D. ⌒ + = 2.00 cy. ax. 10° and his vision is 6/7. The apparent myopia was therefore not axial but was obviously due to change of curvature in the lens.

THE POST-OPERATIVE HISTORY OF SIXTY CASES OF SIMPLE CHRONIC GLAUCOMA — SECOND SERIES.

BY CHARLES STEDMAN BULL, A.M, M.D.,
NEW YORK.

The first series of fifty cases of simple chronic glaucoma and their post-operative history were presented to the Society five years ago, and were published in the Transactions for 1902.

This second series of sixty cases have been under more or less constant observation for a varying period, from five to eleven years. They were all cases occurring in private practice, and the observations and tests used in the repeated examinations were all made by myself.

The operation performed in all of the cases was iridectomy, and but one operation was done on each eye.

In all, one hundred and fifteen eyes were submitted to the operation.

The age of the patients varied between 37 and 78 years.

In the decade	between	30	and	40	years,	there	was	1	case
"	"	"	40	"	50	"	"	were	9	cases
"	"	"	50	"	60	"	"	"	24	"
"	"	"	60	"	70	"	"	"	22	"
"	"	"	70	"	80	"	"	"	4	"

Sex.— Of the 60 cases, 27 were men and 33 were women.

Race.— All were native-born Americans of mixed English, Scotch, Irish, French, or Dutch ancestry.

Existing Refraction.— Of the 60 patients, 18 had simple hypermetropia, 14 had simple hypermetropic astigmatism, 16 had compound hypermetropic astigmatism, 8 had simple myopic astigmatism, and 4 had mixed astigmatism.

In all 60 cases, both eyes were involved.

Operation.— Iridectomy was done on one eye alone in 5 cases, the other eye being either blind from absolute glaucoma, or with the field so narrowed and vision so impaired as to contra-indicate the operation. The operation was done on both eyes at a varying interval of time in 49 cases, and on both eyes simultaneously in 6 cases.

Field of vision before operation.— There was concentric narrowing of the field in all directions, most marked on the nasal side, in 70 eyes.

There was narrowing on the nasal side only in 35 eyes.

There was concentric narrowing of the field with central or para-central scotomata in 11 eyes.

There was loss of the entire nasal half of the field in 4 eyes.

The scotomata, when present, were of a varying size, shape, and location at different times.

Tension.— In all cases which I was enabled to observe frequently before operation, the tension varied at different times in the day, and was higher in the morning, especially after a restless night. This fact has been observed by others, and these variations in tension have come to be regarded as rather characteristic of chronic glaucoma. With the tension higher in the morning, it would seem best to introduce miotic solutions in the early morning before the tension has risen.

An interesting factor in the disease was the condition of the arterial tension, and in six cases I was enabled to have a number of sphygmanometric tests made, and every test showed the presence of increased arterial tension. In a large proportion of the patients who were over 60 years of age, there were well-marked evidences of arterio-sclerosis present in the retinal vessels, and there is no doubt in my mind that this condition plays an important part in the etiology of chronic glaucoma.

Effect of iridectomy on central vision.— There was a temporary improvement in the central vision in 14 eyes, or about 12 per cent. There was no permanent improvement of the vision in any eye. There was no impairment of central vision immediately after the operation in any eye.

There was a slow but steady failure of central vision after the operation in 94 eyes, or about 70 per cent., during a period of five to eleven years.

There was a maintenance of existing vision in 21 eyes for a period of years, the longest being eight years.

Condition of the tension after operation.— There was an immediate diminution of tension in 112 eyes.

There was a permanent diminution of tension, for as long as the patients were under observation, in 24 eyes. There was no apparent effect produced on the tension in 3 eyes.

Condition of the field after operation.— Owing to greater care having been exercised in choosing the cases for operation in this second series of 60 cases, there was no further narrowing of the field of vision in any eye, as the immediate result of the operation. But as the months and years passed there was a slow but steady increase in the concentric narrowing of the field in 92 eyes. In 16 eyes the final result was absolute glaucoma.

Brief resumé.— 1. Temporary improvement of central vision after iridectomy in 14 eyes.

2. No permanent improvement of vision in any eye.

3. No impairment of central vision in any eye.

4. Slow but steady failure of central vision after iridectomy in 94 eyes, or about 70 per cent., during a period of five to eleven years.

5. Maintenance of existing vision after iridectomy in 21 eyes for a period of years, the longest being eight years.

6. Immediate diminution of tension after iridectomy in 112 eyes.

7. Permanent diminution of tension after operation for a period of three to eleven years in 24 eyes.

8. No apparent effect produced on tension by operation in 3 eyes.

9. No immediate increase in narrowing of the field after operation in any eye.

10. Slow but steady diminution of the field as time elapsed in 92 eyes.

11. Absolute glaucoma the final result in 16 eyes.

12. Apparent arrest of the progress of the disease as to central vision, condition of the field, and tension, in 21 eyes.

The best results from the operation, both as to visual acuity and field of vision, occurred in those cases in which the central vision was the best and the field was the least encroached upon, at the time of operation.

From a careful consideration of the 110 cases reported in the two series of cases, I cannot say that my experience and observation have revealed any new facts by which we can establish a prognosis as to whether any given case should be treated by operation or by the use of myotics.

Furthermore, it would seem as if the apparent necessity for continuing the use of myotics after the operation, befogs the judgment as to the lasting effect of an iridectomy on the progress of the disease. In most, if not all of these cases, if the local use of myotics after the operation is for a time omitted or entirely discontinued, the ultimate results are more unfavorable.

From a very close study of the results of operation in individual cases, it would seem that the prognosis for surgical interference is less favorable, the earlier the age of the patient at which the disease first manifests itself. Some curious facts are sometimes elicited by a careful study of each case, such as the following: The number of cases in which the tension remained normal after operation is decidedly greater than the number of cases in which the visual acuity was maintained.

Conclusions.— My own experience in the operative treatment of chronic glaucoma has not led me to regard this method of treatment as a certain means of *cure,* since in the great majority of the cases, the operation is not followed by the hoped-for success, while in a considerable number of the patients there is immediate impairment of vision induced, and in some rapid blindness. We must change our mental attitude and learn to look on iridectomy, not as a means of *cure,* but as a method of either arresting the course of the disease, or of delaying its progress.

Furthermore, it is not so much the *operation* which arrests the disease, but the *early performance* of the operation.

The view that iridectomy should be regarded as a last resort in chronic glaucoma should be stamped as absolutely wrong, for experience teaches that it is very bad surgery.

The operative effect of iridectomy in simple chronic glaucoma is more certain and immediate, the earlier it is done. The slightest narrowing of the field of vision, whether for form or for color, associated with failure of central vision, increase of tension, and cupping of the disc, demand immediate operation. Furthermore the beneficial effect of an iridectomy stands in direct proportion to the increase of tension. An early iridectomy, while the iris is still mobile, the field but little contracted, and the cupping of the optic disc slight, very often arrests the progress of the disease for a long period of time. *Done early,* it offers better prospects for the arrest of the process for a long period of time, than other methods of treatment now at hand.

DISCUSSION.

DR. RISLEY: Will Dr. Bull please define chronic glaucoma?

DR. JACKSON: May I ask whether the pupil is in such cases dilated above the normal and are there also exacerbations?

DR. BULL: It represents to me, occasional, interrupted loss of accommodation, never complete but partial, varying at different periods of the 24 hours (and this opinion is based upon having examined many of these patients very late at night, for my own satisfaction), occasional partial dilatation of the pupil, never complete dilatation, impairment of central vision, concentric narrowing of the field of vision, cupping, more or less marked, of the optic disc of the glaucomatous type, beginning on the temporal side of the disc, and increased tension which at times is entirely absent and therefore requires repeated examinations to make the diagnosis; and when the tension is increased, under the ophthalmoscope, one sees a distinct pulsation, not only of the veins but of the arteries, which can be traced to the periphery. If I find these symptoms in a patient, even though some of them may be absent at times, I am satisfied that person has chronic glaucoma, and having become satisfied on that point, the earlier the operation is done the more satisfactory will be the results.

DR. DE SCHWEINITZ: I desire to congratulate Dr. Bull on the excellence of his paper. Apparently there is great difference of opinion in regard to a suitable definition to be applied to chronic glaucoma. As I understand the matter, this type of disease is characterized by an absence of the signs of glaucoma in the anterior aspect of the eye, at least on ordinary inspection, that is to say, there is an absence of congestive symptoms and pain is lacking. The tension of the eyeball, however, is always increased at some period of the disease, but this symptom is not constantly present, or it may be present at one portion of the day and not at another, or be found during the night hours and not during the daytime. The visual field generally presents a contraction of some sort, most frequently on the nasal side or supero-nasal quadrant. The color fields present a restriction corresponding with that of the form fields and not the disproportion between the extent of the form and the color fields seen in optic nerve atrophy. Practically always, it seems to me, scotomas will be found, either those of the Bjerrum type or analogous ones, which I have myself somewhat elaborately described. Recent improved methods in perimetry are especially valuable in determining them. Most important in the investigation of this form of glaucoma are disturbances in the light-sense. The light perceptive power in chronic glaucoma is lessened, while the light-difference power is relatively not greatly interfered with, and Wahlfours' insistence that reduction of the light-sense is one of the most frequent symptoms of simple glaucoma and may precede by a number of years the actual discovery of the lesions of this disease, is entirely in accord with my own experience.

Some exceedingly interesting statistical results concerning the treatment of chronic glaucoma have been published within the last year. Thus, the operations in the Leiden Clinic under the charge of Koster indicate that in so-called glaucoma simplex iridectomy failed to check the disease in 73.7 per cent. of the cases, but favorably influenced it in the remainder. Sclerotomy is urged in place of iridectomy, although Koster himself, who deprecates the use of myotics because they are likely to interfere with the proper time for performing iridectomy, while he maintains that sclerotomy gives more favorable results from the visual standpoint than iridectomy, thinks both operations are equally valuable in their effect on increased tension, and therefore iridectomy should have the preference, as it is rarely necessary to repeat it.

Schieck, on the other hand, reporting the results from the Tübigen Clinic with reference to the operative and myotic treatment of glaucoma simplex, states that in the cases treated by iridectomy 7.8 per cent. became blind either immediately or within a short time after the operation, 76.5 per cent. showed a more or less gradual progress in the loss of function, while 15.7 per cent. showed only a cessation of the process, that is, no increase in functional disturbance for at least two years. He attributes the comparatively unfavorable results to the long period during which the observations were made. In so far as myotics are concerned, the results were progression in the disease in 61 per cent. of the cases, checking of the process in 39 per cent. The number of cases investigated, however, was much smaller than the operative cases.

Much more rosy are the statistics presented to the Hungarian Ophthalmological Society by Grosz, who maintains that he had success (how great a success is not stated) in 70 per cent. (!) of the cases of glaucoma simplex which were submitted to operative interference.

DR. CLARKE: I have been very much struck by the variation between different operators as to what they mean by iridectomy in glaucoma. Will Dr. Bull please tell us his method and what width or amount of iris he removes? Some years ago I brought up this question in this Society and found a great difference of opinion as to the size of the iridectomy required to enable one to obtain good results. In London I obtained access to the records at Moorefields and was struck by the frequency with which bad results had followed iridectomy. In many of our iridectomies I think we do too much, more than is necessary, and for many years I have made only a narrow iridectomy, getting as near the base as possible; some of the English operators insist upon taking out one-third of the iris.

It may not be entirely pertinent in discussing chronic glaucoma, but I wish to call attention to the fact that when dealing with a very shallow anterior chamber I have found it an advantage to use a probe-pointed keratome to complete the incision which I had started with the usual instrument.

DR. MARPLE: I would like to ask Dr. Bull one or two questions. He spoke of arterio-sclerosis, and I want to know whether he had any intraocular hemorrhages in these cases and whether

they occurred in cases where the evidence of arterio-sclerosis was conspicuous. I was reminded of this possibility by seeing a patient recently where there was evidence of chronic glaucoma and marked arterio-sclerosis.

Another question I would like to ask is, inasmuch as there is sometimes an atrophic element present in addition to the glaucoma, whether he has noticed that the results have been less favorable in such cases than in others. Several observers have noted a difference in the character of the field in the early stages of these two types.

DR. JACKSON: My question as to what constituted simple chronic glaucoma, referred not to the presence of glaucoma but to the variety. What kinds are benefited by operation? I am inclined to think there is a glaucoma, without exacerbation, without change in the pupil or iris until the late stage, that is not benefited by operation. Regarding the class Dr. Bull has referred to, he spoke of the operation not being so beneficial in the younger patients. I think the most brilliant case I have seen, then of two years standing, presented glaucomatous changes in the disc in a woman of 36. Iridectomy was followed by great improvement in the vision and in the field of one eye. The other eye did not improve at all under iridectomy; the disease there was more advanced. I remember one of my earlier cases where the disease had been recognized 18 months before I saw her, in which was a great improvement after iridectomy. But when I last saw her, 16 years after the operation, she was absolutely blind in both eyes. Improvement was maintained for 8 or 10 years and then failed rapidly. I think the iridectomy was justified by the history, but it seems to me there is a class of chronic simple glaucomas, such as Dr. Posey referred to last year at the American Medical Association, that is better treated by myotics.

DR. BULL: I will endeavor to answer the questions as fully as I can. First let me say that statistics of an operation coming from a large institution in which there are a number of operators, are much less valuable to us for drawing conclusions than the cases operated upon by a single man. There are scarcely any two men who do a similar operation in exactly the same way, therefore the statistics gathered from the work of one man, no matter who he is, are better. In operating I generally make use of a broad lance knife. If, however, the anterior chamber is very

shallow, so that the iris is almost in contact with the cornea, and that is very rare in what I call chronic simple glaucoma, I use a narrow bladed cataract knife. I make the incision with the keratome back of the iris, placing the knife tangential to the eyeball and pass the knife straight through by a single motion until it enters the anterior chamber. I then excise a large piece of iris, at least 1/5 of its circumference.

I have never seen in any of these cases showing unmistakable evidence of arterio-sclerosis, any hemorrhage. I should hardly expect it unless there was a very high degree of tension. In the cases reported in these papers there was never any external evidence of intraocular disease and never any sign of irritation or inflammation.

In regard to Dr. Marple's question whether there was unmistakable evidence of atrophy, I suppose he means atrophy of the optic nerve, and I cannot answer that, for while I might suspect its presence, there could be no possible proof except by microscopic examination. To suspect it because the nerve is pale is not sufficient, for we might suppose its paleness due to the continuous tension.

Dr. Risley: May I ask another question regarding this last point? After an iridectomy, if you have no reason to believe there has been an increased tension, and yet there has been a progressive narrowing of the field of vision, is that evidence of increasing blindness being due to the atrophy?

Dr. Bull: That would not be sufficient proof for me. Our indecision or unwillingness to make positive statements regarding glaucoma is because we do not know what it is.

GLAUCOMATOUS EXCAVATION OF THE LAMINA CRIBROSA WITHOUT EXCAVATION OF THE PAPILLA, AND WITH MARKED PAPILLITIS IN A CASE OF ACUTE INFLAMMATORY GLAUCOMA.

BY BROWN PUSEY, M.D.,

CHICAGO.

At the International Congress of Ophthalmology held in Utrecht in 1899, Axenfeld showed sections of an eyeball which presented the unique and very interesting condition of glaucomatous excavation of the lamina cribrosa without excavation of the papilla and with marked papillitis. Clinically the case was one of acute inflammatory glaucoma. Later Kruckenberg[1] reported this case in detail and discussed three possibilities as regards the cause of the anatomical findings. Rosher[2], in 1901, reported a case showing findings very similar to those of the above case. He also discussed the question of aetiology. Recently I have studied a case in which the findings in the nerve head are exactly similar to those described in the case of Axenfeld-Kruckenberg, and one in which the aetiology appears plain.

The patient was a woman, fifty-three years old. In June, 1900, she presented herself at the clinic of Dr. Hotz suffering with acute inflammatory glaucoma in the left eye. She stated that during the preceding three or four months she had suffered from recurrent attacks of pain in the eye and had at times seen halos around lights. The vision had failed rapidly. Dr. Hotz made an iridectomy. Following this operation there was severe irido-cyclitis. During the next few months there were recurrent attacks of pain, and six months after the iridectomy, when the

[1] Kruckenberg, F. Glaucomatöse Excavation der Lamina Cribrosa ohne Excavation der Papille bei ienem Glaucoma inflammatorium acutum. Klinische Monatsbl. für Augenheilk. 1900, xxxviii, Beilageheft, p. 47.

[2] Roscher, A. Ein Fall von glaucomatöser Excavation der Lamina Cribrosa ohne Excavation des Sehnerven. Klin. Monatsbl. für Augenheilk, 1901, xxxix, 947.

patient came under the care of Dr. Westcott, to whom I am indebted for the tissue and the history, the eye was quiet; the anterior chamber was shallow, the lens was thickened and cloudy, the tension was +1, vision =6/20 and the field was narrowed at the temporal side; the fundus could not be seen. Right eye showed peripheral opacities of the lens, there was no cupping of the nerve head, vision =6/12+, and the field was normal. The tension of the right eye was increased. Under local anaesthesia the swollen lens of the left eye was extracted. The operation was without difficulty, but considerable lens matter was left behind. Three days later the patient was given a general anaesthetic, the wound was opened and an attempt was made to remove the remaining lens matter. Following this there was severe irido-cyclitis and fifteen days later the eye was enucleated. The tissue was fixed in formalin and imbedded in celloidin. Sections were made in various planes and stained with various stains.

Macroscopically the tissue shows nothing of interest except a detachment of the retina and choroid.

Microscopical examination shows the episcleral vessels engorged and the tissue swollen and full of new cells. The cornea shows the two operation wounds. The wound made for the iridectomy has healed; the wound for the extraction of the lens has only partly healed. In sections through the closed part one sees the typical picture of a healing wound of the cornea. Around the wound externally, there are many lymphocytes, plasma cells, mast cells, and a few polymorphonuclear leucocytes. There is practically no anterior chamber, the iris and cornea being in contact in many places. Some sections show incarceration of the iris in the corneal wound. In the angle of the anterior chamber some sections show adhesion between the iris and the cornea, others show that such adhesion has previously existed but has been partially or totally broken loose. The vessels of Schlemm's canal in some sections are full of blood. The pectinate ligament in some sections is a mass of dense tissue; in others it is more open. The spaces of Fontana are filled with débris and pigmented cells; pigmented cells are also found in

abundance around the vessel wall of the circulus venosus sclerae; similar cells are also in the perivascular spaces of the perforating vessels of the limbus. The iris is atrophic and is adherent to the lens capsule. There is a good deal of lens matter present. The lens and the capsule are caught slightly in the wound. Where the lens is caught it shows an increase in cellular elements; in other parts there are degenerative changes. The ciliary body is oedematous, its blood vessels are engorged with blood, and it shows an increase in cells. The same may be said of the ciliary processes. The choroid is the seat of an albuminous exudate, which is mostly in the external layers and has pushed the internal layers and retina inwards, giving rise to what macroscopically looked like detachment. In places in the exudate there are masses of mononuclear leucocytes. The choroidal vessels are full of blood. The retina shows no marked changes except in the region of the papilla where it is swollen and thickened and pushed away from the head of the nerve as in choked disc (see figure).

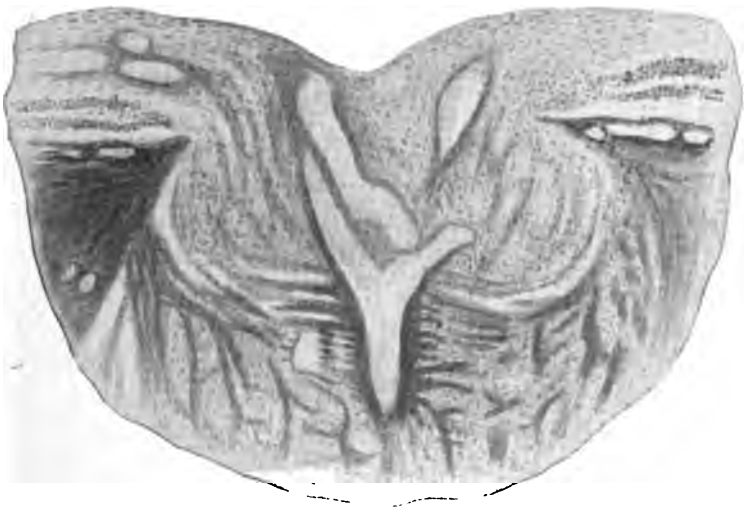

The head of the optic nerve is most interesting in that the lamina cribrosa is pushed back just as is the case in a marked glaucomatous cup, but there is no excavation in the papilla. The cup made by the pushing back of the lamina cribrosa is filled with

nerve fibers (see figure). In the center of the papilla there is a slight depression like a physiological cup. There is some increase in cellular elements in the nerve and the nerve fibers are swollen. The interstitial tissue is increased, the blood-vessels are prominent and their walls thickened. There are no "holes" or caverns such as Schnabel and others have described in optic nerves of glaucomatous eyes.

Briefly the clinical course of the case and the histo-pathology may be summed up as follows. Clinically there is the typical history of a rather rapidly developing inflammatory glaucoma. Iridectomy gave some relief, but after six months the tension was + 1. Again the eye was operated on and this operation was followed by a severe inflammatory reaction. Twenty days later the eye was enucleated. Anatomically there exists in the anterior part of the eye the conditions which mark an inflammatory reaction of subacute type; posteriorly there is a marked papillitis, and a marked cupping of the lamina cribrosa, but no excavation of the papilla. The nerve shows atrophic and inflammatory changes.

To explain the interesting findings of this case of glaucomatous excavation of the lamina cribrosa without excavation of the papilla, and with marked papillitis, I think we have only to appeal to the not uncommonly observed condition of optic neuritis resulting from inflammations involving the anterior part of the eye, and to consider the clinical history. In the light of these facts it is altogether probable that the course of the process has been as follows: There developed in the eye an acute inflammatory glaucoma with the usual result in the nerve head of such condition, viz., cupping. The tension continued over a period of about nine months, but did not bring about complete atrophy of the nerve. Following the second operation there was kerato-irido-cyclitis and resulting from this, neuritis developed in the partially atrophic and cupped optic nerve; this caused a swelling of the tissues, and this again filled up the glaucomatous cup and brought about the choked disc appearance. If I have interpreted the findings and the course of this case correctly — and this seems al-

together probable and agrees with the views of Rosher — the very rare and interesting conditions presented by this case are as regards pathogenesis very simple.

As is well known papillitis has been found clinically and anatomically not infrequently in glaucomatous eyes (this case of course belongs in this larger group), and the question may be said to be an open one, as to whether in such cases, the papillitis is an accidental complication or a part of the glaucomatous process. It would not be fair to generalize on this subject from this one case, but it may be said that this case emphasizes the fact that such a papillitis may be a purely accidental complication.

In closing the discussion of his case, Kruckenberg, bearing in mind one of our most important subjects, makes a very important statement which I think can be appropriately quoted here: Wir Werden uns jedenfalls hüten Müssen, aus solchen eigenartigen Befunden zu viel für die Pathogenese des Glaucoma Schliessen zu wollen.

PROLIFERATIVE UVEITIS.

BY W. ZENTMAYER, M.D.,

PHILADELPHIA.

It is not my purpose to examine critically into the merits of either argument in the interesting discussion provoked by the paper of Fuchs in which he described histological findings considered by him as characteristic of exciting inflammation, but merely to point out the nature of these changes and wherein the views of Fuchs and of Ruge differ, and also to describe the anatomical conditions present in two eyes removed by the writer for undoubted sympathetic inflammation. Fuchs states that of 181 eyes removed because of sympathetic inflammation, or for fear of it, 24 showed proliferate uveitis and that in all but one of

these, reference to the clinical histories revealed sympathetic inflammation, and that in this single exception the clinical diagnosis had been *sympathetic irritation.*

The microscopic examination showed giant cells in 50%, and round cells and epithelioid cells in all of the cases. He holds it characteristic of the choroiditis in the exciting eye that the infiltration with lymphocytes, epithelioid and eventually giant cells, becomes denser towards the posterior pole of the eyeball. The infiltrate occurs first in the outer layers, the capillary layer may long remain normal, the lamina vitrea remains intact even when as the result of the proliferation of the endothelial cells and the immigration of lymphocytes typical foci are found on its inner surface. Usually the choroid is the most affected portion of the tract. In many cases the surface of the iris and of the ciliary body were found free from exudate; as however, surface exudate is found with considerable certainty in endophthalmitis septica, it must be considered as a part of this affection, and when present together with the process which he looks upon as denoting an exciting inflammation, the infection must be considered of a mixed type. He holds that in pure exciting inflammation there is no plastic inflammation present. The infiltrate consists of lymphocytes, epithelioid and at times giant cells. He states that of the ten sympathizing eyes so far studied anatomically, six have shown little or no plastic adhesions, and only two have shown marked plastic inflammation.

Ruge agrees with Fuchs that of the three types of cells, round, epithelioid, and giant, the latter are found in one-half of all exciting eyes, and that in the vast majority of cases when epithelioid cells are found, giant cells are present. He thinks too that the non-discovery of epithelioid cells does not necessarily imply that they are not present and therefore that the inflammation is not of the exciting type, as they might be present though hidden by the round cells. He has found individual giant cells in 3 cases and in various other cases he has demonstrated transitional forms of epithelioid cells to young connective tissue cells in simple traumatic fibrinoplastic inflammation.

Ruge does not consider either the grade or the location of the choroidal inflammation as pathognomonic, as he has found in exciting inflammation, the choroid in some cases intensely and in other cases not at all involved. He therefore agrees with other authors when they assert that "frequently anteriorly, and adjacent to the ciliary body the choroid is found strongly infiltrated while posteriorly it is quite free."

Ruge further asserts that literature shows in 25% of sympathetically inflamed eyes, the presence of a superficial plastic inflammation, and he holds that this does not harmonize with Fuchs' view that when in sympathetic inflammation the iris and ciliary body are bathed in exudate there is present a mixed infection inasmuch as Fuchs entertains the view generally held that the anatomical changes in the sympathizing eye must be, in a sense, the prototype of the typical findings in the exciting eye, as in the secondly inflamed eye complications arising from mixed infections are excluded.

In the following table the writer has arranged the contrasting points upon which, according to Fuchs, the differential diagnosis rests.

ENDOPHTHALMITIS (TRAUMATIC FIBRINOPLASTIC INFLAMMATION.)	EXCITING INFLAMMATION.
1. Location of the inflammation, in the superficial layers of the ciliary body, pars ciliaris retinæ; more posteriorly the retina itself. The underlying choroid involved only when the retina does not afford sufficient protection and then only in the anterior and posterior zones.	1. Location of the inflammation in the stroma of the uvea; the pars ciliaris retinæ and the retina itself often free. The anterior portion of the choroid is the least affected part of this membrane.
2. Exudate is upon the surface of the iris, ciliary body and retina.	2. Exudate confined to the stroma of the affected membranes.
3. Exudate consists of fibrin and leucocytes, the latter composed of polynuclear and mononuclear types, the latter prevailing in proportion to the acuteness of the process.	3. Exudate consists of lymphocytes and the products of the fixed tissue cells, epithelioid and giant cells.
4. Tendency for the infiltrate to travel outwards and perforate the sclera.	4. No such tendency aside from the local destruction of the sclera by pus in panophthalmitis.

The author's cases are as follows:

CASE I. The clinical history was that of a mild purulent panophthalmitis subsequent to an operation for the extraction of a cataract, followed by sympathetic inflammation resulting in blindness. The case is reported in full in the Journal, A. M. A. 1905. The microscopical findings were as follows:

The cornea is almost entirely replaced by connective tissue, which contains many blood-vessels and much round cell infiltration. The surface epithelium is thickened and irregular, sending inshoots of cells into the tissue beneath, and in places is absent over a considerable area. There has been a perforation at the center, and Descemet's membrane is curled up back of the cornea. There is no trace of the lens except for the capsule, which is imbedded in a thick mass of organizing exudate, which presses up against the posterior surface of the cornea. The iris and ciliary bodies are entirely destroyed and can be recognized only by the clumped masses of pigment with which the cellular mass is infiltrated which fills up the interior of the eyeball, and is being converted into organized tissue. To some extent this mass is composed of pus cells. These are particularly prominent on one side in the neighborhood of the ciliary body, and from here a purulent collection surrounds and infiltrates the processes. Elsewhere and in the position of the choroid, the inflammation has more of a plastic character, the cells being mononuclear in type; with them are many endothelial cells, and in certain localities, especially in the posterior half of the eyeball, a great many giant cells. In the tissue there is no evidence of caseation and hence the process is not to be considered tubercular. These giant cells have been long known and well described, especially by Krause, Axenfeld, schirmer and others. The cellular mass representing the choroid is separated from the sclera, as the result of the shrinking of the tissue in the interior of the eyeball, and the space thus left is filled with a moderately cellular exudate which is also being organized, and contains numerous fine capillaries. The retina is almost completely destroyed, only traces of it remaining. The

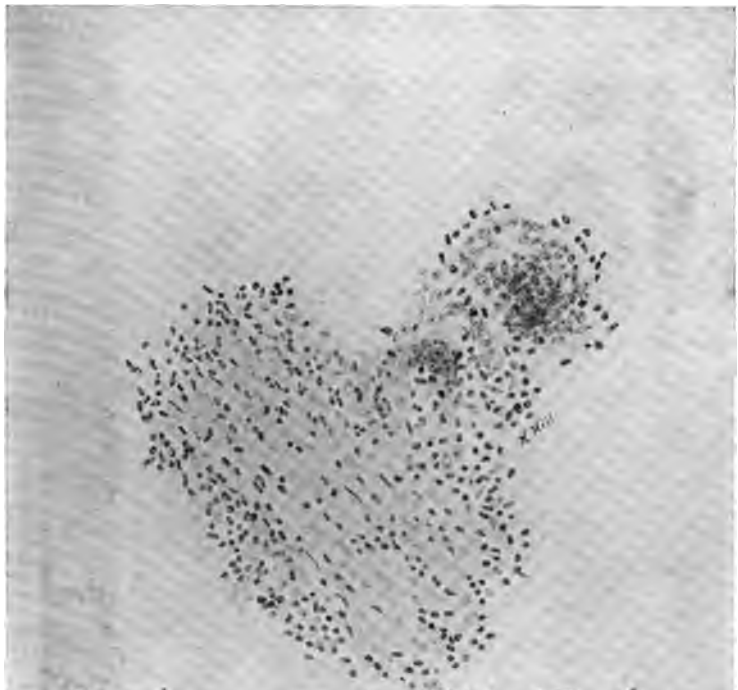

Proliferating Uveitis (Fuchs).
in sympathetic Inflammation
Development of fibroblasts from
Endothelial cells.

vitreous is occupied also by an exudate which contains comparatively few cells but a large amount of fresh blood. It shows also well advanced organization, fine connective tissue processes running in every direction, accompanying newly formed capillaries. The older blood-vessels throughout the eyeball show marked changes; their walls are thickened, the cells of the intima are proliferated, and many of the vessels in the choroid are completely obliterated. The ciliary nerves in the thickened sclera are surrounded by dense mantles of round cells, but outside of the sclera they do not show the condition to as marked a degree. The optic nerve is moderately infiltrated, but the chief excess of cells is in the intervaginal space, especially at their blind extremities within the sclera. Here there is a pronounced proliferation of the endothelial cells, and also many infiltrating round cells. Dr. Shumway summarizes the findings as follows:

"The examination, therefore, shows that the contents of the eyeball has been destroyed by a purulent inflammation (panophthalmitis), which has evidently spread from the anterior segment, from the perforated cornea, and has been succeeded by a plastic form of inflammation, with the production of many giant cells, and the proliferation of the endothelial cells of the tissue. This tissue is now going on to the formation of connective tissue, which is causing shrinking and distortion of the eyeball.

"There is a moderate neuritis, but a more marked perineuritis and an infiltration of the ciliary nerves."

CASE II. Clinical history. G. M. aged 25 years; brakeman, came to Wills Hospital Nov. 3, 1906. On the previous day, while gunning, he had received a charge of shot in his right eye. There was a single perforating shot wound of the ciliary region to the nasal side into which the iris had prolapsed. The vitreous was filled with blood. The eye was blind. The radiograph showed that the shot had not remained in the eye. A fatal prognosis was given and the patient was advised to have the eye enucleated. On the day before Thanksgiving Day he was allowed

a pass until the following Monday, but as there was a suspicious haze of the edge of the disc he was ordered to report daily for examination by the interne. This he failed to do and upon returning, five days later, vision in this eye was found reduced to 5/35. The pericorneal zone was injected, there was a fine precipitate upon the membrane of Descemet and a marked neuroretinitis with peri-papillary œdema. He was at once given a subconjunctival injection of the bichloride of mercury (1-5000) and the blind injured eye was enucleated. The subsequent treatment consisted of the subconjunctival injections of salt solution, atropin, dionin, and inunctions of mercury with the internal administration of salicylate of soda, Grs. xxx t. i. d. The Pupil dilated ad maximum and remained so. The neuritis increased in intensity the first week but thereafter slowly regressed, although when last examined in March was still pronounced and vision= 5/10.

Unfortunately the posterior segment of the eyeball was lost. The miscroscopical examination of the anterior segment made by Dr. H. G. Goldberg, the Pathological Curator to Wills Hospital, shows briefly that the iris and ciliary body were thickened as the result of marked proliferation of the plasma cells and of the endothelium of the blood-vessels. Many of the blood-vessels are being obliterated. There are a few giant cells. There is no superficial plastic exudate. A fragment of the choroid shows the same epithelioidal proliferation, giant cells and obliterating endarteritis.

The histological findings in this case are those designated as "Proliferative Uveitis."

Dr. E. V. L. Brown has pointed out to me that this specimen shows, as have all of the other five which he has examined, that the first part of the ciliary body to be invaded is that just outside of the pigment epithelium, the part which he has termed the extension forward of the orbiculus ciliaris, the analogue of the stroma proper of the choroid, and that in the preserved portion of the eyeball, there being an entire absence of plastic adhesions and

fibrinous exudate upon the surface, the case constitutes a pure example of proliferative uveitis.

It is of interest to note that in the first case the inflammation in the sympathizing eye was of a pronounced plastic type, corresponding to the histological findings in the exciting eye which were those viewed by Fuchs as a proliferative and infiltrative inflammation, and coexisting plastic inflammation (a mixed infection).

In the second case the microscopical findings in that portion of the exciting eye available for examination show an entire absence of plastic adhesions and superficial fibrinous exudate. Again clinically the character of the inflammation in the sympathetically inflamed eye would seem to be a prototype of that found in the exciting eye, as the only evidence of involvement of the anterior segment of the eye was a faint precipitate upon the membrane of Descemet; the inflammation taking the form of an intense neuroretinitis.

DISCUSSION.

DR. PUSEY: May I ask whether Dr. Zentmayer stained any of these preparations for tubercle bacilli?

DR. ZENTMAYER: The specimen was tested for tubercle bacilli and they were not found.

RETINITIS, PROLIFERATING IN CHARACTER, IN A DETACHED RETINA OF TRAUMATIC ORIGIN — REPORT OF A CASE WITH PATHOLOGICAL EXAMINATION

BY WILLIAM T. SHOEMAKER, M.D.,
and
C. M. HOSMER, M.D. (by invitation),
PHILADELPHIA.

The eyeball to be described was enucleated under the diagnosis of glioma; microscopic examination showed the clinical diagnosis to have been incorrect, and an intra-ocular condition present of sufficient interest in the opinion of the authors to warrant the placing of the case on record. As has been commented on many times, and as is well recognized, *pseudo-glioma,* as a diagnosis, although clinically convenient, is essentially negative, and therefore fails of purpose. For this reason the term should not be used, when possible to determine actual conditions microscopically.

The case, Edith C., was referred in consultation to one of the authors (Dr. Shoemaker), April 20, 1906, by Dr. C. C. Bullock of Chatham, Pennsylvania. She was a well nourished girl twelve years of age, whose family history was entirely negative.

When five years old she fell, striking her left eye against the hearth. Shortly after this her mother noticed that the eyes were crossed, but gave to her observation little or no attention. About four years later, or three years prior to consultation, the pupil of the injured eye was seen to be white, following which the eye became injected. From this time headache was complained of, and also pain in the left eye, periodic in character, and occurring about once monthly. No definite history of illness in early childhood could be obtained.

April 20, 1906, the left eye was blind. It apparently had within it a large gray or white growth, seen upon casual inspection, and well demonstrable under focal illumination. The mass or supposed tumor was far forward in the vitreous, its surface being but a few mm. behind the lens. It seemed to spring mostly from the nasal side of the eyeball; was soft looking, somewhat nodular and without movement.

Under full mydriasis, the ophthalmoscope showed a vertical fissure of division far to the nasal side, in and beyond which red fundus and small vessels could be seen with + 10 D. S. Vessels could also be seen far to the temporal periphery, showing apparently through overlying tissue. The palpebral and bulbar conjunctiva, and the entire anterior segment of the eyeball, were free from injection and seemed to be normal in every way. The anterior chamber, iris and pupil were as in the sound eye, the anterior chamber being of good depth and proper formation. The iris reacted consensually, but was inactive for direct stimulation. The movements of the eyeballs were full in all directions. Tension was normal.

The right eye had a vision of $\frac{5}{7\frac{1}{2}}$; was hyperopic 1.5 D., and showed no traces of disease whatsoever. At the time of examination the patient was concluding an attack of whooping cough contracted two months before.

The diagnosis of glioma was made, and the eye enucleated at the Germantown Hospital the same day.

The pathological report on the eye, which was prepared and examined by Dr. C. M. Hosmer at the laboratory of the University of Pennsylvania, is as follows: The eye was fixed in formalin. The retina was detached to the ora serrata, and pushed or drawn into folds. Lying upon the detached retina there is a mass of more or less completely organized connective tissue. This appears as a thicker part on one side, and on the other, stretches away as a narrow band. This arrangement would give a clinical picture of a more or less complete septum, and as the entire retina was bulged forward by sub-retinal exudate would readily

suggest tumor. Passing over the mass, the hyaloid membrane can be traced; it is apparently pulled away from its peripheral attachment on one side, and is adherent to the thicker portion of the connective tissue mass. Lying beneath the thinner or band-like portion of the mass is granular blood pigment. The thicker, or major portion has within it blood pigment and new formed vessels, and is intimately connected with the nerve fiber layer of the retina. Within the retina on this side, are recent hemorrhages and old organizing clots, and about the retinal vessels are pigment deposits with vessel degeneration. It is believed that the thicker mass of connective tissue represents a large hemorrhage into the nerve fiber layer, with subsequent organization, and that the band extending from this was originally a sub-hyaloid hemorrhage, seeping from the first, and undergoing similar organization. It is further believed that this process was subsequent to the complete detachment, inasmuch as the connective tissue mass does not extend into the cone of the detached retina. Within the sulci of the folded retina, are red blood corpuscle collections, and intermingled with these, granular pigment, indicating repeated hemorrhages. The sources of these can be seen to be the nerve fiber layer. Fine fibrils from the central body of connective tissue extend to the periphery where retinal cells of the orbiculus ciliaris are elongated and drawn inward.

Posterior to the retina is a large collection of richly albuminous exudate, which, during preparation, has shrunken, and is so drawn away from the chorioid. The exudate contains a few leucocytes. On one side of the eyeball far forward, there is evidence of a chorio-retinal inflammation in the form of a minute patch. On this side the retinal vessels show occluded lumina with swollen endothelial cells, and are packed about with pigment which is believed to be retinal. On the opposite side, the retinal vessels, especially the arteries, show signs of a low grade inflammation, large mononuclear leucocytes, with an occasional lymphocyte being seen in the perivascular spaces. This may perhaps be a crowding of the perivascular spaces with cells which have been

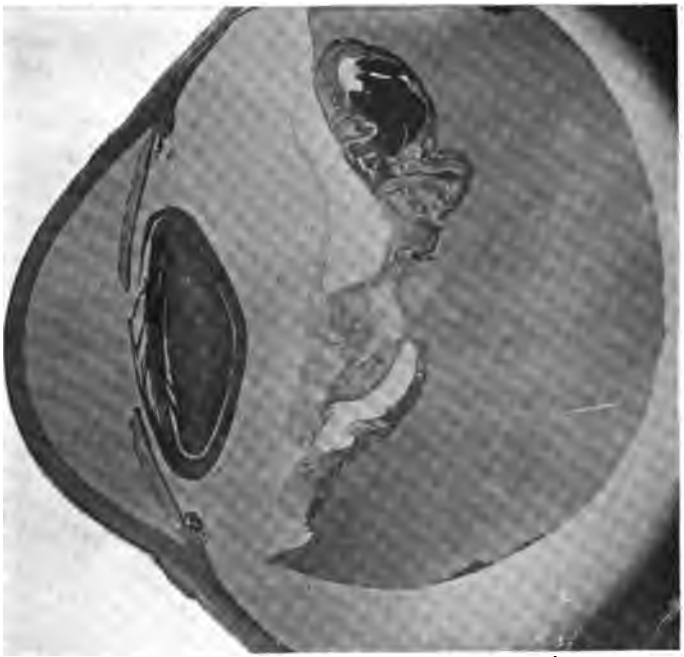

PROLIFERATING RETINITIS IN A DETACHED RETINA

taken up from the organizing clots, instead of a true inflammation.

The rod and cone layer has disappeared entirely, as would be expected when totally separated from its source of nutrition. The pigment layer has for the most part remained on the chorioid. The remaining posterior layers are permeated with the exudate above noted. The nerve fibers have in the main degenerated. The supporting tissue of the retina in its entire thickness seems to be in excess. In places it has an appearance as if combed forward toward the central mass of formative tissue.

The changes in the chorioid so far as they can be studied in a formalin fixed eye, are slight, and of questionable importance. Opposite the point of chorio-retinal attachment, near the ora serrata, there are many lymphocytes. The chorioid on this side is atrophic, and on the opposite side there is evidence of retarded circulation. Large and small drusen bodies are seen on the surface of the chorioid.

The anterior portion of the eyeball, including the small remnant of vitreous, is negative save for signs of slight congestion of the iris and ciliary body, and early degenerative changes in the posterior layers of the lens cortex.

Briefly reviewed the findings here noted constitute the following condition complex: Complete detachment of the retina in a child twelve years old; hemorrhage, formative tissue, new vessels, leucocytes and excess of supporting tissue, all resulting in the formation of a solid mass in the anterior vitreous, clinically resembling a glioma. Absence of uveitis, and of structural changes in the anterior segment of the eyeball. A trauma was sustained when child was five years old, and the present condition had probably been existent to the extent of being noticeable upon inspection for at least three years.

The injury must be regarded as important, and is presumed to be the primary cause of the disturbance. Whether the retinal changes are subsequent to detachment, or the cause of the detachment, we are not prepared to say, but from the absence of iridocyclitis, and chorioiditis, excepting the small area near the ora serrata, which, owing to its minuteness and position need scarcely

be considered, and from the practically normal condition of the remaining vitreous, we favor the view of primary detachment as being most probable. It is also likely that the process once started in a more or less limited detachment, caused further involvement and separation until the detachment became complete. In other words, the process would seem to be almost wholly limited to the retina, and might be regarded as an *endoretinitis proliferans.*

The many changes that may occur in a detached retina have been well described by Ginsberg. His own observations as well as those of deGama Pinto, Nordensen, Velhagen, and others are interesting, and show quite a variety of possibilities. In total detachment, one of two formations is generally assumed: A funnel shaped, or inverted conical detachment, extending from the disk to the ora serrata, or the so-called umbrella detachment, in which the retina, collapsed and folded, proceeds like a stem from the disk, and when about opposite the ora serrata, continues on to the latter as a membrane at right angles to the stem. The latter configuration is usually preceded by, or accompanied by, iridocyclitis. Detachment seldom extends beyond the ora serrata, but occasionally the pars ciliaris retinae is included. (Velhagen).

Excessive folding of the separated retina and massing around the disk, giving rise to a tumor-like mass in this position, has been occasionally observed, and described by deGama Pinto and Velhagen. A detached retina may show inflammatory and degenerative changes, which in certain cases were present before separation, or changes of various character and intensity may occur secondarily in detachments of long standing.

The time at which these secondary changes occur is not definitely known. The rods and cones are always promptly destroyed after detachment. The nerve fiber layer and the ganglion cell layer have been found atrophic after a few weeks. Gliosis or proliferation of the neuroglial tissue, occurs at times and may constitute the essential alteration. Cysts are not infrequently found, and may develop from pre-existing cysts, or otherwise, as

below mentioned. Also, connective tissue formation upon the inner surface is of frequent occurrence.

The retinal blood-vessels always undergo marked changes in old detachments. The vessel walls are thickened, hyalin or sclerotic; the lumina are narrowed and often obliterated. Drusen bodies and blood pigment are found. Hemorrhages may occur, and may be small or large; the latter at times split the degenerated retina and form blood cysts.

Folding of the detached membrane, which is necessarily constant, may by variation give rise to a number of different microscopic conditions. The outer layers only become much folded and convoluted due to relative overgrowth, and appear almost papillary, while the inner layers remain comparatively smooth. The folded surfaces in contact may become adherent in places, and in this way produce spaces and various kinds of cysts. On the other hand the entire retina including the internal limitans may be folded or convoluted. DeGama Pinto describes certain cases of this kind in which sections showed little or no retinal structure, but only irregularly arranged masses of small round cells. There was thus produced a marked resemblance both macroscopically and microscopically to glioma.

DeSchweinitz and Shumway described a detached retina with dropsical degeneration of the visual cells which exactly resembled clinically a glioma.

Of the eight or nine intra-ocular conditions which may be mistaken for glioma, Parson regards as the commonest type a generalized inflammation affecting the chorioid, and which is usually included under the term of "chorioiditis exudativa." This condition he says is wrongly regarded by some as a form of suppurative chorioiditis, but occurring as it usually does in children, as the result of some acute infectious disease, the organisms or toxins of which are not pyogenic, it should not be included among the purulent inflammations.

Treacher Collins on the other hand, who has had the opportunity of examining some very early cases of pseudo-glioma,

thinks that this variety commences as a *retinitis,* although there can be no doubt that the later stages point rather to a primary cyclitis than to a retinitis. He describes a condition very similar to the one here reported, although not of traumatic origin, but in the latter case the condition has remained retinal for at least three years.

A SIMPLE METHOD OF REPRESENTING DIFFERENT FORMS OF OCULAR MUSCLE IMBALANCE BY DIAGRAM.

BY DR. LUCIEN HOWE,

BUFFALO.

In order to discuss intelligently a representation of muscle imbalance we should first decide what muscle balance is, and how it can be represented by diagram.

It is a fundamental fact in physiology that comfortable binocular vision at the near point involves at least three different acts or functions — namely, accommodation, convergence and torsion. When these bear their normal relations to each other we may say that muscle balance exists; when they do not bear their normal relation to each other we have imbalance. In order to appreciate more fully what this statement means, it is well to consider each one of these facts more in detail, and at the same time see how each can be represented by diagram.

First, then, let us see how we can represent this for the normal eye.

(A.) The act of accommodation. This was represented roughly by diagram long ago, by Landolt and other writers on accommodation and refraction. Thus if a horizontal line be divided into any desired number of equal parts, we may select one point which we call zero, and have that show the condition of the ciliary muscle when entirely at rest. Then if each section into which the line is divided represents one diopter of accommoda-

tion, and if the person before us has a power of accommodation of nine diopters, we represent that of course by pointing off nine of these divisions, or, what is more convenient, we draw simply a heavy horizontal line showing at a glance the force of accommodation exerted by that eye or pair of eyes, if they are both practically the same. (Fig. I, A.)

But the act of accommodation takes into account not only the *force* exerted, but also the *resistance* offered to it. Heretofore, in representations of this act, we have counted both factors together, but it is desirable to separate them, because the resistance to accommodation means the degree of inelasticity of the lens. It may also mean the length of the globe which calls for a comparatively slight amount of muscular action in myopia, more in emmetropia, and still more in hypermetropia, this being indeed in inverse proportion to the length of the globe. Now when this resistance which is offered by the lens is normal, we represent it as we did the primary force. We simply draw another horizontal line, dividing it into spaces like the first line. If the resistance is normal for an accommodation of nine diopters, this line which represents the resistance and which we may call R_1 would occupy nine spaces on the horizontal line. (Fig. I, R_1.)

(B.) In a similar way we can represent the power of convergence. Inasmuch as one diopter of accommodation is, under normal circumstances, accompanied by one meter angle of convergence, therefore with emmetropia and normal muscle balance there would be in such a person as is here represented nine meter angles of convergence. Moreover, as under normal circumstances (that is, entire absence of any other form of heterophoria) the amount of resistance offered to convergence by the power of the abductors or by the external check ligaments, or both of these, would also accord practically with a convergence of nine meter angles. (Fig. I, C.) If we wish to show on the line R_2 the resistance which is offered to the convergence in a person who is capable also of nine diopters of accommodation, we must count off on this nine spaces from the infinity point towards the eye, and draw a heavy horizontal line over that distance. (Fig. I, R_2.)

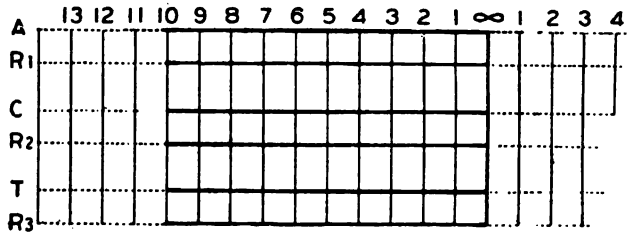

Muscle balance in an emmetrope.

FIG. 1.

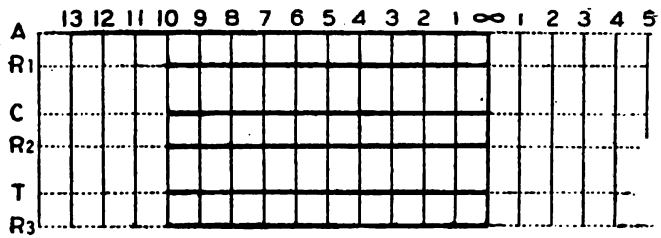

Excessive accommodation of 3 D.

FIG. 2.



Esophoria of 1.50 meter angles.

FIG. 3.

HOW MUSCLE BALANCE AND IMBALANCE CAN BE SHOWN BY DIAGRAMS.

(C.) Finally we should take torsion into account. We know that when the visual axes are in the primary position (that is, in the horizontal plane and perpendicular to the line joining the centers of motion in each eye), the physiological vertical axes are not quite perpendicular, but inclined down from perhaps one-half to one or one and a half degrees. We learned more than a quarter of a century ago, by the measurements of Landolt, published in the second volume of the first edition of Graefe-Saemisch, that torsion undergoes certain changes physiologically with accommodation and convergence. That is, the nearer the object approaches, the more does the upper end of the vertical end of each axis tend to tip outward. This outward tipping decreases when the eyes converge in a plane which is downward, but it increases somewhat when the eyes converge in the horizontal plane, and still more in a plane directed upward. Now the point to which attention is called is this: That inasmuch as we have a certain amount of torsion with each diopter of accommodation, and each meter angle of convergence, therefore when we measure with suitable apparatus the amount of torsion, and find it to be such as occurs with nine diopters of accommodation and nine meter angles of convergence, then we are warranted in constructing another line (Fig. I, T) similar to the first, extending the same distance, representing the power of torsion. As for the resistance offered to this torsion, it must be confessed that we know very little concerning it. But such facts as we have, indicate that a certain amount of such resistance does exist, for otherwise the upper end of each vertical axis would turn altogether too far or not far enough. Therefore we can represent by another line of equal length the resistance which is offered to that torsion. (Fig. I, R_3.)

The foregoing gives perhaps a fair idea of muscle balance and how it can be represented by diagram. There are probably other acts besides accommodation, convergence and torsion which enter into the act of comfortable binocular vision at the near point, such possibly as certain motions of the vertical muscles, which are not

yet understood. But for practical purposes these are the three important functions.

From this it is easy to understand how the diagram which represents muscle balance can be varied for different forms of imbalance. Thus, suppose to a pair of emmetropic eyes we apply a full dose of atropin. The effect is to set at rest entirely the action of the ciliary muscle. In that case we would erase the line which represents the power of accommodation. But as the length of the eye is normal, and the lens is normal, the resistance offered to accommodation would remain as before, and consequently would be normal for a person of that age. For that person also convergence with the resistance offered to it and torsion with the resistance offered to it would also remain normal.

Again, let us suppose that in a pair of normal eyes we use a solution of atropin so weak as to leave part of the accommodation still unimpaired, or suppose a case of diphtheritic paresis in eyes otherwise normal, but reducing the power of accommodation to only three diopters, for example. That would be represented by a line extending from the zero point to three diopters, or what is the same thing, to three meter angles.

Or (Fig. 2), suppose we have to deal with an emmetrope of such an age as to have an accommodation of about ten diopters with corresponding convergence and torsion, and suppose we apply to these eyes a solution of eserin, sufficient to produce a spasm of the accommodation of three diopters. That would be represented by extending the line on A, which represents the accommodation, up to the point marked thirteen.

As we thus represent variations in the accommodation on the first line, so can we represent on the second line R_1 variations in the degree of resistance offered to the ciliary muscle. Thus if we have to deal with a myope of three diopters, of such an age that he would naturally have eight diopters of accommodation with corresponding power of convergence and torsion, then, inasmuch as such a person does not make any effort at accommodation short of three meter angles of convergence, evidently this

power of convergence would be represented by extending the line from the point three to eight.

Several of these supposed cases are not shown in the diagrams but can be easily figured.

In a hypermetrope of four diopters of the same age, with a normal ciliary muscle and with normal power of convergence and accommodation, evidently the line which represents the resistance offered to the accommodation will begin four points beyond infinity, and unless there were something abnormal about the resistance otherwise, it would reach the point four. In other words, there would be eight diopters altogether of resistance offered to the lens. So much for accommodation.

Let us turn now to convergence. Until recently there was no way by which we could express an abnormal convergence, latent or apparent, in terms of the meter angle. That was because we did not have a table which showed at a glance what was the actual size of the meter angle with a given length of the base line. The formula is a simple one as follows: $\text{Sin } C = \frac{d}{n}$. In this C is the angle of convergence, d is one half the interocular base line, and n is the distance of the object. Several years ago one partial table of this kind was published by Nagel, another later by Landolt, but both were very short. More recently the table was improved and only during the last few months it has been revised and published in more complete form in a volume on the "Muscles of the Eye" by the writer. With this table it is a simple matter to ascertain at once the amount of convergence which is made in degrees and minutes when we know the interocular base line and the amount of convergence in meter angles. For example, suppose we have an esophoria (Fig. 3) of six degrees in a person who has a base line 62 millimeters; that means, of course, an inward deviation of three degrees for each eye. Now when we consult our table we look down the first column to the point indicating a base line of 62 millimeters, and follow out on that line until we find the meter angle which corresponds to a convergence of two and one-half degrees for each eye.

If we have already agreed that each of these divisions of the horizontal line shall represent one diopter of accommodation or its equivalent (that is, one meter angle of convergence), it is only necessary to mark off on that line (Fig 3, C) a corresponding distance, and it gives at once a diagrammatic representation of the power of convergence in that individual.

In attempting to represent anomalies of torsion by these diagrams, the table just referred to is of decided value.

For example, let us suppose that a person with otherwise normal eyes, and with an interocular base line of 62 millimeters accommodates and converges for a point one-sixth of a meter distant. On consulting our table we find that this means a convergence of 10° 43″. Also, if we turn to Landolt's table we find that with a convergence of 10° the upper end of each vertical axis tips outward under normal conditions 2° 50″, or in round numbers 3°. But let us suppose that on measuring the amount of torsion of our patient with such means as we have now at command, we find that each axis tips outward say 5°. Now Landolt's table shows that a tipping outward of 5° or more exactly 4° 50″ corresponds to about 18° of convergence. On referring a second time to our table where degrees are converted into meter angles, we find that a person with a base line of 62 millimeters when converging 18° really makes about ten meter angles of convergence. In other words, we have in this person an excess of torsion which corresponds to the difference between six and ten, or four meter angles of convergence, or what would be about four diopters of accommodation.

Now this can be represented in our diagram. That is, if the age of the person is such that under normal conditions he can accommodate and also converge say six diopters, and if the resistance to each one of these factors is normal, then on the horizontal line which represents the power of torsion we would draw the heavy line from the point representing infinity not to six but up to the point marked ten.

It is needless to say that insufficient torsion, when that occurs, is represented in the same way.

As for the resistance offered to torsion, the truth is we do not know much about it in any way, but such facts as we have indicate that under normal circumstances the resistance to torsion is just what we find in proportion to the resistance offered to both the accommodation and convergence.

The fact should also be stated again that as far as torsion is concerned our methods of measurement are somewhat complicated, and accurate measurements require a subject who is intelligent, often some training is necessary, and the examiner must be accustomed to laboratory methods. With these, however, in spite of the errors which enter into the measurement, a very fair degree of approximation can be obtained.

A question may arise. Of what use is all this?

In the first place, it is always desirable in scientific examinations to make our statements as exact as possible.

Second, it is a distinct gain to express heterophoria not only in degrees, but in terms of the meter angle. It relates these two to each other.

Third, it is also a gain when we can express torsion even approximately in the terms of the meter angle.

Finally, it clarifies our ideas of a given case when we can make for ourselves a picture of the condition of the ocular muscles in a given case. Of course it is useless to think of recording every case which is met with in any such fashion. In by far the greater part of cases of muscular anomalies which come to our offices it is only possible at the first visit, or at the first few visits, to make a provisional diagnosis and base our opinion and prescriptions upon that. But in the cases which do return to us with the same complaints in spite of our best efforts, it becomes our duty to work out the details of the diagnosis to as great an extent as possible. In attempting to do this it has seemed to me that we get a better idea by thus making a diagrammatic representation of the imbalance which exists.

In proportion as we strive to be exact in the study of these cases we weed out useless theory from this complicated field

which we call muscle imbalance. With mathematical facts we lay a firm foundation, and only on such a foundation can we build up our science securely and well.

AN UNUSUAL FORM OF HEREDITARY CONGENITAL CATARACT OCCURRING IN SEVERAL MEMBERS OF A FAMILY.

BY BURTON CHANCE, M.D.,
PHILADELPHIA.

In this report I intend briefly to describe the case of a family in which five members are affected by a very definite and peculiar variety of congenital cataract. The family consists of a man, his wife, five sons, and one daughter; the persons known to be affected are the father, the third, fourth, and fifth sons, and the daughter.

The man has no recollection of his parents having disease of their eyes, though he remembers that they wore glasses in his youth. His father lived to be four-score; his mother was already a widow with one child when she and his father married. By this union there were three sons. The stepsister had bad sight, and one of her five children, a girl, had eye troubles. His two brothers had good sight, but as he has been separated from all his family for many years, nothing positive as to their history can be given. His wife, the mother of all his children, has good sight, and her history is negative.

The first member of this family I saw was the sixth child, a boy of eleven, who came for the treatment of a "black eye." The father said he had noticed that this boy at six could not see as well as the other children could at that age; later he got glasses for him at a jeweler's. Except for an attack of measles, and of scarlet fever, his health had been good. He was not as tall as boys of his age usually are, neither was he as robust mentally. He made but little progress at school.

In bright light the boy appeared dazed, and when wishing to examine objects around him, he peered at them. The vision of each eye was only 5/45, but with — 1.75 — 4.00 ax 180°,= 5/15. The eye-balls were well formed and free from external anomalies, while the corneas were clear and the pupils round and mobile. In the center of each lens was an unusual opacity. This opacity had the form of a sharply defined circular disc; it was very thin and placed deep in the lens, apparently between the nucleus and the posterior pole. These discs were about the size of the pupillary spaces, being placed symmetrically, of the color of boiled sago, and of a minutely granular consistence. In the right one there were clumps of opacities which reminded me of mitotic figures; in the left there was an indefinite star in the center, in the sections of which, arranged in a radiating manner, there were the same kind of denser masses as seen in the right. (Fig. 1.)

While the discs were translucent, no details of the fundus could be made out through them, though, beyond their circumferences, the funduses could be studied perfectly, for the peripheral portions of the lenses were quite clear. The retinas and choroids were well preserved for so marked a grade of myopia. No uveal anomalies were seen, and no evidences of rachitis found.

I noticed that the boy's father also peered about while finding his way in the darkened room. He allowed me to examine his eyes, and, to my surprise, I saw in them opacities in the lenses similar to those found in his son's. He is a railway engineer, and he rather resented the suggestion that his sight could be defective. He is moderately myopic, and wears glasses while reading.

The cataract in his right eye was reniform, with the hilum on the lower border; that in the left was almost circular, having a flattened base. Each was as though a film of sago-like substance had been placed behind the pupil, which on magnification was seen to be homogeneous and finely granular. (Fig. II.)

The third son, aged twenty, is a machinist, and has good sight. Deep in his right lens was a dense opaque clump in the

nasal half of a faint circular disc; while in the left there was a disc of such extraordinary thinness as to be scarcely detected — it might have been likened to a simple condensation of the crystalline substance. (Fig. III.)

The daughter, a healthy, rosy-cheeked girl of sixteen, also had discs in her lenses; that in the right was studded with tiny dots, and in the center was a dense opacity. In the left one were several clumps with fine dots about them. (Fig. IV.) Her vision was 4/60, in the right, and 5/30, in the left eye, but this was due to a general myopia of four diopters.

The fourth son, a boy of thirteen, a myope whose vision was 5/15, in the right, and 5/30, in the left, also had discs in his lenses. In his case they were dot-like in consistence, but, irregularly arranged in each, were six distinct circular vacuoles. (Fig. V.)

These cataracts were partial and circumscribed, and they could be seen only by using strong lenses in the ophthalmoscope. They were of the same kind in every case, and they were large enough to block the usual pupillary spaces. When the pupils were dilated the opacities shone out and measured about four millimeters in diameter. In each person they were double, and without exception accurately symmetrical in the two eyes. They appeared to be stationary.

The exact position of the opacities was hard to define. They were not polar, neither were they nuclear, but they seemed to lie between the nucleus and the posterior pole. The discs were almost without thickness, and I can only conjecture as to their nature.

The visual acuity was below normal in every case, for myopia was defined in each, varying from less than one diopter, in the case of the father, to five diopters of compound astigmatism in the youngest child.

The father was a tall, muscular man, and the members of the family seen, including the mother, were apparently healthy. The teeth of the mother, of the daughter, and of the fourth son were badly decayed, though in none of the family were there signs of

Illustrating Dr. Chance's Articles on Congenital Cataract



Fig I

Fig II



Fig III

Fig IV

Fig V

rachitis. At present the branches of the family cannot be reached, for they are lost in Germany, so that it is neither possible to know how many other persons are affected with cataract, nor to ascertain from which stem the defect has descended. It is probable that it was transmitted from the mother of the man, for she had to use glasses early, and her daughter had defective sight, and so had that daughter's daughter.

The cataracts in this series are so remarkably like those described by Nettleship and Ogilvie, in their paper, "A peculiar form of hereditary congenital cataract," read before the Ophthalmological Society of the United Kingdom, on June 14, 1906, that one might think this paper a special chapter of their report. These authors found in four generations of a family, whose pedigree extended for seven generations, nearly twenty instances of a form of cataract quite like that in these cases which I have described. To them the cataract was unique.

I have never seen any cataracts like these, and I venture to present this report because of the rarity of their form, and because of their occurrence in so many members of one single family.

CONCERNING THE VASCULAR CHANGES IN THE UVEAL TRACT, RETINA AND OPTIC NERVE IN QUININE BLINDNESS AND IN TOBACCO-ALCOHOL AMBLYOPIA, AND THE LESIONS FOUND IN THE EYES OF A MAN WHO DIED FROM THE EFFECTS OF DRINKING METHYL-ALCOHOL.

BY G. E. DE SCHWEINITZ, M.D.,

PHILADELPHIA.

The object of the present communication is to summarize briefly the literature pertaining to the vascular changes in the toxic amblyopia in so far as quinine, tobacco and alcohol are concerned; to record a restudy of my sections of animals' (dogs')

eyes blind from the effects of toxic doses of quinine; again to correct certain faulty interpretations published in the original report of the histology of these eyes; and to describe the microscopic findings in the eyes of a man dead from meythl-alcohol. Exclusive of the case of methyl-alcohol poisoning, the paper does not in any way concern itself with the influence of these toxic agents on the nerve tissues, i. e. the retina and optic nerve, either in so far as these actions are well established or are still in dispute.

Ophthalmoscopic Vascular Change in Quinine Amaurosis.—Extreme diminution in the size of the retinal vessels, both arteries and veins, is the rule. Large veins, with normal arteries, or those which are actually or relatively diminished in caliber, have been reported in an early stage of the blindness, for example, by Buller[1]. Later the usual contraction takes place. Mellinger's[2] observation of one case in which the larger retinal bloodvessels were first emptied of blood, but the capillaries, even those on the disc, remained filled, has, in a measure, been confirmed by Gruening[3], who has noted a mild form of quinine-amaurosis, with less pronounced contraction of the retinal arteries and veins, and a decided fullness of the capillaries of the disc which remained as a permanent condition. In Mellinger's patient the filled capillaries later collapsed and the appearances of permanent atrophy supervened.

Occasionally a gray haze in the retina and a cherry-colored spot in the macula, almost exactly repeating the picture of obstruction of the central artery of the retina, has been seen, for example, by Gruening, Buller, Seeligsohn, Browne; or a similar appearance without a cherry spot, for instance, by Herbert Harlan[4].

Horner[5] observed in a patient with long-standing quinine blindness smallness of all the retinal vessels, conversion of the

1 Trans. of the American Ophthal. Soc., 1881, p. 262.
2 Klin. Monatsbl. f. Augenheilk., 1887, xxv, p. 57.
3 N. Y. Eye and Ear Infirmary Reports, 1897, vol. v, p. 6.
4 Ophthalmic Record, 1897, p. 113.
5 Quoted by Brunner, Inaug. Dissert., Zurich, 1882.

superior nasal artery into a white string which was regarded as indicating a thrombosis of this vessel, and white thickenings along the inferior nasal and temporal arteries. In these respects Frank Judson Parker's[6] observation is even more remarkable. Four days after the onset of complete quinine blindness, in a man aged forty-three, as the result of the ingestion of 240 grains of sulphate of quinine in twelve hours, Parker found in his ophthalmoscopic examination of the right eye: "Extreme pallor, nerve pearly white, thrombus of the inferior branch of the retinal vein, the blood column broken in places, endoarteritis of the large branches and obliteration of the small arteries, veins dilated. The left fundus showed the same condition, except the thrombus was in the superior branch of the retinal vein."

In Seeligsohn's[7] patient, a woman, aged 36 years, who acquired blindness as the result of the ingestion of six grams of the drug within three days, the eyeground at first presented the picture of embolism of the central artery of the retina, namely, a diffuse white opacity of the retina, a cherry spot in the macula, narrowing of the blood-vessels and obscurations of the margins of the nerve-head. In the course of a year distinct angio- and perivasculitis were evident, and the vessels were sheathed in white and the blood streams very small. In some places there was positive obliteration and only white strings remained in the place of the vessels. In the third-year after the poisoning, in the right eye there were peripheral areas of choroidal change and sclerotic alterations in the choroidal vessels.

In a case recently seen with Dr. Carl Williams in the person of a young woman, five years after quinine amaurosis, following the ingestion of 80 grains of the drug in one dose, I noted smallness of both sets of retinal vessels and encasing of the arteries, chiefly the inferior nasal branches, with delicate white lines traceable to the periphery, simulating the appearance of perivasculitis.

The *ophthalmoscopic picture of quinine blindness induced in dogs,* in general terms, resembles that seen in man. Thus, Brun-

---

6 Archives of Ophthalmology, xxxv, 1906, p. 420.

7 Centralbl. f. Prakt. Augenheilkunde, June, 1906, p. 182.

ner produced marked ischemia of the retinal vessels; Barabaschef[8] decided thread-like narrowing of the retinal vessels; and I[9] noted, practically always during the stage of blindness, marked contraction of the retinal vessels, particularly of the retinal arteries, and in one dog poisoned with a hypodermic injection of 25 grains of quinine, that is, a grain to the pound, in the right eye, the upper vein just before it left the disc showed a constriction suggesting a thrombus. There were however, no hemorrhages in the eye. Later there was complete obliteration of the vessels on the disc and the arteries were reduced to faint threads. In a dog in which the blindness was continued for 61 days, and in which examination subsequently showed complete atrophy of the optic nerves, the arteries were marked by faint white lines and only the temporal veins were visible and these were greatly contracted. Holden[10] described in a dog blinded with quinine marked pallor of the disc and constriction of the retinal vessels almost to obliteration. Similar observations have been made by De Bono, Atland[11], and other observers.

Vascular changes in the choroid either do not occur, or have been but little studied. True, Dickinson[12] recorded congestion of the retinal and choroidal vessels, a condition of affairs which in all likelihood was not due to the quinine. The choroidal changes in Seeligsohn's cases have been referred to.

Stölting[13] observed in a case of quinine blindness occurring in a young man, in addition to the classical symptoms of this affection, an *atrophy of the iris,* which was evident two years after the beginning of the disease. The irides of both eyes were atrophic in such a manner that the structure was translucent, exactly as it is in an albino's eye. In the following year, although the vision and visual field had improved, the retinal vessels were still

8 Archiv. f. Augenheilk., xxiii, p. 91.

9 Trans. of the College of Physicians of Philadelphia, 1890; Trans. of the Amer. Ophthalmological Society, 1891.

10 Trans. of the Amer. Ophthalmological Society, 1898.

11 Klin. Monatsbl. f. Augenheilk., xlii, 2, 1904.

12 St. Louis Medical and Surgical Journal, 1881, 41, p. 352.

13 Archiv. f. Ophth., lv, 1903, p. 85.

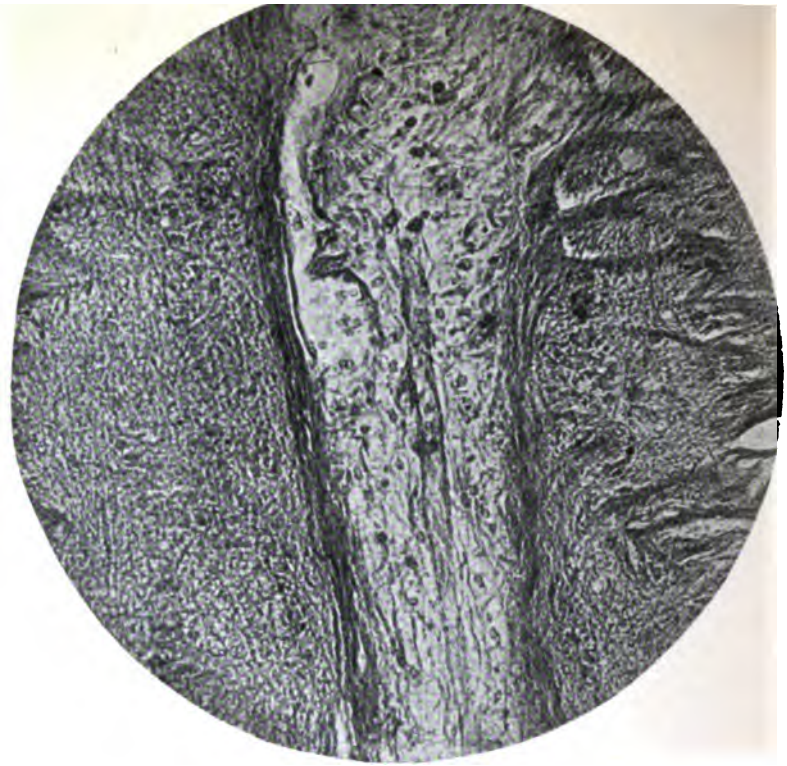

FIG. 1. Optic nerve in the region of lamina of a dog 61 days blind from quinine; stretched and edematous tissues surrounding a central endothelial tube and lying between it and a condensed fibrous tissue separating the surrounding nerve fibers.

narrowed and the atrophy of the iris continued. During the next four years there were no noteworthy changes except an an elaboration of this iris atrophy, which continued during the next three years. The author attributes this atrophy to a toxic disease of the vessels brought about by the action of the quinine, and believes that those writers who have found changes in the vessels of the eye in the late stages of this disease have made observations which are accurate and which lead this author to make the explanation of his case that has just been given.

Microscopic Vascular Changes in Quinine Amaurosis.—Brunner believed that the permanent changes of the vessels which were found in long-standing quinine blindness were probably dependent upon the degenerative alterations in their coats, but apparently did not endeavor to prove his theory by microscopic investigations.

In my first experiments in quinine blindness, with the exception of what appeared to be a blood-clot in the central vein, no absolutely positive microscopic lesion of the vessels was discovered, that is, to quote this paper, "none that might not be attributed to imperfections in technique." In my second paper, in which no investigations were made of the ganglion cells according to modern methods, but in which in a dog blind for 61 days an elaborate atrophy of the optic nerve was demonstrated, it was believed and stated that the central vessel, probably the vein, was occluded by a tissue which was composed of fine reticular fibrous connective tissue, small spindle cells with long processes, small round cells and a small quantity of pigment, in the center of which was a tube of endothelium containing blood corpuscles and to the upper side of which there was a space lined with endothelium and also containing blood corpuscles. This appearance was inaccurately attributed to changes which had taken place in a thrombus, or at least, this was suggested as a possible explanation of the appearances shown in the accompanying photograph taken at that time. A similar section from another specimen taken from a dog not so long blind furnished identical appearances. (Fig. 1. Plate I.)

Ward Holden[14], referring to this side of the question, writes: "Although the arteries were constricted, no histological changes were noticed in the vessels of the optic nerves or retina, there being neither thickening of the walls nor proliferation of the endothelium. The very thin walled central vein of the optic nerve was sometimes found emptied and collapsed, and the delicate connective tissue about it, with its small vessels, being then stretched and apparently increased in amount, suggested the appearance of an organized thrombus in the vein, but this same appearance was noticed also in healthy dogs when the vein was empty." This statement led me to re-examine more carefully my specimens, with the aid of better instruments of precision, and to realize the error of interpretation which had been made, and which I corrected in a later publication[15], where I say: "The vascular changes which the writer investigated would seem to be secondary results and not due to any direct action of the drug, and it is probable that the condition in the central vessel which I found and ascribed to a thrombus, in the light of Holden's observation, must be regarded as a natural phenomenon in the central vein of the dog's optic nerve, and not due to the action of the drug." Unfortunately, wherever such investigations as I have made on quinine blindness have been quoted, the original error of interpretation has found place and not its correction. Therefore, I have within the last few months carefully re-examined my old specimens, some new ones which have never been reported, and some sections of normal dogs' eyes, and the results of these examinations will follow.

(*a*) *Uveal Tract.*— In the dogs' eyes which I described in 1890 and again in 1891, the irides were not preserved or mounted, and therefore bloodvessels cannot be investigated. This is unfortunate in view of Stölting's observations already referred to, because the blindness in one of these dogs was maintained for 61 days, representing a period of amaurosis of greater duration than that of any other dog recorded by other experimenters.

---

14 Loc. cit., p. 40.

15 The Toxic Amblyopias, in A System of Diseases of the Eye, edited by Norris and Oliver, iv, 1900, page 856.

In a third series of quinine-blind dogs examined in Dr. Hare's laboratory in the Jefferson Medical College in 1892, and which have not been published simply because they confirmed my own previous observations on the production of optic nerve atrophy, as well as those of other investigators on the development of ganglion cell degeneration, the iris was preserved and sections examined microscopically. In some particularly good sections the structure of the iris is apparently in all particulars entirely normal and the bloodvessels fully natural in their microscopic structure, and no trace of the atrophy of the iris which Stölting believed might follow as the result of a toxic bloodvessel disease in long standing quinine blindness was discovered; such a lesion, however, could not be expected, as no one of these dogs was preserved alive for more than a month after the original blindness, while in Stölting's patient this iris-lesion did not develop until two years after the beginning of the disease.

In the choroids of the dog blind for 61 days as the result of repeated doses of quinine, and in which there was elaborate atrophy of the optic nerve, the sections having been cut and mounted and stained with carmine, in 1890, there is no evidence of vascular disease in any of the vessels in so far as the endothelium or perivascular tissues are concerned. Apparently they do not differ in appearance from the vessels of a normal dog's eye used as a control, mounted and stained in precisely the same manner at the same time, except in thickness of the wall, or perhaps, more accurately, in a condensed appearance of the tissue. It is, however, difficult to distinguish the elements, and although the dogs were of equal weight, this slight variation from the normal, or apparent variation, may readily be accounted for by difference in the natural constitution of the vessels in so far as thickness of the walls is concerned. In a word, then, in *none of these sections is there any indication of disease of the vessels of the uveal tract.*

(*b*) *Retina.*—The vessels of the retina of the "quinine-dogs," and particularly of the one blind for 61 days before his death, fail to show any positive lesion, either in their lining en-

dothelium, or in their walls, except that the latter are slightly thicker and more condensed than those in the retina of a normal dog of the same weight, and examined at the same time by the same methods (Müller's fluid and carmine stain). The perivascular spacing of the "quinine dogs'" retinas is greater than that in the normal dogs, but the differences are too insignificant to indicate a positive pathological change. It is not a little remarkable that lesions are either entirely absent or not definitely shown by the methods then employed in view of the long standing ophthalmoscopic changes which were present. It is possible that the wider perivascular spacing indicates their contraction and that their walls are more condensed than normal, but nothing more can be said, and even this is not a marked feature or one that can be considered of definite pathological significance.

(*c*) *Optic Nerve.*— In the axis of the optic nerve of the dog blind for 61 days beginning at the nervehead and extending through the region of the lamina posteriorly to a position 2.5mm. behind it, the tissues, which may be traced through serial sections, and which have been shown in fig. 1, plate I, present the following details: At the nerve entrance there is a broken plug of granular material containing a few pigment grains scattered through it. Posteriorly to this and beginning in the lamina is a loose-meshed tissue containing a number of round and irregular granular cells. Bounding this tissue on each side and separating it from the surrounding nerve elements is a band of slightly wavy fibrous connective tissue, varying in width from 18 to 20 microns. Through the center of the previously named loosely constructed tissue containing round cells runs a tube the lining endothelial cells of which are in good condition, while in its lumen are a number of blood corpuscles. This tube is narrow above, 10-15 microns, and gradually widens out into a vessel of considerable size, 33 microns in width, and is finally lost in the posterior portion of the section in a mass of loose connective tissue. Close to the tube in certain places there are long spindle cells which suggest muscular elements. At the upper and outer part of this

PLATE II

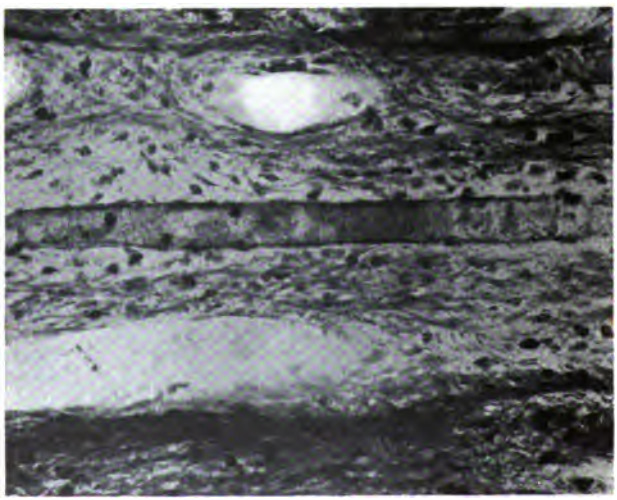

FIGS. 3 and 4. Appearances similar to those of Fig. 1 from a quinine dog blind 61 days.

cord and extending a little beyond the point at which the endothelium tube previously described first appears, there is a large, somewhat crescentic space lined with endothelium and containing a few bloodvessels and giving the impression of a collapsed venous channel. In a second specimen (Dog D) closely similar conditions are present; in the upper part a long venous channel is present, and in the lower part two cross sections of vessels (veins?) with well preserved endothelium and containing bloodvessels. The elements present are, therefore, a central endothelial tube surrounded by a loose fibrous connective tissue, entangled in which are numerous round cells and pigment granules, and here and there, but not very distinctly, some spindle cells suggesting, as previously remarked, muscle fibers, which in its turn is separated from the outlying nervous tissue by a thick wall of fibrous connective tissue composed of closely packed fibers. (Figs. 3 and 4. Plate II.) It was originally supposed that the outer fibrous coat represented the adventitia of the central vessel, and that the loose tissue containing the round and granular corpuscles, in the center of which ran the endothelial tube, might be due to an organizing thrombus, an explanation which was abandoned and corrected after the observations of Ward Holden had been published.

The question at the present is: Does it represent a pathological process, or is it, as Ward Holden maintains, merely a normal phenomenon in the dog's eye, representing the loose connective tissue which surrounds the central vein?

In many sections of normal dogs' eyes no exactly similar appearance was found, and it was on this account that its pathological nature was originally assumed. In one section of a normal dog's eye cut at the same time and since studied, just below the lamina there is a large, irregular venous channel with normal endothelium containing blood corpuscles. Surrounding it on both sides and lying between it as it twists upon itself, is a tissue similar to that which surrounds the central endothelial tube in the "quinine dog," and is composed of loose fibers through which are scattered round and somewhat oval granular corpuscles but no

pigment grains. The spacing between these fibers is, however, much less marked than that which is evident in the quinine specimen (Fig. 2. Plate I.) Two explanations suggest themselves: (*a*) The outer condensed fibrous walls represent the tissue of the pial sheath as it accompanies the central vessel, and the tissue between this sheath and the central endothelial tube is the stretched, loose connective tissue containing corpuscles and small bloodvessels, which normally surrounds the central vein. (Holden.)

(*b*) Professor A. J. Smith of the University of Pennsylvania suggests, as this disposition of the tissues seems to exceed any reasonable normal state of affairs and is accompanied by pigment, indicating a long standing passive congestion, that it may represent a form of œdema either of the coat of the vessel itself, that is, a subendothelial pathological process, or of the loose connective tissue which we know ensheaths the central vessels. In other words, he is of the opinion that the process is too extensive a one to be classified as normal, even though normally much loose connective tissue surrounds the central vessels.

Whichever of these explanations is correct, evidently the outer condensed fibrous coat does not represent the coat of a vessel within which any metamorphosis of clot-formation is taking place.

In none of the cross sections of the optic nerves stained with carmine of the dog blinded for 61 days by means of quinine has the section passed through an exactly similar area. In one section of a dog blind from quinine, in which, however, the duration of the amaurosis was not so long, somewhat less than a month, there is a section across the central vessels. There appears to be no material change in the coats either of the vein or artery. They are, however, surrounded by a loose meshed tissue containing a few corpuscles, in its turn surrounded by a wide, empty perivascular space strongly suggestive of precisely the same phenomenon that is viewed in the longitudinal section, although much less marked. (Fig. 5. Plate III.) No exactly similar appearance was found in the transverse section of any of the normal

PLATE III

FIG. 5. Cross section of the optic nerve of a quinine-blind dog showing the central vessels surrounded by a loose connective tissue, in its turn surrounded by a wide perivascular space.

49, 44, and 44. In all three instances the hemorrhages were sections pass through exactly the same place.

Examination of the cross section of the blood-vessels in the optic nerve septa of the 61-day blind dog (Weigert's stain) shows the central vessels, again, with apparently thicker coats than normal, but with no change in the endothelium, and with wide perivascular spaces which doubtless are due in part to shrinking. Many of the smaller vessels in these sections and in others stained with carmine are collapsed, but endovasculitis and vessel-wall change are not positively to be demonstrated.

Ophthalmoscopic Vascular Changes in Alcohol-Tobacco Amblyopia.— It is unnecessary to analyze the very extensive literature in so far as case histories are concerned of intoxication amblyopia to ascertain whether ophthalmoscopic examination in each and every instance revealed any signs of vascular degeneration. That such signs may be present is well known, not only by virtue of the presence of retinal hemorrhages, but by the other now universally recognized symptoms of early arterio- sclerosis, namely, inequality of the veins, unusual distinctness of the light reflex upon the retinal arteries, and particularly indentation of veins by the overlying stiffened arteries. The subject, moreover, has been well summarized by Dr. William Zentmayer[16] in his report of three cases of alcohol-tobacco amblyopia presenting retinal hemorrhages. His patients were aged respectively 49, 44, and 44. In all three instances the hemorrhages were found in the fiber layer of the retina in the vicinity of the disc and usually overlying the vessel. Zentmayer collected 20 cases in which retinal hemorrhages were noted in intoxication amblyopia. He summarizes them somewhat as follows: Seven occurred in Uhthoff's collection, all alcoholics, six of whom were subject to epileptic convulsions; four in Nettleship's records, one a drunkard, one an abuser of tobacco and alcohol but who recovered without abstaining from alcohol, and one in a man who had been a teetotaler for ten years; Morton's patient used tobacco to

16 Annals of Ophthalmology, vol. x, 1901, p. 436.

excess, and Belt's patient had multiple neuritis and was recovering from delirium tremens. In several instances reported by Ammann small retinal hemorrhages were found in the neighborhood of the papilla. Such a complication is also referred to by Haab. Zentmayer proceeds as follows: "Analysis shows that of the above 17 cases in which I find notes as to the toxic agent used in excess, in 13 instances it was alcohol, and if we include the other 6 cases of Uhthoff, we have 19 out of 23."

In a case recently examined in the University Hospital, a man past 60 years of age, in addition to the usual pallor of the disc, there were retinal hemorrhages and the typical signs of angiosclerosis of the retinal vessels, quite in accord with the evidences of general arterio-sclerosis. As most patients with intoxication amblyopia have reached an age when vascular degeneration is likely to begin, particularly in persons of their habits, these ophthalmoscopic findings are naturally to be expected.

Microscopic Vascular Changes in Tobacco-Alcohol Amblyopia.— The various theories which have been enunciated in regard to the underlying pathological lesions of this form of toxic amblyopia have recently been analyzed by Dalen[17], and one of his classifications (the third in his list) states that certain authors believe that it depends upon a primary vascular change with consecutive loss of nutrition and degeneration of the nerve fibers. Referring particularly to the vascular basis, if I may so express myself, of toxic amblyopia, is the paper of Franz Schieck[18], and to introduce the report of his own case of toxic amblyopia pathologically investigated, with special reference to the vascular changes, he summarizes previous observations along this particular line of research in so far as it is concerned with vascular changes, as follows:

Samelsohn[19] described great vascular development in the interstitial connective tissue of the atrophic area. Each connective

17 Mitteilungen aus der Augenklinik des Carolinischen Medico-Chirurgischen Instituts zu Stockholm, 1906.

18 Arch. f. Ophth., liv, 1902, p. 458.

19 Arch. f. Ophth., xxviii, Abth. 1, 1882.

tissue septum supported a dilated vessel fully filled with red blood cells. He also records Erismann's observation of fibrous thickening of the vessel walls.

Vossius[20] noted thickening of all of the larger vessels, as well as of the coats of the smaller vessels situated in the septal intersections.

In Uhthoff's[21] rich material, at least two cases are named, namely, 1 and 2, in which a new formation of vessels was evident, which were filled with blood and which had very thick walls.

Sachs[22] observed vascular changes in the diseased tissues, and believed that the *vena centralis postica* was the site of the morbid alteration. These vascular changes consisted not only of a proliferating endophlebitis leading to connective tissue changes of the vascular lumen, but to a periphlebitis resulting first in a choking of the peripheral capillaries and afterwards in small extravasations from them. Although not willing to admit that these alterations constituted the usual explanation of affections of the papillo-macular bundle, he urges that in the investigations of future cases, especial attention should be paid to the condition of the posterior central veins.

Sourdille[23] found in the diseased areas of the optic nerve no special alteration in the connective tissue septa, but great changes in the capillaries. The endothelial tubes are remarkably thickened, hyalin and their nuclei increased in size and number, so that the lumen of the tube is narrowed. He concludes that this obliterating capillaritis is a very important and characteristic phenomenon.

Although Birch-Hirschfeld[24] noted in the septa numerous blood-vessels filled with blood, he did not find any changes in the vessel walls or the endothelial linings.

Siegrist[25] found in his specimens optic nerve atrophy, prolif-

---

20 Arch. f. Ophth., 1882, xxviii, Abth. 3, p. 201.
21 Arch. f. Ophth., 1886, Abth. 4, xxxiii, and Ibid, xxxiii, Abth. 1.
22 Archives of Ophthalmology, xxiii, 1894.
23 Die Ophthal. Klinik, No. 23, 1900.
24 Arch. f. Ophth., Bd. liii, Abth. 1, 1902, p. 79.
25 Archiv. f. Augenheilkunde, xli, 1900, p. 126.

eration of the interstitial connective tissue, and enclosed within the connective tissue bundles many new-formed blood-vessels with thickened, sclerosed walls.

Schieck[26] found in the affected temporal portions of the cross sections of the optic nerve marked proliferation of the interstitial connective tissue involving a rich network of new-formed vessels with thickened walls. Cross sections of isolated vessels were also noted amongst the nerve fibers, indicating vascular sprouting in the nerve bundles. Many vessels were sclerotic, often their lumen being unrecognizable, the concentric arrangement of the connective tissue and the well-marked grouping of curved flat cells in such obliterated vessels alone revealing their true origin. There were many transitional forms of vascular degeneration. Where the endothelial proliferation was especially active the vessel contents appeared as clod-like masses which frequently completely occluded the lumen. In both nerves in the sections behind the bony canal, but in front of the chiasm, there was pronounced endarteritis obliterans, in a certain portion not one vessel being visible with normal walls. Even vessels of the largest caliber were extensively obliterated. From the diseased vessels many new formed vessels branched.

In my own case of toxic amblyopia with autopsy and microscopical examination of the specimens[27], very decided vascular changes were evident in the optic nerve vessels, as well as those in the choroid and retina. These have been more elaborately restudied for the purposes of the present paper, and may be described as follows:

In the left eye in a series of sections (1-9) made in the longitudinal direction, the central artery of the retina, either where it penetrates somewhat obliquely posteriorly or lies in the axis of the nerve, usually contains a moderate quantity of blood corpuscles and has a distinctly thickened and compact wall and presents manifest hyalin alteration; so much so that it is not always possible to differentiate the muscular and adventitious elements.

---

26 Loc. cit., p. 458.

27 Transactions of the American Ophthalmological Society, viii, 1897, p. 186.

In no place, however, has there been any distinct disease of the intima. It is rather a fibrosis of the wall itself with hyalin alteration. In one section (L2), where the artery and vein are to be studied in the nerve head in transverse section, in addition to the alterations of the walls, there is a collection of young connective tissue cells, the only section in which such a manifestation was discovered.

In the *retinas* of this series of sections, in general terms, the veins studied in transverse section have compact walls, with hyalin change but without any alterations in the endothelium. The same thickening and condensation with the hyalin change is noticeable in the arteries of the same sections.

Sections of the right eye (6-10) also show thickening and compactness of the walls of the central retinal vessel, with less manifest hyalin change, the condition being rather a perivascular fibrosis, but in the choroid and retina of this series of sections the same changes which have been described in connection with those of the left eye are noticeable.

In transverse sections of the diseased optic nerves the vessel changes are noteworthy and consist of marked thickening of the walls of the septal vessels, with decided hyalin degeneration. No positive change in the endothelium of the larger vessels is evident, but in many of the smaller ones the lumen is practically obliterated, so that the cross section resembles that of a hyalin cord. In one place, where a small vessel can be followed for some distance along a septum, this thickening and hyalin change in the wall, giving it a homogeneous appearance, is especially evident. Within its constricted caliber blood corpuscles are closely packed. These changes are discoverable not only in the small vessels within and at the edges of the diseased area of the nerve, but also in the unaffected portions and in those which lie within its sheath.

From an examination of the sections in which the proliferation of the interstitial connective tissue enveloping a rich formation of new formed vessels with thickened walls was the most noteworthy feature, Schieck argues that so-called toxic amblyopia is really due to an endarteritis obliterans. He brings it into

line with multiple alcoholic neuritis, in which the degenerative process is attributed to vessel disease by some authors. His observations agree in large measure with those of Sachs and Sourdille, who also call especial attention to the vascular changes. The papillo-macular bundle, he points out, on account of its central position is more susceptible to nerve impoverishment on account of vascular sclerosis, than the peripherally situated fibers which are able to resist the results of vascular degeneration on account of their proximity to the lymph currents. He continues his argument thus: The centrally placed fibers, when such vascular sclerosis arises, depend for their continued vitality on a speedy establishment of a collateral circulation. The vascular development accordingly must be regarded merely as a collateral circulation,— the new-formed connective tissue acting solely as its supporting structure. Competent collateral circulation, associated with discontinued action of the toxin, brings about nerve restitution, while continued action of the toxin eventually leads to degenerative changes even in the collateral vessels. He insists that the genesis of this process can only be studied in fresh cases.

Schieck's conclusions have naturally met with opposition. Thus, Birch-Hirschfeld[28] considers them untenable for the following reasons: (1) The central region of the optic nerve is not always the part that suffers the greatest change. For example, in some cases the peripheral portions of the optic are alone affected. (2) The character of the vascular alteration in the vessels of the optic nerve has differed in all the cases examined with the microscope; sometimes the vessels show little alteration. (3) Experiments with methyl alcohol clearly prove that changes in the ganglion cells of the retina may precede a degeneration of the nerve fibers. Despite this fact, the changes in the optic nerve are of such a kind as to support the view that degeneration is a simple consequence of the lesions of the ganglion cells. In this respect there is an analogy between acute poisoning by methyl alcohol and chronic poisoning of ethyl alcohol.

---

[28] The Ophthalmoscope, March, 1904.

Schieck[29] has recently tried to establish his position by an appeal to the clinical rather than to the pathological method of reasoning. His cases are analyzed by Birch-Hirschfeld who doubts that they prove his point. While Birch-Hirschfeld does not deny that in the diseases discussed, namely, retrobulbar optic neuritis from syphilis, from myocarditis, and associated with partial thrombosis of the central veins, and diabetic amblyopia, changes occur in the vessels of the optic nerve and that they possess a certain significance in the production of the disease, he considers it unwarranted to look upon them as the sole cause of the localization of the disease in the papillo-macular bundle. A direct toxic influence can be excluded from none of these. From the close relationship between nerve fibers and the ganglion cells in nutritive and functional respects, from the different structure of the central and the peripheral retina, and from the appearance of the papillo-macular fibers, he thinks it can be readily understood that an isolated disorder of the papillo-macular bundle can exist. It is probable that the relations of the blood-vessel distribution must be regarded, but it is not correct to say that the changes in the vessels alone cause the localization of the disease.

In order further to appreciate the significance of such vascular changes, it is necessary to summarize a few of the clinical data of the cases quoted: Samelsohn's patient was a 63-year-old man, who suffered from double retrobulbar neuritis which began with the clinical picture of an intoxication amblyopia, the central scotomas being at first relative and later absolute. Death resulted from chronic heart disease. The abuse of alcohol and tobacco was not substantiated. Vossius's patient was a 48-year-old man, who three years before his death had a central scotoma and suffered from alcohol amblyopia. He died hemiplegic and aphasic. Uhthoff's first patient was an alcoholic, aged 34, who died from the effects of alcoholism. His second patient was a 61-year-old man who died in an attack of delirium tremens from intercurrent pneumonia. Sachs's patient was a 19-year-old man who

[29] Archiv. f. Ophthal., lvi, 1903, p. 116.

denied the use of tobacco and alcohol, whose optic nerve showed marked capillary hyperemia, with faint radiating streaks of cloudiness in the neighboring retina, and who died of pulmonary tuberculosis. Cerebral tubercles were not present. In spite of this history, his case is classified as one of toxic amblyopia. Sourdille's patient was a 40-year-old woman with a history of alcoholic abuse, and who died of tuberculosis. Birch-Hirschfeld's patient was a 51-year-old man who died of carcinoma of the esophagus. Siegrist's patient was a 55-year-old man who died of carcinoma of the stomach and who had extensive arteriosclerosis of the larger vessels. The man had the history of alcoholic abuse. Schieck's patient was a 35-year-old man who abused alcohol and tobacco, and who killed himself by jumping from a window during an attack of delirium tremens. My patient was a 60-year-old man who at one time had used alcohol, but not for thirteen years prior to his death. He was an excessive smoker, had albumen in his urine, as well as granular and hyalin casts. He died of pneumonia associated with uremia. Dalen's patient was a 47-year-old man who committed suicide, and whose organs were normal. Vessel changes in the optic nerve and retina were not demonstrable. It is evident, therefore, that with the exception of the two suicides and the two chronic alcoholics, in all instances conditions other than the abuse of alcohol and tobacco were potent factors. This is particularly true of Sachs' patient, only 19 years old, with extensive pulmonary tuberculosis and with no positive evidence of abuse of either alcohol or tobacco. Surely the endo- and periphlebitis are not safely to be ascribed alone to these agents in the cases quoted although, as I have written in the report of my case of tobacco amblyopia which came to autopsy, Sachs's belief that the earlier stages of these intoxication amblyopias may reside in vascular disturbances has a good deal to recommend it, and seems to be borne out by the action of certain other toxic agents, notably lead. I did not, however, say that I believed this was proved, or express the positive opinion which Dalen ascribes to me that the disease should be attributed to a primary vessel alteration which occasions a nutritional disturbance followed by degeneration of the nerve fibers.

Methyl-Alcohol Poisoning; Examination of the Eyes.— The eyes, a description of which follow, were removed from a man, aged 30, who died as the result of drinking Colonial spirits (methyl-alcohol) mixed with lemon and water. This spree was participated in by two companions, who also died. The drinking took place during Sunday afternoon and Sunday night, Oct. 3, 1903. How much was consumed is not known. The patient was found unconscious on Monday morning, about 3 o'clock, and was removed to a neighboring hospital, where the following notes were made: "Patient unconscious, pupils dilated, respirations almost inaudible and pulse scarcely perceptible." Death occurred 1 1/4 hours later. Autopsy was made eleven hours after death by Dr. Wadsworth, the Coroner's Physician, who kindly removed for me the eyes and optic nerves. He found marked congestion of the brain, congestion of both lungs with traces of edema, slight atheroma of the valves of the heart, recent hepatitis, diffuse and apparently recent gastro-enteritis, and also fresh kidney congestion. Otherwise there were no lesions.

The eyes were placed in formalin (1 per cent.), longitudinal sections being cut of the posterior halves (the anterior halves were not obtained), and stained with hematoxylin eosin, while fragments of the retina were stained according to Nissl's methods. These mounts and stains were made in my laboratory by Dr. Edward A. Shumway.

The Nissl-stained sections of the retina were carefully examined by Dr. Shumway and myself and showed very decided degeneration of the ganglion cells, that is to say, absence of the chromophilic granules and beginning breaking down of the cell body. Inasmuch, however, as Birch-Hirschfeld[30] in his investigations of the post-mortem changes which take place in the ganglion cells of the retina, has shown that they begin as early as two hours after death, and that by the seventh hour there is complete failure of the appearance of the Nissl bodies, and the blue staining of the ground substance of the cell is lost, and that after 11, 12 1/2 and 18 hours, with complete loss of the chromatic bodies in the gang-

[30] Archiv. f. Ophth., l, 1900, p. 179.

lion cells, they show only rarely a shrunken deeply blue-stained nucleus, with scanty remains of the original structure, such changes as we found could as well be attributed to the post-mortem alterations of the cells as to the action of the methyl-alcohol which the patient consumed. At the present time (3 1/2 years after these preparations were made) the staining has faded and their value for investigation is different. There appears to be in many places an almost complete disappearance of the ganglion cell layer, while those that remain are granular, vacuolated and show a displaced nucleus. One such cell is shown in the accompanying photograph. (Fig. 7. Plate IV.)

At the same time longitudinal sections of the posterior halves of the eyeball and the attached optic nerves were made and stained with eosin hematoxylin. In so far as the optic nerve is concerned, although no stains, for example, the Marchi, were employed, there is no evidence of degeneration of the fibers and no likelihood that such degeneration would be present at so early a stage of the poisoning. In so far as the central vessel is concerned, which is well shown in several of the sections and which contains a certain amount of blood, somewhat disintegrated, there are no discoverable changes in the endothelial lining of either vein or artery, nor are the walls of the artery, in so far as their muscular or adventitious coats are cencerned, in any way diseased. The only pathological appearance seems to be a space lying between the outer wall and the adjacent nerve tissue, filled with a fine reticular tissue, spaced and fenestrated, and representing evidently a process of edema, is well shown in the accompanying photographs (Fig. 6. Plate IV). It occupies a position between the adventitia and its connective tissue sheath and the surrounding nerve fibers. Whether it should be attributed to any action of the alcohol, or whether it is an artefact and represents a separation of the central artery from the surrounding tissue, exactly as one sees a separation of the nerve bundles from the surrounding septa caused by so-called imbedding edema, is a matter for speculation. In order to study this matter, a number of other sections were taken of nerves removed in a similar manner, that is to say, by

PLATE IV

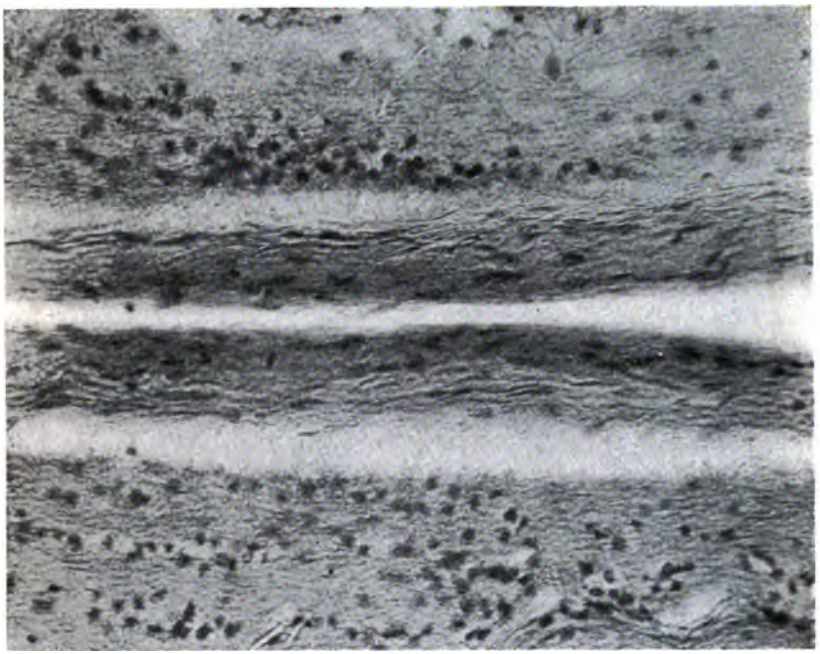

FIG. 6. Central artery in longitudinal section of an optic nerve of a man dead from drinking methyl alcohol, showing a layer of edema between the external coats of the vessel and the surrounding nerve fibers.

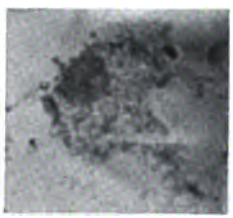

FIG. 7. Retinal ganglion cell in methyl alcohol poisoning.

PLATE V

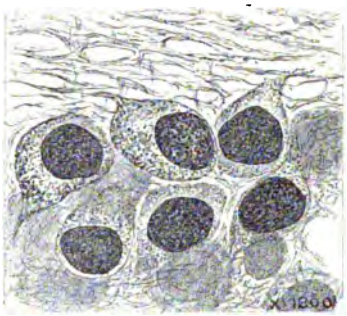

FIG. 8. Normal retinal ganglion cells.

FIG. 9. Retinal ganglion cells in methyl alcohol poisoning.

crushing in the orbital plate and excising the posteror half of the eye, but no exactly similar appearance was detected.

In some places, however, in the methyl-alcohol nerve there is between the septa and the adjacent nerve fibers a similar appearance, that is to say, a space filled with a fine reticular tissue representing a process of edema, resembling the artefacts figured by Coats[31]. Hence this space surrounding the central vessels should probably have a similar interpretation.

Close examination of the retina, in so far as its general structure and vascular supply are concerned, fails to show the presence of any pathological lesion. It is interesting to observe in studying the ganglion cell layer and comparing it with sections of known normal retina similarly stained, that there is no noticeable lesion, as may be seen from the accompanying drawing made from approximately the same position in the retina and under the same amplification, practically the only difference being a slight increase in the density of the nuclei of the ganglion cells in the methyl-alcohol specimens, as compared with those in the normal retina, and a possible swelling, if one may so express one's self, of the cell body, giving the impression that it is slightly edematous and has somewhat bag or bladder-like appearance, rather than that of the natural contour of the cell. (Figs. 8 and 9. Plate V.) This would accord equally with post-mortem changes, or with the influence of the alcohol, and accords, moreover, with several examinations which have been made of cases of human toxic amblyopia, although not before under the influence of methyl-alcohol. Thus, Dalen found distinct changes by the Nissl method, probably post-mortem, in his case, although the ganglion cell layer appeared perfectly normal when submitted to the ordinary stains. In so far as the choroid is concerned, no lesions were found.

In résumé, the following conclusions seem warranted:

1. The ophthalmoscopic evidence of retinal vascular disease in the sense of obliteration of the arteries and apparent conver-

[31] The Pathology of the Eye, by J. Herbert Parsons, vol. ii, p. 657.

sion of their walls into white cords in long-standing quinine blindness, either in human beings or in animals, has been confirmed by a number of observations, beginning with those of Horner and ending with those of Seeligsohn. At least one case is on record, namely, Parker's, in which thrombi were believed to have been seen in the inferior retinal vein as early as four days after the blindness.

2. One case (Seeligsohn's) is on record in which ophthalmoscopic evidence of disease of the choroidal vessels at a late stage of the poisoning, that is, three years after its commencement, was present, but there is no confirmation of such choroidal vessel disease in experimental quinine blindness, in which, however, no specimen has been examined longer than several months after the quinine blindness was induced, nor is there any experimental evidence to confirm the single clinical observation of atrophy of the iris as the result of a toxic disease of the vessels under the influence of this drug as made by Stölting.

3. In long-standing quinine blindness in animals, although the vessels of the optic nerve, of the choroid and of the retina appeared slightly thickened, careful examination fails to confirm the presence of any true endo-vasculitis. There appears, however, in these cases to be an edema with stretching either of the fibers of the walls of the central vein of the retina, or else of the loose connective tissue which encases it. No thrombus formation, however, takes place, and the original statement made by de Schweinitz that he believed in two specimens that such a condition had occurred, is incorrect and was due to faulty interpretation of the phenomena observed.

4. In a number of instances of tobacco-alcohol amblyopia which have come to autopsy, extensive vascular disease of the optic nerve in the form of thickening of the vessels, fibrosis of their walls and hyalin degeneration, as well as endo- and periphlebitis, have been described, notably by Sachs, Schieck, Sourdille, and de Schweinitz, but there is also no satisfactory evidence that these alterations constitute the underlying basis of the disease.

5. In the case of human methyl-alcohol poisoning, while the

Nissl stain showed beginning degeneration of the ganglion cells, such changes could not be positively referred to the action of the drug, inasmuch as the examination was made eleven hours after death, and therefor at a time when the post-mortem changes in the ganglion cells might have begun. No other changes in these eyes were discovered, except a layer of edema surrounding the central artery and central vein of the optic nerve, which also could not be positively attributed to the action of the methyl-alcohol, because it resembles a similar edema which has been noted between the septa and the nerve fibers as the result of an artefact.

DISCUSSION.

DR. HOLDEN: I had long hoped that when we had an autopsy on one of these cases of acute methyl-alcohol poisoning we might be able to clear up some of the points in its pathology. I have had the opportunity of glancing over sections of the optic nerve, and retinas in one such case and I was extremely disappointed. The optic nerve showed no gross changes and particularly was there no vascular change and no edema about the vessels such as Dr. de Schweinitz describes in his case. In this case also the autopsy was made so long after death that the ganglion cells of the retina showed advanced post-mortem changes that made it impossible to say what changes had existed in life.

AFFECTIONS OF THE OPTIC NERVE DURING PREGNANCY.

BY DR. ARNOLD KNAPP,

NEW YORK.

According to Groenouw[1], the optic nerve is not infrequently involved in pregnancy in the form of optic neuritis or of retrobulbar neuritis. Uhthoff found 4 of 66 cases of chronic retrobulbar neuritis to occur in women in advanced pregnancy. Other cases have been published by Kipp, Valude, Power, Lawford, Knaggs and Ole Bull.

1 Graefe-Saemisch, second edition, vol. xi, p. 185.

Groenouw says that the transient loss of vision in these cases cannot be regarded as uremic or hysterical amaurosis but rather due to a neuritis secondary to auto-intoxication agreeing with similar ocular disturbances in labor and lactation. (Uhthoff[2].)

I have observed ten cases where the optic nerve and retina during pregnancy and labor showed changes which differ from retinitis albuminurica gravidarum. On studying the general symptoms which accompanied these eye lesions it seems to me that they correspond to two groups, one which is now recognized as toxemia of pregnancy and the other as sepsis. As the former predisposes to the latter the symptoms are often combined.

I shall briefly report the histories of 3 cases of neuritic atrophy with no other change in eye grounds occurring in pregnant women with other manifestations of toxæmia. The other cases which I shall omit were complicated with sepsis, the eye grounds presenting the additional changes of septic retinitis.

CASE 1. Mrs. R. F., age 32. Seen July 13, 1906, at the Lebanon Hospital by courtesy of Dr. Martin Cohen.

Patient gives a history that she has had five children in a period from eleven to five years ago. She then had four abortions. She is now in the eighth month of pregnancy. Seven weeks ago suffered from severe headache and vomiting. Five weeks ago the right eye became blurred which was shortly followed by an involvement of the left, and in one week both eyes were blind. She has had no convulsions. The headache and vomiting have ceased. Urine examination shows specific gravity 10/20; faint trace of albumen; proportion of urea nitrogen greatly reduced.

On examination: Both pupils widely dilated and immobile; no perception of light in any part of the field. Both optic discs are white; outlines indistinct. Arteries narrow. There is some œdema of the retina in the macular region. On July 20th, labor was induced, and a dead child delivered. Mother died of septicæmia.

CASE 2. Lying-In Hospital. Oct. 4, 1904. In preceding pregnancy there was loss of sight becoming worse after labor

2 Uhthoff, Thirteenth International Medical Congress, Paris, 1900.

for three weeks, then improved, but complained of asthenopia. At present in eighth month of pregnancy complains of blurred vision. Albuminuria. The optic nerves are white and ill-defined. Field normal.

CASE 3. Seen at the Lying-In Hospital, August 12, 1904. Primipara. Three months ago her vision was blurred for two weeks. She then had headache. Now near term the legs are swollen; the urine contains some albumen; optic nerves distinctly white. Right: blurred, nasal half swollen. Left: flat; vision and field normal.

According to Stone[3] the evidences of toxæmia of pregnancy are as follows: In the early months nausea and vomiting; skin manifestations (urticaria). These conditions are all observed in normal menstruation. During the later months there is headache, loss of sight, vomiting, vertigo, neuralgic pains, œdema. The urine may contain albumen and casts. This may be followed by convulsions and coma. Rarely patients will become totally blind, comatose and die.

It is now generally accepted that hyperemesis gravidarum and eclampsia are expressions of a toxic state in which the liver is the seat of the chief lesion, often presenting the same changes as acute yellow atrophy. During the period of lactation there may be a continuation of this state of the system, and these symptoms may consequently persist. One of the most frequent is the insanity.

Chemical examination of the urine by Ewing and Wolff (American Journal of Obstetrics, April, 1907), has shown that there is a disturbance in the nitrogen ratio. The total amount of nitrogen is decreased. The nitrogen which is converted into urea is decreased, while the other nitrogen derivatives are increased.

In the fatal cases post-mortem examination has shown parenchymatous multiple neuritis (Lindemann) and acute degeneration of the liver.

The ophthalmoscopic condition found in my cases at the time

[3] Toxæmia of Pregnancy, by W. S. Stone, M.D., Amer. Gyn., Dec., 1903.

of examination was neuritic atrophy. Whether a central scotoma was present at the beginning cannot be determined as no case was seen in the early stage. The vision is frequently regained, or it remains defective with peripheric contraction of the field and in the most marked cases the eyes are permanently blind.

There can be no doubt that this ocular condition is found with the symptoms of toxæmia of pregnancy and in the absence of other causes it can be safely assumed that an etiological connection exists. I have been impressed by the frequent appearance of pale optic nerves in women, often with normal vision, who have borne children; may this not be the evidence of some toxic influence during preceding pregnancies?

DISCUSSION.

Dr. Posey said that he had seen one case, which probably could be included among those described by Dr. Knapp under Class I. The case referred to was that of a young married woman three months pregnant, who was sent to him for an ocular examination, on account of persistent headache and some dimness of vision. Examination of the urine and blood had been negative. The ophthalmoscope showed neuroretinitis with lymph extravasations into the retina. The ocular symptoms and headache still persisting after ten days of eliminative treatment, artificial labor was induced. All the symptoms rapidly ameliorated. Dr. Hirst of Philadelphia, who saw the case, regarded it as one of toxæmia probably due to failure of the liver to remove the products of tissue change which so often accompany pregnancy. He stated that toxic changes were rare prior to the sixth month of pregnancy and that, though he has had much experience, he had seen but one other case of ocular changes during pregnancy which were not due to albuminuria. That was one of pregnancy of six months, the patient dying in spite of the induction of artificial labor.

Regarding the presence of urea, Dr. Hirst tells me that the amount of urea and of nitrogenous products generally varies so greatly in women during pregnancy that a quantitative test is not of very much value in these toxic cases.

OPHTHALMOSCOPIC APPEARANCES IN CHRONIC CYANOTIC POLYCYTHEMIA.

BY EDWARD JACKSON, M.D.,
DENVER.

A disease most strikingly affecting the veins and the constitution of the blood should, in every case, be carefully studied with the ophthalmoscope. To place on record a case in which the ophthalmoscopic appearances were observed over a longer period than in previously reported cases, and in which symptoms not previously described were noted; and to call attention to the significance of the retinal symptoms of cyanotic polycythemia, is the purpose of this paper.

Mrs. M., aged 60, a Jewess, born in Germany, mother of six children, consulted me August 21, 1901, on account of indefinite blurring of sight, the letters running together after reading a little while; and for epiphora, the eye frequently filling with water, although tears did not often run over the lids.

For years she "has suffered from heart disease (palpitation and dyspnœa), and "overloaded veins." Her lips are purple (grape color), there are small varices on the cheeks, and passive hyperemia of the conjunctiva. The lids are not displaced and the lachrymal passages are normal. The dioptric media are clear; the retinal veins very large, dark and tortuous, double the size of the arteries, which were normal. No other fundus lesion. Vision R. with —0.50 cy. axis 180°, equal 4/6 partly. L.= 4/20, not improved with any lens. Low myopia. Both eyes present a constant, slight, rather slow rotary nystagmus. Prescribed lenses for near work.

1902, 4, 24. She comes for passive congestion of the conjunctival vessels. The pupils are now unequal, the right being 5mm., the left 4mm., in moderate light. Vision has decreased to R. 4/9;

L. 2/60. There is great dilatation of the central retinal vein where it disappears in the nerve head. Otherwise the ophthalmoscopic picture is unchanged.

1903, 3, 6. Vision still failing, R. 4/15; L. light perception in the central and nasal portions of the field. Pupils: R. 6mm., L. 5mm. They do not react to light thrown into the left eye, but react fully to light thrown into the right eye. There are no signs of any new fundus changes. Field of vision for the right eye is about normal — doubtful concentric contraction.

About this time the patient was studied as to her general condition by Dr. J. N. Hall, who reported her case (Amer. Med., June 29, 1903). He found: "The patient slept and ate well, suffered no pain and was always thirsty." (This was, perhaps, dryness of tongue and mouth rather than true thirst.) "There was no constipation. Her lips were tremulous. Her dyspnœa was very marked upon the exertion of removing her clothing for examination of the chest."

"The most striking feature in her appearance is a cyanosis of such intensity as to be startling, giving her lips and tongue the shade of a ripe Concord grape. It is slightly marked upon the hands, and still less upon the trunk and lower extremities. Over the face are to be seen tortuous veins, which are almost black in appearance and 2mm. to 4mm. in width. Although I noticed no special change in her color at my examinations, her daughter stated that she showed a dusky flush at certain times, especially after excitement, which was very noticeable. The fingers are not clubbed. Her height is but little over 5 feet; her weight, 160 pounds."

"The respirations were 30 while seated, the pulse beats 84 per minute, the temperature normal. Pulse strong, regular and of increased tension as compared with the normal; arteries moderately atheromatous. The heart was, if anything, slightly larger than the average upon percussion, the sounds all sharp and clear, the aortic second sound moderately accentuated. The examination was less satisfactory than usual because of her obesity, but of the

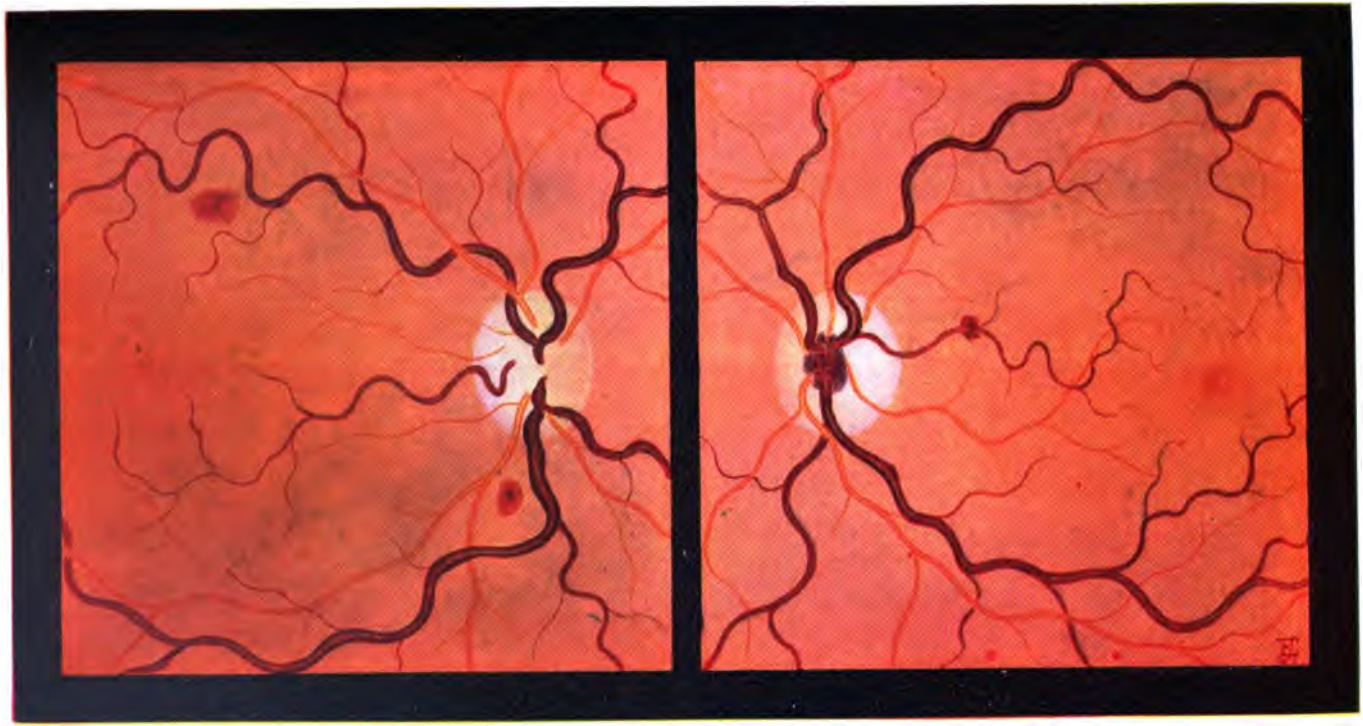

points enumerated there could be no doubt. The lungs were negative, excepting for a few crackles in the bases, probably in the light of the œdema of the legs and the condition of the urine, œdematous in character. There was no evidence of emphysema."

"The thick abdominal walls made the examination of the spleen very difficult. Enlargement was especially sought for, but I could not find it. The organ was certainly not greatly enlarged. The abdominal examination was otherwise negative. No enlarged glands were detected. There was moderate œdema of the feet and legs, and had been for years. None elsewhere except as noted in the lungs. Knee-jerks were normal."

"The urine amounted to nearly 2,000cc. in the 24 hours. Specific gravity 1,012, albumin estimated by Dr. McGraw at .5% by weight. A moderate number of epithelial casts were found in the centrifuged sediment, but curiously scarcely any hyalin or granular ones."

The condition of the blood was as follows: "The drop obtained by puncture was extremely dark in color and coagulated so quickly that it could scarcely be removed from the capillary tube for the blood count. Reds, 9,949,600; normal in character. Whites, 6,500; normal in variety and proportion. The hemoglobin was estimated at 170 on the first examination, January 8 (Von Fleischl); and 200 on March 6. Dr. McGraw found it necessary to dilute the blood twice as much as usual before making the estimation."

1903, 4, 23. Corrected vision in the right eye 4/9. The vision varies somewhat from day to day.

1903, 6, 19. Corrected vision R. 4/6 partly. L. counts fingers at one foot. Faint haze of lens and vitreous in both eyes, but not more than usual in persons of her age. The disks are slightly red and hazy. The accompanying water-color sketch, made at this time, shows the fundus changes in both eyes. It is to be noted that the retinal vessels found are not flame-shaped, but rounded, with faintly shaded borders. No white spots are detected in the retina. The sinus noticed in the left nerve is present, and probably

twice as large as when first noted over a year ago. It is distinctly bluish toward its periphery, and differs in appearance from anything I have seen before. The distention of the retinal veins is not uniform. They look about as when first seen nearly two years ago. The sketch does not exaggerate their size or dark purple color.

1903, 9, 21. Vision R. 4/9 mostly. L: fingers at one foot in the lower nasal quadrant of the field. The patient was not examined after this date. She spent some months at a lower altitude, in California, with very little change in her condition. Subsequently she returned to Denver and continued without marked alteration in vision and in about the same state of health until June, 1904; when she died after a few hours illness, with symptoms of acute cardiac failure. No post-mortem examination. The patient's son thinks that her mother (his grandmother), presented a similar discoloration of the lips and face, and enlarged veins, during the later years of her life. The patient's children are still under middle age. None have shown any symptoms of this condition.

Including the one here reported at least 50 cases of apparently this same disease are now on record. [See Osler, *Am. Jour. Med. Sci.,* August, 1903; Englebach and Brown, *Jour. Am. ed. Assn.,* October 20, 1906; Koster, *Wiener Med. Wochenschr,* 1904, No. 6 and 7; Watson, *Liverpool Med. Chir. Jour.,* July 19, 1906; Uhthoff, *Klin. Monatsbl. f. Augenheilkunde,* Dec., 1906; and a paper by Dr. J. M. Anders, *Am. Jour. of the Med. Sci.,* June, 1907.]

In most of these cases enlargement of the conjunctival veins along with those of the face and other parts of the body has been noted. In every case in which a careful ophthalmoscopic examination is reported, so far as I have access to the literature, the dark color and dilatation of the retinal veins have been observed. In Uhthoff's case, presented at the Heidelberg Congress last year, the dilatation of the veins was noted as quite irregular. The arteries are described as probably somewhat broader than

normal, and a little darker colored, but not strikingly altered. In the case of Engelbach and Brown it is stated that the veins were large and dark blue. In Cabot's second case " retinal examination showed dark and dilated veins, while the arteries looked normal, or a trifle contracted." Koster's case, examined by Bielschowsky, showed the same disturbances in the retinal circulation, to which were ascribed attacks of monocular blurring of vision. In Lohmann's case, reported by Osler, it is stated " conditions of the fundi were negative with exception of tortuosity of the vessels." In Stockton's case, reported by Osler, " Both disks hyperemic, retina surrounding disks thickened; vessels, particularly veins, engorged and tortuous."

In my own case the visible changes in the circulation were confined to the veins. It seems at least uncertain whether any marked alteration has occurred in the arteries in any case yet reported, although loosely worded references might be interpreted as implying arterial changes. The essential pathology of the disease is still in doubt. The natural supposition would be that the primary departure from normal was in the blood-making organs. Great changes in the spleen have been noted in some cases; but were absent in others. The same is true regarding the bone marrow.

As an hypothesis worthy of farther investigation, I would suggest that such conditions might arise from a primary lesion of the general venous system, leading to venous dilatation and stasis, with consequent impairment of the capillary circulation, and with secondary compensatory increase in the number of blood cells and the percentage of hemoglobin. The capillary circulation is profoundly influenced by the venous blood pressure. If the blood making organs respond to demands on the part of the body for an increased supply of oxygen-bearing blood disks, it is altogether probable that response is to demands that come from the domain of the capillary circulation. The disturbance of the arterial circulation is, in this disease, certainly insignificant as compared with the venous.

The probability of retinal hemorrhage would occur to anyone seeing the dilated and tortuous veins that have always been noted; and yet, so far as I know, it has not been reported in other cases. It was only noted at one time in this case, and then it escaped detection until the pupil was dilated with cocain for the purpose of sketching the fundus. Cabot's first case died of a small cerebral hemorrhage. While the apparent venous congestion would be taken to favor hemorrhage, the extreme viscosity of the blood which has been noted in these cases would oppose it. The careful search for retinal hemorrhage is worth making, and it will be interesting to note if the rounded form, instead of the flame-shape, holds generally for such hemorrhages. This rounded form may depend on the layer into which the hemorrhage occurs, or possibly on the tendency of the blood to very rapid coagulation.

With regard to impairments of vision: The general blurrings of sight in my case might be due to circulatory disturbance in the retina. Temporary impairment of vision has been noted in several cases; and Koster's patient was also subject to attacks of ophthalmic migraine, ascribed to similar disturbances of the cerebral circulation. The loss of vision in my patient's left eye seems best explained by pressure within the nerve trunk from the enormously dilated central retinal vein.

Uhthoff suggests that slighter degrees of chronic cyanotic polycythemia may not be very rare; and the ophthalmoscope may help to call attention to such cases. It may at least be said that no case of this disease has been thoroughly studied until a careful ophthalmoscopic examination has been made. And it is not unlikely that careful ophthalmoscopic studies of such cases will throw important light upon the pathology of cyanotic polycythemia.

DISCUSSION.

DR. DE SCHWEINITZ: The whole subject of polycythemia has recently been discussed in the College of Physicians of Philadelphia by Dr. J. M. Anders, who has collected all the cases on record and added to them those which he himself has observed,

and his views in regard to the pathology of the disease correspond closely with those enunciated by Dr. Jackson. Furthermore, the ophthalmoscopic examinations made by Jackson, Uhthoff, and others lend confirmation to these views. It is interesting to note that in some of the cases examined from the standpoint of the ophthalmologist, not only have the eyeground lesions which Dr. Jackson has just depicted been noted, but forms of peripheral amblyopia and migraine. Thus, Koster noted in his case, in addition to venous hyperemia of the fundus, periodic obscurations of the visual field which lasted for several hours and which he attributed to disturbances in the circulation in the retina.

I have examined two cases which presented some of the symptoms of polycythemia, finding great increase in the size of the veins, which were a very dark color. These patients, however, failed to present all of the symptoms of cyanotic polycythemia and therefore the physicians in charge were not willing to make a positive diagnosis of this disorder.

DR. HOLDEN: Several months ago a patient came to the Vanderbilt Clinic complaining of failing vision and on examination presented a curious retinal picture, like some of the drawings shown here. There was no edema of the retinas but the veins were large and tortuous and dark. There was a central scotoma for red and green in each field and a definite history of the excessive use of tobacco. In the medical department the diagnosis of polycythemia was made. He was only under observation a short time, showed no improvement in vision, and I was never quite sure whether the central defect was due to this disease or to the abuse of tobacco.

A CASE OF INTRA-OCULAR TUBERCULOSIS WHICH CLOSELY SIMULATED GLIOMA OF THE RETINA.

BY DR. SAMUEL THEOBALD,

BALTIMORE.

Edward B., a negro lad, 5 years of age, was first seen Feb. 6, 1907, in the out-patient department of the Baltimore Eye, Ear and Throat Charity Hospital. His right eye, the conjunctiva of

which was injected, exhibited a circumscribed scleral staphyloma to the nasal side of the cornea. Ophthalmoscopic examination showed marked opacity of the vitreous humor, with a reflex strongly suggestive of glioma of the retina; and this view of the nature of the affection appeared to be confirmed by the yielding of the sclera, the intra-ocular growth seeming to be about to break through the ocular tunics. Immediate enucleation of the eye was urged, but not accepted.

Three weeks later, Feb. 26th, the case reappeared in my clinic at the Johns Hopkins Hospital. The bulging of the sclera by this time had increased somewhat and ulceration of the overlying conjunctiva had occurred. No appreciable change in the intra-ocular condition was observable with the ophthalmoscope. Removal of the eye was again urged, and this time my advice was accepted, and the patient was admitted to the hospital.

Two days subsequently the eye was enucleated in the usual manner, except that the conjunctiva and subconjunctival tissue in the region of the staphyloma were removed, as well as a part of the internal rectus muscle. Recovery from the operation was uneventful.

During the patient's stay in the hospital, an abscess found to be present in the calf of his right leg was opened, and a considerable quantity of pus evacuated. A careful examination of the lungs, heart, and abdominal organs made at this time showed nothing abnormal.

The enucleated eye was sent to the pathological laboratory of the hospital, where it was examined by Dr. W. G. MacCullum. As will be seen from his report, the intra-ocular changes which I had regarded as almost certainly due to glioma were, in fact, tuberculous in character.

At the present writing, nine weeks having elapsed since the removal of the eye, the orbital contents present a healthy appearance, and the lad's general condition is fairly good, though the operative wound in the leg has not yet closed, and there is a glandular enlargement in front of the left ear.

MICROSCOPIC NOTES.

BY DR. MACCALLUM.

Section through the middle of the eye shows a mass of abnormal tissue, occupying a large part of the cavity of the eye. (See Fig.) The lens is pushed forward and the retina is included in the mass and lifted up from the underlying choroid, from which it is separated by a pigmented coagulated mass. The vitreous humor is reduced to a small amount lying between the foreign mass and the lens. The deeply stained mass of material occupying the cavity of the eye is seen to extend through the sclera, and to spread out upon the outer surface of the eyeball, extending forward as far as the cornea. On the opposite (temporal) side the sclera is apparently intact. The optic nerve shows on one side a small portion of the same deeply staining tissue. Microscopically it is found that this mass is composed of a dense granulation tissue, throughout which are scattered numerous tubercles with typical giant cells, concentric arrangement of epithelial cells, lymphoid cells, etc. There are quite extensive areas of necrosis, with fine fragmentation of the nuclei. The tuberculous granulation tissue is found to begin far forward in the retina, in the substance of which at about the ora serrata there are isolated tubercles. On passing backward it is found that the elements of the retina are spread wide apart by the growth of tuberculous tissue, and fragments of retina are found scattered here and there in the substance of this tissue, usually however on its outer surface. The same thing is true on the other side of the eye, where the tuberculous tissue extends forward to the region of the ciliary muscle. The sclera is interrupted at one point and the tuberculous tissue is continuous with that on the outer surface, which has the same general characteristics. In the space between the tuberculous mass and choroid, that is outside of the displaced retina, the fluid and blood which fill that space are permeated by delicate strands of newly formed connective tissue cells. This is true also of the fluid in front of the retina, for from both sides of the retina near its anterior margin there springs a loose granulation

tissue, which sends off these fine filaments in the fluid contents of the eye. The cornea and lens are unaffected. The sclera at the posterior surface of the eye shows a few scattered tubercles in its substance. Repeated search for tubercle bacilli revealed none.

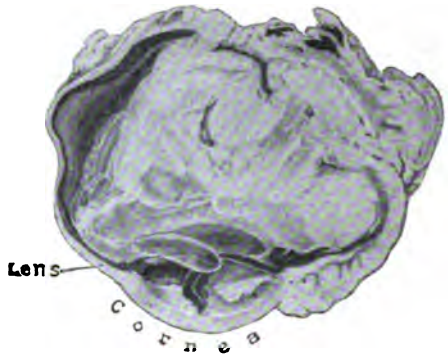

Many cases are reported in which tuberculous lesions of cornea, sclera, conjunctiva, etc., occurred and not a few of tuberculosis of the iris.

Schultze (Archiv. f. Augenheilk., Bd. 33, S. 145-158) described the chronic tuberculous iritis with exudate into the anterior chamber, and thinks it due to infection from the conjunctival sac.

Ammann (Zur Iristuberkulose, Klin. Monats. f. Augenheilk., Bd. 35, 1897, S. 135) found in one case a large white tumor in the corpus ciliare bordering on the iris and cornea.

Lubowski (Arch. f. Augenheilk., Bd. 35, Heft 1/3, S. 183-191) describes a case in which the retina, iris, and ciliary body were tuberculous, and gave symptoms of glaucoma. The retina in its posterior part was thickened to three times the normal. A flat, cauliflower like mass projected from the papilla of the optic nerve into the vitreous. Microscopically this was a tuberculous mass. This probably began in the iris and later affected the retina by implantation from the iris. L. could find only 3 cases in the literature.

Occasionally but not often there are glaucomatous symptoms. *De Berardini* (Tuberculosi bulbare cronica propagata al nervo ottico, Lavori della clin. ocul. R. Univ. d. Napole, V, p. 254) de-

scribed an eye filled with tuberculous masses which extended into the optic nerve and upon the conjunctiva. Animal inoculations positive.

The retina is generally only secondarily affected, even in severe intra-ocular tuberculosis.

In *Kunz'* case (Tuberkulose des Auges, etc., Inaug. Diss., Marburg, 1898) the retina was involved; and *O'Sullivan and Story* (Tuberculosis of retina, Transactions of Royal Academy of Medicine of Ireland, Vol. XVII, p. 1) describe a case in which the retina was the chief seat of infiltration.

PRELIMINARY REPORT OF TWO CASES BELIEVED TO BE INTRA-OCULAR TUBERCULOSIS.

BY COLMAN W. CUTLER, M.D.,

NEW YORK CITY.

Case No. 1. Tumor of Choroid. Probably Conglomerate Tubercle.

Case No. 2. Relapsing Plastic Choroiditis, Probably Tubercular.

This report is of interest because of the unusual character of these cases, and especially because of the careful clinical observations and opsonic determinations of the blood in connection with the use of tuberculin, which has been done by Dr. N. B. Potter for the first time in cases of this sort. The cases are still under observation and treatment and it is possible that later developments may alter, to some extent, the conclusions offered here. But it is believed that the diagnosis and hypothesis are justified by the facts at hand.

CASE I.

C. A., Male. Seventeen years old. At school. Family history negative to tuberculosis, heart and kidney disease. *Previous History.* When eight years old, measles. During convalescence,

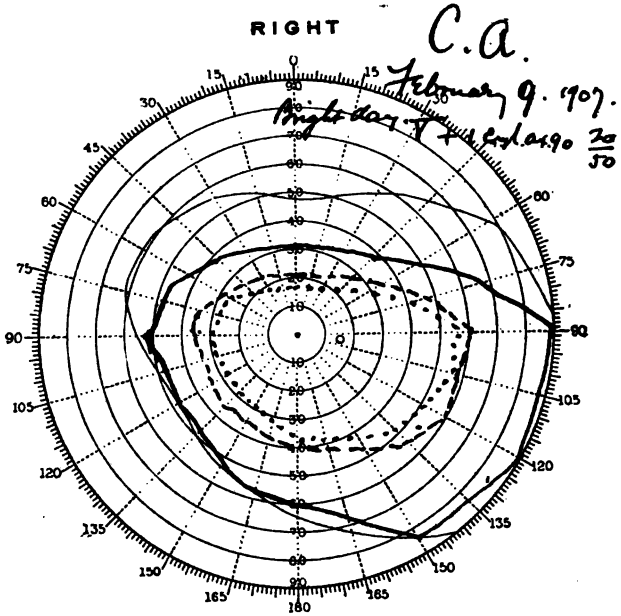
RIGHT
C.a.
February 9. 1907.
Bright day. V
0
15
30
45
60
75
90
105
120
135
150
165
180

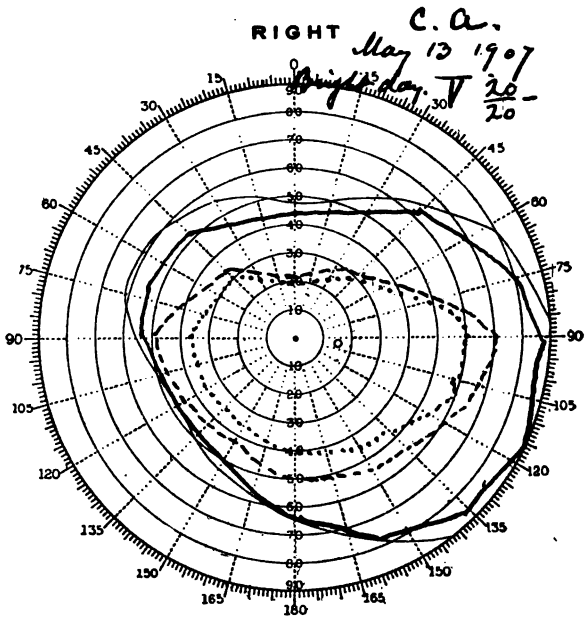
RIGHT
C.a.
May 13 1907
Bright day. V 20/20
0
15
30
45
60
75
90
105
120
135
150
165
180

symptoms of peritonitis, thought to be due to appendicitis. Abdomen opened, peritoneal cavity found filled with a large quantity of clear viscid lymph, but appendix was normal and was not disturbed. Peritoneum was thickened and succulent, but not congested as in peritonitis of septic origin. Operation by Dr. Robert T. Morris. Patient recovered from peritoneal conditions and later developed pericarditis, pleuritis and meningitis. Following summer had malaria. Since then an occasional bilious attack. Habits — smokes three pipes a day. No alcohol. Appetite good. Bowels regular as rule. Patient out of doors a good deal. Venereal — no history obtained.

Present history. No history of trouble with eyes until present illness, November 24, 1906. On this day, shortly after kicking football (patient states positively he suffered neither blow nor fall, nor made any very violent exertion) he noticed a blur before right eye, obscuring the upper half of objects. Neither pain nor irritability of eye. This blur remained unchanged. November 28, 1906,— Ocular examination,— Neither eye shows any external signs of disease. Pupils equal. Tension normal. Media clear.

O. D. A large tumor-like mass is seen downwards involving the lower half of the fundus, from a distance 2 nerve diameters below the papilla as far as can be seen towards the periphery. The upper part of this mass, for from 3 to 4 nerve diameters rises gradually 2 to 4 diopters; the lower part then rises rather abruptly to an elevation of 8 to 10 diopters. The surface is fairly smooth. The color is that of the normal fundus without any nodular appearance. The mass is immobile. At its upper margin, there is considerable grayish œdemalike striation of the retina, reaching nearly to the macular region. Over the greater part of the tumor, there is a branching network of dark lines and lighter spaces, apparently sub-retinal, suggesting, in some degree, the tapetum of the choroid. No signs of active choroidal disease, no new vessels and no connective tissue over any part of the tumor nor in the extreme periphery of the fundus. The optic nerve is hyperæmic, the veins somewhat enlarged and tortuous. Würdeman's transilluminator showed diminished translucency over the site of the

tumor. Vision 20/200; O. S. normal; vision 20/20 +. Treatment — rest in bed; limited fluids; eye bandaged; pilocarpine gr. 1/5 by hypo. daily for five days, followed by profuse perspiration.

Physical examination. Dr. N. B. Potter; December 1st; well developed and nourished; rather pale. Left apex — slight retraction — diminished expansion; slight dullness; prolonged expiration; otherwise normal; urine normal. December 5th; Syrup acidi hydriodic; gtts. 20 to 60 t. i. d.

December 6th; examination of nose by Dr. Culbert; anterior part of middle turbinate removed on account of long standing obstruction of right nostril. Right frontal sinus probed and irrigated.

December 16th. It was apparent that the vision had improved and the field has become larger, although the recumbent position prevented an accurate examination. All signs of retinal œdema had disappeared and the tumor seemed more sharply defined. Exploratory puncture of the sclera was performed in the median line at the point of greatest elevation of the tumor. No fluid escaped. The ophthalmoscopic appearance of mass was unchanged except that the puncture was visible as a slight cicatrix with connective tissue, showing that the knife had penetrated the tumor sufficiently to allow any fluid contents to escape, had such been present. Nerve slightly swollen; above nerve, gray patch.

January 8th; Tb. Opsonic index, 1.35. January 14th; 2 mg. Koch's T. R.; no constitutional reaction; temperature depressed one degree. January 15th: Tb. Opsonic Index, 1.45. January 18th: nerve somewhat more hyperæmic, swollen 1 to 2 diopters. Small gray patch previously noticed above the nerve has resolved into three discrete flecks and slightly below the level of the nerve, along the course of the inferior nasal vein, and posterior to the level of the vessels are eight small gray dots. January 20th: Tb. O. I. 1.02. Spots previously noted are unchanged. The dots downwards and inwards have become much more numerous, some of them being slightly confluent. Further to the nasal side, along the margin of the tumor, are a few small clear striations such as might be caused by stretching or thinning of the retina or super-

ficial choroid. January 21st; group of dots to nasal side of nerve are more fuzzy and larger, but not more numerous. January 24th; this group has almost faded, while during the past few days, a new collection has appeared a little above and further to the nasal side, of the same character. These begin as small discrete dots of a clear white, gradually becoming larger and less sharply defined, fusing with those nearest and, in the course of two or three days, fading away entirely, so that, on January 26th, the first group have entirely gone, the second have become much fainter and with irregular splotches almost like albuminous exudations.

January 31st; 5 mg. Koch's T. R. Tb. Op. Index, 1.13. February 1st, O. I., 1.00; A. M., O. I., 0.9, P. M. Apparently a negative phase. Marked constitutional reaction with a rise of temperature to 101.6 — a total of nearly 3°. Condition of eye same as at last note, except spots were even less sharp and no new ones seen. February 2d, Tb. Op. I., O.8. Nerve a little redder, grayish œdema of nerve fibres. One rather larger white dot remains, others have disappeared. February 4th, Tb. Op. I., 1.25; constitutional reaction over; greatest elevation of tumor apparently 10 to 11 diopters. February 6th, elevation 9 diopters; February 7th; nerve less turgid and edge of tumor more sharply defined. A few more faint dots seen with strong illumination (electric ophthalmoscope), single large one downward is brighter. February 9th, Tb. Op. I., 0.8; Inoculation of 0.0001 mg. T. R. February 10th, Tb. O. I. 0.7; 11th; Inoc. 0.0002 mg. T. R. Spots almost faded except single one downward which is also smaller and duller. Tumor seems wrinkled on its surface as if it were contracted. Elevation 9 diopters. Vision plus 1 cyl. axis, 90 equals 20/40 minus. 14th; Tb. Op. I., 1.45; Inoc. 0.0004 T. R. 15th; Tb. Op. I., 1.02; 18th; Changes since last note trifling until today, when a new group of spots was noted in same general locality. With brightest light, many of old spots can be seen deeply, although invisible to ordinary illumination. February 19th; Tb. Op. I., 0.71, Inoc. T. R., 0.0008.

February 21st; Tb. OP/I., 0.85; Inoc. T. R., 0.0016. The evo-

lution of group noted on February 18th, progressed until February 22d. Those that appeared first became less pronounced, while newer ones made their appearance. No constitutional disturbances. February 23d; O. I., 1.05; Tuberculin inoc. withheld because of marked local reaction in eye. February 27th; spots have diminished in order of their appearance. Those appearing on 18th having in part disappeared. Those noted on 22d being less clear. The nerve which was hyperæmic and somewhat swollen on 20th has become more normal. Vision 20/30.

March 3d; Tb. Op. I., 1.05; 5th; the groups of dots have continued to diminish in number and distinctness. In the periphery, to the nasal side, at the margin of the flatter part of the tumor, seen best with plus 2 diopters, is noted an irregular slate-colored area with whitish striae near it, and below it, and towards the nerve is a faint reticulation not previously seen. These appearances remained practically constant, becoming perhaps a little more marked and being apparently independent of the fluctuation of the crops of dots which seemed to coincide with the lowered Opsonic index and which followed with some regularity the larger doses of tuberculin. 7th; Op. I., 0.87; 18th; appearance of tumor the same; very few dots seen, and they are almost invisible, with brightest illumination. Grayish sub-retinal striation well marked.

In order to bring the retinal or choroidal changes more definitely into association with the inoculations, an interval of nearly a month had been allowed to elapse since the last inoculation during which time there was a gradual and uninterrupted subsidence of the fluctuating ophthalmoscopic changes.

March 19th; Inoc. 0.002 mg. T. R. I. O., 0.9. March 21st; O. I., 1.13; 23d; Inoc. 0.003 mg. T. R. 25th; faint reappearance of dots began on 20th, increasing slightly during following days until today. Seem brighter, but on the whole, much less marked than after large injection February 18th, as if patient were acquiring some tolerance. 26th; Wt. 146 1/2; 1/200,000 B. F. 28th; O. I., 0.83; 30th; 0.000001 B. F.

Radiographic Report, Dr. Lewis Gregory Cole.

Plate 4576.

Region: Chest posterior.
Position: Back flat on plate.
Distance of tube from plate 50 cm.
Exposure, 15 seconds.
Both lungs equally aërated.
Heart shows distinctly.
Walls of the bronchi show distinctly.
Apexes apparently do not appear to be affected.
There is very marked thickening around the root of the lungs, particularly the right side. In the region of the descending bronchus, there are several isolated tubercles.

Plate 4577.

Region: chest anterior.
Position: abdomen flat on plate.
Distance of tube from plate 50 cm.
Exposure, 15 seconds.
Shows thickening around root of right lung even more distinctly, and on this plate, though the involvement of the parenchyma is very slight, I believe we are justified in making a diagnosis of tuberculosis.

April 2d; O. I., 0.78 0.000002 B. F. After Dr. Potter's visit to Saranac, it was decided to employ Bouillon filtrate instead of T. R. Therefore, the small doses were returned to and increased rather rapidly. April 2d; spots are not easily seen but whole region to nasal side of disc and below the horizontal line is a little blurred as though by sub-retinal or choroid œdema. April 4th, 0.000003 O. I., 0.95; appearance of œdema is less. One larger spot seen faintly below the macula grayish in color. April 6th; 0.000004 B. F. April 9th; 0.000013 B. F. The reaction in eye had been so slight that at my suggestion a more rapid increase of dosage had been attempted. April 11th, during last few days, a new crop of fine dots have appeared in original neighborhood, more numerous than for some time past. April 16th, 0.000013 B.

F. April 18th, O. I. 0.86; April 19th, the last profuse crop has gradually faded without any exacerbation during the past week; April 20th, O. I., 0.87, 0.00002 B. F.

May 4th; the inoculations were continued, and on May 1st, a few fresh dots were seen, increasing for four days. About twenty inoculations given, small, with the exception of the first ones, given to produce a constitutional reaction. These small doses will be continued avoiding local as well as general excitation.

This case is reported because the facts themselves are of interest regardless of the construction given them. There can be little doubt that this patient has tuberculosis. The reaction to tuberculin, the physical signs and the X-ray picture are enough to base a fairly positive diagnosis upon.

The intraocular tumor can only be a leuco-sarcoma or a conglomerate tubercle, and the latter diagnosis seems probable because of the appearances of the small white dots in repeated crops after the tuberculin inoculations. It is of great importance however, to determine by experiment whether any other kind of neoplasm reacts to tuberculin, as sarcoma does to certain toxins. These dots vary in size from 1/4 to nearly twice the calibre of a vessel of the first order. They were never seen in front of the vessels; in fact, the impression received was that of considerable depth, as if they became less distinct or their appearance was delayed by the œdema noted as following the use of tuberculin and reappeared three or four days after the inoculation, when the swelling had diminished. This hypothesis is supported by the cycle following the first inoculation of January 14th, which lasted nearly two weeks. And again, on February 18th. At times, it seemed as if the action of the inoculations was cumulative — as if the response was not due to single large doses. It is natural to assume that this cycle constitutes a local reaction caused by toxins from tubercular foci in the tumor. The fact that the eye showed no general reaction, no ciliary injection, or photophobia, and that the vitreous was always clear, might indicate that the bacilli were not numerous in spite of the size of the tumor.

The tumor may well have existed for a long time without at-

tracting attention until the sudden appearance of the blur, which would indicate an increase of œdema or detachment of the retina around the mass and nearer the macula, impairing central vision, which disappeared with the preliminary treatment. Since that time, vision has remained practically unchanged, and the field for form has increased. The mass of the tumor has not increased in size, although certain unexplained structural changes have become apparent near its margin, not exactly like those described by Haab in his classic case of conglomerate tubercle, but possibly of similar origin. The stationary character is contrary to the rule in tubercle of the eye, and might be attributed to the influence of tuberculin.

The field of vision does not correspond to the area of the tumor, showing that form and perception of white objects is retained over a considerable part of it, while gray, and, even with bright light, large colored objects are seen less well showing that the light sense is impaired as well as the color sense. It is not possible to predict the outcome but the patient will be kept under observation and it is hoped that a later report may throw more light on the nature of the tumor and the response to treatment.

Case II.

J. G., male, aged 26. Clerk. Family history: Father died of pulmonary hemorrhage. One sister died several months ago from nephritis and some lung trouble. Did not live with sister. Habits good. No venereal history. Works indoors. Digestion poor. Nervous. Previous history: In 1901, patient had an attack of plastic choroiditis which I reported in a paper read before the section, New York Academy of Medicine. This attack began suddenly. In the left eye, the ophthalmoscopic examination showed in the vitreous a veil of exudation with shreds or filaments stretching forward from the nerve; over the upper and inner half of the nerve was a large white exudation covering, in part, the vessels; outlines of nerve hazy. Vessels not notably large or tortuous. To the nasal side of the nerve, and above it, were two patches, the upper pinkish with edges bordered by a thin deposit of pigment. A retinal vessel passed over it. Below

this, a bright white area slightly raised, with surrounding œdema. Visions 20/50 unimproved. The right eye was normal.

Under treatment with tonics and potassium iodide, condition improved rapidly, and in six weeks vision was normal. Vitreous clear, except for filmy opacities from the exudate overlying the optic nerve. One and a half years later vision was still normal. The ophthalmoscope showed irregular pigmentation and partially atrophic areas corresponding to the former exudation. There were branching prolongations of connective tissue over the vessels on the nerve and extending a little into the vitreous. No signs of activity. There was no suspicion at that time of any constitutional condition except possibly syphilis. But, as the ocular condition improved with comparatively small doses of iodide and coincidental with the improvement in his general health, this diagnosis was not considered probable.

Present history. January 29, 1907. Patient reappeared with the following history. Two weeks ago, he coughed up five or six mouthfuls of blood. At about the same time, he noticed that the vision of the left eye was blurred as six years ago. Three days ago, had another hæmoptysis, several drams, the blood being bright and frothy. Vision has been growing steadily worse. No cough, no sputum, no fever, no sweats, no cardiac or renal symptoms.

Examination by Dr. Potter. Patient fairly nourished — not anæmic. Heart normal. Lungs — right, normal, left, slightly diminished expansion, and impaired percussion note over apex anterior and posterior. Anteriorly, just below clavicle, inspiration is a little harsh and there are a few fine subcrepitant rales and a little increase in whispered voice. Weight 134 pounds.

Ocular examination. Vision right eye, 20/15, normal.

Left eye, 20/40, unimproved. Vitreous: many opacities large and fine; nerve edges blurred upwards and inwards, with œdema extending in that direction one-half to one nerve diameter beyond; outwards and downwards, edges fairly sharp. Upwards and inwards, beyond the exudation on the nerve, about one and one half nerve diameters, is a large white area with blurred soft edges.

Below this, two nerve diameters, or more, is a small area, apparently less active, and between these, several characteristic spots of disseminated choroiditis. Between these is a faint irregular area with serpiginous edge showing indistinctly an erosion of superficial layer of choroid or deep retina, with a very few indistinct white spots at the edge. Cornea, iris, aqueous, lens, normal. Eye not irritable. Tension normal.

February 4th, in French hospital. Temperature, pulse, respiration normal. No further haemoptysis. Tb. O. I., 1.56. February 10th, Tb. O. I., 1.00, general condition improving. No change in pulmonary signs. February 14th, Tb. O. I., 1.34. No rales heard. February 15th, the exudation in vitreous increased; — that on the nerve became more prominent, still confined to the upper and inner quadrant. Vision in left eye, 15/200.

February 17th, 1/20,000 mg. Koch's old Tb. General condition continues to improve. February 17th, vitreous the same; nerve covered with exudate, white; swollen one to two diopters; the clear white mass upwards and inwards is more sharply defined toward the nerve, but seems to be extending somewhat with the soft edge outward; the other conditions unchanged. February 19th, 1/10,000 mg. Koch's old Tb. O. I. to Tb. 0.93. February 20th, O. I. to Tb. 1.07. February 21st, O. I. to Tb. 1.84 1/5,000 Koch's old Tb. February 23d, nerve somewhat clearer, vitreous haze more dense, large spot has a light aureola beyond it as if of an extension outwards, corresponding to the scotoma. Otherwise, same. Vision 20/70. February 26th, 1/2,500 mg. Koch's old Tb. General condition same. Eye conditions appear worse. Vision 20/70, minus. Vitreous haze denser with several new filaments in front of nerve and below it, the large spot is broader and more blurred at the edge, upwards especially. Exudate on the nerve a little less pronounced.

March 1st, condition of eye the same; March 4th, O. I., 1.06; vitreous much clearer, otherwise the same, vision 20/40. March 7th, O. I. to Tb. 0.7, vitreous a little less clear, nerve looked less sharp; extension of large patch out and up is more œdematous but no larger. This activity is undoubtedly responsible for the

vitreous opacities, but it is possible that the exudate on the nerve is also active. Vision 20/40. March 9th, vision 20/30 minus. Advance of exudate has ceased. Vitreous clearer. March 13th, continued improvement, exudate on nerve is much thinner and only up and in does it extend beyond the nerve edge. There are two small areas on the nerve, brighter or whiter than the rest and apparently slightly elevated. March 14th, had a small haemoptysis yesterday and slight epistaxis this A. M. Pulmonary signs same. No rales. Temp. 98.8. P. 88; sent home to keep absolutely quiet. March 15th, no further haemoptysis, temperature 98.8, P. 84. March 20th, has been perfectly quiet, no further haemoptysis; temperature normal; P. 84. O. I. 1.68. March 21st, in spite of the slight hemorrhage a week ago, he thinks the eye has improved. Vision 20/30. March 26th, Bouillon Filtrate, .0000001. March 28th, condition continued to improve steadily, vision 20/20. The white patch is much grayer, showing faintly granular edge and partial atrophy of the choroid, which is seen to extend far towards the periphery in a narrow, irregular oval. The atrophy is not deep, the floor being granular; pigmentation is not black but grayish or slate-colored. The other areas have remained practically unchanged. The small whitish areas on the nerve stand out in greater relief. Vision 20/20.

Radiographic Report. Dr. Lewis Gregory Cole.

Plate 4580.

Region. Chest posterior.

Back flat on plate.

Distance of tube from plate, 22 in.

Exposure, 15 seconds.

Shows a well marked infiltration of the left apex with a few scattered tubercles throughout the entire left lung. There are a few isolated ones apparent in the apex. As seen in all these cases of early infiltration of the parenchyma, we have a very well marked thickening of the roots of the lungs. Whether this is due to thickening of the walls of the bronchi or deposits in the bronchial glands, I am unable to say definitely, but probably it is the latter.

Plate 4581.

Region. Chest anterior.

Position, abdomen on plate.

Distance of tube from plate 50 C. M.

Exposure, 15 seconds.

The infiltration appears very much more marked in the anterior plate, showing that the lesion is more in front than behind.

March 30th, B. F. .0000002; April 2d, B. F. .0000002; April 4th, B. F. .0000005; April 6th, B. F. .0000006; April 11th, B. F. .000001; April 16th, B. F. 000002; April 20th, B. F. .000003; April 23d, B. F. .000004.

This patient undoubtedly has tuberculosis, as shown by the physical signs, the history and the X-ray plates. Because of the active choroiditis, it was not thought wise to give a large dose of tuberculin to produce a constitutional reaction. Tuberculosis, as a factor of the ocular condition, was not suspected in 1901, and the rapid recovery made it necessary to group it in the large and ill-defined class of plastic choroiditis. The recurrence of the ocular condition in an almost identical manner, coincidental with the development of an acute pulmonary lesion, makes it probable that the present attack is tubercular, especially as it has recovered with no other treatment than rest and repeated inoculations of small doses of tuberculin. The condition was advancing somewhat rapidly. The choroidal exudate was increasing during the first period of observation without any treatment, until on February 15th, vision was 15/100. After that date, the changes correspond, as will be seen by the notes, to some extent, to the use of tuberculin. On February 26th, there was a slight increase of exudation, which would perhaps indicate that the tuberculin had been increased too rapidly, provoking a greater activity. This was followed, however, by a gradual improvement, which has continued with slight fluctuations, which may or may not have been due to the treatment, until a relatively normal condition was reached.

DR. POTTER. The interesting part of these cases from a medical point of view is this: If the diagnosis is correct, can we, by watching the changes in the back of the eye, throw some light on the action of tuberculin? In following the opsonic determinations it was hoped that possibly we should note some changes in the back of the eye coincident with the fluctuating index. In the present state of opinion regarding opsonic index determinations we are not justified in drawing any conclusions. In the symposium yesterday, before the Association of American Physicians, it seemed the consensus of opinion that the index is not sufficiently accurate to permit drawing any definite conclusions. In the second case here reported tuberculin was not used for diagnosis because the character of the general disease settled that point. The use of small doses of tuberculin has been so well justified by Dr. Trudeau's results that it seemed wise, in these cases, to follow his principle and try to avoid any local reaction in the eye. At the same time, from what Dr. Cutler tells me of the retinal pictures, it seems that when we produce a slight reaction the ocular condition improves more than when we entirely avoid it. As you know, tuberculin only confers a brief and relative immunity against the disease, but from a clinical standpoint this slight change seems helpful.

DR. DUANE. I had the opportunity of seeing Dr. Cutler's case and almost at the same time was treating a case in my own practice which was similar in the following respects: First, age. My patient was a young man (21) and apparently healthy in all respects. Second, absence of any assignable cause, even traumatism. Third, suddenness of development. In my case the man could be sure that his trouble developed suddenly, because he was amblyopic in the other eye. Fourth, there was a non-pigmented, non-nodular mass, occupying a large part of the lower half of the fundus, elevated about 10 diopters at its inferior edge and shelving off gradually towards the macula. Fifth, and most striking was the development, apparently as the result of the tuberculin injections, of these white dots that Dr. Cutler speaks of, something different from anything I have seen before by the ophthalmoscope. They were close to the large retinal veins, the papillary veins of the second order, were about 1/12 of a disc diameter in width, very faint so as to be made out only by close

examination, entirely unassociated with changes in the surrounding structures and appeared and disappeared with great rapidity.

The difference between my case and Dr. Cutler's was: First, absence of any vascular changes whatever, occurring either primarily or as the result of the action of the tuberculin; second, absence of any change produced by the tuberculin except the white dots above mentioned; third, the fact that in the blind area of the field the loss of sight was everywhere absolute, not relative as in Dr. Cutler's case. The query suggested itself to Dr. Cutler, whether the difference in the character of the field in the two cases might not be of some diagnostic significance, the more absolute loss of sight being rather indicative of sarcoma. Again he queried whether tuberculin might not produce some reaction in a case of sarcoma as well as in one of tuberculosis, so that the development of the white spots in these two cases might not have the diagnostic importance that we are inclined to give them.

Dr. Gruening. I had the opportunity of seeing Dr. Cutler's case twice. The first time I saw these white spots, deep in the retina, and a system of white lines, parallel lines across the retina, with a system of white lines vertical to the first system; I need not go into details because I saw what Dr. Cutler saw at that time and has described. I was very much surprised when I examined the case 10 days later to find that the spots and the two systems of lines had disappeared. I understand now that these changes are ascribed to the action of tuberculin.

Dr. Verhoeff. I think that we must recognize now that there are at least two distinct types of ocular tuberculosis. One is the well known type illustrated by the cases of Dr. Theobald and Dr. Cutler, upon which hitherto our ideas regarding tuberculosis of the eye have been based. The other type has been brought to light only during the past few years by the diagnostic use of tuberculin, and has shown that tuberculosis of the eye is a common rather than a rare affection. This type is characterized by the extreme chronicity of the lesions, and by the more important fact that it is amenable to treatment. To this type belong many cases of choroiditis, cyclitis, iritis, and interstitial keratitis. I have recently shown also that most if not all cases of nodular scleritis are due to this chronic form of tuberculosis. In fact, with the exception of episcleritis periodica fugax, and the rare

cases due to syphilis and leprosy, I believe that all cases of scleritis are due to tuberculosis. The recent experimental work of Stock has thrown considerable light on this type of tuberculosis. By injecting rabbits intravenously with tubercle bacilli he found that foci were always produced in the choroid, iris or ciliary body. These lesions displayed a marked tendency to undergo spontaneous healing and only exceptionally went on to caseation and destruction of the eye. He also found that foci in the ciliary body were most apt to persist, which suggests that scleritis is always primarily an extension from cyclitis.

DOUBLE PERFORATION OF THE EYEBALL BY IRON AND STEEL.

BY DR. WILLIAM M. SWEET,

PHILADELPHIA, PA.

It is not uncommon in injuries of the eyeball from small shot and from particles of exploded dynamite caps for the foreign body to pass completely through the globe into the orbit. Double perforation of the eye by splinters of iron or steel is, however, comparatively rare, as the metal seldom enters the eyeball with a force equaling that imparted by powder or other explosives. Prior to the use of the Roentgen rays in the localization of foreign bodies it was impossible to determine perforation of the posterior scleral wall except in instances in which the wound of exit of the body from the eyeball could be seen with the ophthalmoscope or where enucleation was done and the body found in the orbit. Two cases are reported, one by Hirschberg and one by Seggel, in which the diagnosis was made by the ophthalmoscope, the wound of exit of the metal being plainly seen in the fundus. Kraus, in reporting a case in 1904 of a large splinter of steel which passed through the eyelid and spitted the globe,

[1] Central. f. p. Augen., Jan., 1903.
[2] Klin. Monats. f. Augen., July, 1903.
[3] Zeitsch. f. Augen., No. XI, 1904.

could find but 24 previously reported cases of double perforation by iron and steel. It is probable that the number of injuries of this nature was greater than these figures indicate, but the precise character of the traumatism was not recognised owing to the imperfect means of diagnosis employed.

The cases of double perforation which are given in this paper include injuries from iron and steel, and one from brass, the class of traumatisms that occur in industrial establishments or in occupations requiring the use of machines or tools in working these metals. The subject of gun-shot injuries has been fully considered recently by Marple, so that traumatisms of this character and those from dynamite or other explosives have been eliminated.

The cases here presented have been divided into two groups, the first comprising those in which the radiographs showed the body to have lodged in the posterior scleral wall, a portion of the metal protruding through the sclera into the orbit; and the second group those in which the metal passed completely through the eleball into the orbit.

Many of the patients were referred to me for X-ray localization, and I am indebted to the gentlemen who are named in the individual history of each case for the subsequent history which they have supplied of the results of operation and treatment.

The detailed history of the cases of partial double perforation are as follows:

CASE I. Partial perforation of posterior scleral wall by a large piece of steel. Removed by forceps. Eye quiet three months later. Joseph C., came to the Wills Hospital, service of Dr. C. A. Oliver, May 1, 1901, with injury of the right eye received one week previously. Examination showed a scar of the cornea in the horizontal plane, close to the nasal limbus. Radiographs located a metal body, 6 x 2.5mm., imbedded in the scleral wall, below the disc, one end of the metal extending a distance of 3mm. into the orbit. Operation through an opening between the

[1] Section on Ophthalmology, A. M. A., 1906.

external and inferior recti muscles. The small Hirschberg magnet failed to secure the body, and it was removed by forceps. Three months later the eye was quiet. The man has since disappeared from observation.

CASE II. Piece of cast iron, 10 x 6mm., perforated posterior scleral wall. Removed by forceps. Enucleation. Joseph H. was injured in the right eye 5 weeks before coming to the Wills Hospital, service of Dr. Wm. McClure, on August 25, 1902. There was a scar of the cornea, 10mm. long, extending through the lower or temporal limbus, the lens cataractous, and the eyeball tender. Radiographs showed a metallic body, 13 x 6mm., situated at the posterior portion of the vitreous chamber, slightly below the horizontal plane to the temporal side of the globe, one end of the metal projecting through the sclera into the orbit a distance of 8mm. The magnet was entered through a scleral opening, and, although it attracted the iron, it was only dislodged by means of forceps and scissors. Enucleation one month later for iridocyclitis.

CASE III. Perforation of the posterior scleral wall by a piece of steel, 14 x 1.5mm. Panophthalmitis. Enucleation. William D., entered Pennsylvania Hospital, service of Dr. Geo. C. Harlan, February 4, 1903, with injury of the right eye by a splinter from a steel sledge, received two days previously. Central perforation of the cornea. Radiographs showed a piece of metal, 14 x 1.5mm. slightly above the optic disc, one of the sharp ends extending through the sclera into orbit a distance of 7mm. Panophthalmitis developed, and the globe was removed. The metal was found in the position indicated by the radiographs.

CASE IV. Piece of steel, 10 x 3mm., perforated posterior scleral wall. Patient refused operation and disappeared. Louis I., came to the Wills Hospital, April 23, 1903, service of Dr. S. Lewis Ziegler, with inflammation of the right eye, due to an injury received 3 weeks previously while striking a steel chisel with a large sledge. A scar of the cornea was seen in the lower outer portion, and the lens was opaque. The X-rays showed a metallic body, 10 x 3mm., perforating the posterior scleral wall, above and

to the temporal side of the macula. The difficulty of extracting the body was explained, with the possible loss of the eyeball, but the man refused operation and disappeared.

CASE V. Injury by piece of steel, 9 x 2mm., which penetrated one-half through the sclera posteriorly. Removal 3 weeks later. Irido-cyclitis. Enucleation. Wm. F. was injured in the left eye September 10, 1905, by a piece of steel from a cutter he was holding while another workman was sledging. Entered Wills Hospital, October 1, 1905, service of Dr. McCluney Radcliffe, who found a scar of the cornea, 4mm. long, near limbus, temporal side. Radiographs showed a piece of metal, 9 x 2mm., situated in the lower inner quadrant of the globe posteriorly, the sharp end of the metal extending through the sclera into orbit a distance of 3mm. Operation 3 days after injury, through an incision in sclera, and the point of the 110-volt hand magnet entered to indicated spot. The body was secured after several attempts, with a mass of exudation which surrounded it. The eye failed to become quiet, and was removed for irido-cyclitis three weeks later.

CASE VI. Perforation of posterior scleral wall by piece of steel, 12 x 4mm. Extraction by magnet. Recurring hemorrhages 6 months later. Enucleation advised. Patrick R. entered Wills Hospital, service of Dr. William Zentmayer, October 10, 1906, with injury of the left eye received six hours previously while chipping a rivet. There was a large cut through the upper lid, an incised wound of eyeball, and hemorrhage into the vitreous. Radiographs located a metal body, 12 x 4mm., situated above the disc to the nasal side, the sharp end of the body extending through the posterior scleral wall into the orbit a distance of 5mm. The Haab magnet was brought close to the original wound, but failed to dislodge the metal. The point of the 110-volt hand magnet was then inserted to the indicated location of the body, and attracted the metal, but failed to remove it. The Haab magnet was again tried, and the body secured. Six months later the eye was irritable, a depressed cicatrix existed at the point of extrance of the body, and there were recurring hemorrhages into the anterior chamber. Enucleation was advised.

CASE VII. Chip of steel, 14 x 4mm., penetrated partly

through posterior scleral wall. Panophthalmitis. Enucleation. Harry M., entered Wills Hospital, service of Dr. C. A. Oliver, October 15, 1906, with injury of the left eye received two weeks previously, while chipping a locomotive cylinder. Examination showed a scar in the sclera, in the lower outer portion, about 4mm. from the limbus. Radiographs located a metal body, 14 x 4mm., half moon shaped, situated between the disc and the macula, one of the sharp triangular ends projecting 3mm. through the posterior scleral wall into orbit. No attempt was made to extract the metal, as purulent irido-cyclitis had developed, and the globe was removed. The position of the metal corresponded to the situation shown by the radiographs.

CASE VIII. Splinter of cast steel, 6 x 6mm., shown by X-rays to have penetrated partially through posterior scleral wall. Attempts at extraction failed. Enucleation. Morris W. was injured in left eye December 22, 1906, while chipping a steel casting. Entered Wills Hospital, December 28, service of Dr. S. Lewis Ziegler, who found a wound of the upper lid and of the sclera beneath, hemorrhage into vitreous, and imperfect L. P. Radiographs located a metal body, 6x6mm., 25mm. back of corneal centre, 5mm. above horizontal plane, and 3mm. to nasal side of vertical plane, indicating partial perforation of posterior scleral wall. Operation through scleral incision December 31. The Haab magnet at opening failed to attract the body. The point of 110-volt hand magnet was then passed several times to the indicated situation of body, but failed to secure the metal. Dr. Ziegler then dissected an opening to the posterior portion of the globe, but no response was obtained to the magnet point in this situation. The man refused enucleation and was discharged from the hospital. On January 18, 1907, he came to the University Hospital, service of Dr. G. E. deSchweinitz, and consented to removal of the eyeball if the metal could not be secured. Magnet extraction failed, and the eye was enucleated. The metal was found in a mass of exudation at the posterior portion of the vitreous chamber, close against the sclera, but no portion was found projecting through into orbit. There was, however, considerable

thickening of the tissue over the orbital surface of the sclera at the point at which the body was shown by the radiographs to have perforated the globe. Until microscopic sections are made, it is impossible to determine if the sclera had been perforated posteriorly, as indicated by the X-ray localization, but it is possible that the attractive power of the magnets used was sufficient to withdraw the metal from its scleral bed, but could not disengage it from the exudation which had formed about it.

CASE IX. Chip of steel seen with ophthalmoscope in retina between the disc and macula. Body disappeared from view after several applications of Haab magnet. Subsequently localized by radiographs in orbit back of eyeball. The history of this case has been fully reported[1] by Dr. Herman Knapp and Dr. Lewis H. Taylor, but is included in the series which have come under my observation for radiographic examination. The case is of interest, as the splinter of steel, which was seen in the retina, between the macula and the disc, failed to come forward under several trials with the Haab magnet, and later disappeared from its first position. Radiographs subsequently located the metal in the orbit, close to the eyeball. The passage of the metal from its position as seen with the ophthalmoscope out into the orbit can only be explained by the attraction of the magnet, which was placed at the nasal side of the sclera, acting upon the end of the body protruding through the sclera, and causing the splinter to pass out into orbit.

With the exception of Case IX, the metal inflicting the injury was in every instance of large size, varying from 6 x 2.5mm. to 14 x 4mm. Of these 8 cases the eyeball was lost in 5, two from panophthalmitis and 3 from irido-cyclitis, and in another case enucleation will be required for recurring hemorrhage into the anterior chamber. The subsequent history of the remaining two cases is not known, one in which the metal was secured by forceps and one who refused operation.

The cases in which the body passed completely through the eyeball into the orbit are as follows:

[1] Trans. American Ophth. Soc., 1906.

CASE X. Perforation of the eyeball by a piece of steel, 3 x 1 mm. Attempts to extract metal failed. Eye quiet two years later. G. P. was injured in the left eye twelve days before coming to the Wills Hospital, service of Dr. P. N. K. Schwenk, on June 15, 1901. He was engaged in welding an axle, the helper striking the cooling metal with a large sledge, and a piece of the latter struck the eyeball, causing a wound of the sclera in the lower outer quadrant, near the limbus. Radiographs located a metal body, 3 x 1mm., in the lower temporal portion of the orbit back of globe. Attempts to remove the body failed. Two years later the eyeball was quiet.

CASE XI. Piece of steel, 10 x 5mm., passed through eyeball into orbit. Attempts to extract metal followed by collapse of globe. Enucleation. William J. came to Wills Hospital, service of Dr. McCluney Radcliffe, August 3, 1902, with an injury of the left eye received two days previously while splitting wood with a steel wedge, which he struck with a large sledge-hammer. There was a large wound of the cornea, and the lens was swollen and cataractous. Radiographs located a piece of metal, 10 x 5mm., at the upper and inner portion of the orbit, outside the eyeball. An attempt was made to secure the body, but the corneal wound opened, and the eyeball collapsed and was removed. The steel was found to have passed through the eyeball and lodged at the point indicated by the radiographs.

CASE XII. Two pieces of steel localized by the X-rays, one in the eyeball and the other in the orbit. Panophthalmitis. Enucleation. C. L. was injured in the right eye two days before coming to the Jefferson Hospital, service of Dr. H. F. Hansell. Radiographs located two bodies, one in the anterior portion of the eyeball and the other in the orbit back of the globe. Panophthalmitis developed, and the eyeball was removed. Both bodies were found by the magnet at the positions indicated by the radiographs, the metal in the orbit proving to be a splinter from the hammer which had perforated the globe, and the ocular piece a chip from the tool held by the workman.

CASE XIII. Piece of steel, 10 x 2mm., passed through eyeball and lodged in upper portion of orbit. Extraction not attempted. Eye quiet but slightly shrunken three years after injury. Hooper D. was referred for X-ray examination by Dr. J. A. Ellegood on February 25, 1903. The patient gave a history of injury to the right eye ten days previously while helping in a blacksmith shop to sledge cold steel. There was a large scar in the cornea, and the lens was opaque. Radiographs showed a piece of metal, 10 x 2mm., situated 14mm. above the horizontal plane of the globe, one of the ends of the body 21mm. and the other 31mm. back of the corneal centre. No operation was attempted. Three years after injury the eyeball was slightly shrunken, but the man suffered no discomfort.

CASE XIV. Small splinter of steel localized in the sclera below the disc. Extraction attempted but failed. Subsequent enucleation showed body to be in orbit, outside of eyball. Charles W. consulted Dr. C. S. Merrill of Albany, N. Y., on August 19, 1904, with injury of the right eye received while striking a chisel with a hammer. He came to New York City, and the Haab magnet was tried without response, and he was referred to the author for X-ray examination and treatment by Dr. C. W. Cutler. Radiographs made by my assistant localized a piece of metal, 2 x 1.5mm. at the fundus, slightly below the macula, and close against the sclera. An attempt was made on August 26th, to extract the metal with the magnet, but failed. The patient refused enucleation and returned to his home. Irido-cyclitis developed, and on September 23d the eyeball was removed by Dr. Merrill, who wrote that the body was found imbedded under the tendon of the inferior oblique muscle.

CASE. XV. Small piece of steel passed through eyeball and lodged in orbit. Extraction failed. Eye quiet. John R. was injured in the right eye on June 1, 1904, while chipping cast steel, and came to the Episcopal Hospital two days later, service of Dr. W. T. Van Pelt. There was a wound of the sclera to the temporal side, and the vitreous was hazy. Radiographs made at the hospital indicated that the metal was in the orbit, and extraction

was attempted but failed. Two weeks later the patient was sent to the writer for localization, and the body was found to be situated in the upper temporal portion of the orbit, back of the eyeball. No further operation was attempted, and the eye has remained quiet.

CASE XVI. Small strand of brass wire passed through eyeball and lodged in orbit. Eye quiet two years after injury. Thomas W. came to the Polyclinic Hospital, in the author's service, on December 26, 1904, with ecchymosis of the right eye following a blow from a snowball. After having been under treatment for ten days he complained that the sight of the left was failing. Examination showed a blood clot in the vitreous and a small hemorrhage in the upper temporal quadrant of the retina. Externally a spot of hemorrhage beneath the conjunctiva in the lower outer quadrant, 4mm. from the limbus, pointed to the possible entrance of a foreign body. Inquiry developed that the day previously he was winding the spring of an antique clock, the brass wire cable of which parted, and the drum rapidly unwound, causing the end of the broken cable to repeatedly strike one of the cross supports of the works. The boy stated that he had felt a spark strike the face, but was unaware of injury to the eye. Radiographs located a strand of the wire cable, 4mm. long, and extremely thin, in the orbit, 5mm. back of the eyeball and in a line corresponding with the spot of retinal hemorrhage, which marked the point of exit of the metal after traversing the length of the globe. The boy was kept under observation, the hemorrhage in the vitreous absorbed, and vision returned to normal. Two years after the injury the brass in the orbit had caused no symptoms.

CASE XVII. Small splinter of iron passed through eyeball into orbit. One year later eye quiet, vitreous slightly hazy; retinal detachment. John C. came to the Wills Hospital, service of Dr. C. A. Oliver, on February 10, 1905, with injury of the left eye received while chipping a grip-pin. Wound of the eyeball near insertion of the internal rectus, blackish mass in vitreous extending over nasal side of disc, and retina hazy. Radiographs

located a metal body, 2 x 1mm., situated 27mm. back of the corneal summit, in horizontal plane of globe, and 10mm. to nasal side of vertical plane. Magnet gave no reaction. Eye became quiet, and one year after injury, retinal detachment could be plainly seen through the fine vitreous opacities.

CASE XVIII. Splinter of steel passed through eyeball into orbit. Eye quiet for three months. Low grade irido-cyclitis developed, and globe was enucleated. Thin fibrous band extending from eyeball back into orbit. A. J. was injured in the right eye on March 20, 1905, by a splinter from a sledge. Sight was immediately lost, but gradually returned, so that large objects could be recognized, and the congestion of the eyeball subsided. Three months after the injury the eye again became inflamed at which time he was seen by the writer. Vision equaled imperfect light perception, vitreous hazy, eyeball slightly tender, with evidences of low grade irido-cyclitis. Radiographs located a metal body, 4 x 2mm., situated 29 mm. back of the corneal centre and slightly below and to the temporal side of the optic nerve. The inflammatory symptoms failed to subside under treatment, and the globe was enucleated. On the posterior scleral wall, at the probable point of exit of the metal from the globe, there was a mass of thickened tissue, to which was attached a thin fibrous band which appeared to have extended backwards into the orbit. The metal was found by the magnet surrounded by a firm fibrous mass, and it is probable that the band cut in the removal of the globe connected this mass with the eyeball.

CASE XIX. Double perforation by a piece of steel drill. Eye quiet one year after injury. T. B. was injured in the right eye on April 18, 1905, while using a sledge and drill in quarrying stone. There was a large scar in the sclera at the limbus, and the lens was opaque. Radiographs located a piece of steel, 4 x 2mm., back of the eyeball, to the nasal side of the orbit. No attempt was made to extract the steel, and one year after injury the eye was perfectly quiet.

CASE XX. Piece of hammer head passed through eyeball and lodged in sheath of optic nerve. Enucleation. Gerald H. entered

Wills Hospital, service of Dr. Frank Fisher, on April 11, 1906, with injury of the left eye received twenty-four hours previously. The patient stated that he was attempting to remove a board nailed to the floor by placing the edge of one hatchet beneath the strip of wood and striking the head of the hatchet with a hammer. Immediately following a strong blow upon the hatchet he felt pain in the eye and sight was dimmed. Examination showed a vertical wound near the centre of the cornea, the anterior chamber shallow, and the lens cataractous and swollen. No view of eyeground. Radiographs indicated a piece of metal, 4 x 3mm., situated 25mm. back of centre of cornea, 2mm. below horizontal plane, and 4mm. to nasal side of vertical plane. No pain upon application of giant magnet. The eyeball continued tender, and enucleation was performed. Surrounding the optic nerve was a mass of infiltration which responded to the magnet. The fragment of steel was found in the sheath of the nerve to the outer side, giving the appearance of having perforated through the nerve head.

CASE XXI. Small splinter of steel located in orbit back of globe. Lens cataractous. Eye quiet three years after injury. John F. consulted Dr. McCluney Radcliffe on October 18, 1906, for treatment of a cataract of the left eye. Inquiry developed that the eye had been injured three years previously, while striking a drill with a hammer. The patient did not believe that any metal had entered the eye. There was a small tear in the iris in upper portion, near pupillary border. Radiographs located a metal body, 2 x 2mm., in the orbit, 3mm. back of the eyeball and slightly above the horizontal plane. The eye was quiet, and the patient decided to postpone any operation upon the cataract.

CASE XXII. Piece of steel passed through eyeball into orbit. Purulent irido-cyclitis. Patient refused enucleation. Joseph C. was injured in the left eye on December 31, 1906, while striking a steel set with a heavy hammer. Examination a few hours after injury by Dr. E. S. Saylor, showed a wound in the lower inner portion of the sclera; vitreous filled with blood. Radiographs located a piece of metal, 4 x 1mm. in the lower inner portion of

orbit, close to eyeball. The magnet at wound of entrance of body gave no pain. The man refused to enter hospital for treatment, removed the aseptic bandage as soon as he left the institution, and reported twenty-four hours later with beginning panophthalmitis. He refused enucleation and was discharged.

Of the above thirteen cases in which the metal passed completely through the eyeball into the orbit, the globe was lost in five instances, two because of panophthalmitis, one from iridocyclitis, one from collapse of the ball following an attempt to extract the metal, and one in which extraction failed.

It is unnecessary at this time to dwell upon the importance of X-ray examination in every instance of ocular injury from foreign bodies. In no other way is it possible for the surgeon at the time of injury to determine that perforation of the posterior scleral wall has occurred. With care in determining the fixed points from which measurements are made, the X-ray operator should be able in every case to indicate whether a body has penetrated partly or completely through an eyeball that corresponds in its dimensions with the average adult globe of 24mm. in its antero-posterior diameter, which is the size employed in the diagrammatic charts used in localization. Any variation in the size of the eyeball under examination will, however, affect the position of the metal in reference to the posterior scleral wall as indicated on the chart, although there is always a possibility of error in localization from carelessness in measuring the distance separating the indicator and the centre of the cornea. High degrees of refractive error must influence the size of the eyeball, as has been pointed out by Hansell.[1] Moreover, Stilling,[2] from studies of the size of normal eyes of adults, shows that considerable variation is present irrespective of refraction. From a large number of eyes examined he found that the longitudinal diameter varied from 20 to 25mm., the transverse diameter from 20 to 26mm., and the vertical from 20 to 24mm. In three eyes, one of which was myopic (4 D.), one hyperopic, and a third emmetropic, the length of

[1] Trans. College of Physicians of Phila., Jan. 1906.
[2] Zeitsch. f. Augen.. No. XIV. page 23.

each was the same, 24.5mm., and the vertical and transverse diameters were nearly equal.

The accuracy of localization is shown in Cases 3 and 7, the extent of the perforation of the metal through the posterior sclera, as indicated on the diagrammatic charts, corresponding to the measurements made after the eyeballs were removed.

The possibility of error is seen in case 14. The piece of steel, which was of small size, was localized at the posterior portion of the eyeball, imbedded in the choroid, whereas the metal upon enucleation of the eye was found to have passed into the orbit and rested close to the sclera adjacent to the point of localization.

An instance of error in localization due to the size of the eyeball is reported by Marple[1]. The foreign body was located by Dixon just outside of the sclera, but proved to be inside the eyeball. Subsequent study of the patient, who was a man 6 ft. 2 in. in height showed an eyeball 26 mm. in diameter. A knowledge of this fact at the time of localization would have placed the body inside the eyeball instead of outside the sclera in the orbit.

Foreign bodies that lodge in the orbit usually cause no ocular symptoms. Disturbance is more likely to arise from bodies that are situated close to the posterior scleral wall in the region of the ciliary nerves. The importance, however, of keeping under observation for a considerable period all cases of foreign bodies lodged in the orbit back of the eyeball is shown by the history of case 19. The acute inflammation following the injury subsided, but returned after a period of three months, and was associated with irido-cyclitis that compelled the removal of the eyeball. Whether the recurrence of the inflammation was due to the primary injury to the internal structures of the eye, or was influenced by the band of tissue connecting the eyeball with the fibrous mass surrounding the metal, is a matter of conjecture, but the possible shrinkage of this tissue-mass and the pull it exerted upon the orbital nerves with each rotation of the globe must have had an important effect in keeping up a continued irritation to the entire ocular structures. Some years ago I saw

[1] Section on Ophthalmology, A. M. A. 1906, p. 421.

DR. LAMBERT'S CASE OF DOUBLE PERFORATION OF EYEBALL.

DR. LAMBERT'S CASE OF DOUBLE PERFORATION OF EYEBALL.

Risley
onths
nuous
passed
it.

BALL
VITH

e sub-
which
rmary.
him-
wood
great
one as

to the
izontal
pupil
nation
an air
In the
by a
rhagic
by Dr.
above

used.
xon at

the infirmary, the presence of a foreign body demonstrated and its location determined. (The accompanying chart shows the position of the same.) It was 21mm. back of the center of the cornea, 2mm. below the horizontal plane and 12mm. to the temporal side of the vertical plane.

The patient was placed before a large magnet, the eyeball being rotated inward as far as possible, the point of the magnet being directed a little behind and below the insertion of the external rectus muscle. There was marked bulging.

An incision was then made through the conjunctiva and Tenons capsule. The wound was opened up by a pair of blunt-pointed scissors and the magnet again applied. After one or two attempts the foreign body was withdrawn. This proved to be a very thin chip of steel about 3mm. long by 2 mm. wide. The conjunctiva was then sutured and a bandage applied. The patient made an uninterrupted recovery, the vision remaining at 20/20.

I saw him about three months after he had left the hospital and the eye was perfectly quiet and the vision normal. He has since gone to South America, and I am not able to state his present condition, but have heard through his wife that his eye had given him no further trouble.

A CASE OF FOREIGN BODY IN THE FUNDUS — EXTRACTION BY MAGNET — COMPLETE POST-OPERATIVE ANIRIDIA — PRESERVATION OF GOOD VISION — EXHIBITION OF PATIENT.

BY HIRAM WOODS, M.D.

BALTIMORE, MD.

The patient I have here presents several points of interest in connection with removal of foreign bodies from the eye. He is 32 years old, by occupation a skilled workman in a shipbuilding company. On March 18, 1904, while at work in Richmond, Va.,

the left eye was struck by a flying bit of steel, and has since been useless. There is no external wound, the anterior chamber is deep, iris shelving and attached along its upper border to an opaque capsule. Apparently the lens has been absorbed. There is good l.p. While at work in Baltimore on March 5th last, about 10 a. m., he met with an accident similar to that of three years ago. I saw him four hours later at the Presbyterian Eye and Ear Hospital. There was a small depressed wound at the lower end of the vertical meridian of the cornea, extending about 1mm. into the sclera. A little blood was at the bottom of the anterior chamber. The pupil was normal in size and reacted to the light. V. was 10/200. T-1, slight clouding of the lens, general external hyperaemia, chiefly circumcorneal, haziness in the vitreous, old pigment deposits in the fundus, below and to the nasal side of the papilla, and a small glistening body in the lower and outer quadrant, with tenderness on touch, were noted. The pupil dilated regularly and completely. Through the hazy vitreous a glistening bit of metal was seen, firmly imbedded in the retino-choroidal tissue, external to the vertical, and below the horizontal diameter. Immediate operation was advised. After the usual preparation, the cocainized eye was exposed to the Haab magnet. Reaction was immediate. The ant. segment of the globe bulged forward, the iris came against the corneo-scleral wound, and the patient experienced intense pain, which he bore without flinching. Three attempts at removal by the Haab magnet produced such reaction, but the steel would not come through the wound. Twice the full current was turned on and off suddenly. The patient was seated before the magnet. He nearly fainted from pain, and was transferred to the operating table. I believed it would be necessary to make a small iridectomy at the site of the injury in order to effect a removal. Inspection, however, showed the iris covering the foreign body in the wound, and I decided to make another trial with a smaller magnet we have, and which I think was devised by my friend Dr. Lippincott of Pittsburg. The tip of this magnet was applied and immediately the steel particle attached itself, dragging out what was thought to be part of the iris. The

anterior chamber filled with blood. The protruding iris was excised. The triangular bit of steel measured between two and three mm. in its longest, and a little over 1mm. in its shortest diameter, while its thickness was inappreciable. I had little hope of saving the eye when the man was carried to bed. After-treatment consisted of rest in bed, atropia and internal administration of K I. After a week the blood was absorbed. Inspection showed complete aniridia. The indentations of the ciliary processes are seen around the entire lens periphery. The site of the foreign body in the fundus is occupied by an exudate. Barring the old pigment deposit, already alluded to, the rest of the fundus is in fairly good condition. There are faint lens and ant. vitreous opacities. Central vision is 20/60 with the naked eye, 20/30 (—) with concave 1 D. Jaeg. 1 is read from 10 to 20 cm. with naked eye, 17 to 20 cm. through — 1. There is a negative scotoma in the upper temporal field, caused, I presume, by the old pigment spot. Careful examination does not disclose scotoma corresponding to the site of injury. In reviewing the case one is struck with the excellent vision remaining after so great accidental and operative injury. The permanency of this vision is a matter of solicitude. So far — two months after the operation — there is no evidence of deterioration. There is a cystoid cicatrix at the point of corneal injury. Barring possible infection through this, cataract seems his main peril. The other eye promises good results from operation.

This production of aniridia is the first serious result I have had in a limited experience with magnet extractions. An iridectomy would have been better. The failure of the Haab magnet to extract, is noteworthy.

DISCUSSION OF THE PRECEDING THREE PAPERS.

DR. THEOBALD. I have met with two of these cases. In one, a lad about 15 years of age, a very small shot struck the eye at the corneal limbus, went through the margin of the iris, and passed into the deeper parts of the eye. It was impossible to see anything with the ophthalmoscope, because of extensive hemorrhage

into the vitreous chamber. The feature that was most striking was that the eye quieted down so quickly. I had, at first, anticipated enucleation. A skiagraph made by Dr. Baetjer afforded an explanation — the shot had passed through the sclera and lodged in the orbit behind. Several months have elapsed since the receipt of the injury, and the other eye remains quiet, and the vitreous is gradually clearing.

The other case occurred some months ago and the details are not so clear in my mind. A foreign body, a small fragment of a metallic cartridge, entered the vitreous chamber at the corneal limbus, just missing the lens. The eye behaved remarkably well, and the inflammation was brought under control. An X-ray picture showed that the foreign body was lodged either just outside the sclera or in the sclera itself.

Dr. Gruening. In regard to Dr. Sweet's paper, there is one symptom that was not mentioned, that is, exophthalmos. When there is a double perforation, there is generally, twenty-four hours after the injury, an exophthalmos. I have seen this in three cases and it does not occur after simple penetration of the eyeball.

Dr. Johnson. It is certainly very important that these foreign bodies should be located before we proceed to an operation for removal by making any form of incision into the eyeball. There is another symptom that has occurred in one or two cases I have seen of penetration of the anterior and posterior walls and that is subconjunctival hemorrhage. I have seen a through and through shot wound, similar to Dr. Theobald's case, in which the vision remained so perfect that after two or three years the patient could not tell which eye was the injured one.

The result of removal of the steel from an eye is not to be decided until a considerable period of time has elapsed, because in some cases there is that form of purulent irido-cyclitis which comes on slowly and results in destruction of the eyeball.

I think the localization of the foreign body is of sufficient importance to make it desirable that a radiograph should be taken in each case.

Dr. Risley. I have been very much interested in Dr. Sweet's analysis of these cases and also in one feature of Dr. Woods' paper. I recall the history of one case, of which Dr. Sweet has just reminded me, in which there was marked sympathetic irritation in the other eye. Without waiting for a radiograph, I

advised enucleation. When the ball was removed and opened, to my surprise, the vitreous was in a healthy state and no foreign body could be found. I felt that I had done injustice to my patient by enucleating the eye without further investigation. One of my assistants, however, in looking over the specimen later found the fragment of metal imbedded among the trunks of the ciliary nerves back of the eyeball, close to the optic nerve. Its exact location outside the ball would doubtless have been pointed out by Dr. Sweet had the patient been sent for localization. Dr. Woods' case, I think, emphasizes one of the dangers inseparable from the use of the magnet when the foreign body is entangled in the iris. In these cases it is dangerous especially when the fragment of metal is relatively large. Instead of using the magnet it is safer to resort to our older method of performing an iridectomy which shall include that portion of the iris which contains the foreign body.

DR. MAXSON. The very point just referred to was of great value to me a few years ago. The foreign body was located and repeatedly brought into the anterior chamber by the magnet. I then made my incision with the iridectomy knife and was about to apply the magnet but, remembering this point, used the iridectomy forceps to successfully remove the object.

There is danger in using the magnet to remove steel from the ant. chamber after an incision has been made in the cornea if the steel is caught in the folds of the iris. It is safer to use the iris forceps.

INTERESTING CASES OF EYE STRAIN.

BY DR. J. A. SPALDING,

PORTLAND, ME.

This paper owes its origin to an optician's mistake. For though like many other oculists, I have seen many cases in which nervous symptoms had been relieved by proper fitting of lenses, it never happened to me to hear of such unusual symptoms as were alleged to be due to lenses improperly set.

Mrs. A. consulted me for headaches and constantly impaired health. She was wearing — 2.25 D. C., Ax. 180° O. U. My examination revealed — 2.25 D. C., Ax. 170° O. D.— 2.00 D. C. Ax. 180° O. S. together with hyperphoria O. D. The patient was sent to an optician with a proper formula, to be decentred for the hyperphoria. Although I expected her to report with the lenses for verification, she never consulted me again. On making inquiries she wrote me that being in a hurry she had worn the lenses directly from the optician's. She had walked but a short distance when she felt dizzy, saw double, fainted, and had to be put into a carriage and taken home. I then examined the optician's books, and found that the hyperphoria had been doubled, by improper decentration of the lenses. Allowing for the patient's exaggeration, this case taught me, once more, the absolute necessity for verification of lenses after grinding and setting by the optician. It also taught me the very important lesson of the wonders of eye strain, namely, that such a condition, whether produced by imperfect vision or imperfect lenses, may produce extraordinary symptoms, and that the study of this condition demands great thought, attention and time.

This unfortunate accident happened more than two years ago. Since then I have met with numerous interesting cases of eye strain, worthy of record.

Mrs. B. has been "light-headed" for years, to use her own words. She is always tired. Although previously fitted to lenses and somewhat relieved she does not get a perfect cure. She is never well. She has a sensation of not reaching the floor or pavement when walking. It seems to her as if she were perpetually walking on a very thick rug, laid on the floor or pavement. She has no headache on reading or on using her eyes for near work, but cannot use them long. Without lenses her sensations are very pronounced. With lenses they are less marked. Changing her eyeglass frames into spectacle frames, was of no use. She was wearing + 2.00 D. S. O. U. The addition of + 0.50 D. C. Ax. 90 O. S. improved her condition slightly. She happened to remark at one visit, that when walking she often felt as

DR. LAMBERT'S CASE OF DOUBLE PERFORATION OF EYEBALL.

consciousness lasted, of violent pain in both temples and forehead. No post-mortem examination was made.

After writing the case this far, I met relatives of the patient, from whom I learned that for a long time under suspicion of specific disease the patient was treated abundantly with iodides and mercurials, and later with full doses of bromides. During some convulsions, she would perceive a tingling sensation in the left ring finger. This would creep up the arm with sensation of numbness, then headache, and then she would become unconscious. What might have drawn attention sooner to the eye strain, was that no one paid any attention to the fact that the patient often insisted that her convulsions generally occurred after use of the eyes for near work.

The case is perfect as regards absolute cessation of convulsions after the constant use of proper lenses. It is imperfect in that a post-mortem examination was not obtained, but only because the attending physician could not do it personally. The family were anxious to know the cause of death, but a skilled examiner could not be reached in season.

In another paper on eye strain, I have mentioned the effect of mimicry in children, because in many cases in which eye strain seems to be the cause of some train of symptoms, we must be on our guard to exclude this habit in children, and occasionally in women. Mimicry must be excluded if we wish to have our diagnosis respected. With this in mind, mention may next be made of two cases of prolonged and repeated nausea in two children, yet relieved by proper lenses. Actually, if it had not been for careful observation, by the parents, of these children, the eye strain origin might have been overlooked. In both instances, namely, it was noticed that when the child was obliged to study after a hearty meal, the nausea occurred regularly, but that it was generally absent when the eyes were not used after meals.

As these nearly similar cases occurred in different towns, there could be no question of mimicry. For that reason they may be added to the long list of eye strain cases. One of them differed from the other in that in one the astigmatism was with

looked worn out, aged and exhausted. His former healthy color disappeared and his complexion was chalky.

A skilled general practitioner though treating the patient for three months was unable to be of the least assistance. A neurologist of great experience, called in consultation, could diagnosticate nothing short of a cortical cerebral tumor. It was even seriously discussed whether or not an osteoplastic resection of the skull would be necessary in order to relieve the tension. With this gloomy prospect before him, and a lightning flash scotoma suddenly developing and persisting most of the time, the patient became greatly discouraged.

Suddenly he developed new symptoms, the left foot becoming painful and rigid, followed by a spasm in the calf of the leg, pain extending as far as the hip joint, and walking becoming for a moment or more impossible. One day he had a spasm of this sort, and if he had not clutched the fence and held to it for several minutes he would have been groveling on the pavement. Occasionally he would suffer from numbness in the left little finger, and then in the two adjoining fingers. Being asked to give an opinion, I found the patient so nervous that proper examination was unsatisfactory. I could not help believing, however, that there was now present manifest hyperphoria. In the midst of my perplexity, for owing to various personal reasons into which it is impossible to enter, I did not care to carry on the case, I wrote to the second oculist, suggested hyperphoria, and offered a consultation. He was very glad to meet me more than half way, because having had the patient so many years under his care he was more than glad to go farther. Aided by my suggestion of hyperphoria as the cause of these troubles, together with sub-normal accommodation, three per cent. homatropine was instilled into the eyes. In a few hours the entire train of symptoms ceased, and on giving this formula, the patient was cured and has been cured for two years and six months at the time of writing: O. D. — 75 D. C., Ax. 25° ⊂ ¼° Prism Base down, O. S. — 0.37 D. S., ⊂ — 0.75 D. C., Ax. 125°. A wafer + 1 D. S. was added to O. U. for sub-normal accommodation.

This case is as plain a proof of what lenses will do for eye strain as has ever been offered for publication. It is furthermore proof positive that errors of refraction, combined with imbalance, especially upward or downward in either eye, will positively produce alarming symptoms incurable except by skilled oculists after examination with homatropine or other mydriatics. Furthermore this case adds another proof of the influence of sub-normal accommodation upon nervous manifestations, the list of which has in this paper only been merely hinted at for sake of brevity. Here, in a word, was a man on his way to the grave, in the opinion of his half a dozen medical men, yet cured at once by lenses.

Members of this association do not need to be treated as elementary students, but the experience of every member in the minute intricacies of refraction is worth recording publicly, at every meeting. From such point of view let me emphasize a few facts.

First of all I will call your attention to the important fact that these cases were all verified by various members of this association. They are not opticians' patients at all.

I believe that in important cases verification of diagnosis by other skilled men is of the greatest use because their opinion teaches us points which we may have overlooked. Consultations are often desirable rather than that patients should fall into undesirable hands. Talking over a case is often better than to write for an opinion. We should try to verify our own tests in every possible way. It is of no use for instance to decry the ophthalmometer, or to refract every eye with the ophthalmoscope alone, or to rely wholly on skiascopy, or to try to get exact diagnosis without mydriasis, or to use the Maddox rod alone and give the phorometer up as of no avail. We should utilize every possible test and give more time to patients, and above all be frank and tell them that we cannot decide every case in one visit.

I have observed in some patients that the grinding upon the edges of cylindrical lenses, as done for our sets of trial lenses, acts suggestively, so that we get the wrong lenses owing perhaps to shadows reflected by the blurry portion or by that portion cutting off the light, so that when we utilize a plain cylinder we get

a different effect from that produced before by the ground-edged cylinder.

We fail in many instances to utilize infinitesimally weak cylinders. I recall, for instance, a young man who had been troubled for years with an obstinate blepharitis, treated in vain by half a dozen men, who, although examining the refraction, were not willing to order a weak cylinder. But after I had insisted on the use of O. D. + 0.12 Ax., 90 ⊂ O. S. + 0.12 D. C. Ax., 180°, the blepharitis disappeared for good.

Minute differences in the setting of the axes of cylinders often is of the greatest service. A patient using + 0.50 D. C. 90 had constant headaches still, but on changing the axis of O. S. to Ax. 35°, a cure was effected.

We should be most careful not to jump at the conclusion that because the axis of one eye stands at 90°, the other must of course stand just the same.

Patients, furthermore, should be warned that the axis of astigmatism may change at any minute, and that they should come for renewals whenever a blurry sensation is perceived.

It is amazing that oculists do not inform the profession, in answer to the advertised lies of the uneducated, that poisonous eye drops are no longer used to paralyze the eyes and blur the sight for a week.

An important obstacle in our advance is lack of verification in certain cases of eye strain, for instance. One member reports wonderful symptoms relieved by lenses, yet others decry them and deny them. We ought then, where possible, to offer our cases for examination and verification.

A member sees spontaneous recovery from detachment of the retina, yet because no other member saw it, the case is doubted.

Emphasis in this paper should be laid on the great benefits of decentration of lenses in hyperphoria. Many cases can be cured by this process, which according to other observers must be tenotomized. The operation of tenotomy and advancement is abused enormously in our days. I have just seen a patient with loss of sight in an eye from retinal hemorrhage, with resulting nervous

symptoms because the eye so affected was her best eye always, the other being injured in childhood. Without hyperphoria, and without lateral deviation to amount to much, she had two tenotomies on the hemorrhagic eye, and one on the other; the nervous symptoms continuing unchanged, of course. In another patient with choroidal effusions at the yellow spot and in the periphery of the fundus, tenotomy was done, but of course the choroidal patches gradually enlarged and coalesced, and no benefit ensued. A tenotomy should never be done until the possibilities of lenses have been exhausted. To tenotomize or advance and afterward to refer the improvement to lenses, is indescribably insulting to common sense.

Cure of many cases of migraine lies in the proper fitting of lenses under the influence of a mydriatic. After that, subnormal accommodation and the imbalances have to be studied. Medication in this class of diseases gives temporary relief. Yet in a recent medical journal a physician asserted that he had cured many of his cases of migraine, by using hundreds of pounds of certain powders. The truth was that he had relieved the patient temporarily. A truer cure lies in properly fitted lenses, for constant wear, combined with proper relief for the weakened accommodation.

DISCUSSION.

DR. LAMBERT. Dr. Spalding's first case in which he mentions a mistake of the optician causing considerable trouble, recalls an experience in my own practice. I was consulted by a lady who had been the rounds of the city of New York, and although the glass she was wearing corrected her error of refraction, she was not relieved. She was slightly hypermetropic in one eye and myopic in the other but I discovered two degrees of hyperphoria which I proceeded to correct. The results were magical. She went independently to the optician some time later to have new glasses made and after getting them started off on a trip but had to return, and came to my office with all her old symptoms aggravated. I examined the glasses and found that instead of the base of the prism being up it had been turned

down, thus increasing instead of correcting the existing hyperphoria. The glasses were made right and she had no further trouble.

DR. ALLYN. There are just two points I would like to set forth at this moment. I would say first, always use belladonna, and second, have the glasses sent to you for examination before the patient begins to use them. It will save you a lot of trouble.

A CASE OF UNILATERAL NYSTAGMUS BENEFITED BY TREATMENT.

BY F. H. VERHOEFF, A.M., M.D.,
BOSTON.

The following case of unilateral vertical nystagmus is reported chiefly to call attention to a method of treatment which gave a satisfactory result and which it is hoped may prove of equal value in similarly selected cases. It has also seemed well to add this to the list of reported cases that it may contribute, perhaps, to the solution of the difficult problems relating to the etiology of nystagmus.

Mary S—, aged 18, first seen Nov. 1, 1903. Mother and father not related and have normal eyes. Two sisters have normal eyes. One brother, aged 14, has had marked convergent strabismus since five years of age, but no nystagmus. Patient has always been healthy and has had no severe illnesses. She is above the average in intelligence and made good progress at school. She states that her right eye was first noticed to turn in when she was seven years old, and that the nystagmus was not noticed until she was fifteen.

Examination: Media and fundi of both eyes, normal. Pupillary reactions normal, no hippus. Refraction under homatropine, R. + 1.50s + 1.25 cyl. ax. 60° = $\frac{20}{40}$. L. + 2.25s + .37 cyl. ax. 120° = $\frac{20}{15}$. The right eye shows a convergent strabismus of 52^{Δ} measured by the objective cover test. Subjective tests show

paradoxical diplopia. Thus, a 20^{Δ} prism base out, which as shown by the cover test does not correct the squint, produces crossed diplopia. The diplopia tests (vertical prism or Maddox rod), indicate approximately 10^{Δ} of esotropia, the patient being unable to locate accurately the relative positions of the two images. With both eyes uncovered the right eye shows constant vertical nystagmus, with or without correction of refractive error. When the left eye is covered so that the right is compelled to fix, the nystagmus immediately ceases. The left eye under cover remains free from nystagmus. The nystagmus shows a practically constant frequency of about 200 oscillations per minute, the amplitude of each being about 3/4 mm. On forced movements of the eyes in any direction except upward, the nystagmus ceases. It also ceases when an object is brought very close to the eyes, that is, during forced accommodation, whether the right eye is covered or not. When the patient allows the eyelids of both eyes gently to close, both upper lids quiver as if involved in the nystagmus, the left eyelid much more markedly than the right. Each eye shows normal color perception, and no foveal scotoma can be made out in either eye. Dr. W. N. Bullard, who kindly made a careful neurological examination, reports that the patient shows no evidences of organic disease. Full correction, less +.75s, ordered for constant use.

Nov. 3, 1903. Free tenotomy of right internal rectus. Four weeks later, when the esotropia had decreased to 30^{Δ}, advancement of right external rectus performed. After one week the esotropia was found to be only 9^{Δ}. Nystagmus unchanged.

Dec. 18, 1903, three weeks after the advancement. Occasionally has spontaneous diplopia, during which the left image "jumps." Nystagmus unchanged. Cover test shows esotropia of only 5^{Δ}. Maddox rod shows crossed diplopia. With 20^{Δ} prism base in and Maddox rod, the patient is unable to say which side of light the streak is on, although the two appear some distance apart. With red glass before left eye two images are seen. When patient looks at the red image the white image oscillates vertically. When she fixes the white image the red

remains motionless. In order to induce the right eye to fix, the visual acuity of the left eye was now reduced by adding + 2 D to its spherical correction.

Jan. 7, 1904, three weeks later, the cover test shows parallelism of visual axes. Patient still fixes with left eye most of the time in spite of the blurring glass, and the nystagmus still persists. The left glass was now smeared with vaseline, thus practically excluding the left eye from vision. The right eye therefore being compelled to fix, the nystagmus ceases.

After keeping the left glass smeared with vaseline for five weeks it is found that this additional procedure is no longer necessary, and that the blurring glass before the left eye is alone sufficient to insure fixation by the right eye and to cause the nystagmus to cease. Since, however, the visual acuity of the left eye is enhanced rather than decreased for near vision, this eye is used for reading, during which the nystagmus reappears.

Nov. 17, 1905, over two years after the treatment was begun, the condition last noted remains essentially unchanged. The visual axes are still parallel. The visual acuity of the right eye has slightly improved, to $\frac{20}{30}$, Nystagmus is absent in distant vision with the glasses, and present in near vision or when the right eye is covered.

Although in this case the patient stated that the nystagmus had been present only since she was 15 years of age, it is not unlikely that it had really existed, perhaps in a less pronounced form, long before that time but had been unnoticed. At any rate, in view of the fact that a thorough neurological examination gave no evidence of organic disease, it seems clear that this belongs to the so-called congenital nystagmus, the cause of which is believed to be congenital although the nystagmus may not manifest itself until some time after birth. This classification at least serves to distinguish such cases from the acquired form due to organic brain disease and also from occupational nystagmus.

The satisfactory result of the treatment was no doubt dependent upon four factors, namely, the unilateral character of

the nystagmus, the good visual acuity of the affected eye, the absence of the function of binocular single vision, and most important of all, the cessation of the nystagmus during fixation with the affected eye. The treatment consisted in taking advantage of the latter fact by inducing the nystagmic eye to fix in distant vision. This was accomplished by increasing the power of the spherical glass for the normal eye sufficiently to reduce its visual acuity below that of the nystagmic eye. To accustom the patient to use the nystagmic eye in this way, however, it was necessary at first to reduce still further the visual acuity of the normal eye by smearing its glass with vaseline. After the use of the vaseline was discontinued the patient always used the nystagmic eye for distant vision and thus was free from nystagmus except in near vision when the normal eye was used.

In this connection I should like to call attention also to the advantage to be derived from making use of this procedure in any case of strabismus or anisometropia in which there is good visual acuity in each eye but in which the function of binocular single vision is absent. By compelling the patient in this way to use one eye for distant vision and the other for near vision, reading is made less of an effort to him owing to the assistance of the strong convex glass, and moreover, when presbyopia sets in one pair of glasses still suffices for both near and distant vision. Such a patient thus is given at least one decided advantage over an individual with normal eyes, for in the case of the latter it is generally speaking not feasible to assist the accommodation before the presbyopic age is reached if only on account of the disturbance that would be produced in the relation between accommodation and convergence. Occasionally in anisometropia the patient has already unconsciously learned to use his eyes in this way. Here especially it seems to me that it is a mistake to attempt to correct the anisometropia, but that the glasses should be so adjusted as to confirm the patient in his habit.

In regard to the etiology of unilateral nystagmus,* this case presented one feature that seems to be of considerable signifi-

* For a recent review of the literature on nystagmus, see paper by Alexander Duane, the New York State Journal of Medicine, July, 1905.

cance, namely, the nystagmus if such it may be called, that manifested itself in both upper lids when the latter were allowed to close. It will be seen that this lends strong support to the view upheld by several observers that unilateral nystagmus does not differ essentially in origin from the bilateral form, and that in fact a careful examination will in many cases show a slight nystagmus in the apparently normal eye. In this present case, however, repeated examinations failed to show the slightest nystagmus in the left eye, so that this case serves in addition to demonstrate that even when the cause of the nystagmus is acting on both eyes, on one of them its effect may be perfectly inhibited. That nystagmus was completely absent from the left eye in this case was also indicated by the subjective tests. Thus when diplopia was produced with the right eye fixing, both images remained still, whereas with the left eye fixing, the image pertaining to the right eye continually "jumped."

Assuming then, that the cause of nystagmus acts upon both eyes, whether or not the nystagmus itself is unilateral, the present case, and others similar to it, may possibly be explained as follows: There is first a cortical lesion, probably congenital in origin, that tends to produce nystagmus in both eyes. This is associated with, although independent of, an absence of the function of binocular single vision which leads to the development of squint. Owing to one eye alone now being used for fixation its tendency toward nystagmus is fully compensated for. On the other hand, the squinting eye never being used for fixation, its tendency toward nystagmus is allowed to become manifest.

THE POSITION OF THE OPHTHALMOLOGIST IN THE TREATMENT OF DISEASES OF THE ACCESSORY SINUSES OF THE NOSE.

BY DR. WM. CAMPBELL POSEY,
PHILADELPHIA, PA.

In December of last year the writer was consulted by a lady 61 years of age, on account of the prominence and some dimness of vision of her left eye. She had been refracted by him for compound hypermetropic astigmatism two years previously, and at that time the aspect of the eyes was normal, and nothing pathological was noted. As shown by the photograph which was taken by Dr. Swindells at the second consultation, the left eye was considerably proptosed; being pushed forwards and somewhat downwards. The protrusion was constant and was not affected by pressure, and no pulsation was conveyed to the examining finger. There was no bruit. Both the upper and lower lids were somewhat œdematous, and the entire left temporal-frontal region was likewise boggy and swollen, the skin over this region being stretched and the veins prominent and distended; there were, however, no signs of acute inflammation. Upon palpation, a firm smooth mass was detected directly under the orbital rim, with an indentation in the bone in this position.

With + S. 0.75 D. ⊂ + C. 0.25 D. ax 100° vision was brought to 5/6 in the left eye, though full visual acuity had been attained at the first examination with + S. 0.50 D. ⊂ + C. 1. D. ax. 100°. The media were clear, but the nerve was pale and the retinal vessels were full, particularly the veins and more especially the superior temporal. Venous pulsation was pronounced. This was in marked contrast to the ophthalmoscopic findings in the right eye, where the veins were free from pulsation, and both arteries and veins were of normal size. The nerve, too, presented its normal tint. There was no choking of the lymphatics of either eye. The field for form and color was normal

in the right eye but there was a loss of a sector of considerable size in the upper temporal field of the left.

The ocular symptoms were thought to be due to a distension of the left frontal cells and she was sent accordingly to Dr. F. R. Packard for a rhinological examination. This, however, beyond a very marked swelling of the bullae ethmoidalis, was negative. Transillumination also showed merely a faint antral shadow on the left side. In view of the possibility of specific infection, although there was no history pointing to such a condition, the patient was placed on ascending doses of potassium iodide and kept under close observation, as sarcoma of the orbit could not be excluded. After repeated nasal examinations, necrosed bone was finally found in the anterior wall of the left sphenoidal sinus, a large part of which was removed. Following this, cauterization of all the sinuses was apparently successfully performed, the openings of all appearing patulous.

After a month of expectant treatment, radical operative measures seemed indicated as the outer orbital ridge had now broken down, and crepitation could be elicited under the skin; vision, too, had become more compromised, indicating that the optic nerve was suffering from pressure. With the aid and counsel, therefore, of Drs. Wm. Zentmayer and Francis R. Packard, a curvilinear incision was made over the left eye-brow, laying bare the tissues immediately below the supraorbital ridge. A mucocele at once presented, which was tapped, giving exit to a large quantity of a clear gelatinous fluid. The supraorbital ridge was found to be much disintegrated and the index finger could be introduced into the frontal cells without difficulty. These were enormously distended, it being possible to pass the finger directly across the root of the nose, the septum having been displaced by the distension of the cells. As a dense thickened membrane appeared to line the cells and necrosis was nowhere apparent, drainage into the nose seemed unnecessary, and after the cells were thoroughly emptied of their contents, a drainage tube was inserted at the point of incision and the wound closed.

For the first 24 hours the patient did well, there being but

Mucocele of the left frontal sinus.

little rise in temperature and no subjective sensations. At the end of this time, however, uræmic symptoms developed, which were thought to have been engendered by the ether, as the urine which had been normal before the operation, now contained albumen and blood. The patient was bled, sweated and transfused, and at the end of 12 hours came out of the coma, and for another 24 hours seemed to be doing well, when suddenly the uræmic condition returned, and despite all measures, death ensued from uræmia. No autopsy was performed, but the wound appeared healthy at all times and there was no evidence of infection or cerebral irritation from that source.

This history has been cited not because of the rarity of the case, or of its clinical interest, but because it illustrates a phase in medicine of which, in the opinion of the writer, there is an increasing need of adjustment, namely, the relationship which ophthalmologists and rhinologists bear to one another in the treatment of disease of the accessory sinuses of the nose, and raises the question, upon which of the two does the duty of operating in cases of this nature devolve?

The patient herself chose an ophthalmologist, as the swelling for which she sought relief was manifestly connected with the orbit. He, believing the lesion to be dependent upon a nasal cause, referred her to a rhinologist, for diagnosis and possible treatment, only to have the patient returned with a negative report. The ophthalmologist, then, with the probability of sinusitis excluded, made ready for the treatment of an orbital condition and a Krönlein procedure was thought of, though this assumption was dispelled and the proof of his first diagnosis confirmed by the incision, which placed him in the predicament of an ophthalmologist treating an affection of a sinus.

And there are many similar cases, the most pronounced symptoms of which are ocular, though the underlying condition is nasal. To whom do such cases belong, and within the province of what specialty do they fall?

Manifestly, the proper person to treat them is one who combines both ophthalmology and rhinology in his practice, but as the

number of those who unite these two specialties is yearly becoming less, on account of the impossibility of keeping informed in the knowledge of more than one, as a consequence of increasing research and extent of literature, this association will doubtless not be maintained many years longer.

In earlier years, all cases of sinusitis with orbital symptoms fell to the ophthalmologist. Rhinology had not been developed and practically nothing was known of the accessory cavities; but recently, with increased knowledge in diagnosis and treatment, rhinologists have absorbed the treatment of these cases, and among other procedures have not hesitated to include the orbit in their field of operation, when they were unable to procure satisfactory drainage by intranasal methods. Incisions which lay bare the orbital contents, and dissections which often impair the safety of the eyeball and the optic nerve and seriously threaten vision, are practiced by them, and specialists in this branch who are informed but vaguely of the location of important ocular structures, proceed without hesitation in their operations in this alien territory. It is true, however, that the ophthalmologist is himself wholly responsible for this encroachment, for as a rule he has been entirely negligent in his appreciation of the fact that there are such things as sinuses, and that there are structures upon the other side of the walls of the orbit of which he should be better informed. For beyond the recognition of the fact that nearly all abscesses of the orbit are secondary to sinus infection, until very recently, ophthalmologists were ignorant of many of the symptoms which sinusitis may evoke in their own specialty. The writer has had occasion to allude to the symptomatology of sinusitis at a former time (56th annual session of the A. M. A., July, 1905), and will not dwell further upon this phase of the subject, it being his intention at the present time rather to urge upon ophthalmologists the desirability of a more intimate knowledge of the anatomy and diseases of the sinuses and to insist that when the necessity for orbital incisions and dissections arise in the treatment of affections of these cavities, that they be done by ophthalmologists or at least in their presence and with their counsel. He does not in-

tend by this that the rhinologist should be supplanted in the general treatment of sinusitis, but he is strongly of the opinion that where there are orbital complications or where external incisions must be practiced in the neighborhood of the orbit, the ophthalmologist should hold the knife, or at least superintend the work of the rhinologist. It goes without saying that the ophthalmologist, in his turn, should submit all cases in which he suspects sinus involvement to rhinological examination, and in the event that the condition is reported amenable to intranasal treatment, that a transfer should be at once effected. Should, however, external opening of the sinus be demanded, it is the duty of the ophthalmologist to proceed, though always when feasible with the assistance of a rhinologist. Until the sinus is opened, it is impossible to determine the extent of cells involved, and in the event of extensive disease, the skill and resources of both ophthalmologist and rhinologist will often be taxed to bring the case to a successful issue. The services of both are essential if the patient is to receive the most skillful manipulation and consideration in diagnosis and treatment, and both should work hand in hand. In a case similar to that which has been cited, the ophthalmologist could not have proceeded intelligently without rhinological aid, and with the possibility in view of encountering an orbital neoplasm, the rhinologist would have been rash indeed and manifestedly out of his sphere who would have attempted the operation without the presence of an ophthalmologist.

In order that ophthalmologists should be intelligent operators and consultants in this field, however, it is essential that they should acquaint themselves more fully with what rhinologists have already accomplished, especially regarding their methods of opening sinuses by external incision, and the indications which determine the necessity for this procedure.

The latter phase, especially, has been the subject of much discussion during the recent years and there is still a lack of accord regarding it, especially since it has been proven that in addition to the disfigurement which is occasioned by the scarring of the external operation, a number of fatal cases have been reported

following this method of operative procedure. Those who are interested are referred to the notes of a symposium on diseases of the accessory sinuses at the American Laryngological, Rhinological and Otological Societies held in Boston in 1905 (Annals of Otology, Rhinology and Laryngology, Sept., 1905), and also to the discussion on the diagnosis and treatment of chronic empyæma of the frontal sinus, before the British Medical Association in August, 1899. Papers by C. G. Coakley (Annals of Otology, Rhinology and Laryngology, September, 1905) and C. R. Holmes (Ohio State Medical Journal, February, 1906) are also of value. The consensus of opinion of most rhinologists, however, regarding the necessity for the external operation, is comprised in the following summary, which is quoted from Parker:

Parker, The Nose and Throat and Their Treatment, p. 288: (1) Failure of intranasal methods to establish free drainage into the nose, as shown by persistence of pain and other symptoms; (2) Deterioration of the patient's general health from the continuous discharge; (3) Bulging of the sinus or inflammatory odema over the sinus; (4) An external fistulous opening; (5) Symptoms of cerebral complications.

In addition to these indications, the writer has ventured to insert also a description of the various procedures which are practiced by rhinologists in the external opening of the sinuses, and he would suggest that it might be helpful to operators upon orbital structures if in the future ophthalmological authors should incorporate similar descriptions in their text-books. As recently summarized and described by F. C. Cobb, the external operations for frontal sinus empyæma are as follows:—

1. *Method of Nebinger-Praun.* The incision goes from the nasofrontal suture at the edge of the orbit to a point over the supraorbital notch. The anterior bony wall is chiseled away, then a vertical cut 4 to 6 cm. long is made following the frontal vein. After opening, the contents of the sinus is wiped out and the mucous membrane scraped. The nasofrontal duct is secured by a wick at the base of the wound.

2. *Method of Ogsten-Luc.* An incision at the inner third of the edge of the orbit, which may be lengthened either outwards or towards the root of the nose. The periosteum is pushed upwards and outwards towards the orbit. The opening of the sinus is a little to the outer side of the median line. The nasofrontal duct is curetted, as well as the interior of the sinus and some of the anterior cells of the ethmoid. Through the wide communication with the nose thus made a drainage tube is put in and the outer wound closed. After eight days the bandages are removed. At first drainage tubes were used between sinus and nose, but these were later replaced by strips of iodoform gauze.

3. *Method of Kuhnt.* In this method the whole of the anterior wall of the sinus is removed, with its diseased mucous membrane, as also the upper part of nasofrontal canal. The incision is as follows: A horizontal incision along the supraorbital margin from the eyebrow to the outer third of the edge of the orbit; then a vertical incision from the inner edge of the wound through the soft parts and the periosteum. After lifting the soft parts and the periosteum the whole wall of the sinus is removed with chisel and bone forceps and the edges of the wound are smoothed. All projections into the cavity are thoroughly removed, the mucous membrane is most carefully scraped from the sinus and from the upper part of the duct. The wound is sewed up, leaving only room for a large drainage tube. This method has met with fair success, but causes considerable depression and does not remove the anterior ethmoid cells. When the disease is bilateral the cosmetic result is, of course, better.

4. *Jansen's Method.* Removal of the lower wall of the sinus and resection of the lower border of the anterior wall, curetting the mucous membrane of the sinus and the granulation tissue. This method is not at present used by Jansen, but in 1903 he was doing a boneflap operation of very much the same character as that practiced by Hajek.

5. *Method of Ridell.* Removal of the anterior and lower wall of the sinus. Thorough and satisfactory except for the great deformity.

6. *Killian's Method.* Incision as in Ogsten-Luc, with supplementary incision beginning at root of nose and passing under inner edge of orbit. Incision is not carried through the periosteum of the arch of the eyebrow, but the soft parts are lifted and incision through the periosteum made a little higher up so as to preserve that of the arch. Removal of the whole anterior wall of the sinus with curetting mucous membrane and all inequalities of the bone. Incision then made in the line below orbit as described. Ethmoid cells entered through nasal process of maxillary bone and thoroughly curetted. Upper wall of orbit removed, allowing orbital fat to fill up depression caused by removal of orbital wall. Closure of wound without drainage.

7. *Coakley's Method.* Incision, as in Ogsten-Luc operation. Cavity, thoroughly curetted with the assistance of electric lights placed in sinus. Nasal duct curetted but not widened, the object being to secure its closure; sinus then packed with gauze and repacked until it heals from the bottom.

The advantages and disadvantages of these methods may be summed up in a few words: The Ogsten-Luc has for advantage the slight deformity produced. For disadvantage it has the great probability of recurrence. The same is true of Jansen's method. Kuhnt's, Ridell's and Coakley's methods yield less probability of recurrence, as they destroy the sinus, but they produce greater or less facial deformity, Coakley's probably giving the least of the three. To all of these methods there is one great objection — that the ethmoid cells are not sufficiently considered. Killian's operation seems to combine the advantage of sinus obliteration with the removal of the ethmoid cells; but it is hard to judge as yet of its practical results as far as deformity and danger to the eye are concerned.

As the site of drainage of the antrum is quite distant from the orbit, no reference need be made to that operation here, and the incision and drainage for ethmoidal disease is so familiar to all that mention of its details are unnecessary.

The X-rays have been found to be of decided value in determining the size of the sinuses and their relation to one another,

and should be used in conjunction with transillumination in the diagnosis of all obscure cases.

As dwelt upon in former papers, the writer would condemn the common practice of denying the existence of a sinusitis by the failure of a cursory examination to reveal pus in the nose, for discharge from the sinuses into the nose is the exception rather than the rule, in inflammation of these cavities in which orbital complications tend to develop. It must be remembered, too, that a congestion of the sinus without exudation may originate ocular symptoms. The recent observation of Onodi that the optic nerve and chiasm may become affected from disease in the accessory sinuses of the opposite side, either by extension of the inflammation through congenital defects in the bone (in the wall of the optic canal or accessory sinus, or along the canals from the ethmoidal veins) or through some disturbances in the circulation, such as œdema, hæmorrhage, exudation into the optic nerve sheath, thrombosis, etc., should also be generally recognized.

A very interesting case, which well illustrates the choking of the lymph passage of the retinal vessels in both eyes, but more especially of those upon the side opposite to the nasal lesion, occurred in the writer's practice during the past winter.

D. H., male, 35 years of age, was referred by Dr. Packard 2 years ago, on account of an enophthalmus of the right eye, consecutive to the fracture of the floor of the orbit following a blow while sparring. The enopthalmus was quite pronounced, but beyond the retraction of the globe and some limitation in its excursions, the eye was normal.

About 12 months after the first consultation, the patient came again, upon account of a marked swelling in the lid of the right eye, which had developed suddenly. The palpebral œdema was intense and both lids were somewhat emphysematous. Though vision was normal in both eyes, the ophthalmoscope revealed a marked choking of the lymphatics of the retinal vessels in both eyes, this being especially pronounced in the left eye, where the distension of the lymphatics attained a maximum degree. The retinal arteries were also much diminished in size and the veins

rounded and cord-like. The retina was diffusely hazed. This ophthalmoscopic finding was absent at the first examination and was thought to be dependent upon a stasis in the circulation in the optic nerves, as a consequence of congestion occasioned by an ethmoiditis, which Dr. Packard discovered upon the right side, and which was the probable cause of the swelling of the lids, the sinusitis having been favored by the stoppage of the ducts of the cells, as a consequence of the orbital fracture. Active treatment of the sinusitis caused a rapid diminution in the palpebral condition, and the distension of the lymphatics of the retinal vessels became gradually less pronounced, though white streaks along the side of the vessels are still visible.

The cases of sinus involvement of which perhaps there is the greatest need of a clear understanding by ophthalmologists, are those of mucoceles of the cells. Every ophthalmic surgeon of experience sees a number of such cases yearly, and as the first symptom which attracts the patient's attention is the displacement of the eye-ball, he must be prepared to recognize the condition. Under ordinary circumstances, the diagnosis is easy, the swelling occupying the inner portion of the orbit in the case of the ethmoid cells, and the upper and inner, in involvement of the frontal cells. The projection at first is hard and bony, resembling an exostosis, though later it acquires a tense parchment-like feeling, and when the bone gives way, crepitation and fluctuation may be elicited. As a rule, there is no pain, the history being that of a slow but progressive increase of the swelling, extending over a period of years. It is on account of this slow growth that the eye gradually accustoms itself to the change which its displacement occasions in its relationship with its fellow, so that there is no diplopia, while the optic nerve, by means of its sigmoid flexure, straightens and does not suffer from the stretching to which it is subjected. The nasal examination is negative.

The differentiation of the condition is generally not difficult, for empyæma of the sinuses very rarely occasions distension of the cavity, while tumors are rare, and in the event of their being malignant are more rapid in their course and are generally painful.

Perivasculitis of the retinal vessels with choking of the lymphatics in the left eye of a subject with right sided ethmoiditis.

There is, however, often difficulty in diagnosing mucoceles from syphilitic disease of the orbit, the writer having within the past two years assisted in two operations, which were undertaken for what were supposed to be mucoceles, which proved to be diffuse gummatous infiltration of the orbit. One of these cases occurred in the practice of Dr. Wm. Zentmayer and the other in that of Dr. Frank C. Parker. Both were children, the gumma occurring in one instance in the upper, inner angle of the orbit, in the position where a distension of the floor of the frontal sinus was thought of, while in the other there were hard, bony swellings in the upper and inner portion of both orbits, suggesting a distension of both frontal cells. Thick glairy pus was found in the nose of one case, and other evidences of nasal disease in the other, and the rhinologists in both instances thought it likely that the sinuses were involved and favored operation. The orbital incision discovered densely infiltrated tissue in both cases, without involvement of any of the sinuses. Healing was prompt and later medication with mixed treatment greatly ameliorated the local condition.

The diagnosis is also difficult where a mucocele causes displacement of the eyeball directly forwards, for as a rule the encroachment of the sinus occasioning the proptosis is in the apex of the orbit, and palpation of the orbital tissues is negative. In most cases of this nature, however, the posterior ethmoidal cells are the ones implicated.

As a final point, the writer desires to refer to the fatality of sinusitis, and to report the details of a fatal case, where the submission to treatment when the sinusitis was first detected would doubtless have prevented the spread of the necrotic process and preserved life. D. B., a Russian Jewess, age 20 yrs., came to the Wills Eye Hospital in February, 1903, on account of the prominence of her left eye, which had been getting more pronounced for some time. For three weeks previously she had suffered from violent headache and vomiting, which had been attributed by her physician to a gastric affection. There was no history of traumatism and inflammatory symptoms about the eye had been absent.

Examination showed the left eye to be markedly protruding. The superior rectus muscle was paretic, and the upper lid drooped, covering the upper quarter of the cornea. No tumor was felt in the orbit and the globe could not be reduced by pressure. The pupil was of equal size with its fellow and reacted well to light and accommodation stimuli. The ophthalmoscopic examination of the right eye was normal, but the left nerve was somewhat hyperæmic, and the retinal veins were full and tortuous. Vision and the visual field were normal in both eyes. Although the patient had never had any reason to suppose that she had anything wrong with her nose, a sinusitis was thought of and she was sent to Dr. Walter J. Freeman at the Polyclinic Hospital for a nasal examination. A bulging of the outer wall of the nose was found in the region of the ethmoid cells, and as transillumination showed the antrum to be dark, Dr. Freeman thought that this cavity was also affected. An orbital operation was advised, but was not consented to.

The patient then passed from under the observation of the writer for three years. During this interval, however, she entered another hospital, where sarcoma of the orbit was diagnosed and the patient subjected to the action of the X-rays, in conjunction with the removal of a quantity of dead bone from the orbit.

In October, 1904, while she was still an inmate of this institution, Dr. Freeman saw the patient again, and noted a thick muco-purulent discharge from the left fossa with marked tenderness of the orbit near the ethmoid cells. The exophthalmus had become somewhat more pronounced. An operation was determined upon and the ethmoid cells were accordingly opened, giving access to a very large cavity which extended back to the sphenoid, but from which no pus escaped. The swelling of the orbital tissues following the operation was very great and Dr. Freeman believed that while that part of the dilated cell within the nose was emptying its contents freely into the nose, that the orbit was still affected and that there was retention of pus there. Dr. W. W. Keen was called in consultation and agreed with Dr. Freeman that a sarcomatous condition was very doubtful, as he considered the

case to be one of ethmoidal suppuration. The patient was still under treatment with the X-rays, which were applied two to four times weekly. Further operative measures were advised by Dr. Freeman, but were not deemed desirable by the physicians in the hospital where she was housed.

In February, 1905, the patient was removed to the Polyclinic Hospital and placed under the care of Dr. J. H. Gibbon, at whose request the writer made a second ophthalmological examination, when it was found that the left eye was now proptosed directly forwards to such an extent that all of its movements were much impaired. The upper lid almost covered the pupil, which was 4 mm. in size, and the iris was but slowly responsive to light stimulus. The optic nerve was pale, and both retinal arteries and veins were full and tortuous, particularly the latter. Vision equaled 5/15. The left field was concentrically contracted, both for form and color, and contained an absolute scotoma for form and color at the fixation point. The right eye was normal, save for a slight fullness in the retinal veins. As the patient was delirious and the ocular and nasal examinations demonstrated marked symptoms of pressure within the orbit, after consultation with Dr. Freeman, Dr. Gibbon decided to operate, and with the assistance of Dr. Freeman and the writer, this cavity was incised and drainage effected through the ethmoidal cells into the nose. Viscid mucous was contained in the cells. Dr. Freeman accordingly opened the posterior ethmoidal cells, through the nose, and passed into a roomy cavity, the limit of which he could not determine. Both the anterior and lower walls of the sinus were absent and dead bone could be felt in the roof. At this juncture the patient's condition became so critical that further procedure was deemed undesirable, and the operation was interrupted. Consciousness, however, was never regained, the patient dying the next day with meningeal symptoms.

As no sarcomatous tissue was encountered at the first operation or in any of the other incisions, the assumption is likely that the case was one of inflammation of the sinuses merely, probably originating in a mucocele of the posterior ethmoidal cells, and as

stated at the commencement of the report, had the writer's advice been taken when the diagnosis of the nasal origin of the affection was made clear, and had the cells been properly opened, it is fair to suppose that the fatal termination might have been avoided.

In the observations which Dreyfuss (Krank. d. Gehirns in Folge von Naseneiterungen, June, 1896) made of the post-mortem histories of 50 fatal cases of sinusitis, and which have recently been supplemented by Moritz by 26 additional (Brit. Med. Journal, Jan. 28, 1905), the cerebral involvement in most of these cases was found to be due to a perforation which had resulted either from an inflammatory process or syphilis, rarely from tuberculosis. In many instances, however, no alterations could be detected in the bone itself, though the dura mater was inflamed, the complications being due to infective thrombosis.

Of all the cells, inflammation of the frontal appears to give rise to intracranial lesion the most frequently, the infection usually occurring as a consequence of perforation of its posterior wall with consecutive abscesses in the frontal lobe. The infection, in ethmoiditis, which occurs through the lamina cribrosa, is rapid, and gives rise to general meningitis or frontal abscess. Meningitis and thrombosis of the cavernous sinus may be set up by sphenoiditis, and Dreyfuss in his series of cases noted five instances of cerebral complications following antral disease.

The position of the ophthalmologist in the treatment of sinusitis is threefold,— that of diagnostician, consultant and surgeon. It behooves us, therefore, to acquaint ourselves well with this field, and to develop its ophthalmological phase to a degree commensurate at least with its rhinological.

DISCUSSION.

DR. GRUENING, N. Y. I wish merely to remark that, historically considered, this paper is not correct. The ophthalmologists do pay attention to these conditions and the ophthalmologist must be a rhinologist; that is understood and there can be no doubt about it. Then I wish to say that the labors of Kuhnt and of Berger preceded all of those mentioned here. Luc, Killian and

Coakley are new comers and we must not forget that in this country Kipp and Knapp and Bull and I have done this work for many years.

DR. SHERMAN, Cleveland, O. I am very much pleased with the observation of Dr. Gruening. When I started practice in the city of Cleveland, I found that I had to be a rhinologist as well as an ophthalmologist, as many of the affections of the eye are incident to or associated with disease of the nasal passages or accessory sinuses. I was also interested in an observation of Dr. Spaulding when he said he did not believe that nasal spurs were responsible for some of the affections of the eye that are so troublesome. I wish to state the case of a physician of our city, a graduate of Harvard, who came under the care of a distinguished ophthalmologist in Boston, and notwithstanding his efforts, he failed to get relief from his accommodative asthenopia. After several examinations under mydriatics with failure to relieve his eyes from pain, I suggested the removal of a sharp-pointed posterior septal spur that was in contact with his inferior turbinate. Much to my gratification, he gained immediate and absolute relief after the operation.

In connection with Dr. Gruening's statement in regard to the work of Kuhnt, I beg to remind you that Jonathan Hutchinson asserted that the nasal nerve was the trophic nerve of the eye, more than 25 years ago, which statement has since been confirmed by his son.

DR. POSEY. I am glad to be set right by the speakers regarding the historical part of my paper. I made the statement that this work should be done by those who combined ophthalmology and rhinology in their practice; but at present many of the younger men cannot do that, for various reasons.

ACQUIRED CATARACT IN CHILDHOOD — REPORT OF A CASE.

BY HOWARD F. HANSELL, M.D.,
PHILADELPHIA, PA.

The case described in this paper is an unusual one and unique in my experience. It is that of a boy 3 years old who was brought to me in October, 1906, by his father. The left crystalline lens had every appearance of mature senile cataract and in the cortex of the right lens opacification had commenced. The father stated that he had noticed some months earlier a difference in the blackness of the pupils and that the left one had gradually become white. He had often tested the vision of the left eye and had found it to be gradually growing duller until at the time he consulted me it was reduced to the perception of light. He could assign no cause. The child had been born at the full term of pregnancy; the mother could remember no suggestion that could be held responsible for maternal impression; the child was perfectly formed, of proper weight and nowise different from a perfectly healthy infant. In the first 30 months of life he had met with no accident, had had no serious illness and had never suffered from convulsions. During the teething period no unusual difficulty was experienced. In short, he was, as far as could be learned, a perfectly healthy boy, mentally and physically. At the time of my examination I could detect no fault in his health or development. He was a sturdy, hearty, handsome lad apparently free from all physical ailment excepting that connected with his eyes. The urine was repeatedly examined and found to be normal at each test. No trace of sugar was present at any time. Externally the eyes presented no signs of present or past inflammation and no cicatrices. The pupils reacted well to light, directly and consensually, and to accommodation. All rotations of the ball were well executed and there was no squint. The lens of the

left eye was entirely opaque, milky white, and no striae could be made out nor any line of demarkation between the nucleus and the cortex. Light projection, as tested by two candle flames, was acute in all parts of the field. In the upper nasal quadrant of the right lens a few irregularly curved lines of opacity could be plainly seen by the ophthalmoscope. The opaque striae were directed principally toward the center of the lens and were crossed by others at oblique angles, indicating the involvement of several layers of the lens probably posterior to its vertical meridian. During the next six months the opacities increased in size, density, and in number, the progress of the cataract resembling closely that often observed in the extension of senile cataract. For the reremoval of the cataract three discissions were made and finally the opaque and thickened capsule with some adherent lens matter was extracted. For several days following the last operation there was a small hernia of the vitreous. In a week this had disappeared and with +10D. vision was good. Accurate measurement was impracticable on account of the patient's youth. He could recognize coins and other small objects. The pupil was perfectly black and clear and a distinct view of the normal fundus was obtained. The patient was dismissed to return at such time as the cataract in the right eye had advanced sufficiently for operation. Three weeks later the boy returned on account of partial loss of vision in the operated eye. The anterior layers of the vitreous had become infiltrated or the vitreous itself had partially lost its transparency. This unexpected condition could be referred to two possible causes. Either degeneration of the anterior portion of the vitreous had resulted from the operations and the subsequent hernia, or the infiltration had followed a blow upon the eye received the day before the dullness of vision was noticed. I am inclined to believe the former was responsible. A few days later the child became ill with symptoms of typhoid fever and since then I have not had the opportunity of seeing him.

Ophthalmic literature is exceedingly rich in the contributions it has received on the subject of cataract in childhood but notwithstanding its wealth I have not been able to find the description

of a case analogous to that of my patient. Hess, in his splendid monograph in the 2d Ed. Graefe & Saemisch, speaks of the zonular or perinuclear, the central, the total (a development from the perinuclear or central), the fusiform ("Spindel-star"), the anterior and posterior polar, the pyramidal and finally the inanition or choroidal cataract. In the 1st Ed. of the same work Becker describes in addition to those just mentioned the "white cataract of young persons" or Juvenile "Phakomalacie," which corresponds more closely to my case than any other reference. He says: "From the anatomical point of view the pathologic changes in the lens fibers do not differ from those of senile cataract. One occasionally may see before the appearance of the true opacity a looseness in the connection with each other of the lens layers." He says the sector of the lens to be first involved is not constantly the same. The opacification may begin in the extreme cortex or in many isolated points (C. Punctata) or finally, in the nucleus. Stricker (The Crystalline Lens System) refers to cataract in young persons but fails to mention the development of idiopathic or spontaneous cataract under the age of 30 years. Hunter (Lancet, London, 1905, P. 1419) reports two cases of idiopathic general cataract in children who were first cousins but not members of a cataractous family. The first was a boy, 22 months of age, strong and healthy. In the right eye the lens was totally opaque and pearly white. In the left eye the lens was slightly hazy. The cataract in the right was noticed 6 weeks before examination. The pupils responded normally to light and accommodation. The second case was in a healthy, intelligent girl of 5 years. The right lens was transparent. In the left the opacity began one year before coming under medical examination and had advanced to almost complete maturity. Both pupils were responsive.

The majority of mature cataracts observed in children have their commencement in some one of the congenital forms, usually the zonular. Max Solomon (Monograph, 1872) believes that between the second and fifteenth year nine-tenths come under this class.

A second case of infantile acquired cataract has come under my observation recently. The patient was a girl of 4 years. Both lenses were fully ripe and, according to the statement of the father and mother, the eyes were healthy until about the third year. No history of diabetes, scrofula, convulsions, or the other common causes of cataract could be obtained. This case, however, might well have originated in a congenital opacity that escaped the attention of the parents. The first patient presented the very unusual feature of a complete cataract in one eye and an incipient advancing opacity in the other lens developing from no assignable cause.

A CASE OF PULSATING EXOPHTHALMUS. LIGATION OF THE COMMON CAROTID. DEATH.

EDWIN E. JACK, M.D.,

PATHOLOGICAL REPORT, WITH SPECIMEN.

FREDERICK H. VERHOEFF, M.D.

E. M., Female. Aged 53. Four days before entrance into the hospital she struck her right temple against a door. The injury was so slight that the skin was not broken, no attention was paid to it and she continued her shopping tour in the city. Two days later there was noticed some swelling of the lids and tissue around the eye and an exophthalmus, which was increasing. For two days there had been vomiting at frequent intervals and dizziness, no chills. She suffered much from a terrible noise in the head which came on simultaneously with the other symptoms, and which the patient said was worse than could be made by all the engines in the city. Examination: Face wears an anxious expression and patient is frightened. She sways from side to side in attempting to walk alone; there is moderate prostration. The lids are chemotic and the tissue around is swollen. Decided exophthalmus, pulsation is marked and can readily be seen and felt. A distinct bruit is heard with the stethoscope over lids or

temple, and it, as well as the pulsation, is relieved by pressure on the carotid. Pressure over the eyeball gives some but not so marked relief. The conjunctiva is moderately injected, the cornea clear except for an old scar. Iris is of good color but pupil does not react, the fundus cannot be seen, although there is good red reflex. A pressure bandage was put over the carotid. The following day after a restless night the exophthalmus and swelling around the eye was increased, the conjunctiva was chemotic and serum was forced through it; the cornea began to ulcerate and the patient was in all ways much worse, the pain being intolerable. In the afternoon the right common carotid was tied by Dr. H. H. Germain, with the effect of immediately stopping the pulsation and bruit. The exophthalmus diminished slightly. Difficulty in swallowing followed the operation, but there was no change in pulse or respiration. The next day there was hemiplegia, probably due to ischemia, there was also delirium which persisted with few normal intervals till the end. A general examination made by Dr. W. H. Smith revealed nothing but moderate cardio-vascular disease. There was a gradual improvement in the eye symptoms but the general condition grew worse and the patient died about four weeks after the operation.

Autopsy 17 hours after death. Head only, allowed. Body that of a well nourished female. Rigor mortis. Lividity of dependent parts. No post mortem decomposition. No chemosis of lids or conjunctivæ. No exophthalmos. On right side of neck there is a linear scar of operation (ligation of common carotid).

Dura normal. Pia markedly edematous. Cerebrospinal fluid clear, increased in amount. The right cerebral hemisphere is noticeably larger than the left, evidently due to edema. On section the brain shows no macroscopic lesions.

The right internal carotid artery is decidedly dilated at its exit from the cavernous sinus and has greatly compressed the optic nerve against the upper wall of the optic canal. On section of the nerve at this point it is found to measure 3.5mm. x 6mm. in size, and to show a central oval area measuring 2mm.

x 3mm. The latter is white and opaque and consists of friable material, evidently an area of degeneration produced by pressure of the artery. On the left side the carotid artery is not noticeably dilated, but the optic nerve is slightly compressed, measuring 4.5mm. x 5.5mm. in cross section, and showing several minute white spots towards the artery near the periphery. The circle of Willis shows no appreciable difference in the calibers of its vessels on the right and left sides.

At the site of the right cavernous sinus, the dura is bulged out and pressure on the swelling forces blood out of the internal carotid artery at its exit from the sinus. On lateral cross section through the middle of the cavernous sinus, after hardening in formaline several days, there is found a large sacculated aneurism communicating anteriorly with the carotid artery by an opening 3.25mm. in diameter (Fig. 1). The aneurism is roughly ovoid in shape, measures 8mm. x 10mm., and is free from thrombi. It has greatly compressed, but has not entirely obliterated the cavernous sinus. Its wall in most places is about the thickness of that of the artery proper, but posteriorly over a small area it is extremely thin, friable, and shows a small irregular opening into the cavernous sinus, ½mm. in diameter.

The cavernous sinus on the left side is absent and is replaced by a single small vein in continuity with the ophthalmic vein. The other venous sinuses are normal.

Histological examination.—Fixation in formaline, Zenker's fluid, by Weigert's method for myelin sheaths, and by Marchi's method. Sections made of the internal carotid artery on each side, of each optic nerve at its exit from the canal, and of the right optic nerve at intervals along its entire course. Sections also made of the orbital tissue and of the posterior part of the right eye.

Both carotid arteries show the changes characteristic of advanced nodular arteriosclerosis, namely, proliferation and degeneration of the intima with fragmentation of the elastic tissue, and atrophy of the media.

Sections of the right optic nerve at the exit of the canal, prepared by the Weigert method, show a narrow rim of atrophy all around the periphery, and in the center a large oval area of complete degeneration (Fig. 3), in which the nerve fibers have entirely disappeared and which is markedly infiltrated with fatty granule cells. In sections near the globe, the degenerated area changes its shape and position, becoming more or less sector-like and occupying the lower outer part of the nerve (Fig. 4). The degenerated portion of the nerve is thus confined almost exclusively to the papillo-macular bundle. In places, especially near the globe, Mallory's connective tissue stain shows the degenerated bundle almost entirely replaced by fibrous tissue. Sections stained by Mallory's neuroglia method show a complete absence of neuroglia within the degenerated area, but some neuroglia proliferation at its periphery.

The left optic nerve also shows a narrow rim of peripheral atrophy, but no degeneration of the papillo-macular bundle. There are, however, near the periphery below, four small bundles which show beginning degeneration.

The central retinal vessels show an increase in their adventitia and a certain amount of sub-endothelial proliferation, but not sufficient to obstruct the circulation to any extent.

The orbital tissue is congested and shows numerous epithelioid cells filled with pigment that fails to bleach by the method of Alfieri — blood pigment. There are, however, no hemorrhages to be seen. The fat droplets in the nuclei of the fat cells are unusually large and often multiple.

The retina shows complete disappearance of the layer of ganglion cells, both in the macular region and elsewhere, and atrophy of the nerve fibers. There is only slight edema. The retinal veins and capillaries are greatly congested. One small retinal hemorrhage is found after a long search. Many of the retinal vessels, especially the larger, show marked fibrosis with some sub-endothelial proliferation.

Figure 1.

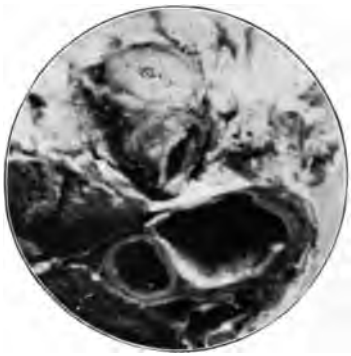

Figure 2.

Figure 3.

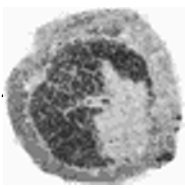

Figure 4.

The chorioid is markedly congested and in places shows proliferation of phagocytic epithelioid cells, many of which are packed with blood pigment.

Pathological diagnosis.— Aneurism of right internal carotid artery with recent perforation into cavernous sinus — arterio-venous aneurism. Edema of right cerebral hemisphere. Compression of right optic nerve by sclerotic carotid artery with degeneration of papillo-macular bundle.

ILLUSTRATIONS.

Fig. 1. View of aneurism from behind. 1, Carotid artery. 2, Cavernous sinus. 3, Aneurismal sac showing communication with artery. 4, Carotid artery after leaving sinus. 5, Pituitary body. The communication between the aneurism and the cavernous sinus occurs in the posterior half of the specimen and is so situated that it can not be photographed. (x 2.10.)

Fig. 2. Showing optic nerve, cut across, compressed by sclerotic carotid artery at exit of right optic canal. The ophthalmic artery is given off at this point. The central area of degeneration in the nerve is well shown. (x 2.10.)

Fig. 3. Cross section of right optic nerve at exit of canal showing degeneration of papillo-macular bundle. Weigert's myelin sheath stain. (x 5.20.)

Fig. 4. Cross section of right optic nerve near the eye, showing degenerated papillo-macular bundle assuming a peripheral position. (x 5.20.)

There have been about 260 of these cases reported, the first in 1805, and this case I believe is the 33d in which an autopsy has been made. It is also the 7th case in which the presence of a rupture of the carotid into the cavernous sinus has been absolutely proven, this being the lesion which most authors agree is the one probably most often present in intracranial cases. The results of the autopsies are as follows: Aneurism of the ophthalmic artery in the orbit, 2 cases; aneurism of the same before its entrance into the orbit, 1; rupture of the carotid artery into the cavernous sinus, 7. To this number, however, may be added 3 cases reviewed by Sattler and one reported by Brandes, in which

the same was practically demonstrated. Sattler thought it probable that 2 others also in his list of 19 autopsies were of this kind. Considering the difficulty in demonstrating this lesion, which Dr. Verhoeff assures me is really great, it is easy to believe that in these cases of Sattler and others a slight rent in the artery may have been overlooked. Aneurism of the internal carotid was present in 3 cases and in another the wall of the carotid was found very much thinned, but no rupture demonstrated. Tumors caused 5 cases and internal hydrocephalus and orbital encephalocele one each and in one there was a communication between some branches of the ophthalmic artery and the sinus. In 6 no aneurism or arterial lesion was found.

In the present case I think it may be considered without question that the aneurism of the carotid had existed long before the rupture into the sinus and that it was spontaneous. There is little doubt, too, that the slight injury was sufficient to produce the rupture in the already thinned and diseased artery. There has been some controversy as to whether an aneurism alone of the carotid could cause the symptoms of pulsating exophthalmus. Rivington, in 1896, made the statement that true pulsating exopthalmus could not be caused by a circumscribed or fusiform aneurism of this vessel and that the symptoms appeared only if the artery ruptured and the blood entered the veins. A statement similar to this is made by Bull in Norris and Oliver's work, that in no case of aneurism of the carotid in the cavernous sinus which came to autopsy were there any signs of venous stasis, exophthalmus or pulsation during life. LeFort, however, in 1890, gave as an opinion that aneurism of the ophthalmic artery, aneurism of the carotid in the cavernous sinus and rupture of the carotid into the sinus, all gave identical symptoms. He also suggested as a means of diagnosis the character of the bruit, the existence of a "bruit de souffle," continuous, with exacerbations being in favor of a rupture into the sinus. Barnard and Rugby, too, in 1904, reported an autopsy on a typical case, in which there was a double sacculated aneurism in the intracranial course of

the carotid but without any communication with the sinus and without noticeable dilatation of the sinus or ophthalmic vein. They, therefore, concluded that such an aneurism could in itself cause the symptoms of the disease. The very large aneurism in our own case seems to have given rise to no symptoms whatever.

Another point of interest is the treatment of these cases. In the whole number of reported cases the common carotid has been tied either as the only method of treatment or secondarily in about 125 cases. Stomann's figures in 1898, referring to 95 cases, are: Cured, 51 per cent.; improved, 17 per cent.; unimproved, 17 per cent., and died, 10 per cent. Reuchlin, in 1902, gives: Recovery, 68 per cent., meaning by recovery probably both cured and improved, and in this way his figures agree with Stomann's. No result in 21 per cent. and death in 9 per cent. Cases reported since that time do not change these figures to any extent. There have been at least 10 cases in which both carotids have been tied. In comparison with the results of ligation may be put those from compression. Stomann reported healing in only 8 out of 53 cases and later in 1902 Reuchlin gave 22 per cent. of recovery from the same treatment. There have been in the neighborhood of 21 spontaneous recoveries. Most writers advise ligation of the carotid as the best method of treatment, but there has been some dissent from this on the ground that there are these spontaneous recoveries, that there are cases on record in which physical signs and symptoms of pulsating exophthalmus have existed a long period without marked effect on the well-being of the patient and with but little danger to life, that there is often a recurrence of symptoms after ligation and that there are dangers of sepsis, hemorrhage and cerebral complications from the operation. One who has had the writer's experience in ligation of the carotid naturally welcomes any other procedure with less attendant danger. Compression offers too little hope of success. The later recommendations of Sattler and of Schwalbach are, therefore, interesting. Both these writers report cures by ligation and resection of the superior ophthalmic vein. Schwalbach's case had previously had ligation of the carotid without result.

Dollinger had a still more interesting case. After an interval of a month ligation of the second carotid followed the first and ten weeks later, there being a return of symptoms, Dollinger tied off some of the small veins and resected about half an inch of enlarged and thickened superior ophthalmic vein. The patient was discharged cured in thirteen days. Woodward did a similar operation following ligation of the common carotid and Golowin has done the same. The cure seems to come from thrombosis spreading from the seat of ligation backward. It is recommended that this procedure be adopted before ligation of the carotid, certainly before tying the second one in event of failure with the first.

In this connection I would like to mention briefly and put on record another case of my own: A. T., male, aged 54. Patient was thrown from a bicycle, striking on the left side of his head, and was unconscious for twelve hours. Two days after there was a loss of outward motion in both eyes, which disappeared at the end of a week, to be followed by an exophthalmus of the right eye, accompanied by a loud noise in the head, which was most marked in the right ear. There was also a dull ache in the vertex and occipital region and some nausea. Examination about four weeks after the injury showed exophthalmus and immobility of the right globe, lids swollen and livid, and the lower part of the conjunctiva chemotic. Pupil, iris and cornea normal. Vision, fingers at 20 feet. Congestion and tortuosity of retinal veins. Pulsation felt and heard through upper lid. The eye symptoms became rapidly worse and three days later he was operated on by Dr. S. J. Mixter. The operation consisted in making deep incisions into the orbital tissue above and below through the lids and there was profuse hemorrhage. The cornea ulcerated and sight was lost, but the other conditions gradually mended. There was a little later a slight recurrence but it was followed by further improvement. At this time a bowel trouble came on, lasting some time, but finally, about three months after entrance, he was discharged. There was still some injection and chemosis of the lower part of the conjunctiva but it was rapidly

diminishing, there was little or no exophthalmus and no pulsation, a cure with loss of sight.

There can be but little doubt, I think, that the cure in this case was brought about in the same way as in the cases of ligation and resection of the orbital veins, the free division of the vessels and bleeding from them leading the way to thrombosis and this extending backward. I should be inclined on another occasion, if the character of the bruit suggested a rupture, or if there were evidences of much stasis or enlargement of the orbital vessels, to try the effect of tying and resecting these, especially if the patient was not young and the case was a spontaneous one. The applicability of this procedure to our first case, however, in spite of the presence to a moderate extent of these indications, is doubtful. It seems as though it could have had but little lasting effect.

SECONDARY GLAUCOMA OCCURRING IN A CASE PRESENTING A CURIOUS FORM OF KERATITIS.

By S. D. RISLEY, M.D.,
PHILADELPHIA, PA.
and
HAROLD G. GOLDBERG, M.D.,

A. J., aged 36, presented himself for treatment at the Wills Eye Hospital suffering from severe pain in his left eye. All perception of light in the eye had been lost from severe inflammation many years before but until quite recently had remained free from pain, irritation or discomfort.

The ball was stony hard and deeply injected. The entire cornea was opaque, presenting a gray, curiously roughened, morocco-like surface. The eye was enucleated, placed in 5% formalin and sent to the pathological laboratory for study. The curator's report follows, which, because of the curious and unusual proliferation mass, which like a flap, separated itself from the underlying layers of the cornea, is deemed of sufficient interest for publication.

DR. GOLDBERG'S REPORT.

The man was admitted to the clinic of Dr. S. D. Risley at the Wills Eye Hospital where a diagnosis of secondary glaucoma was made. There was a history of having had a sore eye many years before, which in the light of the examination was probably an ulcerous keratitis. The eye-ball was received in a five per cent. solution of formalin in which it had remained for about twenty-four hours. It proved to be normal in size, the cornea was covered with a dense opaque cartilaginous material, containing a few blood-vessels in its substance. This membrane through the contraction caused by the hardening action of the formalin, had become detached from the cornea throughout its entire extent, with the exception of one small pedicle-like portion, which was about two mm. in breadth. The cornea beneath this flap *was perfectly transparent.* The pupil was irregularly dilated ad maximum. The lens was cataractous and of color of amber. A section through the equator of the globe revealed the following appearances; The vitreous was contracted and what remained of it was blood stained, the choroid was atrophic and there were pigment heapings everywhere, but especially in the region of the macula, which point was marked by a large white nodule.

The microscopic appearances follow: The substantia propria of the cornea is split into two quite equal parts, the detached portion being united to the eye-ball at the corneo-scleral margin, by one small flap of tissue. At this point there is an enormous proliferation of the epithelial cells of the cornea, the epithelial body being pedunculated, and the peduncle united to the underlying structure by areolar connective tissue. The epithelium of the detached portion of the cornea dips down into the substance in many places, and immediately beneath this layer and encroaching upon it in several places, are striae of calcareous material, while some of the epithelial cells also show this change. On the external surface of the epithelium are found circumscribed heaps of red blood cells. Scattered throughout the substance of the detached portion of the cornea are isolated islands of epithelial cells, one

location marking the point where the cells have invaded different layers of the fibers, a mantle of cells covering a round plug, from which it is separated by a layer of connective tissue cells of the fibers, making it appear under the low power, like a curiously formed blood-vessel. Scattered throughout the same portion of the cornea, are many large, well-formed blood-vessels, most of which are filled with red blood cells, although some contain polymorphonuclear leucocytes. The connective tissue cells have proliferated and some of them have undergone degenerative change. The intact portion of the substantia propria is quite clear, there is no leucocytosis, and no proliferation of the connective tissue cells. The posterior elastic lamina is absent and the endothelium is degenerated. The anterior chamber is almost completely obliterated, the lens is cataractous, the cortical fibers are separated and undergoing calcareous change, well advanced anteriorly. The subcapsular epithelium is absent. The root of the iris is attached to the cornea at the angle by a fine reticulated, connective tissue framework, some of the cells being pigmented. The blood-vessels are degenerated; fibro-cicatricial changes are taking place, and the pars retina is broken up into formless heaps. The ciliary bodies are in much the same condition, there is almost a complete replacement by cellular fibrous connective tissue for muscle, and in this layer are seen many large blood-vessels. The fibrous changes are especially well marked just beneath the pars retina, and here as in the iris the pigment is broken up into formless heaps. Very little remains of the retina anteriorly, the blood-vessels are degenerated, the fibrous changes are at a late stage, the vitreous lamina cannot be made out, and the retina at many small points is firmly adherent to the choroid by a fibrous union. The pigmented epithelium is generally proliferated. Anteriorly the choroid is marked only by a layer of heavily pigmented cells, the character of which cannot be seen, and the layer of non-pigmented connective tissue cells. No blood vessels can be seen. There is a complete detachment of the choroid. Posteriorly the changes in the retina and choroid are practically the same, ex-

cept in the choroid some of the larger vortex veins are intact, but show a complete stasis, being completely filled with red blood cells the mass of which is surrounded by a mantle of leucocytes. ("peripheral drift of the leucocytes" after slowing of the current.) The fibrous changes in the retina are more advanced, large circumscribed areas of fibrous tissue are seen, almost cellular. Surrounding the largest area are several hyaline bodies, and scattered sparingly through it calcareous granules, while at the periphery of the largest fibrous mass are large areas of hyaline material, undergoing beginning calcareous change. Elsewhere, layers of fibrous tissue are found embedded in masses of amorphous pigment. In the near neighborhood of the region just described, are seen large irregular masses of red blood cells not enclosed in walls, these masses lie in the vitreous chamber and contain within them islands of striated fibrous tissue. Some of the blood-vessels in the retina can be seen, most of them being six or seven times their normal caliber, while the walls are composed almost entirely of pure fibrous tissue. Some of the blood vessels in the retina can be seen, most of them being six or seven times their normal caliber, while the walls are composed almost entirely of pure fibrous tissue. It is notable that in these locations the retina shows its best structure. There is complete atrophy of the nerve, and marked hyperplasia of the connective tissue elements.

Conclusions.—The division of the substantia propria into two almost equal parts, the one representing a late stage of corneal destruction, and the other being composed of a clear tissue of a reasonable strength, thickness, and transparency, suggests possibilities certainly worthy of consideration. It is at least interesting to assume that the epithelial invasion of the substantia propria is nature's attempt to cover the clear portion, as though that healthy part had some special attraction for the epithelial cells. These epithelial invasions are hardly unusual, but I have never seen them occur so abundantly, and so persistently as they do in this case. There are many other points of interest about this

UNUSUAL KERATITIS

specimen aside from the corneal changes, and the most notable of them is the relation of the fibrous tissue to the clinical diagnosis of secondary glaucoma. That changes of the kind described could progress to such a late stage before the onset of a glaucomatous attack, seems almost incredible. And yet such is the case as is indicated by the blood-vessel changes. Here is almost a complete destruction of the entire arterial system of the uvea, the veins surviving in a fair degree of preservation, what circulation did take place was obviously between the external portions of the globe and the extreme internum, the intermediate balance being lost. The fibrous changes attacking the choroid first and finding a membrane better adapted for its favorable growth, disproportionately soon destroyed the membrane, compensation for which, was gained through the retina, vitreous, muscular division of the ciliary body, and the iris. The fibrous change in the retina is actually a fibromatosis, which was apparently the final destructive agent in the production of the glaucoma.

A NEW TRIAL FRAME

DESIGNED BY

DR. WM. HOLLAND WILMER.

This frame embodies several desirable features found in no other frame, inasmuch as the cell for cylinders is marked making

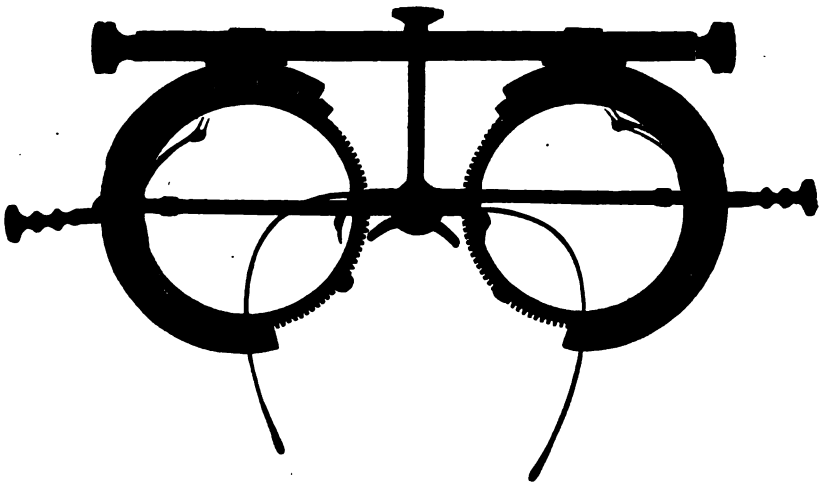



it unnecessary to depend on the slight axis mark on the cylinder lens.

The temples are adjustable, permitting a drop of 15 degrees for reading test.

The frame is made in dark color and is exceptionally light in weight. The graduation on protractor is handmade, insuring accuracy, a very weak point in all frames.

Made by F. H. Edwards, Washington, D. C.

TRANSACTIONS

OF THE

AMERICAN

OPHTHALMOLOGICAL SOCIETY.

Forty-fourth Annual Meeting.

NEW LONDON, CONN., 1908.

Vol. XI, Part III.

HARTFORD:
PUBLISHED BY THE SOCIETY
1908.

BOSTON MEDICAL
FEB 1 1909
LIBRARY.

THE CASE, LOCKWOOD & BRAINARD COMPANY, PRINTERS, HARTFORD, CONN.

CATALOGUED
FEB 1 1909
J. F. B.

TABLE OF CONTENTS

	PAGE
Members of the Society,	459
Minutes of the forty-fourth annual meeting,	463
Sudden obstruction of the central artery of the retina, being a clinical record of five cases; Drs. G. E. de Schweinitz and T. B. Holloway,	471
Embolism of a macular artery and thrombosis of superior and inferior retinal arteries, in a case of embolic softening of the brain; Dr. W. T. Shoemaker,	502
Angioma of the orbit with invasion of the globe along the ciliary nerves; Dr. A. Quackenboss,	510
Macular holes; Dr. C. J. Kipp,	518
A case exhibiting a symblepharon, corneal opacities and a probably fibro-fatty tumor of the conjunctiva, all of pre-natal origin, in a woman with hereditary cataracts at an early age; Dr. Burton Chance,	528
Cyanosis retinae; Dr. H. H. Tyson,	531
A case of grill-like keratitis; Dr. C. J. Kipp,	537
The increasing importance of tuberculosis as a cause of ocular disease, the newer methods of diagnosis and the treatment; Dr. G. S. Derby,	540
Angioma of the choroid; Dr. A. Quackenboss,	557
The teleology and interpretation of nystagmus; Dr. P. Fridenberg,	562
Two cases of sympathetic ophthalmia; Dr. E. S. Thomson,	575
Diffuse interstitial keratitis in acquired syphilis; Dr. J. T. Carpenter,	581
Recent traumatic erosion of the cornea; Dr. R. J. Curdy,	594
Thyroid extract in keratitis; Dr. McCluney Radcliffe,	597
The treatment of immature cataract; Major Henry Smith,	603
The extraction of cataract with a lance-shaped knife; Dr. J. H. Claiborne,	618
An attempt to determine the normal range of accommodation at various ages, being a revision of Donder's experiments; Dr. A. Duane,	634
The clinical measurement of relative accommodation; Dr. L. Howe,	642
Some practical points in the use of prisms; Dr. B. L. Millikin,	650
Strabismus from the operative standpoint; Dr. P. A. Callan,	665
A simplification of De Grandmont's operation for ptosis; Dr. S. Theobald,	673

PAGE

Restoration of sight after nearly a month's blindness from glaucoma; Dr. J. L. Minor, ... 678
Bilateral optic neuritis after ethmoiditis; Dr. A. Knapp, . . 681
Ocular affections associated with disease of the sinuses contiguous to the orbit; Dr. S. D. Risley, ... 685
Mixed streptococcus and pneumococcus infections of the orbit and adjacent sinuses; Dr. C. S. Bull, ... 695
Hemorrhage from the cornea in glaucoma; Dr. T. R. Pooley, . 715
Adeno-carcinoma of orbit; Dr. T. R. Pooley, ... 718
Blepharo-conjunctivitis caused by diplococcus of Morax-Axenfeld; Dr. Brown Pusey, ... 722
Description of cases of shrinkage of the eyeball, with remarks on the processes underlying atrophia bulbi in general; Dr. W. G. M. Byers, ... 731
Report of committee on ophthalmia neonatorum; Dr. L. Howe, . 741

American Ophthalmological Society.
1908-1909.

OFFICERS

President,	Dr. S. B. St. John,	Hartford, Conn.
Vice-President,	Dr. S. Theobald,	Baltimore, Md.
Secretary-Treasurer,	Dr. W. M. Sweet,	Philadelphia, Pa.
Corresponding Secretary,	Dr. A. Knapp,	New York City.

MEMBERS

ACTIVE MEMBERS.

The (*) indicates *Associates*.

Name.	Residence.	Place.
Dr. A. E. Adams,	44 Grand Street,	Newburg, N. Y.
Dr. J. L. Adams,	38 East 51st Street,	New York, N. Y.
Dr. L. A. W. Alleman,	64 Montague Street,	Brooklyn, N. Y.
Dr. A. N. Alling,	257 Church Street,	New Haven, Conn.
Dr. G. W. Allyn,	Empire Building,	Pittsburg, Pa.
Dr. A. Alt,	Metropolitan Bldg.,	St. Louis, Mo.
†Dr. J. A. Andrews,	107 Madison Avenue,	New York, N. Y.
Dr. S. C. Ayres,	4 West 7th Street,	Cincinnati, Ohio.
*Dr. C. H. Beard,	34 Washington Street,	Chicago, Ill.
*Dr. Geo. H. Bell,	54 East 25th Street,	New York, N. Y.
*Dr. Jas. H. Bell,	Moore Building,	San Antonio, Texas.
Dr. H. W. Bradford,		Wolfboro, N. H.
*Dr. Gustave E. Brubre,	413 Oregonian Building,	Portland, Oregon.
*Dr. E. V. L. Brown,	100 State Street,	Chicago, Ill.
*Dr. Wm. E Bruner,	New England Building,	Cleveland, Ohio.
*Dr. H. D. Bruns,	211 Camp Street,	New Orleans, La.
Dr. Charles S. Bull,	47 West 36th Street,	New York, N. Y.
*Dr. W. K. Butler,	1207 M St. N. W.,	Washington, D. C.
*Dr. W. Gordon M. Byers,	346 Mountain Street,	Montreal, Canada.
Dr. Peter A. Callan,	35 West 38th Street,	New York, N. Y.
Dr. F. P. Capron,	118 Angell Street,	Providence, R. I.
Dr. W. H. Carmalt,	87 Elm Street,	New Haven, Conn.
Dr. John T. Carpenter, Jr.,	1624 Walnut Street,	Philadelphia, Pa.
Dr. Burton Chance,	235 So. 13th Street,	Philadelphia, Pa.
Dr. H. B. Chandler,	34½ Beacon Street,	Boston, Mass.
Dr. J. W. Charles,	509 Humboldt Building,	St. Louis, Mo.
Dr. Wm. Cheatham,	303 West Chestnut Street,	Louisville, Ky.
Dr. F. E. Cheney,	126 Commonwealth Avenue,	Boston, Mass.
Dr. J. H. Claiborne,	34 West 36th Street,	New York City.
Dr. C. F. Clark,	188 East State Street,	Columbus, Ohio.
Dr. David Coggin,	7 Chestnut Street,	Salem, Mass.
Dr. Wm. G. Craig,	15 Fuller Building,	Springfield, Mass.
Dr. C. M. Culver,	36 Eagle Street,	Albany, N. Y.
*Dr. R. J. Curdy,	301 Keith & Perry Building,	Kansas City, Mo.
Dr. C. W. Cutler,	52 West 53d Street,	New York, N. Y.
*Dr. Jno. P. Davidson,	316 East Franklin Street,	Richmond, Va.

† Temporarily residing at Santa Barbara, Cal.

Name.	Residence.	Place.
*Dr. A. E. Davis,	50 West 37th Street,	New York, N. Y.
Dr. W. S. Dennett,	8 East 49th Street,	New York, N. Y.
Dr. Hasket Derby,	182 Marlborough Street,	Boston, Mass.
Dr. Lewis S. Dixon,	232 Clarendon Street,	Boston, Mass.
Dr. Alexander Duane,	49 East 30th Street,	New York, N. Y.
*Dr. J. A. Duncan,	70 17th Street,	Pittsburg, Pa.
Dr. J. B. Emerson,	20 East 30th Street,	New York, N. Y.
Dr. Arthur E. Ewing,	Metropolitan Bldg.,	St. Louis, Mo.
Dr. T. H. Fenton,	1319 Spruce Street,	Philadelphia, Pa.
Dr. George F. Fiske,	100 State Street,	Chicago, Ill.
*Dr. W. H. Fox,	1826 Jefferson Place,	Washington, D. C.
Dr. Percy Fridenberg,	60 East 58th Street,	New York, N. Y.
Dr. H. Friedenwald,	1029 Madison Ave.,	Baltimore, Md.
Dr. B. F. Fryer,	Cor. 9th and Cherry Streets,	Kansas City, Mo.
Dr. G. M. Gould,	1722 Walnut Street,	Philadelphia, Pa.
Dr. H. Y. Grant,	Falls View,	Ontario, Canada.
*Dr. L. S. Greene,	1610 I Street,	Washington, D. C.
*Dr. Allen Greenwood,	101 Newbury Street,	Boston, Mass.
Dr. Emil Gruening,	36 East 57th Street,	New York, N. Y.
*Dr. C. W. Haddock,		Beverly, Mass.
Dr. G. W. Hale,	Wilcox Building,	Nashville, Tenn.
Dr. Wm. D. Hall,	138 Marlborough Street,	Boston, Mass.
Dr. H. F. Hansell,	1528 Walnut Street,	Philadelphia, Pa.
Dr. George C. Harlan,	1515 Walnut Street,	Philadelphia, Pa.
Dr. Herbert Harlan,	516 Cathedral Street,	Baltimore, Md.
Dr. David Harrower,	9 Elm Street,	Worcester, Mass.
Dr. N. D. Harvey,	262 Benefit Street,	Providence, R. I.
Dr. H. H. Haskell,	34 Commonwealth Avenue,	Boston, Mass.
Dr. Neil J. Hepburn,	317 West 23d Street,	New York, N. Y.
Dr. Ward Holden,	43 West 48th Street,	New York, N. Y.
*Dr. C. R. Holmes,	8 East 8th Street,	Cincinnati, Ohio.
Dr. E. E. Holt,	723 Congress Street,	Portland, Me.
Dr. Lucien Howe,	87 West Huron Street,	Buffalo, N. Y.
Dr. A. A. Hubbell,	212 Franklin Street,	Buffalo, N. Y.
Dr. D. W. Hunter,	80 West 40th Street,	New York, N. Y.
Dr. J. W. Ingalls,	874 Lafayette Avenue,	Brooklyn, N. Y.
Dr. E. E. Jack,	215 Beacon Street,	Boston, Mass.
Dr. Edward Jackson,	1434 Glenarm Street,	Denver, Col.
Dr. B. Joy Jeffries,	15 Chestnut St., Beacon Hill,	Boston, Mass.
Dr. W. B. Johnson,	170 Broadway,	Paterson, N. J.
*Dr. B. R. Kennon,	64 Granby Street,	Norfolk, Va.
Dr. H. W. Kilburn,	192 Marlborough Street,	Boston, Mass.
Dr. Charles J. Kipp,	560 Broad Street,	Newark, N. J.
Dr. Arnold Knapp,	26 West 40th Street,	New York, N. Y.
Dr. H. Knapp,	26 West 40th Street,	New York, N. Y.
Dr. Carl Koller,	681 Madison Avenue,	New York, N. Y.
Dr. Chas. W. Kollock,	Cor. Wentworth & Com'g Sts.,	Charleston, S. C.
Dr. W. E. Lambert,	47 West 38th Street,	New York, N. Y.
*Dr. W. B. Lancaster,		Amherst, Mass.
*Dr. J. C. Lester	179 Schermerhorn Street,	Brooklyn, N. Y.
Dr. F. N. Lewis,	616 Madison Ave., Cor. 58th St.	New York City.

Name.	Residence.	Place.
*Dr. G. F. Libby,	1434 Glenarm Street,	Denver, Col.
Dr. J. A. Lippincott,	Arrott Bdg., Wood St. & 4th Av.,	Pittsburg, Pa.
Dr. F. B. Loring,	1420 K Street,	Washington, D. C.
Dr. D. B. Lovell,	32 Pearl Street,	Worcester, Mass.
*Dr. J. B. Lynch,	148 West 22d Street,	New York, N. Y.
Dr. F. W. Marlow,	731 University Block,	Syracuse, N. Y.
Dr. W. V. Marmion,	1110 8th Street, N. W.,	Washington, D. C.
Dr. W. B. Marple,	46 W. 53d Street,	New York, N. Y.
Dr. Arthur Mathewson,	408 5th Street,	Washington, D. C.
Dr. Chas. H. McIlwaine,	264 Willis Avenue,	New York, N. Y.
Dr. Jno. R. McIntosh,	40 Coburg Street,	St. John, N. B.
Dr. S. C. Maxson,	225 Genesee Street,	Utica, N. Y.
*Dr. C. H. May,	698 Madison Avenue,	New York, N. Y.
Dr. C. S. Merrill,	23 Washington Avenue,	Albany, N. Y.
*Dr. H. S. Miles,	417 State Street,	Bridgeport, Conn.
Dr. B. L. Millikin,	1110 Euclid Avenue,	Cleveland, Ohio.
Dr. J. Lancelot Minor,	14 Randolph Building,	Memphis, Tenn.
Dr. W. F. Mittendorf,	140 Madison Avenue,	New York, N. Y.
Dr. Charles A. Oliver,	1507 Locust Street,	Philadelphia, Pa.
Dr. H. S. Oppenheimer,	741 Madison Avenue,	New York, N. Y.
*Dr. W. R. Parker,	912 Chamber of Commerce,	Detroit, Mich.
*Dr. S. McA. Payne,	542 Fifth Avenue,	New York, N. Y.
Dr. R. J. Phillips,	123 So. 39th Street,	Philadelphia, Pa.
Dr. Thomas R. Pooley,	107 Madison Avenue,	New York, N. Y.
Dr. William C. Posey,	1831 Chestnut Street,	Philadelphia, Pa.
Dr. M. H. Post,	Metropolitan Bldg.,	St. Louis, Mo.
Dr. H. R. Price,	435 Clinton Avenue,	Brooklyn, N. Y.
Dr. J. S. Prout,	26 Schermerhorn Street,	Brooklyn, N. Y.
*Dr. Brown Pusey,	70 Madison Street,	Chicago, Ill.
Dr. Walter L. Pyle,	1806 Chestnut Street,	Philadelphia, Pa.
Dr. Alex. Quackenboss,	277 Dartmouth Street,	Boston, Mass.
*Dr. McCluney Radcliffe,	1812 Chestnut Street,	Philadelphia, Pa.
Dr. Alex'r Randall,	1717 Locust Street,	Philadelphia, Pa.
Dr R. L. Randolph,	816 Park Avenue,	Baltimore, Md.
Dr. J. M. Ray,	Atherton Bldg.,	Louisville, Ky.
Dr. R. G. Reese,	147 W. 57th Street,	New York, N. Y.
Dr. R. A. Reeve,	48 Bloor Street East,	Toronto, Canada.
Dr. H. O. Reik,	412 Cathedral Street,	Baltimore, Md.
Dr. Stephen O. Richey,	732 17th Street,	Washington, D. C.
Dr. Charles E. Rider,	26 Gibbs Street,	Rochester, N. Y.
Dr. Wheelock Rider,	26 Gibbs Street,	Rochester, N. Y.
*Dr. G. O. Ring,	1900 Chestnut Street,	Philadelphia, Pa.
Dr. H. W. Ring,	187 Church Street,	New Haven, Conn.
*Dr. J. Norman Risley,	1728 Chestnut Street,	Philadelphia, Pa.
Dr. Samuel D. Risley,	1728 Chestnut Street,	Philadelphia, Pa.
Dr. Edmund C. Rivers,	1632 Welton Street,	Denver City, Col.
Dr. Wm. K. Rogers,	188 East State Street,	Columbus, Ohio.
Dr. Dunbar Roy,	Grand Opera House Block,	Atlanta, Ga.
Dr. John D. Rushmore,	129 Montague Street,	Brooklyn, N. Y.
Dr. Robert Sattler,	7th and Race Streets,	Cincinnati, Ohio.
Dr. T. B. Schneideman,	1831 Chestnut Street,	Philadelphia, Pa.

Name.	Residence.	Place.
Dr. G. E. de Schweinitz,	1705 Walnut Street,	Philadelphia, Pa.
Dr. P. N. K. Schwenk,	810 North 7th Street,	Philadelphia, Pa.
Dr. John R. Shannon,	25 W. 36th Street,	New York, N. Y.
Dr. Henry L. Shaw,	19 Commonwealth Avenue,	Boston, Mass.
*Dr. H. G. Sherman,	736 Rose Building,	Cleveland, Ohio.
Dr. Wm. T. Shoemaker,	2031 Chestnut Street,	Philadelphia, Pa.
Dr. Wm. A. Shoemaker,	1006 Carlton Building,	St. Louis, Mo.
*Dr. E. A. Shumway,	2007 Chestnut Street,	Philadelphia, Pa.
Dr. F. D. Skeel,	58 E. 25th Street,	New York, N. Y.
Dr. J. A. Spalding,	627 Congress Street,	Portland, Me.
Dr. Myles Standish,	6 St. James Avenue,	Boston, Mass
*Dr. E. W. Stevens,	421 McPhee Building,	Denver, Col.
Dr. George T. Stevens,	22 East 46th Street,	New York, N. Y.
Dr. Edw. Stieren,	3603 Fifth Avenue,	Pittsburg, Pa.
Dr. Samuel B. St. John,	68 Pratt Street,	Hartford, Conn.
Dr. Geo. Strawbridge,	202 So. 15th Street,	Philadelphia, Pa.
Dr. T. Y. Sutphen,	999 Broad Street,	Newark, N. J.
Dr. Wm. M. Sweet,	1205 Spruce Street,	Philadelphia, Pa.
Dr. Lewis H. Taylor,	83 South Franklin Street,	Wilkes-Barre, Pa.
Dr. Samuel Theobald,	970 North Howard Street,	Baltimore, Md.
Dr. Ch. Hermon Thomas,	3634 Chestnut Street,	Philadelphia, Pa.
Dr. A. G. Thomson,	1426 Walnut Street,	Philadelphia, Pa.
Dr. Edgar S. Thomson,	19 E. 44th Street,	New York, N. Y.
Dr. Jas. Thorington,	120 South 18th Street,	Philadelphia, Pa.
*Dr. Andrew Timberman,	112 East Broad Street,	Columbus, Ohio
*Dr. H. H. Tyson,	47 West 51st Street,	New York, N. Y.
Dr. John Van Duyn,	318 James Street,	Syracuse, N. Y.
Dr. C. A. Veasey,	1833 Chestnut Street,	Philadelphia, Pa.
Dr. F. H. Verhoeff,	101 Newbury Street,	Boston, Mass.
Dr. O. F. Wadsworth,	526 Beacon Street,	Boston, Mass.
Dr. F. L. Waite,	68 Pratt Street,	Hartford, Conn.
Dr. David Webster,	308 Madison Avenue,	New York, N. Y.
Dr. J. E. Weeks,	46 East 57th Street,	New York, N. Y.
*Dr. Cassius D. Westcott,	31 Washington Street,	Chicago, Ill.
Dr. J. A. White,	200 E. Franklin Street,	Richmond, Va.
Dr. W. H. Wilder,	103 State Street,	Chicago, Ill.
Dr. Chas. H. Williams,	1069 Boylston Street,	Boston, Mass.
Dr. Wm. H. Wilmer,	1610 I Street N. W.,	Washington, D. C.
Dr. F. M. Wilson,	834 Myrtle Avenue,	Bridgeport, Conn.
*Dr. J. Scott Wood,	172 Sixth Avenue,	Brooklyn, N. Y.
*Dr. William L. Wood,	412 Oregonian Building,	Portland, Oregon.
Dr. Hiram Woods,	842 Park Ave.,	Baltimore, Md.
Dr. J. P. Worrell,	20 South 7th Street,	Terre Haute, Ind.
Dr. S. Lewis Ziegler,	1625 Walnut Street,	Philadelphia, Pa.
Dr. Wm. Zentmayer,	1819 Spruce Street,	Philadelphia, Pa.
Total,	. . . . .	183

HONORARY MEMBERS.

Dr. F. P. Sprague, .	229 Commonwealth Avenue,	Boston, Mass.
Dr. Jno. Green,	Metropolitan Bldg.,	St. Louis, Mo.
Whole number,	. . . .	185

MINUTES OF THE PROCEEDINGS.

FORTY-FOURTH ANNUAL MEETING.

GRISWOLD HOUSE,
NEW LONDON, CONN., July 15, 1908.

The Forty-fourth Annual Meeting of the Society was called to order at 10 A. M. by President Risley, and the following committees were announced:

On Bulletin—Drs. J. T. CARPENTER and W. T. SHOEMAKER.

On Membership—Drs. HARLAN, HARROWER, GRUENING, DE SCHWEINITZ, and ALLING.

Auditing Committee—Dr. DENNETT.

President Risley made a short speech of welcome.

Committee on Bulletin reported and the following papers were read:

1. "Sympathetic ophthalmia with report of two cases," Dr. E. S. Thomson.

Discussed by Dr. Kipp.

Dr. Holloway of Philadelphia and Dr. Fisch of Boston were invited as guests of the Society to take part in the discussions.

2. "A description of cases of shrinkage of the eyeball with observations on the processes underlying atrophia bulbi in general," Dr. W. G. M. Byers.

3. "Report of two cases of diffuse interstitial keratitis in acquired syphilis," Dr. J. T. Carpenter.

Discussed by Drs. Theobald, Callan, Kipp, de Schweinitz, and H. Smith.

4. "Recurrent traumatic erosion of the cornea," Dr. R. J. Curdy.

5. "Thyroid extract in keratitis," Dr. McCluney Radcliffe.

Discussed by Drs. Pyle, de Schweinitz, Verhoeff, Maxson, Risley, Theobald, Carpenter, Curdy, and Radcliffe.

6. "The treatment of immature cataract," Maj. Henry Smith of H. M. India Service (by invitation).

Discussed by Drs. Kipp, Lambert, Gruening, Pooley, Bull, Pyle, H. Harlan, Johnson, Theobald, Byers, Lippincott, Howe, E. S. Thomson, Sutphen, Webster, Risley, and Smith.

Adjourned to 2.30.

Afternoon session called to order at 2.30.

Dr. R. G. Loring of Boston was invited to take part as a guest of the Society.

Reading papers resumed.

7. "Extraction of cataract with lance-shaped keratome," Dr. Claiborne.

Discussed by Drs. Pooley, Webster, Chandler, Smith, Sutphen, and Claiborne.

8. "An attempt to determine the normal range of accommodation at various ages, being a revision of Donder's experiments," Dr. Duane.

9. "The clinical measurement of relative accommodation," Dr. Howe.

Papers 8 and 9 discussed by Drs. Pyle, Verhoeff, Lippincott, Duane, and Howe.

10. "Some practical points regarding the use of prism-glasses," Dr. Millikin.

Discussed by Drs. Duane, Williams, Theobald, and Millikin.

11. "Strabismus from the operative standpoint," Dr. Callan.

Discussed by Drs. Mittendorf, Webster, Johnson, Howe, and Callan.

12. "The interpretation and teleology of nystagmus," Dr. Fridenberg.

Discussed by Drs. Pyle, Duane, Alling, Verhoeff, and Fridenberg.

13. "Sudden obstruction of central artery of retina with report of cases," Dr. de Schweinitz.

14. "Embolism of a macular artery and thrombosis of superior and inferior arteries in a case of embolic softening of the brain," Dr. W. T. Shoemaker.

Papers 13 and 14 discussed by Drs. Kipp and Verhoeff.

Adjourned to 9 A. M., July 16.

(*Executive session to be held at 8 P. M., July 15.*)

July 16. Called to order at 9 A. M., reading papers resumed.

15. "Case of cyanosis retinæ with congenital patent foramen ovale and pulmonary stenosis," Dr. Tyson.

16. "Angioma of choroid," Dr. Quackenboss.

Discussed by Dr. Risley.

17. "A simplification of de Grandmont's operation for ptosis," Dr. Theobald.

Discussed by Drs. Gruening, Callan, Marple, and Theobald.

18. "Case of restoration of sight after one month's blindness from glaucoma," Dr. Minor.

Discussed by Drs. Verhoeff, Gruening, Johnson, and Minor.

19. "Ocular affections associated with disease of the sinuses contiguous to the orbit," Dr. Risley.

20. "Case of bi-lateral retro-bulbar neuritis after ethmoiditis," Dr. A. Knapp.

21. "Mixed streptococcus and pneumococcus infection of the orbit and adjacent sinuses," Dr. Bull.

Papers 19, 20, 21 were discussed by Drs. Taylor, de Schweinitz, Holmes, Sherman, Callan, Theobald, Gruening, Risley, and Knapp.

22. "Case of hemorrhage from the cornea in glaucoma," Dr. Pooley.

Discussed by Dr. Mittendorf.

23. "Adeno-carcinoma of the orbit," Dr. Pooley.

Discussed by Dr. Sherman.

24. "Angioma of orbit with invasion of globe along the ciliary nerves," Dr. Quackenboss.

25. "The increasing importance of tuberculosis as a cause of ocular disease. The newer methods of diagnosis and the treatment," Dr. G. S. Derby (by invitation).

Discussed by Drs. Carmalt, Callan, Verhoeff, Byers, de Schweinitz, and Derby.

26. "A case presenting unusual corneal condition of prenatal origin," Dr. Chance.

27. "Histological investigation of a case of blepharo-conjunctivitis caused by diplo-bacillus of Morax-Axenfeld," Dr. Pusey.

28. "Macular holes," Dr. Kipp.

Discussed by Dr. Zentmayer.

29. "Grill-like keratitis," Dr. Kipp.

Adjourned at 1.30.

Executive session held July 15.

Called to order by the President at 8.30.

The President announced the loss by death during the past year of the following members: Dr. R. H. Derby, Dr. Wm. Thomson, Dr. D. B. St. J. Roosa, Dr. G. Hay, and Dr. H. G. Miller.

On motion of Dr. Marple, the Chair was requested to appoint a committee consisting of the personal friends of the deceased members, who should prepare suitable memoirs for the transactions. This committee was appointed subsequently as follows: Dr. W. E. Lambert, Dr. G. C. Harlan, Dr. J. B. Emerson, Dr. C. H. Williams, and Dr. N. D. Harvey.

The Treasurer's report was read by Dr. St. John, and was reported on by the Auditing Committee as correct. It was accepted and ordered on file.

The Secretary read a letter from Dr. Jno. Green of St. Louis, renewing his resignation as a member. On motion of Dr. Bull,

seconded by Dr. St. John, the resignation was accepted with deep regret, and Dr. John Green was then elected an honorary member of the Society on motion of Dr. Bull, seconded by Dr. St. John.

The Committee on Membership announced that the following candidates were recommended to the Society for election:

Dr. Jno. P. Davison, Richmond, Va.
Dr. B. R. Kinnon, Norfolk, Va.
Dr. S. McA. Payne, New York City.
Dr. G. H. Bell, New York City.
Dr. J. B. Lynch, New York City.
Dr. J. L. Duncan, Pittsburg, Pa.
Dr. H. S. Miles, Bridgeport, Conn.
Dr. L. S. Greene, Washington, D. C.
Dr. Andrew Timberman, Columbus, Ohio.
Dr. J. Norman Risley, Philadelphia, Pa.
Dr. E. V. L. Brown, Chicago, Ill.
Dr. W. R. Parker, Detroit, Mich.

These gentlemen were declared duly elected as associate members.

The Committee also referred a number of names of candidates to the Committee for 1909.

The following list of officers for 1909 was then presented by the Committee:

President — Dr. S. B. St. John, Hartford, Conn.

Vice-President — Dr. S. Theobald, Baltimore, Md.

Secretary and Treasurer — Dr. Wm. M. Sweet, Philadelphia, Pa.

Corresponding Secretary — Dr. Arnold Knapp, New York City.

Publication Committee — Dr. W. S. Dennett, D. W. Hunter, and W. M. Sweet.

Member of Executive Committee — Dr. G. E. DE SCHWEINITZ.

These nominations were confirmed by the Society, and the officers declared elected.

The Secretary read a list of names of candidates for membership which were referred to the Committee for 1909.

After discussion as to the eligibility of foreigners to membership, Dr. Carmalt moved an amendment to the Constitution, providing "that a class of corresponding members to the number of 25 be created to be composed of foreigners." This amendment was laid over for action on the following day.

The following resolution offered by Dr. Howe was carried: "That a committee of five be appointed, to be known as the Business Committee, the incoming president and secretary being ex-officio members. It shall be the duty of said committee to prepare a program for the next meeting, to publish a presessional volume, determine the time to be occupied by each reader of a paper or speaker who discusses it, and to decide all other details pertaining to the scientific sessions of the meeting."

The Secretary read a communication from Dr. Brown Pusey, concerning the work of Prof. Greff on the germ of trachoma. On motion of Dr. Howe, the recommendation contained therein was referred to the Business Committee. The President subsequently appointed Drs. Howe, (chairman,) de Schweinitz and Taylor to act with the President and Secretary as the Business Committee.

The Secretary read a communication from the Chief Census Statistician, regarding nomenclature in medical diseases, asking for appointment of a committee on the subject. (This committee was voted, and subsequently appointed, consisting of Drs. Duane, Jackson, and Reik.)

A communication from Dr. Musser, regarding action of the Society in connection with the International Meeting at Budapest in 1909 was read, and the Society voted that the communication be referred to the Business Committee, with power to act.

A communication from the International Congress to be held

at Budapest, inviting the Society to send delegates, was also referred to the Business Committee.

The report of the Committee on Ophthalmia was read by Dr. Howe, and the Society voted to receive the report and continue the committee.

Voted, that the Society meet next year at the Griswold House, New London, on Wednesday and Thursday, July 14th and 15th.

Voted, that the assessment for the coming year be $5.00.

Adjourned to meet in Executive Session again on 16th.

Executive Session called to order 1 P. M., July 16th.

Two names of proposed members were read by the Secretary.

Voted, that our present delegate to Cong. Am. Phy. and Surg., Dr. Bull, be re-elected.

Dr. Carmalt withdrew his ammendment to the Constitution offered yesterday.

Dr. Gruening reminded the Society that Dr. St. John who had just been elected President of the Society for the ensuing year, had held the office of Secretary for twenty years, and moved that the Society place on record its appreciation of Dr. St. John's long and faithful services. The motion was adopted by a unanimous rising vote.

S. B. ST. JOHN, *Secretary.*

Members present at Forty-fourth Meeting:

Dr. G. C. Harlan,
Dr. J. L. Minor,
Dr. W. T. Shoemaker,
Dr. L. Howe,
Dr. S. B. St. John,
Dr. P. A. Callan,
Dr. W. K. Butler,
Dr. Wheelock Rider,
Dr. W. M. Sweet,
Dr. A. Duane,
Dr. G. E. de Schweinitz,
Dr. D. Harrower,
Dr. J. T. Carpenter,
Dr. D. Webster,
Dr. C. J. Kipp,
Dr. A. Knapp,
Dr. C. M. Culver,
Dr. S. D. Risley,
Dr. W. B. Johnson,
Dr. N. J. Hepburn,
Dr. W. J. Pyle,
Dr. J. A. Lippincott,
Dr. McCluney Radcliffe,
Dr. Wm. Zentmayer,
Dr. W. S. Dennett,
Dr. E. S. Thomson,
Dr. W. F. Mittendorf,
Dr. H. Harlan,
Dr. C. S. Bull,
Dr. E. Gruening,
Dr. D. B. Lovell,
Dr. W. E. Lambert,
Dr. Jno. R. Shannon,
Dr. S. Theobald,
Dr. H. W. Ring,
Dr. W. H. Carmalt,
Dr. S. C. Maxson,
Dr. J. W. Charles,
Dr. W. G. M. Byers,
Dr. Brown Pusey,
Dr. H. H. Tyson,
Dr. D. Coggin,
Dr. J. D. Rushmore,
Dr. Alex Quackenboss,
Dr. H. B. Chandler,
Dr. W. H. Wilmer,
Dr. W. G. Craig,
Dr. T. R. Pooley,
Dr. A. N. Alling,
Dr. F. H. Verhoeff,
Dr. C. H. Williams,
Dr. T. H. Fenton,
Dr. F. H. Lewis,
Dr. B. Chance,
Dr. W. B. Lancaster,
Dr. W. B. Marple,
Dr. C. R. Holmes,
Dr. R. J. Curdy,
Dr. J. R. McIntosh,
Dr. B. L. Millikin,
Dr. L. H. Taylor,
Dr. G. T. Stevens,
Dr. T. Y. Sutphen,
Dr. L. S. Dixon,
Dr. F. W. Marlow,
Dr. Percy Fridenberg,
Dr. H. G. Sherman.

SUDDEN OBSTRUCTION OF THE CENTRAL ARTERY OF THE RETINA, BEING A CLINICAL RECORD OF FIVE CASES.

By G. E. de SCHWEINITZ, M.D. and T. B. HOLLOWAY, M.D.,

of PHILADELPHIA.

The record of the phenomena of central retinal artery-block, always interesting, may, even in the absence of opportunity for their study from the pathological standpoint, help our interpretation of the signs of this affection. Hence we report the following five cases, and will make special reference to (*a*) large central scotoma as an onset-symptom with smaller central scotoma as a permanent end-product; (*b*) extensive vasculitis and perivasculitis as the ultimate outcome of the original obstruction; (*c*) long periods of prodromal visual disturbances, in one instance in the form of recurring vertical hemianopsia; (*d*) the possible relation of spasm of the central vessels to the condition under consideration; (*e*) the presence of a small area of functionating retina surrounding the optic nerve entrance; (*f*) the temporary presence of a scotoma in the visual field closely corresponding to the position of this retinal zone around the nerve-head, which in some cases is ultimately the only area which retains visual perception; and (*g*) the therapeutic value of deep ocular massage, and the exhibition of nitro-glycerin.

Case 1. F. B., male, aged 52, college professor, was first seen in consultation with Dr. T. F. Branson, April 14, 1907.

Family History.— This contains nothing of importance, except that the patient's father died of some form of Bright's disease.

Personal History.— The patient has had the usual diseases of childhood, but in general terms has been healthy throughout his life; his habits have been perfectly good; syphilis and tuber-

culosis may be definitely eliminated. The patient has led an extremely active life from the literary standpoint, and has been an incessant worker in his college and devoted to his literary labors. In these respects he has been far from temperate, and is in consequence high-strung and in general terms "nervous."

On April 1, 1907, feeling the need of general examination, he consulted Dr. T. F. Branson, whose examinations demonstrated the presence of slight cardiac dilatation, with a systolic murmur at the base of the heart, rather soft in character. There were no palpable signs of sclerosis. The urine was light amber in color, had a specific gravity of 1010, contained some uric acid crystals, a trace of indican, a trace of albumin, and three epithelial, four granular and twenty hyalin casts in each 15 c. c. of fluid. One week later the trace of albumin continued, and there was decided increase in the number of casts.

Five years prior to the patient's present discomforts, his eyes were examined for the purpose of ascertaining whether or not glasses were required. They had never been used during his long and active literary career. The results were as follows:

O. D. — .50 c axis 165, 6/5
O. S. — .25 c axis 180, 6/5

To these cylinders suitable convex lenses were added for reading; there were no anomalies of the ocular muscles. Each disc was a vertical oval, rather gray in its deeper layers, with sharply marked scleral ring; the veins were fuller than normal; there were no pressure signs, but the light streaks on the retinal arteries were more distinct than normal.

Additional History.— On the 12th of April, 1907, after a period of proofreading persistently pursued for many hours at a time, the patient noted several complete obscurations of the vision of the right eye, lasting for a few seconds, which were attributed to "a disordered stomach." On the following day, toward its close, a similar obscuration of vision occurred which did not pass away, and for which on the following morning his physician

was summoned, who in turn asked one of us (Dr. de Schweinitz) to see the patient, about eighteen or twenty hours after the occurrence of the obscuration.

Examination of the eyes revealed the following conditions:

O. D. vision reduced to hand movements in the periphery of the lower field, the center of which was occupied by a large central scotoma, extending 20 degrees in all directions around the fixing point, and which merged into a complete loss of the upper field. The disc was slightly congested, the veins dark and uneven, and the lower temporal artery markedly uneven. A bank of fog (retinal edema) occupied the entire center of the eyeground, extending from the disc in all directions toward the periphery, and in the center exactly at the macula, was a typical, although not very brightly colored, cherry spot. There was no cilio-retinal vessel. The light reflex of the pupil was faintly preserved.

O. S. vision was normal, the veins were somewhat overfilled and slightly uneven, and near the nasal side of the disc there was a rather large, yellowish-white exudate.

The patient was put to bed, pilocarpin solution (gr. ss.$f\bar{3}\bar{i}$) instilled in each eye, and systematic finger massage instituted over the right eye.

At the expiration of sixteen days, when the next eye-examination was made, the vision of the right eye, excentric, was 1/100, the surface congestion of the disc had subsided, and all vessels were now small, but apparently carrying normally tinted blood and with no break in the blood columns, nor had there been any such breaks at the original examination. The bank of fog was somewhat thinner, but still plainly visible, as was also the cherry spot at the macula. The field of vision was somewhat concentrically contracted,—in other words, there had been a partial restoration of the lost upper field. The central scotoma, now about 10 degrees in diameter, was absolute (see Fig. 1). The vision of the left eye was normal, and the area of exudation at the nasal side of the disc had disappeared.

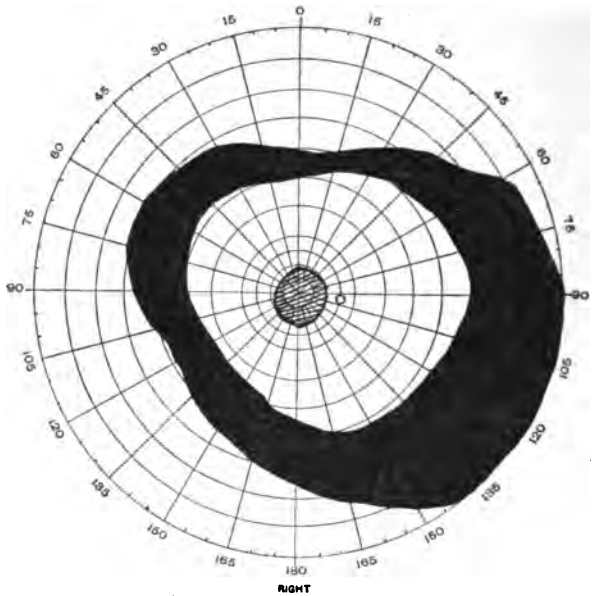

FIG. 1.

Case 1. Central scotoma sixteen days after obstruction of central artery; originally it had been just twice this size.

On the 17th of May the vision of the right eye had risen to 1/45, the disc was extremely pallid, and there was one small exudate at its outer margin. The general retinal edema had disappeared, but some fine macular changes were beginning to be visible. The central scotoma persisted.

On the 11th of June, vision had risen to 4/150, the head being turned slightly to the left, and the patient, to use his own expression, saw through the scotoma as if it had holes in it. All retinal vessels were shrunken, especially those on the disc surface, but no definite plug or obstruction could be detected in any one of them. In the macula there was an oval area of erosion and a few small white dots.

Five months later, when the next examination of the eyes

was made, namely, on the 15th of November, 1907, the nerve-head was entirely atrophic, all vessels were shrunken, especially those on the disc, and a faint thickening of the perivascular lymph-sheaths was evident. The field of vision was similar to that already described, and which is pictured in Fig. 1.

General examinations made shortly after the lodgment of the obstruction in the central retinal vessel, yielded the following results:

May 2, 1907: The cardiac sound had distinctly increased in harshness over the base, but there was a moderate improvement in the urine, which still contained a trace of albumin, but only three or four casts in each 15 c.c. of the fluid.

Three weeks later, namely, May 30, 1907, an examination of the cardio-vascular system was made by Dr. Alfred Stengel, who writes as follows:

"I find rather suggestive indications of arterio-sclerosis in the patient's complexion and the beginning whiteness of hair. There is moderate thickening of the peripheral retinal vessels, especially the brachial, and examination of the heart discloses a slight enlargement of the left side, that is, the left border is a little beyond the mid-clavicular line. The systolic sound is heavy and prolonged, and over the base and aortic area there is a harsh murmur, followed by an accentuated second aortic sound. The blood pressure is systolic, 135, and diastolic, 100. The condition seems to me to be one of moderate arterio-sclerosis, with probable involvement of the cerebral vessels rather in advance of the peripheral."

Additional notes as to the physical condition of the patient are furnished by his physician, Dr. Branson, as follows:

June 12, 1907: Specific gravity of the urine 1020; increased number of casts; entire absence of albumin.

June 26, 1907: Physical examination showed decided improvement in all respects; the cardiac area had decreased in size, the murmur was softer, and the urine about negative.

October 14, 1907: Cardiac area about normal, murmur very

soft, and patient apparently in excellent condition; no signs of progression in the vascular or cardiac conditions; urine the same as at last report.

The next and *last eye examinations,* made respectively April 27, 1908, and May 14, 1908, after the patient had made a most injudicious tramp which included rather extensive mountain climbing, showed that the vision of the right eye was 6/60 eccentric, the scotoma persisted, the disc was atrophic, with beginning shallow cup; all branches of the central vessels were small, but somewhat larger just as they left the disc than either on the disc itself or in the peripheral distribution. The vision of the left eye was normal, and there were faint signs of pressure, that is to say, indentation of underlying veins by the arteries.

As the result of this mountain climbing, there was for a time distinct cardiac dilatation, Dr. Branson reporting that the apex beat was diffuse and throbbing, and one half inch to axillary side of nipple and extending down to sixth rib. The sounds over the heart base were exaggerated and harsh, and the heart was missing every fifth beat. There was, however, no recurrence of either albumin or casts. Absolute rest in bed and appropriate medicines produced rapid and marked improvement. The blood pressure measured at this time was systolic 135, diastolic 90. The patient was commanded to take a complete rest, and has for the time given up most of his literary duties.

Summary.— Briefly summarized, the conditions in Case I may be stated as follows: Moderate arterio-sclerosis, with probable involvement of the cerebral vessels rather in advance of the peripheral; slight enlargement of the left side of the heart, with a harsh murmur over the apex and aortic area and accentuation of the second aortic sound; probably a certain amount of secondary nephritis, indicated by the presence of small amounts of albumin in the urine, which was of low specific gravity and contained also granular and hyalin casts; immoderate use of the eyes in literary labors; symptoms indicating sudden obstruction of the central

artery of the retina with most of its classical signs, followed by a partial restoration of vision, 6/60, in spite of the ophthalmoscopic appearances of optic nerve atrophy with shrunken vessels; preceding the onset of blindness, several obscurations of vision. The unusual symptom in the case was the presence from the beginning of a large central scotoma, which gradually shrank in size, but persists in the form of moderately produced central scotoma.

CASE 2. F. H., female, aged 32, colored, married, came to the Dispensary for Diseases of the Eye in the Hospital of the University of Pennsylvania, on May 24, 1907.

Family History.— The patient's mother is dead, the cause of death being unknown. Her father is living and well. She has four living children, who are in good health. There is no history of miscarriages.

Personal History.— The patient had measles in childhood, rheumatism twenty years ago, and malaria three years ago. For several months there has been some edema of the legs. The patient at times has suffered from slight dizziness, but has no flatulence, nausea or gastric pain; the bowels are regular. There has been no pain in the head, cough or dyspnoea; the appetite is good and sleep is regular; there is moderate leucorrhœa.

On May 20th, or four days prior to the patient's entrance into the hospital, she retired "with the sight of each eye as good as ever"; when she awoke on the morning of the 21st, the left eye was completely blind.

General examination revealed an enlarged hard, freely movable gland at the angle of the right jaw, one that had broken down at the angle of the left jaw, and one that was discharging in front of the left ear. There were numerous other enlarged glands on the left side of the neck. The lungs were negative. The heart was enlarged; the apex beat was in the fifth interspace outside of the nipple line; there was a mitral regurgitant murmur, and the second sound was decidedly accentuated; pulse 92; temperature 98; weight 111 pounds. There was a slight

pretibial edema, which, as already noted in the past medical history, had been more marked. Urine: specific gravity 1026; no albumin; no sugar, casts or crystals.

Examination of the Eyes.— O. D. V.= 6/6; the media were clear, the disc a vertical oval and surrounded by choroidal changes, spreading out into a wide area of absorption above, with some pigmentation at its borders, and two patches of choroidal atrophy on the nasal side. The whole fundus was slightly stippled.

O. S. V. = no light perception; the media were clear, on the disc surface the arteries were normal in size, but at its margin became much reduced in caliber. The veins were enlarged, dark in color and slightly tortuous. There were a few hemorrhages along the course of a venous twig coming from the macular region. The whole retina was edematous, and at the macula there was a small, round, dark red spot, the so-called cherry spot, although, as is usual in the colored races, dark in color. The direct light reflex of the pupil was lost; the indirect reflex preserved.

On the 8th of June, 1907, or nineteen days after the loss of vision, the edema was much less marked and chiefly produced along the vessels, the smaller branches of which were sheathed in white lines. The macular spot had become brownish-red in color and was mottled with fine, pin-point white dots. One week later the edema of the retina was still less marked, although present particularly in the central area, while small streaks of it were apparent along the vessels. The white spots in the macula had become larger, had coalesced and were more or less angular in shape. Two weeks later the edema had entirely disappeared, except near the disc along the upper and inner vessels. A marked perivasculitis was evident, and a granular mottling of the posterior pole of the eye was present on the nasal side, while through the macular region a number of small cholesterin crystals were noticeable, and the white dots in the region of the cherry spot were more pronounced than at previous examinations. One

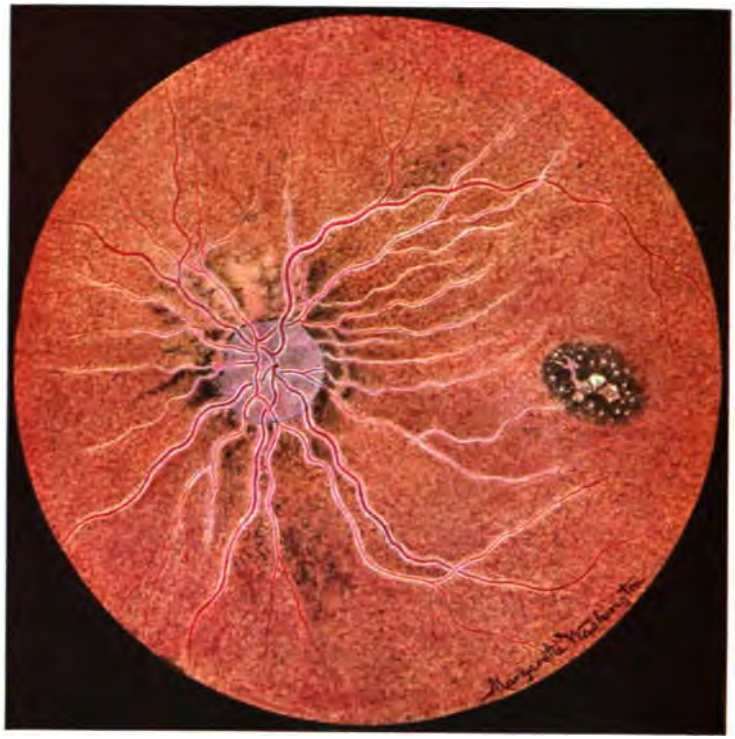

FIG. 2. Extensive perivasculitis following obstruction of central retinal artery.

FIG. 9. Fundus appearance of Case 5 fifteen months after obstruction of

week later, misty patches remained along the upper vessels, while all of the vessels at the disc were accompanied by white lines which were most apparent along the smaller branches, especially a horizontal branch which passed to the nasal side, and a smaller branch running down and out and passing upward toward the macula. This vessel about a disc's diameter from the disc could not be recognized as such, but was represented simply by a white line. The white dots in the cherry-spot-region were still larger, and the whole posterior pole of the eye was mottled.

Four weeks later the dark mottled spot in the macular region continued to have much the same appearance as has already been described, but its edges were less defined. There was decided increase of the perivasculitis, and along one moderate sized artery running down and out the white lines could be traced far out into the periphery. The mottling of the fundus seemed to be more marked than ever, and resembled somewhat the appearances occasionally seen in hereditary syphilis. The disc was white and atrophic.

One week later the accompanying water color (Fig. 2, colored plate) was made by Miss Washington. As will be seen, the disc is paper-white in color and shows advanced atrophy. It is surrounded by irregular pigmentation, and all of the vessels of the fundus are encased in white lines, those running out toward the macula having been converted entirely into white cords. In the macular region there is an oval, pigmented area dotted with white points, which have coalesced in the center into an irregular whitish mass. The general fundus is pigmented and mottled.

Summary.— Briefly summarized, the conditions in Case 2 may be stated as follows: Enlargement of the heart with disease of the mitral valve and accentuation of the second sound; adenitis, possibly tubercular, of the cervical lymphatic glands; suggestion of syphilis, but no definite proof of its presence; sudden loss of vision of the left side without prodromal symptoms, and with most of the typical signs of obstruction of the retinal artery; complete loss of vision from the beginning without the slightest

return of light perception; ultimately complete atrophy of the optic nerve; and as an unusual sequel most extensive vasculitis and perivasculitis of the retinal vessels, the macular branches being practically converted into a series of white lines.

CASE 3.— M. T., female, aged 32, unmarried, masseuse, was admitted to the medical ward of the University Hospital, September 15, 1906.

Family History.— The patient's father and mother are living and in good health; one brother died of hip disease, one sister of tuberculosis of the lungs, and another sister in infancy; two brothers and one sister are living and are in good health.

Personal History.— The patient has been in poor health most of her life. She had the usual diseases of childhood, as well as several attacks of gastritis. She has had three attacks of acute rheumatism, the first when she was 14 years old, the second when she was 16, and the third when she was 29, and the duration of these attacks was from two weeks to three months. During the intervening periods, there were several slight attacks of chorea. The patient has always been subject to attacks of palpitation, and to other attacks which are described as "smothering," during which breathing was performed with great difficulty. Two years prior to her entrance into the hospital, following unusual exertion, she had a slight hemorrhage from the lungs lasting for two hours. Examination at that time by Dr. Stanton demonstrated an area of dullness in her right lung, but the hemorrhage was attributed to congestion and not to ruptured vessels.

The patient has been myopic since childhood, and the tendency to myopia is inherited through the mother's line; one sister wore glasses for short-sightedness. Twelve years ago the patient was stricken with sudden blindness while walking home from school. It is maintained that this blindness was absolute in both eyes, although she appears to have managed to walk several squares alone, and then waited for schoolmates, with whom she finished the walk without betraying the blindness. This attack lasted half an hour, and disappeared as suddenly

as it had come. For the past five or six years, she has had frequent attacks of haziness of vision of the left eye, but never of the right. These periods of hazy vision lasted for a few seconds.

Additional History.— On the 12th of September, 1906, the patient was admitted to the wards of the University Hospital, with the statement that on the 7th of that month, or five days prior to her admission, while giving massage, she became suddenly blind in the left eye. There were no immediate premonitory symptoms and no hemianopsia, or any other form of half vision, although, as previously stated, for some time, and particularly for a year prior to this loss of sight, there were brief periods of filmy vision. In addition to the blindness of the left eye, the patient had marked gastric distress, gaseous distention of the stomach, dyspnœa, and edematous ankles.

Physical examination at that time by Dr. Morehead, the resident physician, gave the following results: The patient was a well-nourished woman, with good bony and fair muscular development, and considerable panniculus adiposus, especially over the abdomen. The skin was clear and gave evidences of moderate anemia. There was no cyanosis or jaundice. The right pupil reacted promptly to light and accommodation; the left pupil was semi-dilated and fixed; there was lateral nystagmus. A slight lateral curvature of the spine was evident. Examination of the lungs revealed no notable lesions. The deep cardiac dullness on the right side extended ¾ inch to the right of the sternum, above to the third rib, and on the left side nearly to the anterior axillary line. In the fourth interspace 1¼ inches from the left margin of the sternum there was a rough, presystolic murmur, a loud first sound, a faint blowing systolic murmur and a long rumbling diastolic murmur. At the apex there was a loud first sound and a faint systolic murmur. A systolic murmur, loud and blowing in character, was well heard in the second interspace just to the left of the sternum, and here the second sound was markedly accentuated and reduplicated; at times the cardiac action was quite irregular. There was

some impairment of resonance and prolongation of the expiration below the right apex. The liver dullness extended from the level of the fifth rib to the costal margin in the mid-clavicular line. The organ was not palpable; the lower border of the stomach, not inflated, was half an inch above the level of the umbilicus. Examination of the blood revealed hemaglobin 73, red blood cells 4,200,000, white blood cells 6,960.

Examination of the Eyes.— V. of O. D. with —3 sph. ⌒ — 3 cyl., axis 15, 6/12; pupil reactions normal; visual field for form and colors practically normal. The disc was a vertical oval, of good color, the retinal blood vessels of normal size and carrying normally tinted blood. There was lateral nystagmus.

V. of O. S. possibly faint light perception in the upper field. The ophthalmoscope revealed the usual appearances of stoppage of the central artery of the retina, namely, markedly contracted vessels, wide-spread edema of the retina, and a cherry spot in the macula. The disc was pallid, its margins cloudy, and shrinking of the arteries in all directions was most pronounced.

The patient was not again seen until April 25, 1908, when an ocular examination in the Dispensary for Diseases of the Eye, revealed the following conditions: Corrected vision of O. D. 6/12. There was practical absence of ophthalmoscopic lesions except a general rarefaction of the choroid coat.

V. of O. S. entirely absent. The media were clear, the disc in the stage of advanced white atrophy, both sets of vessels being markedly contracted in their entire distribution, no one set more contracted than the other, and no spot indicating any local obstruction. There were slight evidences of perivasculitis along the vessels on the disc.

Summary.— Briefly summarized, the conditions in Case 3 may be stated as follows: History of acute rheumatism and chorea; one attack of pulmonary hemorrhage; no tuberculosis demonstrated; enlargement of the heart, with systolic and presystolic murmurs, and accentuation of the second sound; sudden loss of vision of the left eye with no immediate premonitory

symptoms, but with a history that twelve years prior to its occurrence, there was one temporary period of absolute blindness in both eyes, lasting for half an hour, and during five or six years prior to the ultimate loss of vision there were many brief attacks, lasting but a few seconds, of hazy vision of the left eye, which had been particularly marked in the year before the final loss of vision developed; characteristic signs of obstruction of the central artery of the retina with at first faint light perception in the upper field, but within a short time complete blindness, which has remained permanent; final ophthalmoscopic atrophy of the optic nerve, marked contraction of both sets of vessels, and faint perivasculitis.

CASE 4. O. W., male, aged 65, broker, was first seen in consultation with Dr. Morris J. Lewis, May 27, 1907.

Family History.— The patient's father died suddenly of heart disease at the age of 71, his mother lived to the age of 80, and in general terms, the family history is good.

Personal History.— This is exceptionally good. As a child and as a young man the patient was always healthy. During service in the Civil War, he suffered from diarrhœa and occasionally from chills and fever. Recently he has had attacks of dizziness while walking, and he has always been a great walker, and in general terms devoted to outdoor exercises. There was no history of specific taint. The patient was accustomed to take six ounces of alcohol daily in the form of whiskey. On the 27th of May, while reading index cards which were rather hard to decipher, the vision of the right eye was suddenly obliterated. On the preceding day he had had one short period of blurred sight, to which no attention was paid.

General Examination.— The patient is a tall, finely formed, vigorous man. The pulse beat was 60 per minute, and there was no marked atheroma noticeable in the peripheral vessels, no clang of the second sound, but there was a soft apex systolic murmur. The liver dullness extended below the ribs, and there was some edema of the legs. The urine was amber-colored, clear, with

acid reaction and a specific gravity of 1012. It contained a faint trace of albumin, but no sugar. With the microscope a few epithelial cells, some leucocytes, cylindroids and mucous threads were detected.

Examination of the Eyes.— This was made thirty minutes after the loss of vision recorded in the preceding paragraph, and revealed the following conditions: V. of O. D. described by the patient as "inability to see a thing"; he probably had faint light perception. Pupil reacted slightly to direct illumination. There was complete obliteration of the entire arterial tree, all of the

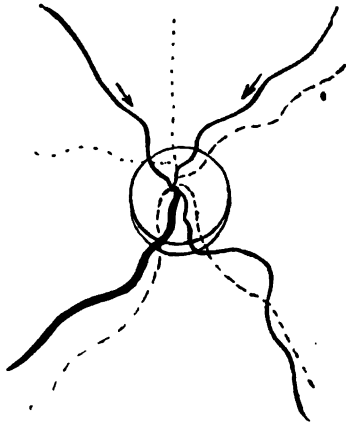

FIG. 3.

Case 4. Complete obliteration of entire arterial tree; reversal of blood in upper veins; distension of lower temporal vein.

branches being emptied of blood. The lower temporal vein was somewhat distended with dark blood; all other veins were shrunken, and in the veins above the disc the current was reversed and the blood columns broken by bubble-like interspaces (Fig. 3). The vision of the left eye was 6/9, and with his reading glass + 3 ⌒ + .50 c axis 45 0.50 was read at 30cm. With the exception of some distention of the retinal veins and a little tendency to indentation by overlying arteries, there were no lesions.

The patient was immediately placed in a recumbent posture and deep massage of the eye practiced for ten minutes. At the expiration of this time there was practically a complete restoration of the blood current in all the previously emptied vessels, except one artery which passed directly upward between two branches of the temporal vein, and one vessel which passed directly outward (Fig. 4). There was not at this time, nor sub-

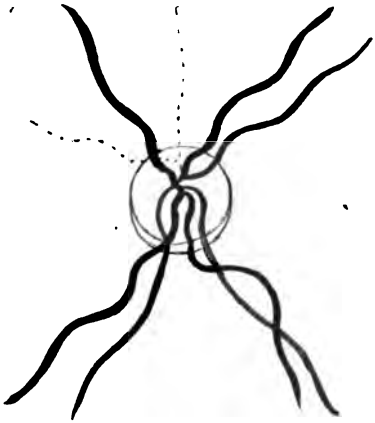

FIG. 4.

Case 4. Restoration of arterial circulation after 10 minutes of massage, except in arteries marked by dotted lines.

sequently, any edema of the retina, nor the formation of a cherry spot at the macula. Three hours later, the massage having been continued at intervals and pilocarpin having been instilled into the eye, the retinal vessels were even fuller than has just been described, except in the upper vessel already named. The peripheral field was normal above, contracted below, and contained two wedge-shaped scotomas, one directly below the fixing point, and one upward and outward from the blind spot (see Fig. 5). Four days later the conditions described were similar, except that the lower scotoma was somewhat smaller and the contraction of

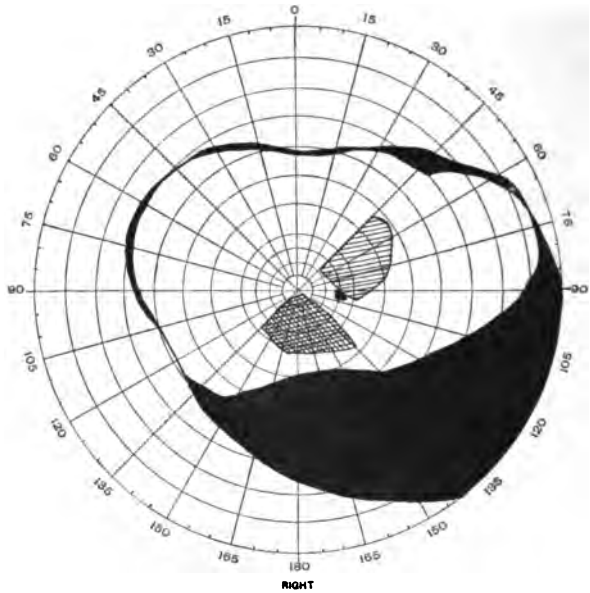

FIG. 5.

Right field of Case 4, showing the paracentral scotomas and contraction of lower field three hours after partial restoration of circulation following massage. Compare with Fig. 4. Left field normal.

the lower field less marked (see Fig. 6). V. was now 6/60 by tipping the head slightly forward. At the expiration of two weeks, the treatment having consisted in the administration of iodides, nitroglycerin, and interrupted massage, the vision rose to 6/9, the head being tipped slightly forward. The scotoma remained unchanged. There was apparently no alteration in the caliber of any retinal vessel, except the upper temporal artery, which just beyond the disc and as far as it could be followed, was contracted.

The last ocular examination was made June 18, 1908, or a little more than one year after this sudden obstruction of vision had occurred, with the following results: The disc was normal in color; all retinal vessels, both arteries and veins, were filled with normally tinted blood, except the upper temporal artery,

which began to diminish in caliber just beyond the porus, and at the edge of the disc was especially contracted with a curious half twist in its course, beyond which it regained slightly in diameter, but remained diminished in size as compared with the other retinal arteries as far as it could be traced to the periphery. The field of vision was as in Figure 7. The letter vision, by tipping the head slightly forward, was 6/9.

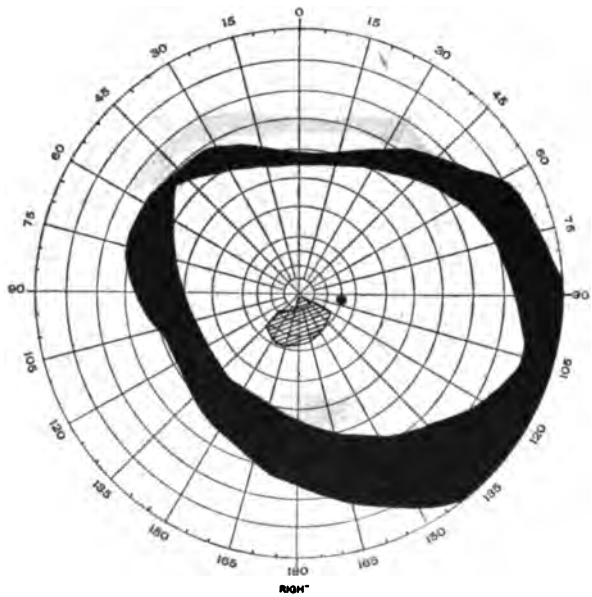

FIG. 6.

Case 4. Visual field four days after obstruction of central artery of retina; paracentral scotoma. Compare with Fig. 5.

Summary.— Briefly summarized, the conditions in Case 4 may be stated as follows: No apparent arterio-sclerosis, or not more than is usual at the age of life of this patient; general condition extremely good, with the exception of a faint apex, systolic, cardiac murmur, and a trace of albumin in the urine; sudden loss of the vision of the right eye after one short period of blurred sight on the day preceding its occurrence. Examination

thirty minutes after the onset of the blindness demonstrated probable faint light perception and complete obliteration of the entire arterial tree, all branches being emptied of blood, together with shrinking of all veins, except the lower temporal vein, which was distended with dark blood, and the two veins above the disc in which the blood current was reversed, and the columns

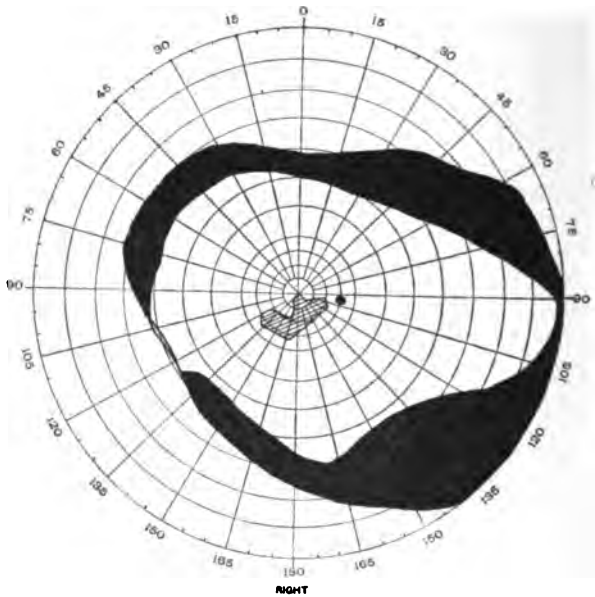

FIG. 7.

Case 4. Visual field one year after obstruction of central artery of retina; vision 6/9.

broken by bubble-like interspaces; no edema of the retina, and no formation of cherry spot in the macula; complete restoration of the blood currents in the previously emptied vessels after ten minutes of deep massage of the eye, except in one artery which passed directly upward between the two branches of the upper temporal vein, and in one vessel which passed directly outward toward the macula; three hours later even more perfect restoration of the blood currents than has just been described, except in the upper vessel already named; normal extent of the visual

field upward but decided contraction below, together with two wedge-shaped scotomas, both paracentral, one directly downward and the other one upward and outward from the blind spot, the latter occupying a position similar to the area of preserved vision which is not infrequently found in cases of sudden obstruction of the central artery of the retina; gradual restoration of the entire field, together with improvement of central vision, which ultimately reached 6/9, and now more than a year after the obstruction of the central artery, a moderately contracted visual field with a somewhat irregularly shaped paracentral scotoma in the region downward, originally occupied by the larger wedge-shaped scotoma; present ophthalmoscopic appearances entirely normal, except contraction of a branch of the temporal artery of the retina which passes directly upwards and curves downward toward the macula; no perivasculitis and no hemorrhages.

CASE 5. L. F., male, aged 19, was first seen December 4, 1906.

Family History.— The patient's parents are living; his mother has been subject to rheumatic pains. Five brothers and three sisters are living and in good health; five sisters died in infancy.

Past and Personal History.— The patient has never been robust; as a child he had measles and diphtheria. He had spermatorrhæa for about one year. He has not suffered from headaches, his digestion has been fairly good, although at times he has had gas-formation; the bowels have been regular. He has been subject to tonsillitis, but never has had rheumatism. He has had enlargement of the cervical glands.

For the past two years the patient has had attacks of visual disturbance which came at irregular intervals, once or twice a week, possibly but once in four weeks, and which persisted for one to two minutes. The first thing detected was a confusion of objects seen by the right eye. The vision would then become dim, and he only "saw with half an eye." If he looked at an object he could see only the upper half; less frequently only the

lower half. Upon one occasion this phenomenon was apparent to the left eye. After the hemianopsia had persisted about a minute, throughout the darkened area a series of irregular bright lines would be noticeable, followed by a clearing of this darkened area, after which for a limited time the originally obscured portion of the field would have a "more rosy hue and would seem brighter than the other half." For the relief of this condition he visited another hospital in January, 1906, but nothing abnormal appears to have been detected.

On December 6, 1906, while the patient was dressing, the vision of his right eye became dim. It appeared as though "there was a veil before my eye that was getting thicker and thicker." In a few minutes he was practically blind.

General Examination.— The abdomen was well developed. The edge of the liver was sharp and could be felt two fingers' breadth below the costal margin. The femoral and inguinal glands were distinctly enlarged; the cervical and axillary glands palpable; the epitrochlear gland was not enlarged. The vocal fremitus was good, and the resonance over both lungs normal. The cardiac impulse was moderately forcible, although diffuse, and was most marked in the fourth interspace slightly within the nipple line. Cardiac dullness began in the second interspace, extending to the left to the nipple line, on the right to one inch to the right of the sternum. There was a slight and inconstant systolic puff heard at the apex, and to some extent over the pulmonary region, most pronounced when the patient was standing. There was an accentuation of the second sound at the apex and in the pulmonary area. The systolic pressure was 123; the pulse 76. Examination of the blood and of the urine yielded negative results.

Examination of the Eyes.— V. of O. D. equalled hand movements in a small area on the temporal side. The media were clear, the arteries were reduced to threads and the veins about normal in size. The entire eyeground was covered with a white fog, which was most pronounced above, below, and to the

temporal side of the disc, which was pallid in color. At the macula there was a typical cherry red spot. These ocular examinations were made about eight hours after the first visual obscuration was noticed. The visual field is depicted in Fig. 8, and was taken by means of two candles. It represents only a small patch on the temporal side up and out from the blind spot.

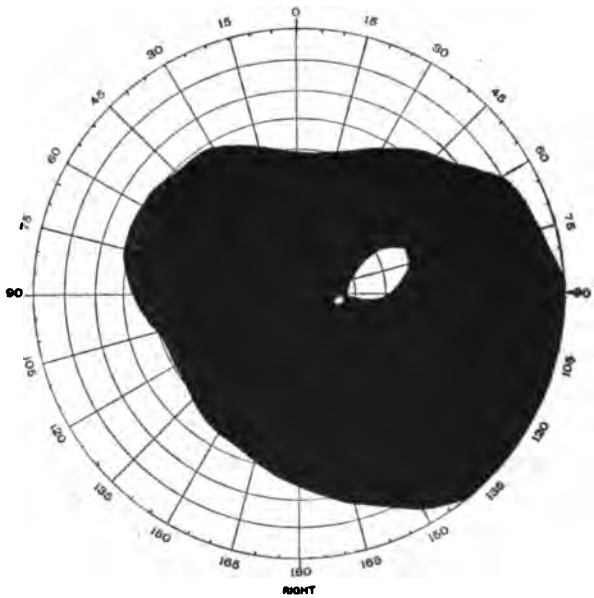

FIG. 8.

Case 5. Small preserved field on temporal side.

On the following day the conditions were much the same, with perhaps a greater extent of the retinal edema and even more pronounced reduction in the size of the blood vessels, in which there was no reversal of the blood currents. Pressure upon these vessels almost obliterated them, but did not cause pulsation.

V. of O. S. 6/6; refraction hyperopic; media clear; veins full; general eyeground in fair condition.

The treatment consisted in massage of the eyeball, the internal administration of iodid of sodium and nitro-glycerin.

On the day following the obscuration of vision, a large flame-shaped hemorrhage appeared upon the surface of the disc. Four days later the edema about the disc and in the macular region was less marked. The cherry spot, somewhat darker in color, appeared to be larger than at the original examination. A few small hemorrhages were detected in the immediate neighborhood of the macula.

On January 3, 1907, or eleven days after the loss of vision, a beginning white atrophy of the disc was already most marked. Cholesterin crystals were evident in the macula. Vision at this time and during subsequent examinations, as late as the 14th of January, 1907, was 6/150 eccentrically. The vision of the left eye continued to be normal.

Although the patient was seen from time to time, no careful re-examination of his eyes was possible until the 18th of March, 1908, that is to say, about fifteen months after the loss of vision. The results of this examination are as follows: V. of O.D. = ; Snellen 45 can be detected when held one meter from the eye upward and outward. The media were clear; the disc exhibited advanced atrophy. In the macular region there was a granular round spot about two-thirds the size of the disc, a darker red than the surrounding fundus and containing a number of white punctate spots, among which could be detected some cholesterin. Both sets of vessels were much reduced in caliber (Fig. 9, colored plate). The general appearance of the fundus is depicted in the accompanying water color. Many of the vessels were lined by white borders, and these were especially noticeable along the smaller branches which proceeded from various directions toward the macula. Most of these branches could be ultimately traced only by means of the white lines, the vessels themselves, that is to say, as carriers of blood-streams, being indistinguishable. The eye was deviated slightly upward and the visual field obliterated, except for a small area on the temporal side surrounding the blind spot.

Examination of this eye according to the plan suggested by

Fischer, demonstrated that light was perceived just as soon as it fell upon an area immediately surrounding the entrance of the optic nerve. In order to make this test, a screen in which a hole 5 mm. in diameter had been made, was placed between the source of light and the eye to be examined. Through this aperture the light was reflected by means of an ophthalmoscope mirror which enabled the observer to note accurately upon which part of the retina it impinged. Corresponding to this functionating area are the visual fields exhibited in Figures 10 and 11.

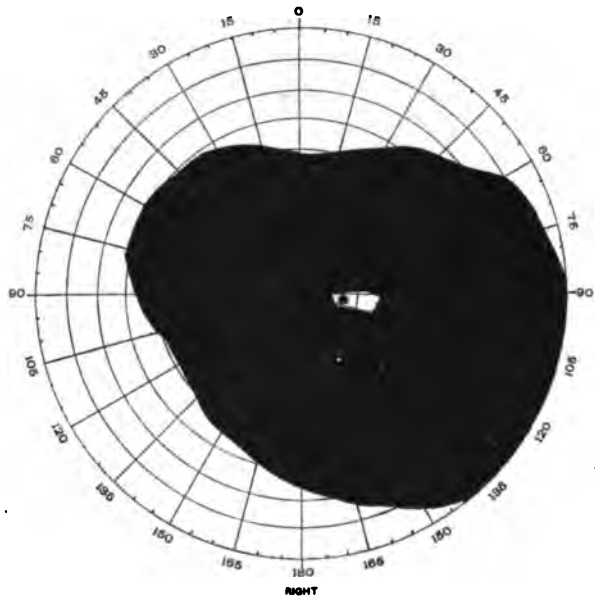

FIG. 10.

Case 5. Small visual field representing area of functionating retina surrounding blind spot.

Summary.— Briefly summarized, the conditions in Case 5 may be stated as follows: Some enlargement of the cervical glands; distinct enlargement of the femoral and inguinal glands; history of tonsillitis but no rheumatism; no marked cardiac disease, and only an inconstant systolic murmur heard at the apex and to some extent over the pulmonary region; loss of the

vision of the right eye, immediately preceded by a few minutes of dim vision, but for two years before this occurrence numerous attacks of visual disturbance coming on at irregular intervals, once or twice a week and persisting for one or two minutes; these attacks of visual disturbance manifested themselves in the form of a vertical hemianopsia, sometimes with obliteration of

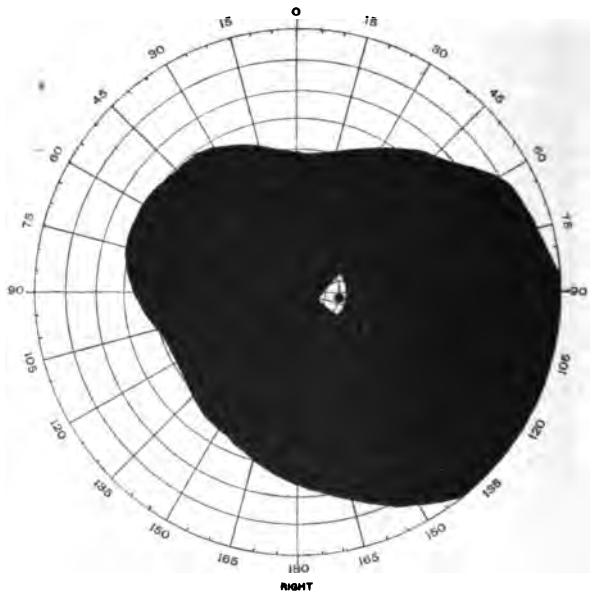

FIG. 11.

Case 5. Small visual field representing functionating area of retina surrounding blind spot. Left field normal.

the upper and sometimes with obliteration of the lower half of the object under observation, followed by a gradual clearing of the darkened area, which before vision was completely restored assumed temporarily a rosy hue and seemed brighter than the other half of the visual field. Examination of the affected eye was made about eight hours after the visual obscuration began, and presented the typical signs of obstruction of the central artery of the retina, namely, contracted vessels, area of white edema and cherry red spot; vision was reduced to the

perception of hand movements in a small area of the visual field on the temporal side; gradual subsidence of the acute symptoms and the development of post-embolic atrophy, with the preservation, however, of the visual area already named, which persists at the present time, more than a year after the occurrence of blindness, and which is indicated in the maps of the visual field herewith presented.

Remarks.— That central scotoma as part of the symptomatology of obstruction of the central artery of the retina is a comparatively uncommon phenomenon is indicated by the researches of R. Fischer[1], who at the time he wrote (1891) could find only eight genuine and four doubtful cases. From his analysis he concludes that "embolism (obstruction) of the macular arteries should be regarded as the cause of the scotoma in most of the cases, but not with certainty in all of them." The same explanation is accepted by other writers (Snell, Hawthorne, and others). For those cases to which apparently occlusion of the macular arteries does not apply, Fischer has suggested the following theories: (*a*) In addition to obstruction of the central artery, occlusion of one or other of its branches or accompanying vessels in such a manner that the central opticus-fibers are affected, and a defect appears in the center of the field of vision; (*b*) special individual susceptibility of the center of the retina to defective nourishment, in its turn dependent upon the diminished force or supply of the blood-streams; (*c*) cilio-retinal artery occlusion, causing a loss of that central portion of the visual field which in other instances the permeability of such a vessel, if present, sometimes preserves when the central artery is obstructed (Knapp); (*d*) actual demonstrable lesion in the macular region, for example, a hemorrhage. None of these theories satisfactorily explains the condition in Case I, in which a large central scotoma merged or "broke through" into loss of the upper field, and was the prominent symptom of the onset

[1] Ueber Embolie der Arteria Centralis Retinae, Leipzig, 1901, p. 202.

of blindness. Except for the bank of retinal edema and the cherry spot in the macula, the signs were somewhat analogous to those of retrobulbar neuritis; indeed, in some cases of the latter affection, according to Fischer, these appearances have been seen. Twenty hours after the blindness the surface of the disc was congested, and the veins dark and uneven; the arteries were not materially shrunken and one of them (the lower temporal) was markedly uneven. There was no evident occlusion of the macular vessels, and no lesion in the center of the retina other than the cherry spot. It is conceivable, we think, if the obstructing tissue, or obstructions additional to that in the central vessel, as Fischer suggests, did not by pressure cause this scotoma, that the central vessel lesion originated an edema which spread along and compressed the axial fibers of the optic nerve with sufficient force to invalidate their function and interpret itself by this large central visual defect. Subsequently atrophy of these fibers took place, and a smaller absolute central scotoma was the ultimate effect.

The inferior paracentral scotoma in Case 4 is to be explained by interference with macular vessel supply, which, indeed, is still evident in one small branch which curves upward and descends toward this region.

Careful examination of the clinical histories of patients who have suffered from sudden obstruction, either of the central artery of the retina, or of one of its branches, will usually develop the fact that there have been periods of temporary blindness, sometimes of exceedingly short duration, of the affected eye prior to the final partial or complete loss of sight. Indeed, sudden loss of vision preceded by such temporary obscurations, to use the language of Hawthorne, brings the diagnosis of embolism, or perhaps, more accurately, obstruction of the central artery of the retina, definitely under suspicion. At one time, it will be remembered, no less an authority than Priestley Smith thought that these temporary obscurations might be utilized to elaborate a differential diagnosis between thrombosis of the

retinal artery and embolism of this vessel, inasmuch as he stated that the former condition was apt to be preceded by previous attacks of temporary blindness in the affected eye, and giddiness, faintness, and headache — symptoms which are usually absent, in the latter condition. To what exactly such periods of temporary obscuration should be credited, is not definitely known; perhaps they should be attributed to alterations in the caliber of the central vessel, or to spasm in association with endarterial disease which subsequently is the cause of the permanent obstruction; perhaps to spasm alone, which, again to quote Hawthorne, is a speculative suggestion, and which from the investigation of Coats, seems to be eliminated as a factor; perhaps, finally, to temporary arterial collapse, as has been reported by Hoppe, the collapse being so great that for the time there is contact between the arterial walls, forming a sort of valvular closure which depends upon a temporary lowering of arterial pressure, so that such pressure is overcome by the intraocular tension.

That such temporary periods of absolute blindness lasting from a few minutes to as much as half an hour, during two to twelve years, may precede the ultimate total obstruction of the central artery is evident from Cases 3 and 5. It is quite impossible to believe that small obstructions, which afterwards passed away, could have been the cause of these attacks of blindness for such long periods of time, that is to say, obstructions in the form of emboli or thromboses. Exactly how to explain them when they occur in the form of a vertical hemianopsia, as they did for two years in Case 5, is not easy. They could hardly have depended upon disturbance of the circulation in the occipital lobes, or at the base of the brain, and we are led to believe that the theory of arterial wall collapse or spasm, local in the retina, or the central artery, furnishes the best explanation of this somewhat unusual phenomenon.

The opportunity of observing the fundus of the eye during an attack of transient blindness believed to be due to spasm of

the retinal artery, is comparatively infrequent. Within the last two years, several papers concerned with the subject have been published, notably those by Zentmayer[1], D. F. Harbridge[2], and R. A. Lundie[3]. Reference to Hoppe's case[4] of apparent embolism of the central artery of the retina, attributed to arterial collapse has already been made. While it is true, as Coats[5] maintains, that "there is at present no pathological proof that the obstruction may be caused by spasm apart from endarteritis," it is equally true from the clinical standpoint that the effect of spasm must be reckoned with. Harbridge's patient was repeatedly examined, not only by Harbridge himself, but also by Zentmayer, de Schweinitz, and others, and the following phenomena observed: At the beginning of an attack there was gradual diminution in the caliber of the inferior temporal artery, rapidly succeeded by the other retinal arteries, until they were completely collapsed. Following quickly upon the arterial change, the veins underwent a similar process. The nerve-head became pallid, the retina somewhat hazy. The retina vessels looked like ribbons against the fundus. This condition continued about four minutes. Then the inferior arteries began to fill, quickly followed by the others, and by the veins, the inferior becoming enormously distended. Sight was restored immediately upon the filling of the vessels, while the pupil was still dilated.

Through the courtesy of Dr. Harbridge, we have been permitted to observe closely similar appearances in another of his patients, a woman aged about 35, whose case history he has not as yet reported. The obliteration of the entire arterial tree of the right retina of the patient described in Case History No. 4, and which remained complete for about forty minutes, at the expiration of which time the current was restored, except in one artery which passed directly upward, may be explained by assuming the presence of spasm in association with endarteritis,

[1] Trans. Section on Oph., A.M.A., 1906, p. 582.
[2] Ophthalmology II, 1906, p. 647.
[3] Ophthalmic Review, XXV, 1906, p. 129.
[4] Archiv. f. Ophthal., LVI, 1, 1907, p. 177.
[5] Royal London Ophthalmic Hospital Reports, XVI, 1904-1906, p. 303.

which under the influence of treatment relaxed, except in the vessel already named in which the obstruction remained permanent; or by assuming that the obstruction (embolus or thrombus) originally located in the central vessel was dislodged by the massage until it reached the small artery passing upward, where it remained.

It is a matter of observation that in a number of cases of obstruction of the central artery of the retina a small area of vision is preserved on the temporal side of the field, and this was notably evident in Case 5 of the present series. We were able to confirm Fischer's observation that under these circumstances the perception of light is confined to a small area around the papilla by noting that the moment the ophthalmoscopic image of a flame fell on this region it was at once appreciated, although the rest of the fundus was unresponsive. Coats, referring to this phenomenon, says he has not met with a perimeter tracing to show the exact position of the functionating area, but we have succeeded, with the aid of our exceedingly intelligent patient, in securing such a map which exactly represents the area in which light was perceived (Figs. 10 and 11). The most satisfactory explanation of this condition is, to use the language of Coats, that the capillary anastomosis between the ciliary and retinal vessel systems in this region is capable of keeping up the nutrition of a small zone of retina in the immediate vicinity of the disc.

An interesting visual field phenomenon in Case 4 was the temporary presence (about two weeks duration) of a scotoma similar in shape and position to that of the area of preserved vision representing the region around the papilla which remained functionally active in the retina of Case 5. It is true, it did not surround the normal blind spot, but extended somewhat up and out from it, and in this respect corresponds in shape to the first map of the visual field of Case 5, *i. e.*, the area of preserved vision (Fig. 8). It would seem possible, therefore, that this scotoma may have been due to a temporary failure of circulation in the

capillary anastomoses between the ciliary and central vessel systems before referred to, just as the preservation of circulation in these vessels accounts for the area of retained vision in other cases. It is also possible that it was caused by obstruction of a small lateral branch whose collapse was noticeable during the earlier weeks of the visual disabilities of this patient.

Concerning the value of deep massage of the eye for the restoration of the circulation after obstruction of the central artery of the retina little need be said. It has been practiced by a number of surgeons abroad, and has been particularly advocated in this country by Würdemann, Gifford and others. It is regarded as irrational by W. T. Shoemaker[1], who thinks the pressure is liable to stop the flow of such blood as remains in the vessels, and furnishes favorable conditions for further agglutination of the vessel walls. He believes in the efficacy of the nitrites, and regards with favor forced muscular action of such a character as to accelerate the heart and the peripheral circulation. A careful examination of the literature, however, indicates that a number of cases have been most favorably influenced by deep massage of the eyeball, as was notably the case in one of the patients of the present series, in whose retina after ten minutes of such massage there was almost complete restoration of the previously emptied arterial circulation. It is quite possible, as Jackson[2] points out, that the good results under these circumstances depend upon the fact that the original obstruction was not due to embolism or thrombosis, but to arterial collapse, or to spasm, and that it is not proved that an embolism has by this means become dislodged or a thrombus has been removed. Be this as it may, there is enough evidence to render the trial of this procedure worthy of respect, and it would seem to us that its efficiency is enhanced by the previous instillation of pilocarpin. The indication for the use of the nitrites is evident.

---

[1] Journal of the American Medical Sciences, 1904, p. 677.
[2] The Ophthalmic Year Book, 1904, p. 119.

The remaining case of the series, or the one in which an extensive vasculitis and perivasculitis was the ultimate outcome of the original obstruction, requires no special comment, except to point out its unusualness. It would seem to indicate that the original process had depended upon systemic intoxication, probably specific, although not definitely established.

DISCUSSION.

DR. F. H. VERHOEFF, Boston: I should like to offer a possible explanation of the central scotoma in Dr. de Schweinitz's case. Microscopic examination shows in most cases obstruction of the central artery within or immediately behind the lamina cribrosa. In some cases the obstruction is farther back (drawing on the board). If it is here (within the lamina) the collateral circulation is good and the nerve fibers do not suffer, but if it is far back here the collateral circulation is poorer and the nerve fibers would be injured. Owing to the fact that the macular fibers are the most vulnerable a central scotoma would result.

In connection with the question of intermittent vision, it seems unlikely to me that muscle spasm could be a factor in the arterio-sclerosis cases. In these the muscle fibers are degenerated and the phenomenon would seem more likely due to changes in blood pressure. In younger people, however, muscle spasm of the central artery no doubt may occur.

EMBOLISM OF A MACULAR ARTERY AND THROMBOSIS OF SUPERIOR AND INFERIOR RETINAL ARTERIES, IN A CASE OF EMBOLIC SOFTENING OF THE BRAIN.

WILLIAM T. SHOEMAKER, M.D.,

PHILADELPHIA.

The patient from whom the eyeball herewith described was obtained, was a Jewish woman 41 years of age. She was admitted to the German Hospital, Philadelphia, November 22, 1907, and died there twelve days later.

The medical diagnosis was uremia, chronic parenchymatous nephritis, broncho-pneumonia, and left-sided cerebral disturbance. which autopsy proved to be softening with hemorrhage.

The ophthalmic diagnosis was *embolism of a macular artery*, a condition which has been confirmed by the pathological examination. It may be questioned whether or not the obstruction found is an embolus or a thrombus, but the weight of evidence favors the former.

The case is of interest in that the eyeball, which was removed a few minutes after death, contained a condition difficult to secure for examination in the acute stage, and while the exact age of the obstruction is not known, the complete cycle of events pertaining thereto, was but eighteen days. It is probable moreover, that the eye condition was subsequent to the brain condition which marked the fatal onset.

Six days before admission to the hospital, the patient while sitting on a chair, suddenly became faint and fell to the floor. She had convulsive movements of the arms and legs lasting about ten minutes. She then passed into a semi-comatose state, in which condition she remained until death. From her husband it was learned that she had had "kidney trouble" for the past five

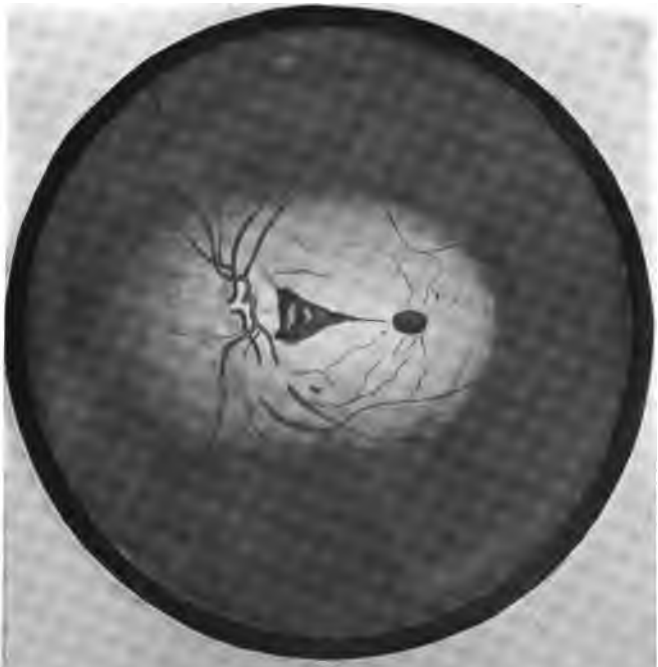

Embolism in a Macular Artery.

Sketch made two days before death of patient.

years, and frequently had fainting spells similar to the present attack, but from which she had always recovered within a few hours.

Examination of the patient showed much emaciation. Eyelids held in half closed position. Right labio-nasal fold obliterated; right side of upper lid drooped over mouth cavity. Jaw dropped, and breathing through mouth. The limbs were moved in response to irritation. The heart sounds were disordered, there being slight presystolic and systolic murmurs heard at the apex. The second aortic sounds were valvular and relatively accentuated; there was no thrill.

The left arm and leg were frequently moved, there was no spasticity; the reflexes on that side were normal. The right arm and leg were not voluntarily moved. Both were spastic; the knee-jerk was exaggerated; the Babinski and Gordon reflexes were both present. The broncho-pneumonia supervened November 29th, five days before death.

The notes from the Pathological Department of the German Hospital concerning this case are in brief as follows:

The Urine — contained albumen ½ volume. No sugar; urea varied from .022 grms. to 1 cc., to 2.5 per cent.

Autopsy — 12/4/1907.

1. Chronic interstitial nephritis.
2. Broncho-pneumonia.
3. Softening and hemorrhage of the brain (left hemisphere) with edema of the meninges, and foci of round celled infiltration.

Section of Kidney — showed also chronic parenchymatous nephritis (late stage) with foci of sclerosis.

Liver — congestion — slight fatty infiltration. Foci of necrosis.

Spleen — Large interstitial hyperplasia.

The examination of the eyes upon day of admission showed both sides, conjunctiva pale and clear; no lacrimal disturbance; no deviation or apparent paralysis. The pupils were 2/3 and evenly dilated; reaction to light was not prompt.

Ophthalmoscope O. D., Media clear, disk well defined, vessels of uniform calibre, arteries rather pale, light streaks present; no hemorrhages or exudations.

O. S., Media clear, disk margin blurred; vessels uneven and of variable calibre; the veins are full. At the posterior pole is an extensive area of edema in the center of which is the macula, presenting the characteristic picture of the cherry-red spot in acute obstruction. In the edematous area, the smaller vessels coursing toward the macula are enlarged and plainly seen.

The macular spot has a diameter of about one-half that of the disk. There are a few hemorrhages, notably a small one below the disk in the course of the inferior temporal vein, and a large triangular one with its base coincident with the temporal margin of the disk and its apex terminating near the macula.

The water color sketch by Dr. Mary Buchanan, shows well the fundus picture two days before the death of the patient.

As there was no visible evidence of obstruction in the central retinal artery or in any of the larger branches, and as there was no cilio-retinal vessel present, the diagnosis of embolism of a macular artery was made, as best explaining the fundus picture.

Some three hundred serial sections were made by Dr. Hosmer, and we are able to show the obstruction situated as supposed in a macular artery.

PATHOLOGICAL EXAMINATION BY CHAS. M. HOSMER, M.D., PHILADELPHIA.

The eye was fixed in formalin for 22 hours, then in Zenkers' Fluid for 18 hours (secondary fixation in Zenkers' was for the purpose of preventing that contraction of tissues which occurs after fixation in formalin and subsequent hardening and dehydration in alcohol,—this was not accomplished). Then washed and hardened in iodized alcohols of increasing strengths. Frozen, and a 10 mm. central horizontal disk taken for microscopical study. This was embedded in celloidin and cut in toto. The sections, twenty microns in thickness, were mounted serially, being stained alternately by hematoxylin and eosin, and Van Gieson's.

Fig. 1. Shows thrombosis of superior retinal artery on disk (Th. s.r.a.) and edema of retina. (Magnified 25 diameters.)



Fig. 2. Shows thrombosis of inferior retinal artery (i.r.a.) on disk and edema of retina. (Magnified 25 diameters.)

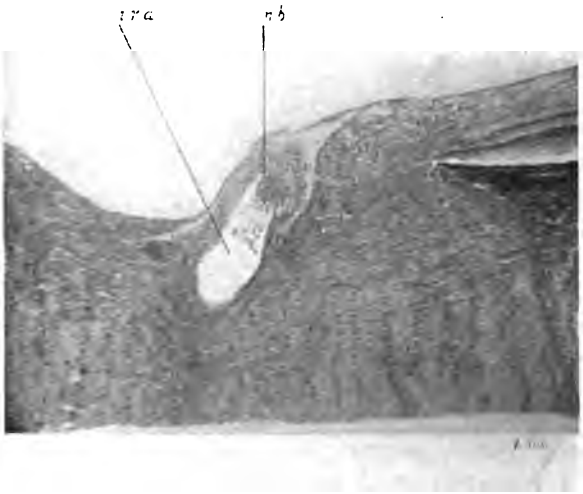

Fig. 2. Shows thrombosis of inferior retinal artery on disc. (i.r.a.) and edge of nasal branch. (r.b.) (Magnified 106 diameters.)

Fig. 3. Shows thrombosis of inferior retinal artery on disk and extension of thrombus (t.t.) into nasal branch. (Magnified 106 diameters.)

These are numbered I.1, I.2, I.3, S.1, S.2, etc. as they lie below or above a section chosen as the central.

Sections show the anterior half of the eye normal save for signs of old marginal ulceration of the cornea, and a recent infiltration of the margin down and in.

The pathologic changes in the posterior half of the eyeball are confined to the retina and the optic nerve.

An apparently homogeneous, internal limiting membrane is unusually prominent, especially on the temporal side, having a sharp anterior, and an irregular posterior outline. The inner endings of the retinal supporting fibres are united intimately with the foregoing, save in a broad band circumscribing the fovea. In the area of this band the appearance is that of the membrane having been pushed off from its retinal attachment by serous fluid. Some finely granular debris remains beneath the now lax membrane. The membrane is closely adherent over the fovea. In the perifoveal zone above mentioned, there is noticeable disappearance of supporting fibres. In the position of the nerve fibre layer there has been practically complete disappearance of the essential elements; there remains little more than a meshwork of supporting fibres, trellising blood vessels in places. The spaces between these remaining fibres are larger on the temporal side where the edema has been more intense. Partially filling these spaces is very finely granular matter, blood corpuscles and tissue debris. In some sections a horizontal stratification suggests remaining fibrous bundles; these however, are found degenerated, and without sharp outline.

The ganglion cell layer shows degeneration of all these cells. This is most marked in the region of the macula, where, in the main, the cells are swollen, practically homogeneous, and the nuclei stain not at all or very poorly. On the nasal side many of the cells lie in cystic cavities, many have disappeared, and those remaining are shrunken.

There seems to be generalized accentuation of the spaces of the internal reticular layer.

The elements of the internal nuclear layer show fairly well generalized edema infiltration with separation, which in many places amounts to fairly large cystic spaces. Throughout the layer many cells show degeneration; in the macular region this is total with fragmentation of the nuclei. In the far temporal portion of this layer, increasing from below upward, there is very marked so-called cystic degeneration of the retina,— large spaces filled with clear fluid separated by strands of supporting fibres.

The external reticular layer shows edematous separation of its outer portion, Henle's layer. This is more marked on the nasal side. In the temporal periphery, " cystic degeneration " of the retina involves this layer for a short distance.

The external nuclear, external limiting membrane, and rod and cone layers are normal, save as they show mechanical disruption with secondary degeneration, as shall be described later.

The retinal arteries show a thrombotic process beginning at their origin from the arteria centralis retinae, and extending into each for a distance of about 0.5 mm., these arteries are the superior and the inferior main stems, and a large nasally directed branch. Their greatest diminution of lumen is seen in sections S.3, I.14, and I.6 respectively; we would estimate these reductions as 8/12 for the superior, 6/12 for the inferior, and 7/12 for the nasal. The thrombotic mass lies upon the degenerated endothelium of the vessel and is made up of finely granular, almost homogeneous material taking the stain by hematoxylin and eosin, and picric acid by Van Gieson's and contains a few nuclei. In some parts this does not completely fill the space occupied by the thrombus. This mass is covered by new formed endothelium. The position of the thrombus varies, but for the most part, in the superior and inferior vessels it is apposed to the anterior portion of the lumina. The subendothelial connective tissue of the vessel wall apposed to the thrombus is very loosely arranged and partially fills a space between the endothelium and the lamina elastica.

The arteria centralis retinæ appears normal. A temporally



[illegible]



[illegible]

directed artery is given off from the superior stem; (v. sec. 33) this is entirely occluded at its origin by a mass of hyaline material filling in the temporal edge of the here flattened parent stem. In the center of this mass there is an ovoid more highly refractile body, an embolus.(?) This vessel, traced by examination of many sections runs to the macula and was apparently the principal nutrient vessel to that region.

The optic nerve presents the appearance of generalized degeneration of the fibre bundles. The remains of these lie in the spaces of the supporting fibrillae as granular detritus, or as swollen homogeneous strands.

The walls of the central vessels of the nerve appear normal.

Taking up now a more detailed description of the macular region, we find overlying the fovea, the membrana limitans interna firmly adherent. For a considerable distance on all sides of this central area of the macula, the membrane is loosened from its attachment with the nerve fibre layer. The space beneath this detachment is in great measure free; in the position of the nerve fibre layer, however, the granular debris of the structure of this layer presents.

There is advanced necrosis of the cellular elements of the ganglion cell layer and of the internal nuclear layer as has been described.

In those sections showing the "fovea," I.41 to I.60, recognized by the thinning and final disappearance of the ganglion cell layer over this area, this is found, instead of being depressed, to have its inner surface on a level with the surface of the thickened balance of the retina. The peripheral supporting fibres of this spot have the appearance of being stretched, and have an oblique direction from the periphery inward. This appearance is more marked on the temporal side. The membrana limitans externa is displaced forward, being on a line with the internal reticular layer of the surrounding macula. The portion of the membrane corresponding to the foveal spot is detached at its margin, from the balance of the membrane. At the foveal periphery, the ret-

inal structures describe a double curve from without inward, first a curve anteriorly and away from the fovea, then in toward the latter. A few elements of the rod and cone layer remain attached to the membrane, but these are for the most part detached from it, and a mass of finely granular matter is interposed. The rods and cones are distorted and in various stages of degeneration; a large cystic space lies posterior to this forward displacement of the foveal fundus. The pigment layer in this region shows some disturbance, displacement and swelling of some cells and a few low drusen formations. The external limiting membrane for a short distance about the foveal region shows wrinklings with distortion of its penetrating rods and cones. Throughout the macular region the venules and capillaries are dilated, show about them small hemorrhages and in some sections show their contents coagulated.

PATHOLOGICAL CONCLUSIONS.

I. The widespread degeneration of those retinal layers dependent upon the retinal vascular supply for nutrition is due to diminution of this supply by partial thrombotic occlusion of the arteries. The more intense degeneration of the macular region is due to total obstruction of its principal nutrient artery. The process amounts to ischemic necrosis.

II. The edema is due to alterations in the vessel walls rendering them more permeable and permitting the transudation of serum.

III. That the hemorrhages are due to similar cause as is the edema.

IV. That the amount of edema was probably increased, and the hemorrhage in part caused by back pressure in the veins.

V. That there has been an umbilicated bulla about the fovea, the anterior covering of which was the membrana limitans interna, and the fundus of whose umbilication was the fundus of the foveal spot.

VI. That by means of pressure the fluid of this bulla has

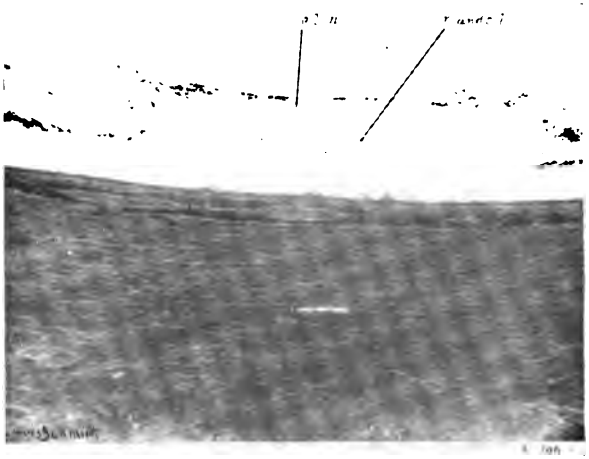

Fig. 6a. Foveal region showing elevation of [illegible] limiting membrane (e.l.m.) and remnants of rod [illegible] layer (r.a.n.l.) displaced. Intraretinal [illegible] of serous fluid.
(Magnified [illegible] diameters.)

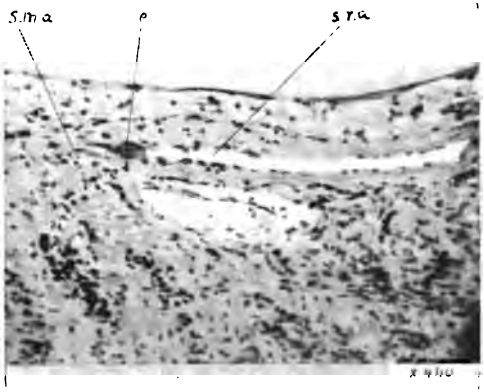

Fig. 6. Shows Embolus (e) of superior macular artery (s.m.a.) at its origin from the flattened superior retinal artery. (s.r.a.)
(Magnified 240 diameters.)

been put under sudden tension with expansion in the direction of least resistance, which was through the membrana limitans externa, by rupture of this membrane. Prior to this by nature of its anatomical relations, there was wrinkling of the membrane about the fovea.

That therefore this appearance is of artificial production, probably at the time of enucleation.

DISCUSSION.

DR. C. J. KIPP, Newark: I have at present under my care a case which throws a good deal of light upon the nature of this disease. A man of 45 without kidney disease presented himself about two years ago with a perfect picture of embolism, of central retinal artery. Within a short time all the arteries had changed into silver wires. A year after embolism of the right eye had occurred he came to me with a thrombosis of the upper branch of the central retinal vein of the left eye, the entire upper half of the fundus being covered with hemorrhages and sight reduced to 5/12th. Since then he has had hemiplegia and is now in a condition of mental imbecility, showing that not only the arteries supplying the eyes but those supplying the brain were diseased.

ANGIOMA OF THE ORBIT WITH INVASION OF THE GLOBE ALONG THE CILIARY NERVES.

BY ALEX. QUACKENBOSS, M.D.,
BOSTON, MASS.
PATHOLOGICAL EXAMINATION BY F. H. VERHOEFF, M.D.

Angiomata may be divided into three classes — Vascular Naevi, Telangiectases, and Cavernous.

Simple naevi are due to an excessive development of capillaries, they vary greatly in size, are usually on the same level with the skin, and may be bright red in color, or of a darker hue, having the so-called port-wine shade. This form is always congenital, and shows little tendency to spread.

Telangiectases show a network of dilated capillaries, are similar to naevi in structure, but differ, in that they are rarely congenital, being acquired, and that they are more apt to increase in size.

The third class, cavernous angiomata, have a distinct tumor formation; they consist of a framework of connective tissue with chambers of varying capacity and many enlarged vessels. They are usually acquired and appear soon after birth.

The head is a favorite site for angiomata and many are seen about the orbit. In the lids they may appear as simple naevi, or they may be situated more deeply and are then seen shining through the skin with a bluish lustre. The latter consist of a mass of large sized blood vessels, readily felt through the lid.

Primary angiomata of the conjunctiva are very rare and are usually situated at the inner canthus, starting in the caruncle. Most cases are originally situated in the lid and have gradually passed over onto the conjunctiva.

Two forms of angiomata are usually found in the orbit, one involving the anterior part and associated with the same condition in the lid. It starts in the lid, extends back into the orbit, is not sharply defined and has no capsule. The second

FIG. 1.—Photograph of sectioned tumor and globe, showing invasion of corneal limbus, sclera, chorioid and optic disk.

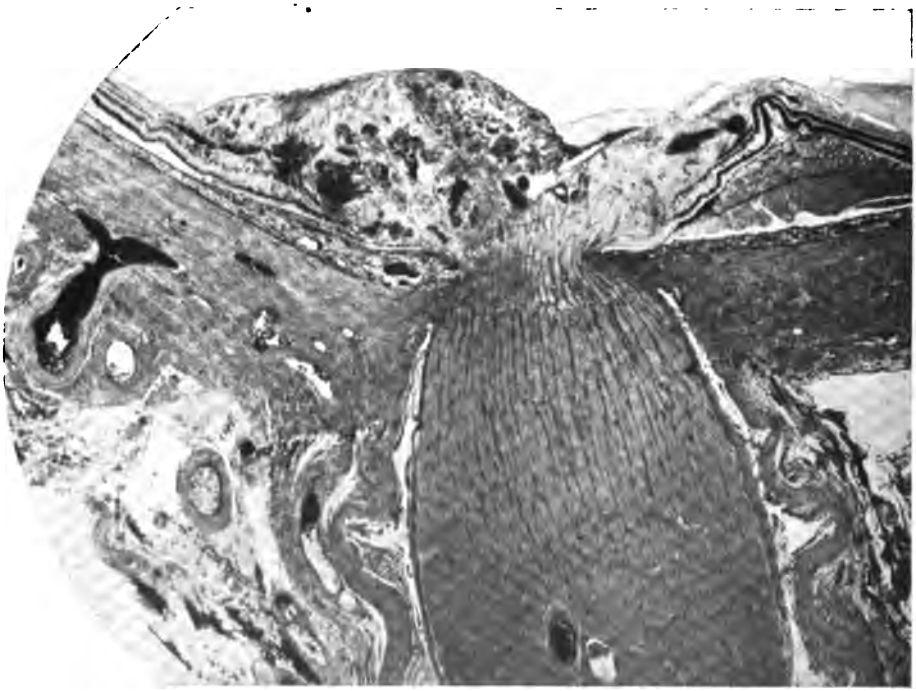

FIG. 2.—Photograph of section showing angioma extending from chorioid into optic disk. Mag. x-16.

form, cavernous, usually develops within the orbit itself, its favorite location being within the muscle cone. It has a firm white fibrous capsule, grows slowly, pushing the eye forward. Angiomata of the orbit seldom if ever pulsate and there is no bruit. Forced muscular exertion, coughing or sneezing often causes an increase in size of the tumor, while pressure often diminishes it.

For the cure of angiomata various lines of treatment have been employed, electrolysis, cautery, nitric acid, injection, ligation and extirpation. Removal is the best line to follow wherever possible, and it should be done early, on account of the tendency to increase in size.

The following case illustrates this tendency of a vascular tumor to increase; it started in the lid, invaded the orbit and then the globe.

Thomas M., age 32, was seen at the Infirmary in the Fall of 1907. In infancy there were a few dilated blood vessels in the conjunctiva of the lower lid of the left eye. The temporal portion of the ocular conjunctiva also showed the same condition. This condition remained stationary until about the age of twelve, then the angioma rather suddenly increased in size, the lower lid became swollen and the eye was pushed forward. Following this period of activity the process remained quiet for about ten years. At the age of twenty-three the lower lid became more swollen and electrolysis was used with some benefit. Then ensued another period of rest for about six years, only to be followed by renewed activity, the swelling, which up to this time had been confined to the lower lid extended to the upper, the eye became more prominent and for the first time difficulty in closing the lids over the eyeball was experienced. Slow but gradual increase in the size of the tumor, caused increasing exophthalmos, and the cornea became ulcerated from exposure. Up to the time of corneal involvement, the vision remained nearly normal in the eye. For the past ten days the eye has been very painful.

At the present time, October, 1907, marked exophthalmos exists, the eyeball appears to be wholly out of the socket, both lids markedly swollen, the lower one everted. There is no motion of the eyeball. The cornea is ulcerated. Through the skin of the lower lid is felt a hard tumor about the size of a large walnut. There is no pulsation or bruit. Examination of the naso-pharynx negative — no glandular enlargement.

Under either the outer canthus was divided, the eyeball was freed from the conjunctiva and muscles above, and then the eye with tumor attached was dissected from lower lid and orbit. The tumor was firmly attached to the orbit by numerous fibrous bonds. There was considerable hemorrhage during the operation, no large vessels were cut but there seemed to be a general oozing from the whole surface of the tumor. The eyeball with tumor attached was about the size of a goose egg. The external canthus was sutured and the orbit packed with gauze. Recovery without incident. Following the operation the question arose as to whether anything ought to be done to the lids. They had been enlarged and distended for so long that they appeared like empty pouches, after the contents of the orbit were removed. It was decided to leave them alone and they gradually diminished in size. A letter from the family physician was received nine months after the operation saying that the lids were about normal in size and that there had been no recurrence.

In looking through the reports of this Society, I find cases of Angiomata of the Orbit, but none invading the globe itself. Drs. Harlan, Bull and DeSchweinitz have contributed to the subject. Dr. Lippincott in 1895 reported a case of Angioma of the Ocular Conjunctiva.

Pathological Examination:— The specimen, consisting of a large tumor mass with the eye enclosed, was fixed in Zenker's fluid. The section made through the greatest diameter of the mass almost exactly bisected the globe, passing through the centre of the cornea and the middle of the optic disc and nerve.

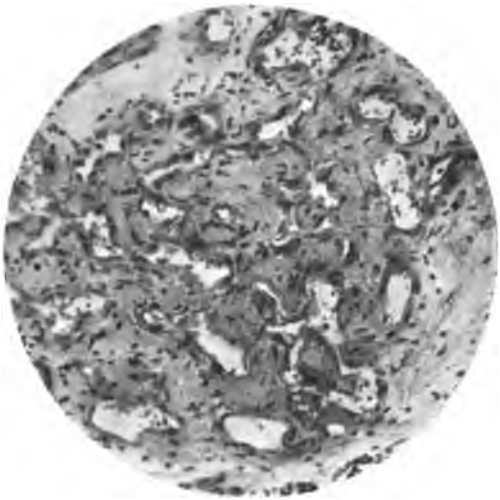

FIG. 3.—Showing structure of nodule in optic disk. Mag. x-130.

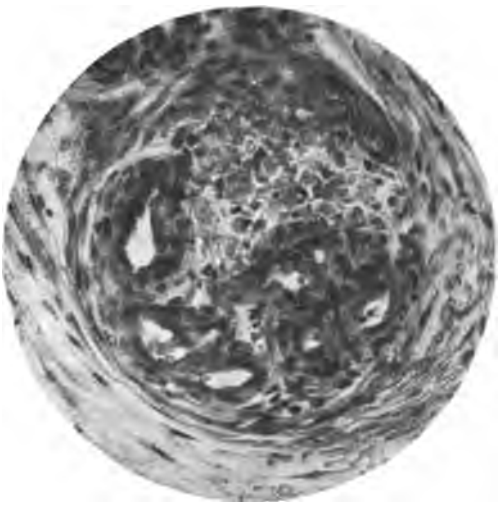

FIG. 4.—Ciliary nerve in cross section invaded by vessels of angioma. Mag. x-216.

(Fig. 1). The tumor consists chiefly of two rounded nodules connected together. The largest is below and measures 3 cm. in diameter. The other nodule represents an extension backward into the orbit and measures 3.7 cm. x 1.7 cm. in greatest cross section. In addition to this the larger nodule sends a number of firm band-like prolongations into the orbit. The tumor represents a sharp outline anteriorly, but posteriorly it passes more or less diffusely into the orbital tissue. The larger nodule is in direct contact with the globe and anteriorly has sent an extension into the bulbar conjunctiva lifting it up in the form of a mound 3 mm. to 5 mm. high all around the limbus. The cut surface of the growth shows an abundant fibrous stroma permeated with blood vessels of all sizes. Most of the vessels show extremely thick walls.

The globe measures 25.5 mm. antero-posteriorly, 23 mm. vertically. The cornea shows a large central ulcer 5 mm. in diameter containing a clear central area 2 mm. in diameter. The bulbar conjunctiva is swollen as already described, and overreaches the cornea 2.5 mm. The anterior chamber is 4 mm. deep and filled with bloody coagulum. The pupil, 2.5 mm. wide, is free from membrane. The filtration angle is not occluded by the iris. The iris and ciliary body are swollen. The lens, 8.5 mm. x 5 mm., is clear. The vitreous humor is coagulated after fixation. The choroid is in situ and appears thickened around the disc. The retina is also in situ, except on one side of the disc where it shows a small localized separation with coagulum beneath it. The disc is greatly swollen, to 8 mm. in diameter and 2 mm. high, suggesting choked disc. The swelling, however, is uneven, the lower portion showing the greater elevation. The lower portion also shows an excessive vascularization. Immediately below the nerve the sclera is highly vascularized by vessels which are in continuity with the tumor and which seem to pass into the thickened choroid. The subdural space of the nerve is not distended.

Microscopic Examination shows the tumor to be a telangi-

oma. The connective tissue stroma is fibrous or hyaline, unusually abundant, and forms no definite capsule. There are few hemorrhages. Vessels of all sizes are numerous, but where the tumor is invading the surrounding tissue those of capillary size are most frequent. None of the new formed vessels, even the largest, show a well marked muscular coat, but many have a few muscle fibers at the periphery. The walls of the larger vessels are as a rule extremely thick and composed chiefly of tissue apparently identical with that seen in senile endarteritis except that it is free from degenerative changes. This tissue represents the intima and resembles the proliferated intima of angiosclerosis also in not occurring as an even layer but as nodules along the walls of the vessels. It consists mainly of stellate cells, and after hematoxylin and eosin staining shows only a slight amount of intercellular substance. The latter often stains decidedly blue. Mallory's phosphotungstic acid hematein shows, however, an abundance of fibroglia fibrils in relation with the cells, so that it would seem proper to speak of the tissue as fibroglia. Within and around this tissue a differential stain for elastic tissue shows always a certain amount of elastic tissue, sometimes an excessive amount. The stroma of the tumor is also rich in elastic elements.

The growth shows a marked tendency to invade nerves both large and small. The nerves are evidently first invaded by capillaries which enlarge and finally destroy the nerve substance. Sometimes a large vessel is found whose origin in a nerve is apparent only from a small amount of nerve substance attached to its inner wall. The nerve tissue is definitely recognized by the arrow head markings of the myelin sheaths. The presence of nerve tissue within the lumen is a certain indication that the vessel was not formed by the gradual enlargement of a single small vessel and at first glance makes its orgin seem difficult to explain. Careful study of a large number of sections, however, shows that such vessels are formed by the gradual breaking into each other of small cavernous blood spaces within

FIG. 5.—Showing canalization of posterior ciliary nerve at entrance into sclera.
Note mass of nerve tissue remaining within the lumen. Mag. x-33.

FIG. 6.—Showing invasion of striated muscle. Mag. x-50.

the nerves. The nerve thus becomes canalized as in the case of a thrombus.

Individual striated muscle fibers are also attached by capillaries of the tumor which grow within the endomysium and finally replace the muscle substance. Around the invading capillary the endomysium often proliferates, while the endothelium of the vessels also proliferates causing complete obstruction in some cases. In this way whorl-like structures are formed which simulate the pearly bodies of endotheliomata.

Microscopic examination of the globe. The mound of tissue around the limbus is found to be conjunctiva invaded by the growth. At the limbus on each side the corneo-scleral tissue is deeply invaded, and one section shows the invasion to have reached the canal of Schlemm. The cornea shows a central suppurating ulcer which presents the peculiarity of having a sequestrum in its centre. The sequestrum shows complete hyaline necrosis and in it scarcely a nucleus of any kind can be seen. No bacteria can be brought out within it by the Gram method. The sequestrum takes up the anterior three fourths of the corneal stroma and is sharply defined. Behind and around it the stroma is densely infiltrated with pus cells many of which are necrotic. Descemet's membrane is destroyed and the infiltrate is in continuity with the exudate in the anterior chamber. The epithelium has disappeared from almost the entire surface of the cornea and the latter shows the appearance characteristic of drying. The anterior chamber is filled with exudate composed of pus and blood most of the cells being necrotic. The iris shows a comparatively slight infiltration with pus cells but contains many chronic inflammatory cells. It is giving off a marked exudate of pus cells from its posterior surface. The ciliary body is only slightly infiltrated and the exudate from its surface contains numerous phagocytic epithelioid cells in addition to the more abundant pus cells. The choroid shows no purulent infiltration and only an insignificant perivascular infiltration with lymphoid cells just posterior to the ciliary body.

The pars optica retinae is almost free from infiltration but occasionally one of its vessels is found surrounded with lymphoid cells. Here and there it is giving off phagocytic epithelioid cells into the vitreous body. The retina and choroid are otherwise normal except in the vicinity of the disc as will be described. The vitreous humor is infiltrated with pus cells anteriorly, but posteriorly contains numbers of epithelioid and lymphoid cells.

Just below the optic nerve entrance the sclera has been invaded by the tumor. The new vessels are seen growing within the clefts of the sclera and in places extending into the choroid. Most of the vessels are small but frequently small cavernous spaces are formed due apparently to the smaller vessels opening into one another. The appearances presented suggest that in every instance the invasion has taken place along a nerve, even when the nerve substance is no longer recognizable. The portion of the choroid invaded is that extending immediately around the optic disc for a distance of about 3 mm. At one edge of the disc the choroid is increased to about double its normal thickness. The invading vessels are most of them of almost capillary size, but vessels which take up nearly the entire thickness of choroid are also met. In the affected region the stroma of the choroid is more abundant and denser than normal. All the layers of the choroid are involved in the growth except the chorio-capillaris and the membrane of Bruch which are everywhere intact. At the lower margin of the disc the new growth of vessels continues into the disc and then extends partly into the retina. One very large vessel can be followed along the course of a posterior ciliary nerve into the choroid where it branches, one branch passing backward into the disc. In the disc the growth forms a fairly well defined nodule. The remainder of the disc shows simple œdema with some hemorrhages, as does the retina around it. Near the disc the retina is separated from the choroid by albuminous coagulum. Within the nodule the fibrillar tissue of the disc has been largely replaced by hyaline connective tissue, remains of the original

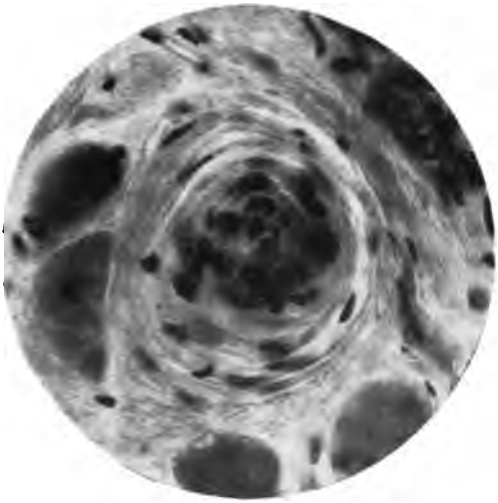

FIG. 7.—Vessel of angioma replacing striated muscle fiber. Proliferation of endomysium of muscle fiber and complete obliteration of lumen of vessel by endothelial proliferation. Mag. x-388.

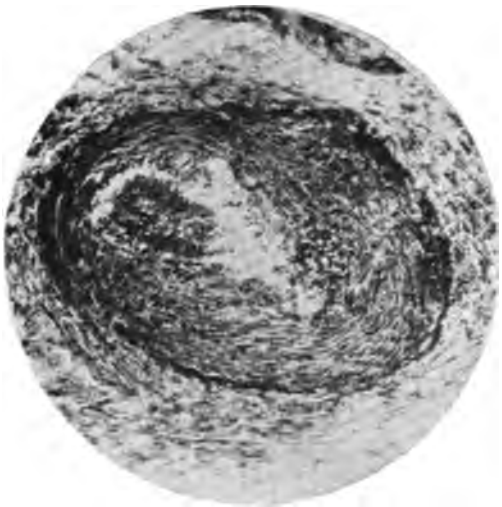

FIG. 8.—Excessive proliferation of intima in blood vessel of angioma. The new tissue is composed of fibroglia intermingled with elastic fibers. The elastic tissue is especially abundant at the periphery. Differential elastic tissue stain. Mag. x-105.

tissue being represented by proliferated neuroglia. No fibroglia or smooth muscle fibres are present. From the surface of the nodule and disc, an exudation of epithelioid and chronic inflammatory cells is taking place, called forth no doubt by the inflammatory condition in the anterior part of the eye. Some of the blood spaces within the nodule are filled with recent fibrinous thrombi.

The nerve stem is not œdematous and appears normal. The central vessels are somewhat dilated but are otherwise normal except far back where they run in the pial sheath. Here the artery shows well marked endarteritis. The nerve stem has not been invaded by the tumor.

Pathlogical diagnosis. Hemangioma of orbit. Invasion of ciliary nerves, sclera, choroid, and optic disc. Suppurative keratitis.

Remarks: The most important histological features of this case are, the marked tendency of the angioma to invade and extend along nerves, the invasion of individual striated muscle fibers with formation of whorl-like structures, the marked subendothelial proliferation in the larger new formed vessels, with production of fibroglia and elastic tissue, and finally, the invasion of the interior of the globe, especially of the optic disc.

The invasion of the nerves was first by vessels of about capillary size which later became enlarged and in some instances formed a cavernous structure. Sometimes the intervening walls of the cavernous spaces thus formed entirely disappeared so that a large nerve trunk was converted in a single blood vessel. The whorl-like structures produced by the invasion of striated muscle fibers simulated those of a dural endothelioma, but here the concentric laminae were apparently produced partly by proliferation of the endomysium around the invading vessel.

The occurrence of the marked endothelial and subendothelial proliferation in the vessels of the tumor, with production of tissue similar to that seen in arterio-sclerosis suggests a possible

explanation of the exuberant growth of the tumor. For it seems probable that toxic substances in the blood which in some individuals give rise to arterio-sclerosis, might cause the abnormal vessels of a naevus to take on exaggerated growth. In this particular case the presence of such toxic substances was suggested by the marked endarteritis displayed by the central retinal artery. On the other hand it seems equally possible that the endovasculitis both of the tumor vessels and of the central artery was compensatory in character, and due to the high localized blood pressure associated with the tumor.

The keratitis in this case was apparently due to exposure, but the extensive involvement of the ciliary nerves suggests the possibility of a neuropathic origin.

The invasion of the interior of the globe by an orbital angioma with the formation of a nodule in the optic disc apparently has heretofore never been recorded, and the fact that the invasion occurred along the posterior ciliary nerves seems particularly noteworthy.

MACULAR HOLES—A CLINICAL CONTRIBUTION.

By CHARLES J. KIPP, M.D.,

NEWARK, N. J.

The condition described as macular holes and holes in the retina by English writers, and as retinitis atrophicans sive rarificans centralis by Kuhnt, and as Durchlöcherung der Retina by Haab, is probably not as rarely seen in this country as one might infer from the fact that there are less than half a dozen cases by American writers on record. Until 1900, when three papers on this subject appeared in the medical journals in Germany and England, but little attention was paid to it, although, as Ogilvie has pointed out, a case similar to one of his own was published by Knapp as early as 1869. Knapp's case is, however, a doubtful one, and was misinterpreted by him. The first case about which there can be no doubt was reported to this society

in 1871, by Dr. Henry B. Noyes, and published in the transactions for that year. The case is entitled "Detachment of the Retina with Laceration of the Macula Lutea." Loring has evidently seen such a case, for in his text-book of Ophthalmology (1891), in speaking of circumscribed retinitis of the outer layer, he says: a marked feature in some of these cases is the peculiar appearance which the central portion of the macula and fovea present. The latter seems to be so sharply defined that it has the appearance of a clear cut opening — as if indeed the tissue had been cut in this place with a punch. Nothing is said of a relationship to injury.

Dr. Coates of London, who has recently exhaustively reviewed the literature of this subject in the Royal London Ophthalmic Hospital Report, Vol. XVII, part I, page 69, where also a complete bibliography can be found up to 1907,[1] after quoting Noyes' case, says: "the history of this condition is interesting on account of the frequency with which it has been rediscovered, and I have given these full extracts from Noyes' paper because there has been a tendency in literature to ascribe the first discovery to Kuhnt and Haab. But after so clear and exact a description, there can be no doubt as to where priority properly rests."

It is not my intention to review here all that has been written on this subject, and would refer any one interested in this subject to Mr. Coates' most interesting paper already mentioned. I may here, however, say that I find that there are nearly thirty-seven cases of so-called hole in the retina on record. In twenty-seven of these a blow on the eye or some injury was the supposed cause of the condition. In ten of these cases an injury could be excluded, and vascular disease, retinal hemorrhage, arteriosclerosis, albuminuria, and irido-choroiditis are given as the probable cause. Amongst these ten cases (non-traumatic) there are three in which a hole in the retina was found in both eyes.

[1] Since then Trietmayer (Zeitschrift für Augenheilkunde, Band XVIII, November, 1907, p. 447) has contributed three cases all due to traumatism.

Of all these cases, only six were observed in this country; one of traumatic origin by Noyes; one by Holden, and two non-traumatic cases by de Schweinitz. In the discussion following de Schweinitz's paper before this society in 1904, Dr. Gould mentioned that he had seen this condition, and I mentioned very briefly the case which is here reported as Case II.

My own cases are as follows:

CASE I. *Traumatic perforation of the retina.*— H. D., about 26 years of age, a well-developed man, who up to the time of the accident had had no disease of either eye, and whose vision in both eyes had been excellent, was first seen at the Newark Eye and Ear Infirmary, April 27, 1907. He stated that on July 4, 1904, he had been struck on the left eye by a base ball, and that since that time the vision of the left eye had been much impaired. Present state: the eye is E. S. 6/60 V. F. intact for white and color, a small central scotoma can be made out. Tn. The media are perfectly clear. The pupil is active. The disc is somewhat blanched in temporal half. The vessels are of normal size. At the macula is a perfectly circular spot, about two-thirds size of disc. It is of a bright deep red color, on which are scattered some minute pigment dots and several small bright white spots. The retina around this red spot is somewhat hazy for some distance, and on the sharply defined margin of the red spot are five or six small bright yellowish-white dots, which appear to be situated in or on the retina. The floor of the deep red spot is on a somewhat deeper level than the grayish sharply defined margin, and is best seen with a — 1 D glass. It gives one the impression of being cupped, and looks as if a piece of the retina had been cut out with a trephine. The opacity of the retina is greatest at the margin of the hole and gradually merges off into the normal retina. Above this hole the pigment of the retinal epithelium is somewhat irregularly distributed, and all over this region of the retina are scattered very fine crystalline particles which sparkle as the light from the mirror strikes them. Otherwise the fundus is normal.

The right eye was normal in every way. The patient was seen again thirteen months later, and the condition found at first examination was unaltered.

CASE 2. *Macular Hole not the result of injury.*— Miss R. M., 26 years of age, is a well developed and healthy looking woman, whose parents are living and in good health, and whose brothers and sisters are all in good health and without disease of their eyes. She has never been seriously ill, denies syphilis, and her eyes have at no time been inflamed or painful. She was seen by me for the first time in July, 1904, and came to consult me about her left eye, the sight of which had been defective for some time. She could not tell how long the sight had been impaired, but was certain that the eye had never received a blow or other injury. The right eye was as good as ever. The examination of the right eye revealed a mixed astigmatism with S. 5/6. The fundus of the eye was normal. The left eye was practically blind. She could see movements of hands close to the eye. The exterior parts of the eye were entirely normal. The iris was of same color as that of right eye and of normal texture. The pupil was active and of same size as that of the healthy eye. The lens and the vitreous were perfectly clear. The disc was rather pale in its temporal half, and on this was an almost black spot of oval form; two other pigment spots were situated just outside of its temporal margin in the choroid. The retina was perfectly transparent, except in the region of the macula where it was decidedly hazy. The haziness was most marked around the central area which was of a deep red color, and gradually faded into the normal. The central portion of the macular region was occupied by a bright deep red spot in size about one-half diameter of the disc; it was circular in shape and was sharply defined in outline. The spot was not of uniformly red color, but on it or in it were many small yellowish-white dots. This deep red region appeared to be situated slightly deeper than the opaque retina surrounding it. The retinal vessels were of normal caliber, and there were no other fundus changes. I prescribed calomel

in which there are yellowish-white dots arranged in lines running vertically. The color of this area is very much like that of the bottom of the hole in the other eye. The retina of this entire region appears perfectly transparent, and the retinal vessels can be traced to the region of the fovea lutea. There is no collection of pigment to be seen at the margin of the light colored area or in its neighborhood. This region, like the disc, is best seen without any glass behind the mirror. Repeated and very careful examination of the visual field showed a very small central scotoma for form and color. The light sense of the left eye was much reduced. With a smoked glass before his eyes he could see only 6/60, while I could see with same glass before my eyes 6/8. On questioning about his vision at night, he admitted that he has difficulty in getting around at night, and much more so at present than in former years.

The patient has been under my observation for the last sixteen months, and at this time the picture in both eyes is about the same as when first seen. I saw the patient about once in every fortnight and examined his eyes under homatropine most thoroughly. With regard to the right eye, I can say positively that in the region around the hole, the surface of the retina was most distinctly seen with a + 2 D glass, while the floor of the hole was like the disc, best seen without any glass. The retina was therefore either thickened in this region 2/3 mm. or else was pushed forward by a plastic exudate behind it to that extent. There were no folds in the retina and no other signs of detachment. The two light-colored spots seen below the hole did not impress me as being opacities in the retina itself, but rather as circumscribed exudates under the retina, or as perhaps spots of atrophy in the choroid similar to the large patch of choroidal atrophy in the left eye.

In the left eye there were seen slight evidences of a former choroiditis around the disc. The bright deep red area situated above the patch of atrophy of the choroid, seemed to me almost identical in color with the color of the floor of the hole in the

Right Eye.

Left Eye.

right eye. I assume that here the retina was thinner, more transparent than in other parts, so that the pigment epithelium was visible here. In the light-colored area below this, not only the pigment of the retinal epithelium, but also the stroma pigment of the choroid, had disappeared. There were no collections of pigment to be seen anywhere around the atrophic region, nor, indeed, anywhere in the ophthalmoscopic field, except just below the lower margin of the disc. That the deep red area was not an extravasation of blood is quite certain, as it did not change in appearance in the least during the period the eye has been under observation, and moreover it did not have the uniform red color of a blood extravasation. The retina over both the deep red and the light-colored areas was perfectly transparent, and the retinal vessels could be distinctly seen in it.

We have therefore two very dissimilar pictures of the eye-grounds of this patient. In the right eye the picture does not differ from that described by Noyes and others since, under the name of a hole in the retina or macular holes. In the left eye the choroid is in a state of atrophy in the macular region and the retina is present, but apparently much thinner over a small area, just above the atrophic spot in the choroid. From the history of the case it seems probable that the injury to the right eye 16 years before he came under observation, is responsible for its present condition. It is not impossible also that the left eye received a blow at the same time that the right eye was injured, although the patient does not remember it. In fact the patient was not aware the left eye was defective before he sought my advice. It must therefore remain undecided whether the changes in the left eye are due to traumatism or disease. It may possibly be a congenital defect. It may also represent the result of an incomplete rupture of the choroid, but its location, its form, the absence of collections of pigment at its edge or on it, and the fact that choroidal vessels were present seems to me to make this impossible. To me it looks much more like an atrophic area following a circumscribed inflammation of the

choroid. An œdema of the retina caused by the choroiditis would perhaps also account for the atrophic area of the retina seen just above the atrophic area of the choroid. I have been unable to find amongst the recorded cases, one in which a hole in the retina was present in one eye and choroidal atrophy in the macular region in the other eye. There are several cases on record in which a hole in the retina in the macular region was present in both eyes, but in all of these it arose spontaneously. There is one case on record in which the two eyes of a man received blows at different times and in which a macular hole was found in each eye, some time after the injuries.

I venture the suggestion that in my case a choroiditis attacked both eyes some time in early life, and that the disease of the choroid caused the change in the retina in the right eye, and the so-called hole in the macula. I look upon the two light-colored spots below the hole as patches of atrophy of the choroid shining through the cloudy retina. In the left eye the region immediately adjoining the disc shows evidences of a former inflammation of the choroid, and the large atrophic patch is doubtless also the result of such an inflammation. Kuhnt has pictured a case of hole in the retina, which has also several light colored spots in or under the retina near the circumference of this hole, and in addition a large atrophic patch in choroid close to the disc. This case would seem to confirm the view I have suggested: that the hole in the retina is the sequence of a choroiditis.

As regards the pathology of this condition, I can only repeat what others have written. Coates in the paper repeatedly referred to, says: Reis, in discussing his own cases and those in literature, very properly points out that since exactly the same appearance may arise after a contusion and after certain diseases, especially irido-cyclitis and retinal vascular diseases, it is necessary to presume some pathological factor common to these two conditions. He elaborates the theory already foreshadowed by Fuchs, that retinal œdema is the underlying lesion. This is opposed to Monteith Ogilvie's supposition that the hole is a tear

by contracoup — by the convergence on the posterior pole of waves transmitted through the fluids of the eye, and that therefor it occurs at the moment of injury. Against this theory it may be observed that on the one hand a hole has never been observed sooner than 60 hours after the contusion (Ogilvie, Case 5). On the other hand opacity of the retina without a hole *has* been observed after injury in a case in which a hole subsequently developed (Reis, Case 3, Holden). Oedema of the retina with subsequent formation of a hole has also been observed in cases in which there has been no injury (Kuhnt, Case 3, de Schweinitz). The theory of contracoup furnishes no explanation of the cases arising in connection with iridocyclitis and retinal vascular diseases, whereas retinal œdema is not only probable in such cases but furnishes the desired factor common to them and to cases of injury (Berlin's opacity). Moreover such pathological evidence as we possess all points in the same direction. The cases of Pagenstecher and Genth, Fuchs, Murakami, and v. Hippel, whether they arose from injury or from disease, had this in common, that large cystic spaces were present in the fovea and in the retina around.

The state of our knowledge from the pathological point of view may be summarized as follows: *No case has been seen ophthalmoscopically and examined microscopically.* Coates adds four cases of his own which he hopes will add something to the pathological data. In neither of these cases was the hole seen ophthalmoscopically. He summarizes his conclusions as follows: Macular holes are produced by an œdema of the retina at the posterior pole. The œdema may not be confined to the region of the fovea, but the appearance of the hole will only be produced if there is a defect at least of the inner layers of the retina. Possibly for the complete typical picture without membrane or shred, a total defect of all the layers of the retina is necessary, and that such a complete defect may arise from retinal œdema is proved by Case 2, above. The œdema may result from a contusion, in which case it is the same as the œdema which pro-

duces Berlin's opacity; or it may arise from toxines in the vitreous, the result of iridocyclitis; or from retinal vascular disease.

Rupture of the retina at the time of injury is not the cause of macular holes. This is proved: (1) by those instances which occur without injury in cases of iridocyclitis, choroido-retinitis, retinal vascular disease, albuminuric retinitis, etc. (2) by those cases in which diffuse opacity of the retina *without* hole has been observed after contusion and in which a hole has subsequently developed. (3) by Case 4 (Coates' case) in which such rupture occurred, but in which the measurements and appearances could not be brought in line with the clinical picture of a macular hole.

DISCUSSION.

DR. WM. ZENTMAYER, Philadelphia: Some 15 years ago there was brought to the Wills' Eye Hospital a colored man who had received a severe blow on the eye which was followed by intraocular hemorrhage with greatly increased tension. That evening I was called by the resident as he feared the necessity of an enucleation of the eye on account of the severe pain. I did a paracentesis and the glaucomatous symptoms subsided. Examination of the fundus some days later showed the deepest excavation of the nerve head that I had ever seen, and a circular area at the macula about the size of the head of a pencil, the floor of which was a little darker than the surrounding chorioid. The only change that occurred later was that the central portion became granular and the lesion presented all the appearances of, what to-day is known as a "hole at the macula."

NOTE.— Since this paper was written, Dr. Alt and the writer of this paper have published in the *American Journal of Ophthalmology* for August, 1908, a case in which a hole in the macula was seen ophthalmoscopically twenty-four hours after an injury, and in which the histological examination of the eye confirmed the diagnosis.

A CASE EXHIBITING A SYMBLEPHARON, CORNEAL OPACITIES AND A PROBABLY FIBROFATTY TUMOR OF THE CONJUNCTIVA; ALL OF PRENATAL ORIGIN, IN A WOMAN WITH HEREDITARY CATARACTS AT AN EARLY AGE.

BURTON CHANCE.

Mrs. E. M., aged 52, consulted me in March, 1907, for the removal of "Cataracts." Two years before this I removed soft cataracts from the eyes of her daughter, aged 24. The lady's mother had had bad sight from early years, which E. M., in her childhood, had been told was caused by cataracts. The history of her mother's mother is uncertain, yet it is believed that she too had cataracts. The lady herself was healthy and robust, except for imperfect eyesight, which in the previous three years had failed so much that she was able to tell the movement of the hand at only a foot or two. She never had had inflamed eyes, neither had they ever been injured; but she had had "birth marks" on them: there was a story of prenatal impression connected with their origin. The description of these "birth marks" is the object of this communication.

The external appearance of the eyelids was healthy and their actions normal, but projecting from below into the fissure of the right eye was a pearly, unpigmented, vascular mass which approximately measured 6x4 mm. On withdrawing the lower lid, the tumor was seen to be adherent to the globe; it appeared to spring from the retrotarsal fold, and, advancing across the limbus, its base blended with the cornea about 2 mm. beyond the limbus in the lower and outer eighth. The point of union was defined by a dense white line. The tumor projected beyond the plane of the lids, though it could not readily be seen when the lids were tightly closed. It was irregular in outline and nodular in form; the outer portion was cyst-like. The surface was smooth and conjunctival in appearance, and, it was soft and easily palpable on its firm base in the sclera. I regarded it as a fibrofatty tumor. On raising the upper lid the retrotarsal fold was seen to be bridged across by a broad symblepharon, as wide as the

tarsus, and attached to the cornea 3 mm. within the limbus. This singular formation was adherent to the globe. It was striated, moderately vascular, smooth on the surface, soft and pliant. Where it was attached to the cornea there was a very dense white line, and beyond this, like a shadow, was a fainter line. The attachment melted into the substance of the cornea and beyond into the sclera, so that a fine probe could not be insinuated beneath the borders. The tarsal cartilage was present in the upper lid. The movements of the lids and globe were not impeded by the malformations present.

Beneath the epithelial layer of the cornea was a densely opaque white line, which extended obliquely across it from about 2 mm. above the horizontal meridian, well within the limbus, downwards to beyond the vertical, where it ended in a hook, projecting upwards and inwards. The width of the line was almost uniformly 1 mm. The remaining portions of the cornea were clear and the entire exposed surface sparkling. The cornea was not under-sized.

(The accompanying drawing is perfect in details, yet the artist was not able to depict the vividness of the ensemble as it appeared to the beholder.)

In the upper outer quadrant of the cornea of the left eye was a broad, dense, pearly white, scleral tongue, which extended to about 3 mm. within the limbus. This tongue was evenly continuous with the sclera, and where it ended on the cornea there was the same sort of line and shadow as was noticed demarcating the abnormal structures in the right eye. The corneal surface was not appreciably elevated by the projecting tongue, and the remaining portions of the membrane were perfectly clear.

I must regard these opacities and the adhesion of the eyelid to the globe as of inflammatory origin, yet in a most careful study of the corneas with a strong loup no obliterated nor patulous vessels could be found, and as the irises were normal in their structure and in their functions, it is all the greater evidence that they were not caused by disturbance in the evolution of the embryologic layers. The patient would not allow me to remove any

Dr. Burton Chance's case of unusual corneal condition of pre-natal origin

portion of the abnormal tissues; I can only conjecture as to their histology.

The lenses were dark and densely opaque and about the periphery of each there was a singular festooning of the superficial elements; there were neither stars nor radii. In all fields there was good light-projection.

The left crystalline was extracted by the combined method, without accident, after which the patient was able to recognize the window bars. The incision was made straight through the scleral tongue. The capsule was dense and very tough. The cataract was of a deep brown color; it was large and had but little cortical.

The healing progressed rapidly. In two weeks the lady came to my office; the eye was then quiet and a hasty trial of the vision gave 5/15. One week later a thin web of capsule stretching across the nasal half of the coloboma was discinded. On the removal of the Hays' Knife a good quantity of a rather viscid fluid exuded. For two days the lids remained slightly puffed and the globe was tinged for several days. After a week the media were seen to be clear and the fundus perfectly healthy; the vision 5/9. Two months later, with correction, the vision equaled 5/5, and with + 16 D. + 2 D., ax. 90 degrees, her daughter's reading spectacles, she read and sewed with perfect comfort.

CYANOSIS RETINAE.

BY HENRY H. TYSON. M.D.,
NEW YORK.

In 1861 H. Knapp first called attention to the changes in the fundi oculi known as cyanosis retinae. Forty-four years later, in May, 1905, Posey read his paper on that subject before this society in which he referred to the literature, citing eighteen cases including his own, with a brief resumé of each. Since then I have found no other recorded cases. Before reporting an additional case, a review of the etiology and pathology of general cyanosis due to congenital cardiac disease as accepted at present time and bearing upon the case may be of interest.

Various congenital cardiac diseases and malformations may cause fundus changes, viz.: "Foetal endocarditis, malformations resulting from imperfect development of certain parts usually septal, persistence of foetal conditions, *e. g.*, foramen ovale or ductus arteriosis."

Patent foramen ovale or defect in the auricular septum, although one of the most common congenital cardiac malformations, about 50 per cent., is not one of the most important; it rarely occurs alone but is often found with pulmonic stenosis, to which it is frequently secondary, or it may result from imperfect development. In pathological conditions the opening is from one-fourth to one inch in diameter.

Pulmonic stenosis is one of the most frequent and important lesions. It may be due to foetal endocarditis or to a malformation. It is more constantly associated with cyanosis than is any other congenital lesion. The amount of obstruction varies from a slight narrowing of the orifice to complete atresia.

While the symptoms of congenital cardiac disease are usually manifested soon after birth, they may not be noticed until after puberty. Cyanosis is the principal objective symptom and is present in over four-fifths of all the severe cases. It may be slight and only noticed upon exertion, or intense and constant, giving the skin a leaden color and the mucous membrane a raspberry hue. Holt states "that the view that cyanosis depends upon admixture of arterial and venous blood is generally discredited. In the great majority of the cases at least the explanation is a deficient oxidation of the blood in the lungs, owing to some interference with the pulmonary circulation. In 63 per cent. of the cases in his series of 242, there was found pulmonic stenosis or atresia or a small pulmonary artery. In cases with obstruction to the pulmonary circulation a polycythemia is present, the increase in the number of red cells being proportionate to the cyanosis, the average being about 7,000,000; the hemoglobin is usually correspondingly increased, in one recorded case 140 per cent. The number of leucocytes is changed very slightly, disproving the theory of blood concentration."

Fromherz considers hyperglobulia and macrocythemia as oxygen carriers to offer a functional counterbalance for the cyanosis. Calabrese considers hyperglobulia to be due to irritation of the blood producing organs by the overloading of the blood with carbonic acid gas.

The best explanation of the polycythemia seems to be that it is compensatory, and that the blood hypertrophies like other tissues, the blood forming organs are stimulated to greater activity by the demands for oxygen. The quantity of the blood remains the same, but the number of erythrocytes and hemoglobin increase and consequently the oxygen carrying power is very greatly increased. This in part compensates for the smaller amount of blood that can traverse the lungs and there become oxygenated. (Holt.)

A condition similar to the cyanoderma of congenital heart affections occurs in the permanent hyperglobulia with splenic enlargement and cyanosis, but without heart lesion, which has been described by Vasquez. As there are congenital heart lesions with only very slightly pronounced physical signs, the differential diagnosis between the two conditions can only be made by the presence or absence of a disproportionately large spleen.

After congenital cyanosis has existed a long time structural changes are found in the veins, which are dilated and have hypertrophied muscle in their walls. (Loubaud.) The capillaries become fibrosed and thickened, dilated and tortuous. The foregoing facts account for the prominence of the retinal vessels in these cases. Posey in his description of the vessels of the fundi in cases of cyanosis retinæ states that they attain a size which is rarely equaled in any other condition, this being particularly true of the veins, which may become enormously dilated and tortuous, the arteries, though usually similarly distended, being affected to a less degree, etc. I agree with him as to the veins being greatly dilated, but would state that in the fundi of some cases of dementia praecox I have observed veins equally as large, and in a few cases, in the acute congestive stage, even larger, as will be noticed by a view of the illustrations, the relative size

of veins to arteries being as four to one. This disproportion in size of veins to arteries being one of the principal ocular signs of the disorder, according to the Tyson-Clark syndrome. The case of cyanosis retinae which I am permitted to record came under my observation during the month of May, this year, and has the following history:

M. N., age 12 years. Normal labor — was not a "blue baby" at birth; breast fed up to nine months and apparently perfectly healthy. About two years of age during a convulsion, gastro-enteric in origin, he became blue, and this condition has persisted in varying degree ever since. Has had measles, pertussis and mumps. He has never been strong physically and although he plays and runs with other children he tires quickly and gets blue and very short of breath. He has severe palpitation after climbing stairs and often complains of feeling cold, especially in his hands and feet. Coughs upon exertion. Mentally he is very active and bright, but cannot concentrate his mind long at his books because his eyes tire and the print appears green to him and causes headaches. He is very nervous and excitable, but not as a rule irritable. Mental excitement produces very active cardiac palpitation. Appetite is very good and his digestion is normal. He has always been extremely constipated and is obliged to take cathartics daily. His chief complaint is dyspnoea upon exertion.

Physical Examination.— Perhaps a little undersize for a boy of 12 years, but well built and muscular. Skin has a bluish tint and mucous membranes are bluish black, as are also the tips of his fingers and toes, which are clubbed, due to venous engorgement. His heart seems slightly enlarged to right, action is of fair force and regular. Over the second and third spaces to the left of the sternum is a loud and harsh murmur with a musical element and apparently presystolic in time, although it is continued throughout most of systole with a soft, blowing character. This murmur is transmitted up along the course of the pulmonary artery and over the second space is felt a slight thrill. No other murmurs. The lungs show congestion at their

Illustrating
Dr. Tyson's case of
Cyanosis retinæ

bases. Abdomen, both liver and spleen just palpable, otherwise normal. Urine sp. gr. 10 12, acid reaction, no albumin nor sugar. Excess indican. Microscopic examination negative. Blood from finger: hemoglobin 120; white cells, 9,800; red cells, 8,080,000.

Drs. Walter James and L. H. Shearer, the latter to whom I am indebted for the general history of the case, concurred in a diagnosis of congenital patent foramen ovale with pulmonary stenosis.

(A faint idea of the cyanosis of his face, which happened to be slight upon the day that his photograph was taken, may be obtained by a view of the plates which Mr. Brulatour of the Lumière Process Co., of New York and Paris, France, kindly prepared for me.) The cyanosis shows itself in his ears, lips, mucous membrane of mouth, palpebral conjunctiva and finger tips. The injection of the ocular conjunctiva is due to dilation of vessels which also encroach on to the periphery of the cornea, the sensibility of which is diminished. Color fields are markedly contracted. Vision 20/20. Exophoria 6° distance, 12° near.

As will be noted by the drawing representing the fundus of the left eye (direct method), the fundus is much darker than normal, with a violet tinge; disc appears red, due to dilatation of capillaries upon its surface; veins are blue black, arteries of the usual color of veins, both being dilated and tortuous and extending to the periphery, the intensity of the cyanosis retinae varying with that of the general cyanoderma.

Nagel asserts that if the ophthalmoscopic examination reveals that the retinal arteries as well as the veins are darker and broader than normal, the presence of a connection between the two sides of the heart is assured; whereas if the darker coloration and tortuosity is limited to the veins, he believes that the existence of some other congenital lesion is indicated which does not permit of the admixture of venous with arterial blood. My case might be considered as a confirmation of this assertion, but before accepting this theory as the rule, we must consider as possible the fact that we may have conditions in which we

and as this had no effect whatever on the disease, I substituted Dionin in powder once daily and instillation of a ½% solution of atropin. Under this treatment the irritation subsided gradually in the course of a few weeks, but the opaque dots and lines were in nowise changed by the treatment. After the irritation had abated, I resumed the application of the yellow oxide of mercury salve, and this was continued for several months. Three months after his first visit to me the eyes were in a comfortable condition but the opaque dots and lines were as numerous as ever. At this time it seemed to me that the dots were less in number while the number of the short opaque lines was greater. The opacities were perhaps less in numbers at the periphery of the cornea.

During the following year I saw the patient about once every 3 months, but did not notice any material change in his eyes. The last time I saw him was October 17, 1906, more than two years after his first visit to me. He had no pain in his eyes and they gave him no trouble. His vision was about 6/10 in each eye. No improvement from glasses. The short opaque lines had become a little narrower and were less numerous in the central portion of the cornea of the right eye. In this upper part even now several small round opaque dots. There were no blood vessels in any part. The epithelial layer was intact but reflected unevenly. The accompanying sketch was made at this visit, both eyes were about the same. The visual field is intact and tension is normal in both eyes.

The case above reported seems to me to be very much like the case of so-called grill-like keratitis reported by Fehr (1) Similar cases have been reported under the name of trellised opacity of the cornea as well as lattice form opacity of the cornea by Bieber (2) Naab (3) Dimmer (4) Hauenschild (5) and Freund (6). They all speak of this disease as a very chronic affection of the cornea, which usually attacks several members of the same family. A comparison of my case with those above mentioned shows that it differed from them in this.

DR. KIPP'S CASE OF GRILL-LIKE KERATITIS

Both Eyes Aug. 28, 1904

Right Eye Oct. 17, 1906

Left Eye Oct. 17, 1906

that my patient was the only one in a large family who suffered from an eye disease. In its clinical features the case here reported bears a very strong similarity with those reported by the above named writers. It represents probably an early stage of this disease. As to the etiology of this disease we know nothing and treatment was of no avail in all of the cases on record.

Histological examinations have been few, they seem to show that a hyaline degeneration of the superficial layers of the cornea and of Bowman's membrane with secondary involvements of the epithelial layer is present.

According to Freund (6) the grill-like keratitis is characterized as follows:—I. It is a hereditary disease which makes its appearance after puberty. II. Its signs are grayish dots situated superficially under the epithelium, slightly raising the same and causing great unevenness of the surface of the cornea. The opacities are situated around the centre of the cornea. III. A diffuse opacity of the cornea which under the loupe is resolved in a grill-like network and in addition shows branching linear opacities running radially, especially in the beginning of the disease.

IV. The periphery of the cornea is always free from these opacities.

I have been unable to find the record of a similar case in the writings of American authors. The two cases described under the name of "family macular degeneration of the cornea by C. A. Veasey" (7) are probably of a similar nature, but their clinical features differ considerably from my case.

REFERENCES.

(1) Fehr, Centralblatt f. praktische Augenheilkunde. 1904 p. 173.

(2) Bieber, Uber einige seltene Hornhaut Erkrankungen, Inaug. Diss. Zurich, 1890, quoted from Naab (3).

(3) Naab, Die gittrige Keratitis, Zeitschrift für Augenheilkunde, 1899 Bd. II. p. 235.

(4) Dimmer, Zeitschrift für Augenheilkunde, 1899 p. 354.
(5) Hauenschild, Zeitschrift für Augenheilkunde, Bd. VI, 139.
(6) Freund, v. Graefe's Archiv f. Ophthalmologie 1903.
(7) Veasey, Transactions American Ophthalmological Society Vol. X. p. 387.

THE INCREASING IMPORTANCE OF TUBERCULOSIS AS A CAUSE OF OCULAR DISEASE. THE NEWER METHODS OF DIAGNOSIS AND THE TREATMENT.[1]

BY GEORGE S. DERBY, M.D.,

BOSTON.

This paper does not pretend to be a full discussion either of the literature or of the clinical and pathological aspects of ocular tuberculosis, but merely a report of observations which I have been making during the past ten months on the new tuberculin tests, and over a considerably longer period of time on the diagnosis and treatment of tuberculosis of the eye.

Up to a comparatively recent period, tuberculosis of the eye has been considered a rare disease. Horner's statistics show one case in 4,000; Groenouw's one in 4,600; Hirschberg's one in 5,000; Eyre's one in 3,000; Stephenson's one case of conjunctival tuberculosis among every 1,500 patients. More recently, Helbron reports that out of 15,000 cases observed in the Berlin clinics, one in every 200 was tubercular, and states his belief that the disease will be observed even more frequently in the future.

Wilder, in his address at the recent meeting of the American Medical Association, lays special stress on the need of more careful consideration of tuberculosis as a cause of ocular disease.

In 59 cases of chronic uveitis tested subcutaneously with

[1] Read by invitation at the meeting of the American Ophthalmological Society, July 16, 1908.

tuberculin by Stock, 61% gave a positive reaction; while in 23 cases of scrofulous disease, 87% reacted.

Hess reports over 50% of positive reactions to tuberculin in 100 cases of ocular disease.

Verhoeff has called attention to the frequency with which cases of scleritis and episcleritis react to this test, and among many others, Von Hippel and Bull have furthered our knowledge of the frequency of tuberculosis of the eye and of its treatment.

No mention of this subject can be made without referring to Stock's brilliant and exhaustive experimental investigations on animals. By injecting tubercle bacilli into the blood he was able to produce in rabbits, uveitis, scleritis, sclerokeratitis, and finally small nodules in the conjunctiva, and chalazion-like swellings in the lids.

It is easy to explain the great discrepancy between the earlier and the later figures on the frequency of ocular tuberculosis. In former years the diagnosis could be made only in one of two ways: either by the finding of tubercle bacilli in the diseased tissue, or by animal inoculation, and it is obvious to what a small number of cases one or the other of these methods can be applied.

The introduction of tuberculin has proved of the first importance, but unfortunately its general adoption has been slow, chiefly on account of the accidents which occurred before its dangers were appreciated. Then too, the subcutaneous test has its limitations, as it cannot well be applied among ambulant patients, and thus its use is confined to a comparatively small number of cases. Nevertheless, it has added vastly to our knowledge of ocular tuberculosis. The introduction of the new methods of performing the tuberculin test has greatly extended the applicability of this very valuable diagnosis agent. As to the value of these tests (I refer only to the so-called conjunctival or ophthalmo-reaction of Wolff-Eisner and Calmette, and to the cutaneous reaction of von Pirquet) it is not necessary for me to speak. For a very complete consideration of the subject I may

refer to Wolff-Eisner's work, published in the Beiträge zur Tuberculose, Band IX, Heft I, a monograph of nearly 200 pages, and 245 references. It must be admitted, however, that as yet there are many unsolved problems connected with these reactions, among which may be mentioned their relative delicacy, their relationship to each other and to the subcutaneous test, and the meaning of the various types of reactions which occur.

My observations with them were commenced last September, at which time comparatively few articles had been published, and nothing had appeared from the standpoint of the ophthalmologist. My intention therefore was first to determine for myself the applicability of the conjunctival test in the Out-Patient clinic, and later to investigate from the clinical standpoint the part played by tuberculosis in the etiology of ocular diseases. This test was therefore performed on a variety of cases, in many of which there was not the slightest suspicion of a tubercular origin. After sufficient experience had been obtained I limited my observations to those cases in which there seemed to be a likelihood of tuberculosis, and finding that the conjunctival reaction could not be made use of in many instances on account of binocular disease, the cutaneous test was added, and where possible in the later cases of my series both tests were applied, simultaneously.

For the conjunctival test, I first employed a tuberculin prepared by Dr. Baldwin of Saranac, and obtained through the kindness of Dr. John B. Hawes, 2d, and Dr. Cleaveland Floyd. My results were not as consistent with this as with the tuberculin supplied by the H. M. Alexander Company of Marietta, Penn., which I now use. This latter preparation comes sealed in sterile tubes in strengths of ½% and 1%, and I have used the 1% solution almost exclusively. For the cutaneous test I used first Alexander's old tuberculin in full strength and later a 25% solution, as recommended by Wolff-Eisner. For the control vaccination, I have employed a solution of glycerine and carbolic acid made up to correspond to the tuberculin. The vaccination

has been performed on the left upper arm, the two areas being about three inches apart.

My observations have been made chiefly among the out patients of the Carney Hospital and of the Massachusetts Eye and Ear Infirmary, and I am greatly indebted to the staff of the last-named institution, especially to Drs. F. M. Spaulding and L. W. Mansur, for allowing me to make use of their material.

Since the tests were carried out on dispensary patients, it was impossible to make as frequent observations as was desirable, and it is probable that a number of tests have been recorded as negative, which, had the patient been seen in less than 24 hours and followed for several days, a positive reaction might have been found. This only serves to strengthen the results obtained. Where circumstances permitted, an endeavor was made to have a general physical examination made.

I have tested about 150 cases, and 103 of these are reported in this paper. Of these 83 reacted positively; 18 were negative; and 2 were doubtful. The conjunctival test was performed 61 times; 45 positive, 14 negative, and 2 doubtful. The cutaneous test was performed 58 times; 52 positive, 4 negative, and 2 doubtful. On 16 patients both tests were performed. On 14 both were positive; once the skin test was positive and the conjunctival negative, and once both were doubtful. Taking up more especially the cases which were thought to be tubercular, either on account of the clinical type of the disease, the history, or the general appearance of the patient, I have 93 cases divided as follows: 43 cases classed as phlyctenular disease, because no better general term is available, of which 38 reacted and 5 did not; about 88%. 16 cases of relapsing sclerokeratitis, all positive; 100 %. 16 cases of scleritis, 13 positive, 2 negative, 1 doubtful; 81%. 9 cases I have classed as uveitis, in most of which the disease was chiefly in the anterior part of the globe. These were selected as possible tubercular from their general appearance, and from the lack of any other apparent cause. All reacted positively. Of 3 cases of interstitial keratitis, 2 were positive,

and the third, a healed case, had 18 months previously reacted to tuberculin subcutaneously, and had suspicious signs in her lungs. In 4 cases, showing vitreous opacities and cloudiness in the lens, one of which showed a peripheral choroiditis, one was positive, 2 negative, one doubtful. A case of tuberculosis of the conjunctiva gave a positive reaction. The other cases are scarcely worth mentioning, as most of them were among my early observations when I was merely experimenting with the reactions. Three chronic dacryocystitis, all negative; two optic atrophy, negative; one typical periodic episcleritis, negative; one corneal ulcer, negative; one in a man with enlarged glands, and in poor general condition, positive; one case of chorioretinitis, positive; an apparently healthy woman with a chalazion gave a delayed positive reaction.

In regard to the reactions themselves there are a number of points which may be of interest. In four cases there was a delayed reaction which did not take place until after 48 hours. All of these patients appeared to be in excellent general condition, which accords with Wolff-Eisner's belief that this is the reaction of the clinically healthy who have an encapsulated focus. Two of these reactions were conjunctival; one was cutaneous; and one showed the interesting feature of a delayed reaction to both tests. In this series of cases, the conjunctival reaction has not been especially characterized by the redness and swelling of the caruncle which is alluded to by so many writers. Not infrequently a marked injection in the lower bulbar conjunctiva, forming a pyramidal area with its apex at the lower limbus occurred.

Several of the conjunctival reactions were severe. In one case where the test was made on a supposedly healthy eye, the patient developed a mild episcleritis of three weeks' duration. A more careful examination showed the presence of a previous involvement in the form of a faint corneal nebula. One case of phlyctenular conjunctivitis of the right eye developed a similar condition, and also a small corneal infiltration in the previously

healthy left eye. This cleared up without incident. Several other phlyctenular cases developed an obstinate conjunctivitis of several weeks' duration. One exceptionally obstinate phlyctenular keratitis of six months' standing developed a severe inflammation in his healthy eye following the instillation. There was very marked scleral injection and a severe infiltration of the cornea. This is only now subsiding after three months. A negro with a tubercular involvement of the conjunctiva of the left eye (bacilli were found in a piece excised) gave a moderate positive reaction in the healthy right eye. He was referred to a tuberculosis clinic for general examination, and there, through inadvertence, received another test drop in the previously tested eye; an exceedingly acute conjunctivitis, with immense and hard swelling of the lids resulted. The eye presented the picture of acute gonorrheal disease. Luckily in ten days time it subsided without damage. In four cases, tuberculin was instilled into a diseased eye. The first has been mentioned, and resulted in a mild episcleritis. A drop of ½% tuberculin was instilled into the diseased eye of the previously mentioned negro, who showed tuberculosis of the conjunctiva. Nothing more than a mild reaction took place. A case which showed vitreous opacities and beginning cloudiness of the lens in both eyes reacted, but showed no lighting up of the ocular disease. The same was true of a case of chorio-retinitis.

Since there has been considerable discussion as to the value of the reaction obtained after a second instillation of tuberculin, the first test having been negative. I have excluded such cases from my series. In the few cases of this kind which I have seen, the second reaction has always been more marked than the first. Wolff-Eisner, however, believes that the conjunctiva only becomes sensitized to tuberculin in tuberculous individuals, be the disease either open or latent. Likewise I have avoided including any cases which have had tuberculin injections, in order to avoid that possible source of error.

In my hands the cutaneous reaction has apparently been

more sensitive than the conjunctival. The figures are misleading, however, as only during the latter part of the work have I used the second test, and therefore chiefly on those cases where a tuberculous infection seemed probable. Then again there was a considerably greater proportion of negative reactions with the first preparation of tuberculin which I used than with the later one.

There have been no untoward results from the cutaneous test in my hands. The reaction has varied in intensity, from a very slight redness and swelling around the vaccinated area to a very marked redness and puffiness of some extent, and several times to the formation of a bleb. In no case has the patient complained of pain or difficulty in using the arm, and in most instances he has not been aware that anything has taken place. Wolff-Eisner calls attention to the special value of this test to the ophthalmologist, and regrets that it has not come into as much favor as has the conjunctival test. On the other hand, various writers have objected to it as uncertain, except in infancy, and some regard it as too delicate a test. Wolff-Eisner believes that a positive conjunctival reaction points to active tuberculosis, while the cutaneous test may appear when there is a healed lesion. The exact relationship between the two has not been worked out as yet, and will not be until many cases have been tested simultaneously by both methods, and the results compared. As Wolff-Eisner points out, it is very desirable that this should be done, and that the subcutaneous test be also used, so that it may be determined in what degree the older and severer method may be supplanted by the newer and more convenient ones. The present weight of evidence tends to prove that the cutaneous test is specific, and of great value. If this be true, it will almost entirely supplant the conjunctival test in ophthalmology, for already in a number of cases, severe disease of the eye has been induced by the latter, while all that can be laid against the former method as yet is the exceedingly rare occurrence of a mild type of lymphangitis, very possibly due to faulty asepsis.

My limited experience had led me to fear the conjunctival test in all diseased eyes, even though the process is healed, and in the healthy eye when there is active disease of the cornea in the other. Also, as has been pointed out by several writers, the subcutaneous injection of tuberculin for therapeutic purposes is very likely to light up a fresh reaction in an eye previously tested, and may keep the eye inflamed over a long period of time. The cutaneous test takes but little more time in its application, is at least equally sensitive, and is harmless to the patient.

Since pathological statistics show that a very large percentage of subjects coming to autopsy have active or healed tubercular lesions, it is evident that we should not make a diagnosis of tubercular disease of the eye based alone on a positive tuberculin test. With a view to securing other confirmatory evidence, it has been my intention to have a thorough physical examination made of each case. This was impossible, as my observations were carried out on patients who could not be closely controlled, and most of whom had to be referred to other hospitals for the examination. Many did not return, and on others it was impossible to obtain reports. The examinations made were carried out to a large extent by men who have had very considerable experience with tuberculosis. I have records of 46 cases. Thirty-two of these 46 had physical signs outside of the eye which were regarded as suspicious. Four of the remaining cases gave a tuberculous history, either a parent or child of the patient being affected. Ten cases were negative. In other words, 69% of the cases examined showed some general evidence of tuberculosis.

Let us analyze these cases more closely. Of the 32 which were positive, 16 gave evidence of a pulmonary process. Sixteen cases out of 46 examined showed signs which were suspicious of a tuberculosis of the lungs. In 15 cases out of 46 there was evidence of a tubercular adenitis. One case had a tubercular spine, another had a tubercular knee.

Of the 10 negative cases, one was the conjunctival tuberculosis already referred to, showing the bacillus in the excised

tissue; four were in very poor general condition, but showed no definite signs. Two showed a slight daily increase in temperature.

Of the 32 positive cases, 17 had a phlyctenular keratitis, 9 a sclerokeratitis, 3 scleritis or episcleritis, 2 interstitial keratitis, 1 a superficial corneal ulcer. Of the 10 cases with negative physical signs, 2 were phlyctenular, 2 sclerokeratitis, 3 uveitis, 1 chorioretinitis, 1 interstitial keratitis, 1 tuberculosis of the conjunctiva.

To my mind the phlyctenular series is the most interesting and striking of all. We can no longer doubt that scleritis, sclerokeratitis and uveitis, are often of tubercular origin, but still there exists a doubt as to the cause of phlyctenular disease of the eye.

My figures, such as they are, point strongly to a tubercular origin. Out of 43 cases, 38 reacted to tuberculin, about 88 per cent. (which corresponds exactly to Stock's 23 cases tested subcutaneously). In 19 of my cases a physical examination was made and of these 16 gave some evidence of tuberculosis, nearly 89 per cent.—undoubtedly a greater percentage than will be found among a larger number of cases.

It is said that the phlyctenule is not a tubercular manifestation, first because its pathological structure is not typical of tuberculosis; secondly, because tubercle bacilli cannot be found in it; thirdly, because inoculation into animals does not produce tuberculosis. These objections may be met by the tuberculotoxin theory by which it is postulated, that these lesions are caused by toxins and not by living germs. To my mind the theory of which Wolff-Eisner is one of the chief exponents seems more probable. This states that the question is purely one of dosage, that where only a small quantity of tubercular material is deposited, then the pathological changes will not be characteristic and typical tubercle formation will not take place. The first change in a tissue produced by tubercular material may be simply the gathering of lymphoid cells. Unless

a greater degree of infection takes place, it seems plausible that epithelioid cells, giant cells and caseation may all be lacking. Thus we may get tuberculosis without tubercle formation. In this connection it is interesting to note that Wolff-Eisner believes that tuberculin depends for its action on fragments of bacilli which contain an endotoxin, which can only be liberated by lysins manufactured and present in the tissues of the tubercular individual. Furthermore, that the tubercular individual manufactures tuberculin in the body and when an excess is present the introduction of more tuberculin from outside fails to excite reaction, as, for instance, in tuberculosis of the third stage. This view is supported by the experiments of Calmette, Breton, and Petit, who obtained the conjunctival reaction after the introduction of small quantities of tuberculin, subcutaneously, into guinea pigs, but failed to obtain it when a large quantity was injected.

We know that the instillation of tuberculin into the eye has often produced a typical crop of phlyctenules and has even led to a typical phlyctenular keratitis. It is well recognized that often even in typical tubercular tissue it is difficult to find bacilli and that this tissue introduced into animals will not cause the disease unless a sufficient quantity be taken.

Müller in one case out of 20 infected an animal with tuberculosis by inoculating a phlyctenule. As is well recognized, this disease occurs most often in so-called scrofulous children, and it can be no longer doubted that scrofula is tuberculosis.

Since at autopsy tubercular lesions, healed or active, are found in from 40 per cent. to 90 per cent. of subjects, it follows that only in a small percentage of cases, most of them of a severe type, is the diagnosis made during life. There are then many mild cases, some of which are not seen by the medical man, and others in which the signs and symptoms are not clear enough to render the diagnosis possible. Most of these patients get well, and only in the event of autopsy is the disease manifest. In a large percentage of cases where it has been possible to make a definite diagnosis of tuberculosis, the disease has been in an

advanced stage and cure has been uncertain. This is especially true of pulmonary tuberculosis in which the finding of bacilli in the sputum clinches the diagnosis, but means advanced disease. I believe the same conditions exist in regard to ocular tuberculosis. Formerly only the hopeless cases, leading to the destruction of the eye, were recognized, while now we are beginning to recognize the milder types which are curable.

If tubercular disease of the eye is as prevalent as my figures tend to show, it will lie in the power of the ophthalmologist to take a more active part in the fight against tuberculosis than he can at present. We see hundreds of these cases in our clinics each year. My small series shows that many have signs pointing to tuberculosis in the lungs or elsewhere. These are the incipient cases that the tuberculosis expert wishes to reach. Even if the patient shows no general signs of the disease himself, he may be the means of directing attention to the whereabouts of an active focus of tuberculosis in the community. A few months ago I referred a child with interstitial keratitis and a positive skin reaction for general examination. The report came back that although her general condition was poor, there was nothing definite to be found, but that her mother, who was with her and not under medical attention, had an active phthisis.

Before taking up treatment, allow me to present one or two tentative conclusions. First, I believe that in ophthalmology it is rapidly becoming possible largely to discard the subcutaneous tuberculin test. In these newer reactions, especially in the cutaneous test, we have a far simpler means of diagnosis, and one that is productive of no harm to the patient. I have seen a number of cases in which, to say the least, recovery was retarded by the severe local reaction which followed the injection of tuberculin for diagnosis. It seems to me that the use of tuberculin in this way to confirm the diagnosis by local reaction should be employed only with the greatest caution, if at all.

The belief that the conjunctival reaction will be largely supplanted in ophthalmology by the cutaneous test or some other

procedure has previously been stated in this paper. Furthermore, undoubtedly, the need for these tests will decrease as we become more and more conversant with the appearance of ocular tuberculosis, for after all a positive reaction alone is but one link in the chain of diagnosis, possibly one of the weakest, and in any case not more important than the clinical type of a disease history, the general examination of the patient, the lack of another probable cause.

TREATMENT.

I shall endeavor to be as brief as possible and shall say nothing about local measures, as I have already taken up too much of your time. It seems obvious that these patients should be handled like other cases of tuberculosis. The strictness of the treatment should in a general way be proportionate to the severity of the disease. A mild case in a state of fair nutrition may need but little attention, whereas, the patient with severe recurrent sclero-keratitis and with signs in the lungs may need a very careful regimen. It is very easy to give advice to a dispensary patient in regard to general hygiene, but it is exceedingly difficult to compel him to do anything for himself unless we have a means of controlling him. We cannot take all these patients into our hospitals, and most of our eye hospitals, I believe, have poor facilities for handling this disease. I believe the most practical way of treating these cases is by means of the tuberculosis class, and I have been fortunate in being able to refer many of my patients to the tuberculosis class of the Massachusetts General Hospital, which is run in connection with the invaluable Social Service department of that institution, and is under the charge of Dr. John B. Hawes, 2d, and Dr. Cleaveland Floyd, to whom I owe a large debt of gratitude. There the patient is carefully examined, weighed, and the temperature taken. He is given explicit directions as to general living, fresh air, amount of food, exercise, and the like. He is given a book in which to make a careful record of his daily life. He is visited

in his home by one of the class workers, and is shown how to live in the fresh air, and occasionally he is helped financially when that is necessary. He reports to me as often as desirable, and once a week at the class.

We have been able to handle our patients very satisfactorily by this method. Of course it will not do for all, as some need still stricter measures before improvement will be noted. Some of these we can refer to the day camp in the warmer seasons of the year, and occasionally a case is sent to the sanatorium.

It seems to me that our first indication is to build up the general health of these patients by every means in our power, and to impress them with the fact that tuberculosis is a chronic process and that a cure is at least a question of months.

I have no statistics as to treatment to present, for of the 40 odd cases which I have followed, none has been under treatment longer than two years, and a number for only a few months. I have under treatment now some 30 patients, among which are nine cases of sclerokeratitis, ten phlyctenular keratitis, five scleritis and episcleritis, one interstitial keratitis, five uveitis, one tuberculosis of the conjunctiva.

There is no doubt as to the great improvement in the general condition of all these patients, and it has been the greatest satisfaction to observe with what faithfulness they have followed our directions and have continued under treatment for month after month. In most of our cases tuberculin has been used. At first we injected it at the eye clinic, beginning with 1/500 of a milligram of the old preparation. It did not take long to convince us of the power of this agent.

We obtained general and local reactions with as small quantities as 1/200 and 1/100 of a milligram, and on several occasions the patient undoubtedly suffered. Since then I have believed that tuberculin should only be administered by the expert. Our patients are now injected once a week at the tuberculosis class, the initial dose being 1/100,000 of a milligram of the T. R. The dose is very gradually and carefully increased and when the

patient tolerates it, may reach several milligrams. It has seemed to Drs. Hawes and Floyd and myself that these eye patients are especially susceptible to tuberculin, that they are very quick to react locally and get a rise of temperature. In several cases it has been impossible to increase the dose to any great extent. With one, even after months, we could not get above 1/2000 of a milligram. As a rule the production of a local reaction in the eye has seemed to do harm.

My observations on the use of tuberculin in some 30 cases have not convinced me of its therapeutic value. Neither has it seemed to do harm when the proper precautions have been observed. We are still using it and expect to continue. On the other hand, it has been evident that careful and scientific building up of the patient does good and under it and appropriate local measures these patients get well, unless the disease has progressed too far before treatment is instituted.

Allow me to report very briefly a case which shows markedly the results of careful treatment.

Lizzie Drennan, 38 years old, came to the Carney Hospital, January, 1907. For years she had been subject to recurrent attacks of ocular inflammation which have materially reduced her vision. The patient had a typical sclerokeratitis with extensive corneal scars, thinning of the sclera, a few posterior synechiae, V. = 10/200 O. U. She was taken into the hospital and reacted generally and locally to subcutaneous injection of tuberculin. We gave her tuberculin injections in the hospital and had much trouble in avoiding a reaction. As she did not improve she was referred to the tuberculosis class on March 7th. At this time her weight was 138 pounds, temperature 99.2, and there were suspicious signs at the right apex. Both eyes were inflamed. She was made to reduce her home work to three hours a day, to stay out of doors six hours on a balcony, and she slept with three windows open.

She took from three to four quarts of milk in the twenty-four hours. There was but little improvement in her eyes for

two months. Then they quieted down and for a year past they have given no trouble. December 12, 1907, her temperature was normal, lungs negative, weight increased from 138 to 166 pounds. She was then taking 7/1000 of a milligram of tuberculin and was the picture of health. Treatment was then stopped except for general precautions and she has remained well since.

As a whole our results have been very encouraging, and I hope to report at length on them at some future time. The only cases which I have had where there has been a permanent diminution of vision are two of uveitis in which there were extensive posterior synechiae when the patient first came under observation. In one of these cases an iridectomy was followed by an almost complete opacification of the cornea.

Discussion.

DR. P. A. CALLAN, New York: I have been very pleased to hear the conclusions of Dr. Derby, especially as to the eye test. Personally I cannot speak very much about the test, but owing to the unfavorable reports I have been afraid to try it. For five years I have been using it subcutaneously and have come to the conclusion that we are all more or less tuberculous. I say this advisedly. In the majority of the patients I got reaction, both local and constitutional. I am satisfied, moreover, that I did harm in some instances. I didn't use it as a means of therapeusis but simply as a means of diagnosis and I used it on syphilitic cases especially. As I say, I got a reaction in the majority of cases. I think we should go slowly. Because you get a reaction from the subcutaneous test it doesn't necessarily follow that you have tuberculosis to deal with.

DR. F. H. VERHOEFF, Boston: It seems to me that these new tests are of very little value in individual cases but are of great value in statistical studies such as Dr. Derby has made. In a particular case a reaction may mean only that the patient had tuberculosis in childhood which has entirely healed, while the present trouble may be due to syphilis or something else. In infants, however, the tests are of more value because time has been insufficient for complete recovery from the disease.

In regard to the cause of phlyctenular conjunctivitis, most

of us, I think, are now convinced that it is always tuberculosis. The ocular lesions themselves, however, have never been satisfactorily explained. The theory that they are due to the direct action of toxins is not convincing. I would suggest a theory brought to my mind by the recent experimental work on hypersusceptibility or anaphylaxis. This theory is also based upon the action of toxins, but not a direct action. It has been found that if a small amount of horse serum is injected into a guinea pig no apparent harm results, but that if this is followed after a certain interval by a second dose death ensues. Definite local lesions have been found by Gay and Southard. Vaughn has found that egg albumen acts in the same way, and the principle is now believed to be of general application. The explanation given is that certain tissue areas are sensitized by the first injection, which reacts to the second. Suppose now a child becomes infected with tuberculosis, perhaps of the bovine type. Suppose further that the infection is quickly overcome. Before the activity of the bacilli has ceased, certain tissues have become sensitized by the tubercular toxins, notably certain areas in the conjunctiva and cornea, in the skin, and the mucous membrane of the nose. At a later period, which may be quite remote, a reinfection occurs or the old bacilli become active again. The fresh supply of toxin thus produced reacts on the previously sensitized areas, and gives rise to inflammatory foci in the form of phlyctenules, eczema of the face, chronic rhinitis, and possibly also the adenoid hypertrophy in the naso-pharynx.

The focal character of the lesions might be due to some peculiarity in the tissues sensitized, or less likely to the lodgment of tubercle bacilli which before their destruction sensitize the areas in which they lie.

In confirmation of this theory we have the facts that phlyctenular conjunctivitis has been produced by the subcutaneous injection of tuberculin and also by the ophthalmic test.

DR. W. G. N. BYERS, Montreal: I would add my word of congratulation to Dr. Derby and express my satisfaction that his studies have led him to the broad conclusions he has enunciated. He has pointed out the part that we as oculists should play in the general fight against tuberculosis and has given us useful suggestions as to the treatment of tuberculous patients and methods to be adopted for the general supervision of these patients.

My attitude from the first in regard to the ocular reaction was a very conservative one. It is a matter of satisfaction to me that Dr. Derby has laid so much stress upon the relative value of the cutaneous as compared with the ocular reaction.

DR. G. E. DE SCHWEINITZ, Philadelphia: I can confirm from my own experience the dangers of the Calmette test, to which Dr. Derby has made reference. I have watched with much interest all of the cases in the University Hospital in which this test has been applied, and have had the usual experience of seeing in several instances intense conjunctivitis, on several occasions the development of elaborate phlyctenular disease, and in one particularly interesting case a series of subconjunctival hemorrhages, so extensive that they lifted up the bulbar conjunctiva. I have been particularly gratified in the treatment of phlyctenular disease in my dispensary at the University Hospital, where we have had the opportunity of having the cases followed to their own homes by the social workers in the same manner as Dr. Derby describes, because in this hospital we follow the same plan which is adopted in Boston. It is a very easy thing to tell the mother of a child who is the subject of phlyctenular keratitis that she must have this kind of diet and that sort of remedy, but often the mother is unable to follow the advice. If, however, one of the workers goes to the child's home and sees that all of the directions are followed out, the results are extremely good.

DR. G. S. DERBY: I did not for a minute intend to state that I thought the value of the tuberculin test should be considered too highly. I have seen the subcutaneous test do harm in a number of instances. The skin reaction, of course, does not. The production of a local reaction in the eye seems hardly justifiable for a diagnosis, unless it is in a special case.

DR. RISLEY: Not even in a case where the inflammatory condition in the eye suggests tuberculosis?

DR. DERBY: I have set the patient back a week or more by the local reaction in the eye and it does not seem to me a fair thing to do in constitutional cases.

ANGIOMA OF THE CHOROID

BY ALEX. QUACKENBOSS, M.D.,

BOSTON, MASS.

Pathological Examination by F. H. Verhoeff, M.D.

Bessie B——— age eleven, was seen at the Massachusetts Charitable Eye and Ear Infirmary, August 30, 1907. The story was as follows: A short time after birth the parents noticed that the right eye had a peculiar look, as if there was a white substance inside of the eye: As the child grew older this condition became more noticeable. The sight was always defective and for a number of years there has been absolute blindness. For several years the eye has at times been red and painful.

Examination shows a well developed girl of eleven; on the right lower lid, extending down onto the cheek, is a naevus, port-wine mark. On looking at the eye, your attention is at once attracted by a yellowish reflex from the fundus; this is easily seen at a distance. The vision of the eye is nil, there is slight ciliary injection, the pupil is moderately dilated and displaced to the left, there is no pupillary reaction, the iris is atrophic, there are a few blood vessels upon the iris, the anterior chamber is shallow. Tension plus. Examination of the fundus shows a complete separation of the retina, the retina being pushed well forward.

A diagnosis of secondary glaucoma was made; the eye had the appearance of glioma or pseudo glioma, the history of long duration practically ruling out a malignant growth. The eye being painful and having no vision, enucleation was advised. Operation under ether without incident. The report from the laboratory revealed the true nature of the case.

Angioma of the choroid is very rare. Parsons, speaking of the rarity of this condition, says that it should not be con-

fused with angio-sarcoma, which is less rare and very malignant. The condition is congenital and is apt to be associated with naevus of the face. Most of the cases have been observed in young people, but the age of reported cases ranges from five to sixty-nine.

Diagnosis is possible only after pathological examination. The first symptom usually complained of is disturbance of vision, then ensues a period in which the sight gradually diminishes, or it may remain stationary for a number of years only to fail suddenly. Then follows a second period in which there is complete blindness, but the eye remains quiet and free from inflammatory symptoms for several years. Eventually the eye becomes inflamed, the tension is increased, secondary glaucoma develops and enucleation is required to relieve pain.

Meller reports a case of angioma of the choroid in a woman of thirty-three who accidentally discovered impairment of vision five years before the onset of glaucomatous symptoms. During the five years there had been gradual loss of sight leading to complete blindness, but no attack of pain. During this period the patient was greatly annoyed by photopsia, in the shape of fiery rings, the attacks lasting several minutes. Meller thinks the photopsia is due to mechanical irritation of the retina, caused by the varying pressure of the angioma.

Angiomata usually occur in the posterior part of the choroid but may occur in any part. Parsons thinks that they show no uniform relationship with the foetal choroidal cleft, as only two cases are reported as definitely situated in the lower quadrant. The tumor may involve all layers of the choroid or simply the choroidea. They usually have no capsule and fade off imperceptibly into the surrounding normal choroid. The minute structure is that of ordinary cavernous angiomata, there are a number of large irregular spaces filled with blood, the spaces are lined with endothelium and separated from one another by thin fibrous walls.

Pathological Examination:— After fixation in formalin the

FIG. 1.—Photograph, showing angioma of chorioid in greatest cross section.

globe was sectioned without freezing. Diameters of globe: antero-posterior, 24.75 mm.; vertical, 23 mm.; horizontal, 24 mm. The cornea, 12 mm. in diameter and 1 mm. thick, is clear. The anterior chamber is 2 mm. deep and free from coagulum. The filtration angle is blocked by the root of the iris for about 1 mm. all around. On the temporal side there is a beginning intercalary staphyloma. The ciliary body is atrophied and its processes elongated. The lens, 7 mm. x 2.5 mm. in size, is cataractous and calcareous, and is retraced 3 mm. behind the iris by the separated retina. The retina is completely separated in the form of an irregular funnel and converted into an opaque membrane. The pre-retinal space contains a delicate fibrillated tissue, evidently contracted vitreous humor. The sub-retinal space contains coagulum. The choroid over the greater part of the fundus is replaced by a reddish friable mass whose cut surface on close examination is seen to have a finely honeycombed appearance. This mass surrounds the disc but does not extend over its surface. On the temporal side it attains its greatest thickness, 7 mm., and reaches the equator. In the nasal side it reaches the ciliary body but attains a thickness of only 2 mm. The greater part of the surface of the mass is covered with a layer of hard material, apparently bone, in places 2 mm. thick. To this posteriorly the retina is firmly united. Adherent to the surface there are also several small collections of blood containing glistening dots.

Histological Examination: Decalcification in 5% nitric acid. Celloidin sections. The cornea shows a few superficial scars, but is otherwise normal. The episcleral tissue shows marked venous congestion but no infiltration with inflammatory cells. The iris is highly atrophic, and at the periphery, where it is united to the ligamentum pectinatum and cornea, its stroma has in many places entirely disappeared, leaving the pigment layer alone. The ciliary body and processes are atrophic but much less so than the iris, and are markedly congested. There is no cyclitic membrane. The separated retina everywhere shows advanced gliosis and is

much disorganized by cicatricial contraction. The multipolar ganglion cells and the rods and cones have entirely disappeared.

Microscopic examination of the choroid shows that it is pervaded throughout by a cavernous hemangioma. The blood spaces are remarkably uniform in size, averaging about .14 mm. in diameter. None of them contain thrombi. Their walls usually consist of an extremely thin layer of connective tissue, which stains feebly after Van Giesen's method, lined by a single layer of endothelium. The spaces are so closely placed that often the same wall serves for two, while not infrequently the spaces are separated by a layer of endothelium only. The stroma of the tumor, aside from that forming the walls of the spaces, is also extremely scanty, consisting of delicate fibrillated connective tissue situated in the triangular areas between the blood spaces. Sections stained differentially for elastic tissue show none present within the growth. The tumor thus consists mainly of a mass of blood permeated by an insignificant amount of connective tissue.

Pigmented chromatophores, evidently remaining from the original choroid, are fairly abundant in the tumor. Their pigment fails to give the iron reaction and is readily bleached by the method of Alfieri. Strangely enough, the tumor proper contains no pigment which gives the iron reaction. In places, however, the retinal pigment epithelium is packed with iron pigment arising no doubt from repeated intraocular hemorrhages.

The normal structure of the choroid is almost entirely lost except just behind the ora serrata. The chorio-capillaris, however, is frequently intact, although it is sometimes replaced by fibrous connective tissue. A large portion of the surface of the growth consists of plates of true bone the medullary spaces of which are frequently filled with adipose tissue. Sometimes they contain the cavernous tissue of the angioma proper. The pigment epithelium is lost over the thickest portions of the bony plates but is continued over their margins so that their origin is plainly in the choriocapillaris. The pigment epithelium shows an enormous development of colloid excrescences. These are

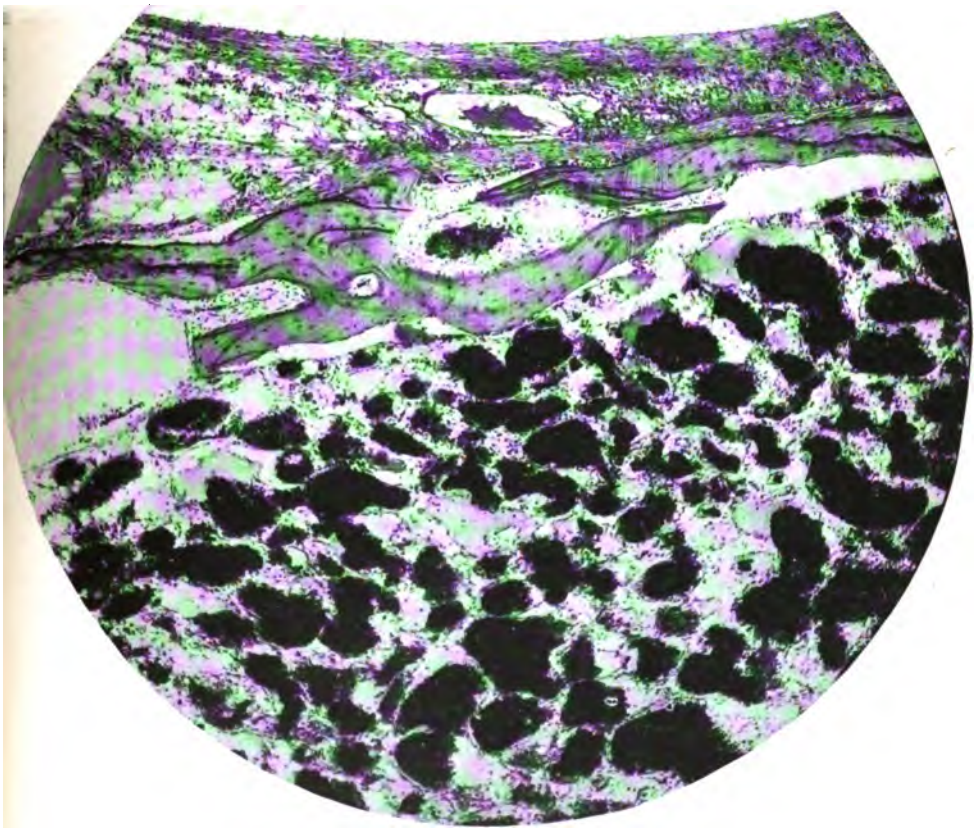

FIG. 2.—Photograph of section, showing cavernous structure of angioma and ossification of chorio-capillaris. Mag. x-62.

especially marked anteriorly, where by fusing together they form in places an almost continuous layer. Some of them show calcification, but none have become organized or ossified and are clearly not concerned in the formation of bone. Beneath them the choriocapillaris is often intact while the elastic tissue of the membrane of Bruch is always so. Many of the colloid bodies show, in addition to the well-known concentric lamination, a fine radial striation. This is best seen in sections stained in phosphotungstic acid hematoxylin. The membrane of Bruch fails to show the granular degeneration commonly seen in association with colloid excrescences in senile eyes. The small hemorrhagic extravasations attached to the surface of the growth contain no fibrin and show no disintegration of their red corpuscles, although the latter stain more feebly than normal. The presence of numerous characteristic spaces left by cholesterine crystals shows, however, that the hemorrhages are fairly old.

Neither the optic nerve nor the retina extending out from it have been invaded by the growth. The nerve stem is completely atrophic. Serial sections of the sclera at the points of exit of two of the vorticose veins fail to show any extension of the growth through the sclera. The veins themselves show marked endophlebitis. There is also endovasculitis of some of the posterior ciliary vessels, with complete obstruction in some cases.

Pathological Diagnosis: Cavernous angioma of choroid. Ossification of choriocapillaris. Secondary glaucoma. Calcareous cataract. Separation of retina. Intraocular hemorrhages.

REFERENCES:

Parsons, Pathology of the Eye, Vol. 1.
Meller, Zeitschrift f. Augenheilkunde, Jan. 1907, p. 50.
Fehr, Centralblatt Augenheilkunde, June, 1905, p. 161.

DISCUSSION.

DR. S. D. RISLEY, Philadelphia: It may be of interest to place on record here a case I have had under observation twelve

or fifteen years; to wit: a woman, aged twenty, who came with a large port-wine deformity on the right side of the face and a totally blind right eye, with deep glaucomatous cup, but no angioma of the chorioid — only deep cupping of the disc. The left eye was healthy.

THE TELEOLOGY AND INTERPRETATION OF NYSTAGMUS.

By PERCY FRIDENBERG, M.D.,

New York.

The peculiar disturbance of ocular motility which forms the subject of this paper has been one of particular interest to ophthalmologists, because of its frequent association with congenital amblyopia, to neurologists, as a concomitant of various affections of the central nervous system, and of late years especially, to otologists, on account of its practical importance as a symptom of labyrinthine involvement in otitis. The publications in this field are numerous, and there is a wealth of data as to the clinical details of nystagmus, the direction, rate, and character of the faulty movements, and a corresponding variety of theories as to their pathology, etiology, and mode of development. It is not the purpose of this paper to contribute to any of these subjects, but rather to review the material already at hand, in the light of a uniform hypothesis as to the nature and significance of the function of ocular fixation, and of its disturbances. It has seemed to the writer that something might be gained for the practical purposes of the clinician, oculist or aural surgeon, by a methodical analysis of this complex symptom; an attempt to explain its physiological and neurological rather than its purely nosological significance, and to offer a tentative basis of interpretation from the standpoint of biology. At the very beginning of our investigation we are struck by the lack of uniformity in the clinical material, and the resulting discrepancy of statements as to the nature of the motor anomalies described as nystagmus,

and further study soon leads us to distinguish two main classes of this anomaly which are different not only clinically, as has already been noted by A. Graefe, but as I believe, physiologically as well.

A metaphysical consideration impresses on us, as a preliminary, the conception of ocular fixation as a function of dual significance to the sentient individual, having as its purpose not only the purely visual perception of things, as such, but also and equally, the no less important conceptions of the relation of those things to the subject, and of the latter to the sum of things perceived or conceived, that is, to ideal space. It is a question how far these conceptions depend on visual and oculomotor impressions, whether they are directly due to sensory nerve action at all, or whether, as physiologists of authority claim, they are not rather mediate results depending on processes of judgment. Recent advance in the study of the anatomy of the inner ear and its neural relations to other peripheral sense organs and to the cerebrum would appear to show that there is a very intimate and complex relation between the labyrinth and the centers for associated movements of the eye, which logically postulates a corresponding physiological and psychological interdependence of these two organs. Breuer and Mach have shown that the labyrinth is the organ of perception for changes of position (static organ; otoliths) and direction of rotation (dynamic organ; semicircular canals) and any modern study of nystagmus must take into consideration not only the visual but the equilibrational aspect of this very involved and interesting question.

In his latest publication, an extensive monograph on the labyrinth, v. Cyon (1908) has even advanced the theory that the inner ear is the organ for the perception of direction, and mediately for the conception of time and space, and number. Three-dimensional space is a concept depending on a specific function of the three semicircular canals, and our geometrical systems, in fact, all mathematical ideas and reasonings, are based on data received, originally, from the organ of hearing and

equilibrium. The acoustic labyrinth, so called, serves indirectly to bring about conceptions of time and number by the regular quantitative differences in the tonal perceptions which it mediates, and their reference by the psyche to logical, i. e. causal, factors. While much of this author's argument is metaphysical, his main thesis is based on many years of careful and varied animal experiment, and a most thorough and painstaking study of the phenomena of equilibration. However much we may hesitate, at present, to follow him to the logical limits of his far reaching conclusions, there is no doubt that his theory of the labyrinth, starting, as it does with data which have formed the basis for the Breuer-Mach hypothesis, and by an imaginative yet thoroughly logical process of reasoning leading to an assumption of almost infinite significance, must be taken into account in any scientific attempt at a philosophic analysis of our ideas of space, and must, above all, lead to a broader conception of the functions of the organ of vision. It is this idea of the visual processes as part of a complex mechanism for the maintenance of equilibrium closely interrelated with the labyrinth, and with its cerebral centers for the judgment of and adjustment to direction, motion, and space — an idea which is neither original nor novel, yet which has been overlooked in theoretical discussions as well as in practice — that I have taken as a basis for my study of one of the most interesting and complex as it is one of the most obscure, of oculomotor anomalies.

My thesis is, that nystagmus is neither clinically nor teleologically susceptible of a single interpretation and uniform characterization, but that we must recognize, in the multiplicity of disease forms, two main types, which differ widely, not only in their evidential features, but as I shall attempt to show, in their mode of development, nosological significance, and psychological bearing. These two forms represent characteristic and superficially similar disturbances of ocular motility, but they can best be understood as anomalies, the one, of macular fixation, and the other, of eye motion for direction, ideal or actual, and, mediately,

of subjective position, and of objective space. To indicate broadly the two forms which I wish to separate, we may speak of them, in terms which have already been applied clinically, but which, as we shall see, are not strictly correct, as congenital and acquired, as visual and directional, as autogenous and reflex, as idiopathic and symptomatic, as paretic and spastic, according as our point of view is that of etiology, physiology, clinical analysis or neuro pathology.* The application of these, and of a number of other methodological criteria, may now be made the basis of our differentiation.

Congenital Nystagmus. This form is usually observed as a result of partial loss of vision in early infancy, before the function of macular fixation has been acquired. The theory that it is due to concomitant developmental arrest in the central nervous system, that it is in fact of neuropathic origin, has been generally

* The characterization of either form of nystagmus by a single term which shall be accurate as well as definitive, meets with the difficulties inherent in any attempt to equalize the conflicting claims of scientific terminology and those of practical utility. "Congenital" and "acquired" are neither strictly true nor to be applied without limitation, as the first form is not inborn but acquired in early infancy, before the development of the centers for fixation, while a practically identical type appears later in life, as a symptom of at least one affection of the central nervous system, namely, multiple sclerosis. This fact also militates against the use of the terms idiopathic and symptomatic. The strict opposition of "visual" to "directional" or "fixational" is partially nullified by the obvious consideration that all nystagmus is to some extent at least visual. "Autogenous" and "reflex," again, are open to the objection that one form of fixational nystagmus, that occurring in paresis of the abducens, is, strictly speaking, autogenous, although clinically it is directional. The antithesis of the two types is not absolute, but approximate only, except for forms which, as will be shown later, are at the two extremes of a continuous series which shows a number of mixed as well as of transitional forms. "Paretic" and "spastic" apply not so much to the muscular mechanism involved as to the centers of fixation and points of reflex excitation (labyrinth, cerebellum) which are in a state of partial or complete paralysis, due either to the lesions of disease, or to non-development, on the one hand, and in a condition of abnormal activity as a result of pathological or artificial irritation, on the other. The congenital form is also spoken of as oscillatory or undulatory. Amblyopic nystagmus would, perhaps, be the best descriptive term. The acquired fixational form is now frequently referred to as "nystagmoid twitching," and might similarly be characterized as directional or equilibrational, if the latter adjective be not, as it so frequently and incorrectly is, limited to the labyrinthine type; a nomenclature which ignores the important rôle of vision and of ocular motions in the broad function of equilibration and the sense of direction and space.

abandoned, for the following reasons. It can not logically be supposed that the same selective action on a single center, that of fixation, would accompany a variety of ocular lesions, many of which are, evidently, not neuropathic at all. Again, there is frequently no developmental defect of the organ of vision whatsoever, the deterioration of vision being due to mechanical interference with the entrance of light into the eye, as in leucomata due to ophthalmia neonatorum, or to intraocular inflammation acquired soon after birth. Bumm has called attention to the frequency of retinal hemorrhages intra partum, and showed that these might become absorbed later on, leaving no trace, and giving color to the view that the resulting amblyopia and nystagmus were congenital.

Clinically this form might be described as an eye tremor, as it is a restless, pendulum like motion (A. Graefe) in a certain definite direction, which, although independent of volition, does not hinder or inhibit voluntary eye-motions, but accompanies them in their individual type. The nystagmus may be horizontal, vertical, or mixed, or purely rotational, depending, in the last instance, on the action of the oblique muscles, in abduction, and on that of the superior and inferior rectus in adduction. The excursions are uniform and fairly rapid, and have absolutely no directional effect. That is, the net result of the ocular motion is an oscillation or undulation about a point which may be designated as the zero point, or point of equilibrium. From a neurological aspect this undulatory nystagmus could be considered as a paretic tremor. The motion could be registered graphically as a wave similar to that of the double vibrations of a tuning fork; the ordinates representing the amount of excursion of the globe, and the abscissae, the time interval, with uniform, equal, and regular excursions on either side of the wave path, resulting in equal positive and negative phases. Biologically we have to deal with a series of non-purposive, or at least not adapted motions which are not in the interest of clear vision, and which from the phylogenetic standpoint might fairly be considered as a reversion to

a lower type of function. Descending in the scale of animal life we reach a more and more rudimentary form of fixation, which, apparently paradoxically, is associated with increased complexity of structure and apparent variety of function. At the lowest stage we have constant motion in place of interrupted, graduated and adapted action, which is fairly constant in intensity no matter what the stimulus. In this respect vision on this low plane resembles the tactile sense, from which, as we know, the sense of sight has been evolved, being spread over a large part of the ectoderm and susceptible, while only partly adjustable, to a great many stimuli. Functional evolution goes hand in hand with a regional limitation, and more marked differentiation of the respective phases of rest and activity. The motions of congenitally nystagmic eyes, like those of the invertebrates, suggest the pseudo-pods and tentacles of some marine animals, with their incessant, aimless weaving motion.

The development of a similar oscillatory nystagmus in later life as a result of disseminated sclerosis, and possibly of cerebrospinal syphilis also depends on destruction of once normal supranuclear fixation centers, and has its analogy in other fields of neuro-pathology (senile tremor).

Congenital nystagmus is generally due to affections of both eyes; the most common causes being partial opacities of the media, remains of fetal disease, developmental anomalies, albinism, complicated or high grade refraction error, and color blindness. Amblyopia is the usual accompaniment. In these cases there is no sensation of eye motion or of apparent motion of objects in the external world. The nystagmic motions of the eyes are not seen in the mirror by these patients, who in this respect resemble normal individuals. The faculty of abstracting from this impression, or rather of not having any impression, is cited by Graefe as the highest attainment of empiristic training of the sense organs, like the regional exclusion of the image of one eye in strabismus. To the writer, this phenomenon, at least in "congenital" nystagmus, appears to be susceptible of a more

logical explanation on the assumption of a faulty development or a non-development of local signs, retinal as well as cerebral, under the combined influence of amblyopia and ocular tremor. Among other characteristics of vision in these cases we note that binocular vision is unchanged, that disjunction by prisms shows fixed images, and that stereoscopic vision and fusion reaction take place as usual. Voluntary motions of the eyes are usually limited, and have little or no effect on the degree of true congenital or oscillatory nystagmus. The latter has no symptomatic bearing, except in so far as it enables us to postulate visual defect developing in early infancy, and consequent non-development of the fixation faculty.

Acquired Nystagmus. The most striking clinical features of this form of nystagmus are its frequent occurrence in labyrinthine and cerebellar disease, its association with vertigo, and the directional character of the eye motion. Neurologically it may be described as a clonic spasm of fixation; the twitching character being striking and invariable. A graphic representation of this form would show a series of half waves all on one side of the wave path, with a marked lack of correspondence between the ascending and the descending portion of the wave, although the amount of excursion, and the rate are uniform. The ascending portion of the individual curve is almost straight, corresponding to the twitch of the eye. It is this rapid motion according to which the nystagmus is said to be to the right or left, toward the affected side or toward the sound side, and so on, as it is the most striking of the two phases and seems to indicate the direction most accurately. The descending curve is a more gradual and slower one, and represents a return to the position of equilibrium, that is, to the zero point, but it is to be noted that there is never a negative phase, and that consequently there is no oscillation. The net result is a directional clonus, as stated above. Studies of normal fixation have shown that this directional nystagmus corresponds exactly to the muscular adjustment of the eye in fixing objects in progressive motion through space.

The rapid motion is a motion of compensation ("Einstellung" of the Germans) intended to bring a new object or series of objects into the field of macular fixation, and during this motion there is no distinct vision. A similar leap may be observed in reading the narrow columns of a newspaper; the compensation motion from right to left, *i. e.*, backward to the next line, being associated with only the most indistinct visual impressions. The slow phase of the curve is the actual fixational component and this motion takes place in the direction of the motion of the objects in external space, following and keeping pace with their change of position, whether real or subjectively conceived. This form of fixation clonus, which is clinically identical with fixational nystagmus, may be observed in its most typical form in looking out of the windows of a moving car at passing objects. In spite of the intensity and frequency of these motions, which can be seen so strikingly in others, we are absolutely unconscious of the motions in our own eyes. The reason for this is probably to be sought in a psychical adjustment, by which the ocular motions are brought into logical, causal connection with the visible motion of external objects, and an unconscious judgment, causing us to abstract from and disregard the ocular motion. It is significant that there is absolutely no vertigo in this form of fixation, and that dizziness develops only, as Nagel has pointed out, when the external objects cease, apparently, to turn, and the sensation of subjective motion arises. The determining factor in the development of vertigo is accordingly neither the sensation of objective nor that of subjective motion, but a discrepancy of sensations, causing conflicting or antagonistic conceptions of position or motion. The resulting confusion and disagreeable feeling which we call dizziness, and which is rarely a sensation of actual turning (rotational vertigo) might be explained by an application to the field of sensation of the principle of contrary innervation which Meltzer has adduced in analysing motor disturbances such as cramp.

The symptomatic significance of fixational nystagmus de-

pends on its strikingly directional quality, and to a certain extent on the manner in which it can be elicited. Thus there are forms of occupational nystagmus, such as that observed in miners, which is due to the combination of poor illumination and prolonged forced position of the eyes. The theories that this form is neuropathic, and that it is due to the bad air of the mines have been disproven. The nystagmus is periodic, developing in poor light, and being elicited on forced motion of the eyes upward and to one side. There is false motion of objects causing intense vertigo, and accurate fixation is much impeded. According to Arlt, the nystagmus of miners was caused by hemeralopia with retinal torpor, and was to be considered as an automatic attempt to aid vision. Graefe has shown that this is incorrect, as low illumination does not cause retinal torpor; this symptom developing, on the contrary, as a result of overstimulation by bright light. Furthermore, these nystagmic motions are not originally voluntary, and as they cause a false sense of motion in objects, they must interfere with vision instead of aiding it. Hemeralopia is rarely associated with nystagmus, while darkness causes a permanent strain of fixation. The deciding factor is the strain of eccentric fixation, and miners' nystagmus must be considered as an intermittent clonic spasm, a functional neurosis, analogous to writer's cramp with paresis. Nystagmus with head nodding, as seen in infants with good vision, under the guise of spasmus nutans, nodding spasm, or tic de salaam, is a condition very similar to that described above and analogous in etiology. It has been found that these children were generally kept in dark, poorly lighted rooms with a single small window or other light source high up and to one side. The elements of deficient illumination, and of forced eye position sufficiently explain the phenomena, which disappear when the children are put in well lighted rooms. Exclusion of fixation effort by bandaging the eyes immediately stopped the head nodding, which was probably an attempt at compensation.

The significance of nystagmus in labyrinthine and cerebellar

disease is a subject of great practical importance, but one which can only be considered very briefly in this paper. The clinical data are varied, and at times appear to be conflicting. Something may be gained for an easier understanding and a uniform interpretation of the facts if we consider nystagmus, in a broad way, as part of the somatic reaction, the oculomotor part that is, intended to restore supposedly or actually disturbed equilibrium. It has been shown that stimulation of the nerve terminals in the ampulla of a semicircular canal produces a sensation of turning in the plane of that canal, and that the resultant nystagmus corresponds to the change of position of objects which would follow such a rotation of the individual. This reaction may be caused in normal individuals by actual rotation. In labyrinthine disease it is due to irritative lesions of the semicircular canal, and then develops spontaneously, or may be elicited by a number of artificial stimuli, such as mechanical pressure with a probe, syringing with hot or cold water, galvanism, or compression of air in the external auditory meatus. The results are uniform in so far as the sensation of turning is always toward the irritated side, and the rapid motion of the nystagmus, similarly, to this side. Hot water, and the cathode closure act, in this respect, as irritants. The same holds good of otitic cerebellar disease; the nystagmus and sense of rotation vertigo being toward the side of the lesion. In these cases the nystagmus may be spontaneous, while the stimuli applied to the labyrinth, as mentioned above, fail to elicit purely local reactions, showing that the otitic lesion has resulted in a destruction of the sensory terminals in the inner ear, and excluding this region as a source of nystagmic reflex. In both otitic and cerebellar disease there is frequently a turning of the head in association with the eye motion. This head turning is always away from the affected side as would be expected, if we consider this motion as part of the somatic reaction for compensation of disturbed balance, as an automatic reflex adjustment of the body in accordance with a sensation of rotation or of loss of balance. The apparent discrepancy of eye

and head motion disappears if we realize that correction in one instance is normally connected with central fixation of external objects, and in the other with a readjustment of the head to the rest of the body, and of the latter to its own supposed change of position in space.*

Another characteristic and striking feature of fixational nystagmus is the degree to which it is influenced by voluntary positions of the eye. Thus it is always more marked, and frequently can be elicited only, in certain definite extreme positions, and grows less marked or disappears entirely when the eye is placed in the opposite, or in a position of equilibrium. In paresis of an ocular muscle, this position of choice corresponds to the sphere of action of the affected muscle; thus in abducens paresis, nystagmus develops on attempting to look toward the paralyzed muscle. In many other forms of fixational nystagmus a similar condition is observed. Thus, opening both eyes, or the exclusion of one may affect the amount of nystagmus, which may develop spontaneously as a form of associated movement on attempting to close the lids or to look upward. Such reactions are common in hysteria.

---

* Nagel has shown that we can construct a series of dizziness — forms along a line at one end of which we have purely visual, and at the other equilibrational, disturbance. One extreme would be represented by the dizziness in diplopia, due to actual paresis of a muscle or induced by prisms, and the blurred and distorted images produced by cylinders or doubled lines of type. At the other end we find the purely rotational vertigo caused by rapid turning, and in an intermediate position the mixed forms due to irregular changes in the visual field with more or less disturbance of equilibrium, as in ships, swings, and so on, as well as the form caused by swinging mirrors. Similarly we may arrange nystagmus in a line ranging from the purely visual forms to those which are equilibrational. The observations of Nagel, Delage, Cyon and others would seem to disprove Barany's hypothesis that vertigo depends on nystagmus, and that it does not develop if nystagmus is prevented, as by exclusion of visual impressions. We have seen that nystagmus may occur without the slightest vertigo, and experiments with prisms and cylinders show that the converse also holds good.

Peters, Snell and others have recently advanced a theory of the labyrinthine origin of miners' nystagmus. This assumption is not in accordance with all the clinical facts, and is unnecessary if we consider the eye, as we must, as an essential factor in equilibrium, and as intimately related for the purposes of this function with the nerve-terminals in the semicircular canals through their cerebellar end-stations.

In labyrinthine nystagmus indicating irritation, nystagmus is increased on looking toward the affected side, and may disappear entirely on looking in the opposite direction. This has its analogue in physiological fixation of objects in motion, the range of fixation-effort being much greater and the innervation more intense when looking toward the source of motion, as toward the locomotive from a car window, than in the opposite direction, *i. e.,* backward along the track. The mechanical explanation of this difference is that in the one case voluntary deviation effort is added to the reflex twitch, while in the other the two motions are antagonistic and tend to neutralize each other.*

DISCUSSION.

DR. WALTER L. PYLE, Philadelphia. I desire to call attention to the fact that the human eye is always in motion. Modern psychologists and physiologists deny the existence of a distinct "point" of regard. A few sinple subjective experiments conclusively prove that what has been called a "point" is really an easily demonstrable "area" of regard. I believe that often the border-line between the normal oscillations of the eyeball and so-called "nystagmus" is very obscure. Nystagmic movements

* The rôle of fixation effort and eyestrain is strikingly evidenced in cases of acquired nystagmus cured by correction of errors of refraction. According to Barany, only slow movements of the eyes are innervated from the vestibule, rapid oscillations originating in the supra-nuclear centers for fixation. Light narcosis inhibits rapid oscillations together with voluntary movements, while the slow form of nystagmus is not affected. In case of paralysis of the supra-nuclear fixation center, vestibular irritation causes slow movements of the eyes, while nystagmus does not occur. As we have paralyses of associated ocular movements (convergence, binocular fixation, conjugate abduction) due to central lesion, so we may assume developmental anomalies or irritation — states due to lesions of disease, causing spasmodic, uneven, or excessive reaction to normal stimuli. Nystagmus from this point of view could be considered as a fixational intention — tremor or as an ataxia of the gaze.

The anatomical basis for this reaction is the connection of the labyrinth through Deiter's nucleus and the cerebellar cortex with the center for associated motion, conjugate deviation, to the same side. It has been shown that the labyrinth is in connection with the abducens of the same side, and with muscles which turn the head and trunk toward the opposite side, an arrangement which again shows the uniformity of response to reflex irritation resulting in disequilibrium, if considered as a somatic reaction of correction or readjustment.

may be the result of a simple fatigue-neurosis. There may be a lowered vitality of the retina or of the general nervous system.

DR. ALEXANDER DUANE, New York. On the subject of the first variety of nystagmus I had a theory that I propounded once five years ago but never published. It seems to me it might hold good possibly. It is this: In the young child, who has not yet learned to fix, a stimulus coming from the right side falls on the left side of the retina and the impulse is sent to the left side of the brain to the angular gyrus, whence it descends as a motor impulse, crossing over to the right side so as to act on the right externus and left internus and swing both eyes to the right. As soon as the eyes swing past the object the process is reversed; the sensory impulse strikes the other half of the retina, travels up to the right side of the brain and thus swings the eyes back. If that were all, the child's eyes would simply oscillate about the point of fixation. But another mechanism comes into play, i. e., when the eye is opposite the object, so that the image falls on the macula a strong impulse is sent up to both sides of the brain at once so that the eye is impelled to move at the same time to the right and to the left and hence remains steadily in place. It is thus that the normal eye learns to fix. Now in the case of a child with a defective macula in both eyes, or one whose macular image is blurred by corneal or lenticular opacities, the second mechanism doesn't operate because a preponderating impulse is not sent up from the macula, and we have then a condition of oscillation about the point of fixation, i. e., a nystagmus. I believe the same explanation may hold good for miners' nystagmus due to exposure to insufficient illumination and blunted sensibility of the macula with central scotoma.

DR. A. N. ALLING, New Haven. I should like to enquire whether I understood Dr. Fridenberg to state that his second variety of nystagmus movements, that is where there is a quick jump to one side and then a slower movement backward, occurs only in cases with cerebral lesions of some sort. It seems to me that we see this same type also in some cases which are due to imperfect vision and in congenital amblyopia as well as in the so-called false nystagmus in weakness of the eye muscles.

In this connection I should like to speak of a case in which there was an opacity of the cornea in one eye and a cataract in

the other. When I saw him the other day he had developed nystagmus with the quick motion to the right while just before operating I observed that the rapid motion was to the left. In other words there was a change for some unknown reason of this phase to the opposite direction.

DR. F. H. VERHOEFF, Boston. There is one point in connection with nystagmus that I think has been generally overlooked which was first called to my attention by Mrs. C. L. Franklyn, noted for her theory of color perception. She noticed in a certain number of color blind persons a nystagmus which on careful study she found associated with a minute central scotoma. Perhaps if this were searched for it would be oftener found.

DR. FRIDENBERG. As to Dr. Duane's theory it may be accentuated by the observation of children with the other type of nystagmus associated with head nodding, in which it is not oscillatory. This nystagmus is fixational or directional in character and analogous in etiology and clinical course to miners' nystagmus. By removal to a well lighted room the head nodding is stopped. The same thing applies to miners' nystagmus. These patients have vertigo due to false motions.

As to the development in ordinary cases of amblyopia of the rapid or slow type I have no personal experience sufficient to form a definite opinion.

REPORT OF TWO CASES OF SYMPATHETIC OPHTHALMIA.

BY EDGAR S. THOMSON, M.D.,
NEW YORK CITY.

The following cases seem worthy of report on account of their fortunate termination. They are, briefly, as follows:

CASE I. Mr. B., 71 years old, rheumatic but otherwise in good health, called me to see him December 28, 1906, on account of an attack of pseudo-membranous conjunctivitis in the right eye. He was sent to the hospital, where he remained until January 24, 1907. The attack was severe, with scant discharge but intense swelling and some enlargement of the pre-auricular and cervical lymph glands. (I considered the attack a Parinaud's

conjunctivitis.) The temperature at first ran up to a little more than 100°. The cornea became necrotic early, and at the time of his discharge the whole lower half of the cornea was flattened and cicatricial, with iris included in the scar, as the result of a perforating ulceration. The lens escaped during the attack.

February 22d he went South, with the eye entirely quiet and without tenderness on pressure.

April 21st he returned with a low grade of iritis in the left eye, which had appeared three days previously. The pupil was contracted, there were several posterior synechiae, and both eyes had marked ciliary tenderness. He was admitted to the hospital at once and the right eye, which had only light perception, was enucleated. The vision of the left was 20/100. He was put on full doses of bromides, hot water applications every three hours, mercury vasogen one dram twice daily, and the following morning two leeches were applied to the left temple. He was kept in bed with the eye bandaged. Atropine was used very guardedly but in sufficient quantity to keep the pupil partially dilated. It was impossible to rupture the synechiae and the attempts were early abandoned. Until April 25th he had considerable pain and morphine enough to control it was administered.

April 25th he was put upon a dosage of fifteen grains of aspirin every two hours while awake, the mercury being discontinued, and thereafter his treatment consisted of rest and attention to the general health, diet, etc., with from 125 to 150 grains of aspirin in the twenty-four hours. He improved steadily, the irritative attacks became less frequent and less severe, and finally, May 18th, he was discharged from the hospital with a vision of 20/70, the eye quiet, the pupil of normal size, but three or four posterior synechiae. Aspirin was continued in doses of fifteen grains three times a day until May 25th.

He continued gradually to improve until in October the vision was 20/30, in December 20/20—and in January 20/20 with the correcting lens. There were no retinal or nerve changes and but few floating vitreous opacities.

The pupil moves quite freely at present, in spite of the synechiae, and the vision remains the same. The light sense is somewhat reduced, probably on account of a certain amount of organized exudation which remains on the anterior surface of the lens.

Examination of the enucleated eye showed dense cellular infiltration of the iris and ciliary body with inclusion of the iris in the corneal scar tissue.

CASE 2. Charles S., 62 years old, was admitted to the hospital July 27, 1907. He was of good general health but rather lacking in robustness. In a fight one week before, a finger was stuck in his left eye. There was a severe kerato-hypopyon, with the anterior chamber half full of exudate, moderately increased tension with severe pain. A keratome incision was made by Dr. Dean Foster and the hypopyon evacuated. The following day the hypopyon, having reaccumulated, was again evacuated, but the pain and increased tension continuing with steady progress in the corneal ulceration and infiltration, a Saemisch section was done August 10th. His recovery following this was uneventful and he left the hospital August 27th with a large cicatrix in the lower part of the cornea, in which the iris was included. Vision in the eye was light perception only.

September 27th he was readmitted with a low grade of iritis which had been coming on for three days. There were two small posterior synechiae which ruptured after the installation of atropine. Pain and photophobia were severe and there was considerable ciliary tenderness in the left eye, which was at once enucleated. Vision of the right was 4/200.

He was put to bed, the eye bandaged, enough atropine was used to dilate the pupil, hot water applications begun, and a free catharsis instituted. He was given mercurial inunctions for five days and aspirin in fifteen-grain doses was given from September 29th to the time of his discharge from the hospital, increasing rapidly to 130 grains in the twenty-four hours. He improved gradually and was discharged October 19th, with the eye quiet, the pupil well dilated, vision 20/200, and considerable vitreous

haze. His vision gradually improved, under the administration of iodide of potassium, until in the February following the vitreous was entirely clear, vision 20/40, and there remained only some diffuse choroidal atrophy in the macular region.

The examination of the enucleated eye showed an intense plastic uveitis, with inclusion of the iris in the corneal scar, as in the former case. The whole uvea was filled with lymphocytes and epithelioid cells. The choroid was involved throughout.

In considering the treatment of sympathetic inflammation, one cannot but be struck with the fact that it seems, in the light of experience, to assume a certain form. Whatever may be our views as to the pathology of the condition, the treatment is quite analogous to the treatment of septic processes in other parts of the body.

First in importance is rest and freedom from irritation. The circulation should be kept quiet by absolute rest in bed and all tendency to irritation of the eye through light should be avoided by bandaging. The most limited examinations consistent with a proper knowledge of the progress of the case should be made. Every one knows how intensely irritative such cases are, and I am sure that I have seen bad results follow a too prolonged examination. I am in the habit of using a very subdued light, and at first do not use a condensing lens at all. These precautions should be kept up until the ciliary circulation is almost free from hyperaemia.

Atropine should, of course, be used, but rather guardedly. It must be borne in mind that the most severe infiltrates are apt (judging from the examination of the exciting eye) to be found in the ciliary body and anterior part of the choroid — at least in a certain proportion of cases. The iris inflammation is important chiefly through its tendency to lead to the formation of posterior synechiae, being rather dwarfed by the inflammation of the ciliary body and its effects on the nutrition of the eye, and therefore only enough atropine should be used to keep the pupil moderately well

dilated. If this fails to keep the pupil open nothing is gained by forcing the atropine. If this latter be done in a certain number of cases a damming back of the blood into the ciliary body occurs and the ciliary hyperaemia is actually increased. I am accustomed to use atropine with great caution and if synechiae have formed which cannot be ruptured, I use only enough to secure the greatest dilatation allowed by the synechiae. If increased tension supervenes I at once stop the atropine and confine myself to pilocarpine instillations, stopping even these if they are not effective in reducing the tension. Eserine I never use in this connection. If the vascular excitation persists the tension is very difficult to control and it is better to rely on morphine and general measures than local ones, which are but too apt to increase the irritation.

Hot water applications should always be used and may be applied as frequently as every hour. They tend to relax muscular cramp in both the iris and ciliary body, and have an important effect in stimulating the lymph circulation.

It goes without saying that the general health should receive the most careful attention and the nutrition should be kept up by studying the individual case, being careful not to over-stimulate the circulation.

For general administration the drugs which resist plastic formation, the salicylates, mercury, iodide of potassium, and quinine, have been long advocated and continue to be our only hopeful line of treatment. The chief value of mercury is probably in cases with a latent specific tendency, and on account of the difficulty of excluding this, it is almost always wise to begin treatment by a vigorous exhibition of mercury by inunctions. The tonic value of quinine cannot be denied, but personally I have not had much success in its administration in this class of cases. It is difficult to give very large doses, the toxic effects are annoying and I have always been in doubt as to its real value. Iodide of potassium is of value principally in the later stages of the attack.

Salicylate of soda in large doses, as advised by Harold Gifford, has always seemed to exert a favorable influence, but here again we are confronted by the difficulty of administration. It frequently nauseates the patient and the tinnitus is apt to be severe. Aspirin (or acetyl-salicylic acid) was very well borne in the two cases reported. The deafness and tinnitus were not very marked in either case and passed off during the continued administration of full doses. Very little difficulty was experienced in its administration as far as the digestion was concerned. It was given at first in capsules, then in milk, in brandy, and in one case with stewed fruits. There was no nausea nor digestive disturbance to speak of at any time, and the variations in its administration were simply to avoid the unpleasantness of taking so much tasteless powder.

I am strongly of the opinion that the aspirin had a great deal to do with the recovery of the two cases reported. That both cases were due to a form of disease in the exciting eye which makes for one of the less severe types of sympathetic uveitis cannot be denied, but it is also true that any case of sympathetic inflammation is a most serious condition and if not carefully treated is apt to go on from bad to worse, so that all cases of recovery from this disease are worth considering.

DISCUSSION.

Dr. C. J. KIPP, Newark: I have seen four cases of sympathetic ophthalmia in which the patients refused to have the injured eye enucleated and yet complete recovery took place. Enucleation was advised but refused and, contrary to all expectations, good sight was obtained in the end. I have, of course, seen a number of such cases as the writer has reported, but do not know if many have been recorded. I have recently seen a case in which in spite of all treatment, including enucleation of the injured eye, the sympathetic inflammation continued and some two months after the inflammation started a ciliary staphyloma developed. Some weeks later, pus filled the anterior chamber and purulent choroiditis followed, ending in atrophy of the eye. I

suppose that the infection occurred through the staphyloma. I could not explain it in any other way. I have never seen a purulent choroiditis follow a plastic irido choroiditis except in this case.

DIFFUSE INTERSTITIAL KERATITIS IN ACQUIRED SYPHILIS.

DR. JOHN T. CARPENTER,
PHILADELPHIA, PA.

Interstitial keratitis, due to *acquired* syphilis, is probably not sufficiently rare to justify the further reports of mere clinical histories; but, in my opinion, the subject is one worthy of interest and a careful review of the facts should prove timely.

That the cornea may become involved in acquired syphilis can no longer be denied, inasmuch as at least 100 well authenticated cases have been recorded, in which, as a late secondary or tertiary symptom, diffuse interstitial keratitis appeared in patients suffering from syphilitic infection. Indeed, the rarity of its occurrence may be more apparent than real, for, as Valude and Stevenson have remarked, we are apt to overlook the possibility of acquired syphilis in young patients, and thus fail to search for evidence of infection from syphilitic nurses, or from one of the many sources in which the disease may be innocently acquired. Moreover, cases mentioned in discussion have never been formally recorded, and Davis, in a paper read before the Ophthalmic Section of the American Medical Association, June, 1908, called attention to the paucity of reports in American, as contrasted with Continental and English ophthalmic literature.

It is uncertain to whom belongs the credit of first recognizing the relation between acquired syphilis and interstitial keratitis, but Verhaege (Gazette des Hôpitaux, Oct. 15, 1904) states that although Velpeau (Maladies des Yeux, 1840) refers to the action of syphilis in producing keratitis, Follin (Pathologie Externe, 1861, p. 708) was the first writer to point out that the cornea might suffer in *acquired* syphilis. It is certain, however, that in 1873 Jakowlewa (Zürich Thesis) published 51 cases of interstitial

keratitis, of which two were clearly due to acquired syphilis. In the same year, Fournier (Leçons sur la syphilis chez la femme) cited cases having a similar origin.

Some interesting statistics have been collected illustrating the relative frequency of acquired as compared with inherited keratitis. Verhaege thinks that from two per cent. to three per cent. of all cases of interstitial keratitis are due to acquired syphilis. Haltenhoff only finds it 5 times in 72 cases. Stevenson's figures show that 1.9 per cent. to 10 per cent. of all cases of the disease may be credited to acquired syphilis.* Alexander, in 50,000 patients suffering from various eye diseases, found it 13 times. In about 7,000 patients from my private case-records I have met with interstitial keratitis of this variety but twice, while in the Eye Dispensary of the University Hospital, among 12,000 patients, we were able to find one case of interstitial keratitis in acquired syphilis. I am indebted to the courtesy of Dr. George E. de Schweinitz for permission to include the notes of this additional case.*

French, German and English journals contain almost all the records of the cases thus far reported. Trousseau mentions 11 cases; Valude quotes about 40; Wandel reviews 45; and, at various times, in English ophthalmic literature we find reports by

* Name	Reference	No. of cases	Due to acquired lues	Percentage
Jakowlewa	Zürich Thesis, 1873, ...	63	2	3.1
Dier	Zeitschr. f. Augenheilk, May, June, 1889, ...	..	..	1.9
Haltenhoff	Bull. et Mem. de Soc. franc. d'ophtal., 1887, ...	66	5	7.5
Pfister	Klin. Monats. f. Augen, 1890, p. 114, ...	130	..	3.8
Anke	Centralbl. f. prak. Augen, 1885, p. 360, ...	100	10	10.0

Morton, Wordsworth, Lang, Juler, Lawford, Critchett, Stevenson, Treacher Collins, Fisher and others.

With the exception of Wilder's paper (Journal A. M. A., Dec. 21, 1901) and a few instances such as Ellett's, Marlow's and Hildrup's, American literature is almost silent in regard to this complication of acquired syphilis. Davis, in his paper (loc. cit.) containing the histories of two additional patients, states that in the Transactions of the American Ophthalmological Society he has not been able to find the record of a single case, and I venture to express the hope that this communication may stimulate others in this society to record in our Transactions their personal experience in this rare condition, and thus establish the truth as to the frequency of interstitial keratitis in acquired syphilis.

Characteristics of this Form of Diffuse Interstitial Keratitis.

I. *Symptomatology.*

Briefly outlined, this disease presents the following distinctive features. With an onset insidious in character, and without marked ciliary injection, the cornea is found to contain many irregularly outlined, gray, deeply-placed, punctate lesions beginning either in its central portion, or, more rarely, in its periphery. These punctate lesions gradually fuse, and the cornea becomes opaque without decided involvement of its surface, or of Descemet's membrane. Following the infiltration, vessels push from the periphery into the parenchyma of the cornea, but the vascularity is usually less pronounced than in the well known "salmon patch" described by Hutchinson, in consequence of which lachrymation and photophobia are not prominent symptoms. The cornea, after a short time, begins to clear, and usually, without marked signs of involvement of the uveal tract, returns to almost normal transparency, resulting in a more or less complete cure in from five weeks to three months.

Trousseau believes that the more protracted course and more serious nature of the inherited form is due to the lesser resisting power of the tissues in childhood and adolescence. In support

of this he cites the history of a boy aged 8, infected by his nurse, in whom the keratitis assumed the severe character usually seen only in inherited syphilis.

A second form of diffuse interstitial keratitis, seen less frequently than the foregoing, is characterized by a peripheral opacity usually situated on the upper part of the cornea, and more or less triangular in shape, accompanied invariably by a severe plastic iritis. More circumscribed in extent, it has been called "Partial Interstitial Keratitis" by Alexander. The opacity in this variety becomes dense — "ground-glass cornea" — and the "salmon patch" may be pronounced; the iritis which invariably accompanies it being its distinguishing feature. Hoch, Demarbaix and Sturgis have published cases, while Alexander and Nagel ascribe it to a trophic disturbance, produced by degenerative neuritis of the ciliary nerves, caused by inflammation of the iris and ciliary body.

Unilaterality.— Contrary to the rule in the inherited form, the interstitial keratitis of acquired syphilis almost invariably attacks but one eye. According to Verhaege (loc. cit.), in about 70 per cent. of the cases one eye was attacked. It has been suggested that the unilaterality of the affection, as well as its milder character, is due to the prompt curative action of mercury.

Period of Onset.— The length of time between the initial lesion and the appearance of this corneal complication varies within wide limits, from three weeks in Loewensohn's unique case, to 23 years in Ellett's. Verhaege says 36 per cent. occurred in the second year, and according to Stevenson 10.8 years is the average period in the cases collected by him, while but few cases have been reported as occurring under two years — three, only, within one year.

Complications.— Iritis, involvement of the anterior portion of the uveal tract, indicated by vitreous opacities and inflammatory foci well forward in the choroid, often accompany the interstitial keratitis of acquired syphilis; but, if we except the rare form, known as partial interstitial keratitis, in which iritis is the in-

variable rule, these complications are far less frequent than in the inherited type of keratitis.

As an unusual complication may be mentioned corneal ulceration (Treacher Collins), and a few instances of destructive inflammation of the eyeball — panophthalmitis or resulting staphyloma.

Associated Symptoms.— Inasmuch as this corneal complication is usually found in the tertiary stage of syphilis, oro-nasal ulcerations, palmar and plantar psoriasis, gummata of the skin, periosteum and muscles, ozena, facial paralysis, vitreous opacities and choroido-retinitis have been noted as associated lesions.

II. *Pathology.*

Naturally but few eyes affected with true interstitial keratitis have been examined microscopically, and I have found no record of such examination in keratitis of acquired syphilis.

Fuchs' description of the pathologic anatomy of interstitial keratitis is as follows: dense infiltration of the most posterior layers of the cornea, so that they sometimes appear as if transformed into granulation tissue; numerous newly formed blood-vessels in the posterior and middle layers. The infiltration at the margin of the cornea is continued into the ligamentum pectinatum, the iris, and the ciliary body. Nodular aggregations of lymphocytes were also found with accumulations of leucocytes upon Descemet's membrane. That changes occur in the endothelium in interstitial keratitis is rendered probable by E. v. Hippel's fluorescin experiments, since deep staining frequently occurs in these cases. (Parsons Pathology, Vol. I.)

Leber, Nuel, Stevenson and others regard interstitial keratitis as invariably secondary, following uveitis; but J. Herbert Fisher (Trans. Oph. Soc. United Kingdom, Nov., 1907) thinks that this is by no means universally accepted.

In v. Graefe's Archiv fur Ophthalmologie, 1906, Elschnig reviews at length the literature of the Pathology of Parenchymatous Keratitis. His microscopic study of the corneal lesions was made

at the earliest stage yet reported upon. He finds it absolutely sure that the corneal alteration is primary, and that the earliest change is an excessive proliferation of the fixed corneal corpuscles (and also of the wandering cells), which then swell and degenerate. Just in front of Descemet's membrane were masses of proliferated corneal corpuscles, with a few round cells and many giant cells, and structures resembling giant cells, but no epithelioid cells. Stains for bacilli were negative. The widened lymph spaces of the cornea were filled with a granular detritus, and the lamellae between them were in places necrotic and infiltrated with round cells. There was widespread vascularization, and many of the arteries of the uvea showed proliferation of the intima, with obliterations and thickening of the degenerated walls. (Oph. Year Book, 1906.)

III. *Etiology.*

Interstitial keratitis in acquired syphilis is a disease of adult life, occurring usually between twenty and fifty. We must not forget that cases occurring in childhood may be overlooked. Stevenson records the history of an infant aged four months, while Monphous and Trousseau observed it in children of one and eight years respectively.

Parenchymatous keratitis has been experimentally produced in rabbits and monkeys by inoculating the cornea with scrapings from chancres and other lesions in the human being, and the spirochetae pallidae have been found in such lesions. Stevenson and others, Stock, Peters, Römer and Babb, have found spirochetae in congenital syphilis of the eye. According to Stevenson the cause of the keratitis is the deposit and multiplication of the spirochetæ, which come from the uveal tract.

Certain it is that the discovery of the spirochetæ by Schaudinn and Hoffman in May, 1905, and the subsequent confirmation by many observers of the importance of this organism in the production of syphilis, opens up a fruitful field in the etiologic study of syphilitic lesions in ocular tissues. Chancre of the conjunctiva

followed by interstitial keratitis, as in my first case, furnishes a clinical confirmation. The parallel between the experimental production of parenchymatous keratitis by inoculation, and this association of keratitis with chancre in the immediate vicinity is only too obvious. In this connection, Treacher Collins (Royal London Oph. Hos. Reports, Vol. XVI) remarks: "The association of these two rare affections would seem to imply more than a chance coincidence. It would suggest that the proximity of the primary lesion in syphilis to the eye predisposes it to become subsequently the seat of an interstitial keratitis. The fact that, in each case, the keratitis occurred in the eye on the side on which the chancre was situated, and, so far as the history of the cases go, on that side only, is further in keeping with this suggestion."

There seems to be no foundation for the claim, sometimes made, that interstitial keratitis in this class of patients is produced by the general dyscrasia rather than by the toxin of syphilis. Pathologic investigations refute this claim, which is, moreover, not borne out by the clinical records, most patients showing a satisfactory condition of general health.

Next in etiologic importance to syphilis is tuberculosis. The experience of Pflüger of Bern, who reported 30 cases (Heidelberg Cong. 1896) in which influenza caused interstitial keratitis, is unique. Isolated instances of interstitial keratitis have been reported in rheumatism and after the exanthems (mumps) but in these we may suspect inherited syphilis.

IV. *Differential Diagnosis.*

A most useful aid is furnished by Bull's classification (Morrow's System of Genito-Urinary Diseases, Syphilology, and Dermatology, Vol. II, p. 550), which is as follows:

1. Diffuse parenchymatous or interstitial keratitis, which may involve either the center or the periphery of the cornea; or may assume a triangular shape, and this is always accompanied by malignant iritis.

2. The true keratitis punctata of Mauthner, or the keratitis

interstitialis punctiformis specifica of Hoch, in which numerous punctate spots of infiltration appear in the parenchyma of an otherwise transparent cornea, without iritis.

3. Keratitis punctata in which the punctate deposits are accompanied by a generally cloudy cornea and by iritis.

4. Gummatous degeneration of the cornea.

There is usually nothing in the appearance of the interstitial keratitis of acquired syphilis to distinguish it from the inherited form. Only by a thorough investigation of the family and personal history, and by a painstaking search for the distinctive lesions of hereditary syphilis, can we satisfy ourselves as to the true nature of the individual case under consideration. Without a clear history it may be impossible to distinguish tubercular from syphilitic keratitis, as the clinical features may be identical, and microscopic examination fails to differentiate between the two conditions.

V. *Prognosis.*

The prognosis regarding restoration of vision, and duration of the disease, in the acquired form, is almost invariably favorable, although Wordsworth, Alexander, Griffith and Symons have reported cases in which the disease terminated in blindness. As a rule, to which there are few exceptions, one may promise early and complete recovery — a sharp contrast, indeed, to the gloomy prognosis of inherited interstitial keratitis, which drags its weary length over long months of apparently futile treatment, and terminates not only in corneal opacities, but, in many instances, leaves the eye seriously damaged by associated destructive lesions of the deeper portions of the uveal tract.

VI. *Treatment.*

Interstitial keratitis due to acquired syphilis responds with remarkable promptitude to antisyphilitic remedies. Mercury, whether administered by inunction, intra-muscular injection or by the mouth, produces rapid subsidence of the inflammatory

symptoms, apparently controls vascularization, and, finally, produces absorption of the corneal infiltrate in a manner quite analogous to that seen in the melting away of a so-called gumma of the iris. Large doses of potassium iodide do not seem to act as beneficially, and in my first case appeared to aggravate the condition. The local treatment does not differ from that of ordinary interstitial keratitis; atropin, dionin and measures to secure rest of the inflamed organ, should be followed by massage with the ointment of the yellow oxide of mercury. The average duration of the disease — five weeks to three months — illustrates the powerful curative influence that mercury possesses in these cases.

Clinical Notes.

The clinical notes of my patients are as follows:

CASE I. A. P., male, aged 27, suffered from a chancre of left lower lid involving conjunctival surface at inner canthus, first noticed about June 1, 1905. The diagnosis, abscess of the lachrymal sac, made by another physician, was followed by free incisions, and at the time of his first visit, July 19, 1905, there was intense swelling, which closed the lids; but, near the inner canthus, a broad, ulcerated area with sharply outlined edge was discovered just within the lid margin. The surrounding induration, together with glandular involvement of the neighboring lymphatics, led to a careful examination for other evidences of syphilis. Faint copper-colored spots were found on the arms and thorax. (see Fig. 1).

The diagnosis of chancre of the lid was made and vigorous mercurial treatment instituted. Well-marked secondaries followed and in about 4½ to 5 months after the initial lesion, the onset of mild symptoms of ciliary injection, photophobia and lacrymation, led to a careful examination of the cornea. Beginning at the lower corneal periphery, a number of gray, deeply placed areas were seen, which gradually became more numerous, fused, and in a few weeks typical diffuse interstitial keratitis developed. In addition to the general opacity of the deeper layers,

the cornea showed radiating fan-shaped streaks proceeding from the inflammatory focus first discovered near the lower border of the cornea. Steady progress of the opacity slowly obscured the entire cornea, and a well defined "salmon patch" developed—vision being reduced to counting of fingers (see Fig. 2).

Under active mercurial treatment the cornea slowly cleared, the vascularization disappeared and ultimate visual acuity 6/7½ was gained. Although the severity of the keratitis was quite as intense as in an average attack of inherited interstitial keratitis, the cornea cleared completely except for the remnants of new vessels which had pushed in from the periphery of the cornea. The "salmon patch" in this case, while quite typical, remained limited to the lower half of the cornea.

Remarks.

It is interesting to note in connection with chancre of the conjunctiva followed by interstitial keratitis, that this association has been found no less than ten times in literature. The following table shows the name of the reporter, sex of patient, and the time of development of the keratitis after the appearance of the chancre. I have called attention earlier in this communication to the fact that the presence of a chancre in the vicinity of the eye seems to predispose that eye to an attack of interstitial keratitis—a fact commented upon by both Lang and Treacher Collins.

CHANCRE OF THE CONJUNCTIVA OR EYE-LID FOLLOWED BY INTERSTITIAL KERATITIS.

	Reporter.	Sex.	Onset of Keratitis after Chancre.
1.	Lang.	Male.	1 Year.
2.	Lawford.	Male.	5 Months.
3.	Marlow.	Female.	10 Years.
4.	Trousseau.	Not given.	Not Given.
5.	Trousseau.	Not given.	Not Given.
6.	Valude.	Male.	4½ Years.
7.	Collins.	Male.	1 7/12 Years.
8.	Collins.	Female.	3 Years (Chancre of Lip).
9.	Snell.	Female.	21 Years.
10.	Carpenter.	Male.	4½ Months.

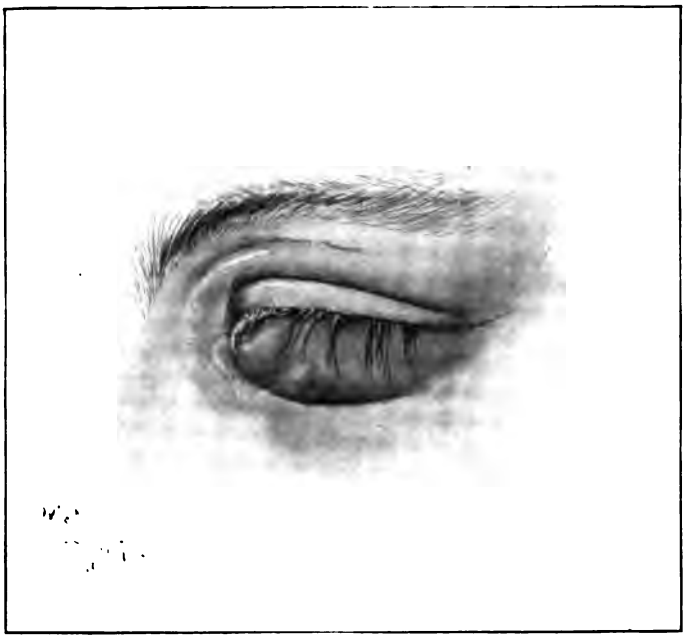

FIG. 1. — June 1, 1905

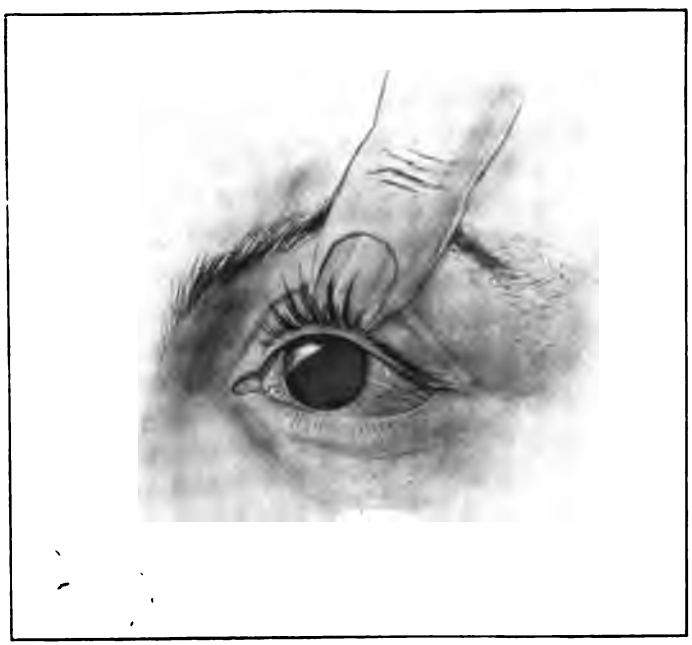

FIG 2. — Jan. 17, 1906.

CASE 2. S. X., male, aged 39; primary lesion February 1, 1892, followed by unusually severe secondaries; gumma of ciliary body which perforated the sclera and necessitated enucleation; destructive uveal inflammation in the remaining eye terminating in secondary cataract, which was successfully removed, giving fairly useful vision; recurring attacks of uveitis over a long period of years, until in 1901, or nine years after the initial lesion, he had a severe parenchymatous keratitis marked by a peripheral ring-shaped area of deep infiltration, showing a tendency to superficial ulceration in different spots. After several recurrences there finally appeared, about eleven years after the chancre, a sharp, well-marked attack of diffuse interstitial keratitis with pronounced vascularization, which yielded to the active administration of mercury and iodides in about two months. Within a few months the patient died of cerebral syphilis.

CASE 3. E. M., male, aged 50, consulted Dr. de Schweinitz at the University Hospital, July, 1904, because of severe interstitial keratitis affecting the central portion of the left cornea. The vascularization was not pronounced, and after failure to secure improvement under the usual routine treatment, carefully carried out, vigorous mercurial treatment was substituted, which resulted in so prompt a subsidence of the keratitis, that the diagnosis of its syphilitic nature seemed to be confirmed. The right eye remained unaffected.

DISCUSSION.

DR. SAMUEL THEOBALD, Baltimore: I think it is a pity that we should use the term "interstitial keratitis" having reference to cases of the character described. We all have a very definite view of what we mean by the interstitial keratitis of Hutchinson. It is not only a characteristic process, but has a definite clinical history, one of the chief points of which is chronicity. I should rather call these cases *parenchymatous* keratitis. Of course, it is simply a question of terms, but I have always preferred to use the term interstitial keratitis with reference only to cases due to inherited syphilis. Parenchymatous keratitis, at times, has a

certain resemblance to the typical Hutchinson form, but clinically it is entirely different, and the cases that have just been described, I think, might be more aptly termed "parenchymatous," to distinguish them from the clinical entity we are all familiar with as the interstitial keratitis of Hutchinson.

DR. PETER A. CALLAN, New York: I had personally felt that it was more or less a waste of time to publish these cases; it was beyond a doubt that they were due to acquired syphilis. I have seen quite a number. Dr. Davis, before reading his paper in Chicago, spoke to me about it. As far as the type is concerned there is very little difference, in my opinion. As a rule I find, as the doctor stated, that only one eye is affected in the acquired form, whereas in the inherited form both eyes are affected.

I have never put on record two cases I had of abscess of the cornea occurring in the inherited form. Books say that it does not occur and I have never seen but these two cases.

I think the only difference is the rapidity with which these cases get well.

DR. C. J. KIPP, Newark: I suppose no one doubts today that we do see a form of keratitis in acquired syphilis. I have seen a number of such cases, but it is often difficult to decide whether the disease is due to acquired or inherited syphilis. I treated a case, a young man of twenty-nine, who went through a regular form of what is known as interstitial keratitis, who I am sure had not acquired syphilis. I have also treated a woman of forty with interstitial keratitis of the same form we see in children, who assured me that she had not acquired syphilis. We cannot fix a limit as to when interstitial keratitis may follow inherited syphilis.

DR. G. E. DE SCHWEINITZ, Philadelphia: In addition to the case which Dr. Carpenter has quoted as occurring in the University Hospital, there was another one of bilateral parenchymatous keratitis unquestionably due to acquired syphilis in a young woman aged 18. In this case, however, there were extensive uveal tract lesions which, perhaps, as well as its bilateral character, remove it from the class to which special reference has been made by the essayist. I tapped the anterior chamber with good therapeutic results and hunted for the spirocheta pallida, but without success. From the therapeutic standpoint I am inter-

ested in the value of the administration of iodide of potassium as compared with the exhibition of mercurials, and I have come to believe, following the advice of Dr. Edward Martin, formerly Professor of Genito-Urinary Surgery in the University of Pennsylvania, that the persistent use of mercury without iodides yields far better results than either the mixture of the two remedies or the iodides alone. One of the difficulties attending the administration of iodide of potassium in large doses is the danger of producing nephritic irritation, and my results with inunctions of mercury preceded by a cabinet sweat bath have far exceeded in value those from iodide of potassium.

MAJOR HENRY SMITH, of H. M. Indian Medical Service: As regards the treatment of these cases, whether syphilitic or non-syphilitic, my experience tends steadily in the direction that mercury given in sufficient quantity, bringing the patient to the verge of salivation, is of infinitely more use than any other drug we possess.

As regards the rapid induction of the effect of the mercury, which is of great importance in the treatment of some of these cases, especially of iritis and irido-cyclitis, hypodermic injections of pilocarpine tend to induce the effect much more rapidly than it can be obtained without its use. I presume the vapor bath referred to would aid in the same manner, but have never employed it. In my experience a few leeches to the temple tend to induce the effect of mercury almost as rapidly as the pilocarpine injections. Leeches to the temple seldom do harm and certainly tend to the induction of rapid mecurialization.

As regards atropine for dilatation of the pupil in cases of iritis or irido-cyclitis a few leeches applied to the temple will also increase the rapidity of its action, if it is going to act at all. I do not know the explanation of this fact, but in my observation it is a fact.

RECURRENT TRAUMATIC EROSION OF THE CORNEA.

REPORT OF A CASE DUE TO LACHRYMAL STRICTURE.

BY R. J. CURDY, M.D.,

KANSAS CITY, MO.

This was a typical case of recurrent erosion following superficial injury, in this case a scratch of the cornea of the left eye by the point of a fern leaf. The patient, a married woman 28 years old, came under my observation in October, 1904, two years after the original injury, and six months after the first sign of recurrence. During these six months there had been marked exacerbations and remissions, and occasionally short intervals of almost entire absence of the symptoms. The case had been under treatment several times, but without benefit, excepting temporary relief of pain. On examination the left eye showed slight conjunctival catarrh, moderate photophobia and lachrymation, and a central vertical faint gray line on the cornea measuring 2 by 3/4 mm.; the pupil was dilated from a solution of atropine which the patient had been using at home. The right eye was normal.

Vision, OD 18/15 Hm O.25:
OS 18/24 Em.

There was constant discomfort, but pain only for about two hours after waking. Treatment now begun was the use of silver nitrate solution 1/480 for the conjunctival catarrh, and yellow oxide of mercury ointment 1/120 at bedtime with massage, and massage on waking and before opening the lids, as recommended by Stood. This treatment was without benefit excepting that the morning pain seemed somewhat less severe. After eighteen days of this treatment, a slight distention of the left lachrymal sac was noticed, and pressure on the sac forced its contents into the

nostril. The patient then gave a history of old lachrymal obstruction beginning long before the corneal injury, and shown by constant slight lachrymation, and occasional visible distention of the lachrymal sac, which would appear at times and disappear. This condition had never been treated. On passing a probe a stricture was found in the upper portion of the duct, which yielded readily to repeated probing. After dilatation of the stricture there was complete disappearance of all symptoms of irritation, and the gray opacity of the cornea gradually faded, leaving no trace; after which, vision of OS was 18/15, Em. There has been no recurrence.

Recurrent traumatic erosion of the cornea has a characteristic subjective symptomatology on which the diagnosis is based; the objective signs are variable and have given rise to different ideas of its pathology and etiology, as is shown by the titles under which it has been described, viz., recurrent or relapsing traumatic erosion, recurrent traumatic vesicular or bullous keratitis, and recurrent traumatic keratalgia. As pointed out by De Schweinitz and by Stood in 1901, the conditions described under these titles are the same, except in the appearance of the corneal lesion. This may be an erosion, a vesicle, or may be not demonstrable. The primary injury is a superficial one caused by semi-blunt force; a scratch by a finger nail, or a corner of stiff paper, or the point of a leaf. There is no apparent injury of Bowman's membrane. After a few days all symptoms of trouble cease, and there is apparently perfect recovery. But after an interval varying between a few weeks and many months there is a return of all the symptoms of the original injury, pain, photophobia, lachrymation and ciliary hyperæmia, and in addition to these the characteristic symptom of this disease occurring on waking from sleep, and described as a feeling of adhesion between lid and globe, and of rupture of the adhesion on opening the lids; this followed by the pain and other symptoms of corneal abrasion, lasting for an hour or two. During the remainder of the day the eye is nearly or quite free of discomfort, but the same trouble

appears next morning, and day after day. It is assumed from this history that there is, in fact, adhesion to the lid of the imperfectly formed new epithelium, and that this epithelium is torn away on opening the lids. An erosion is left which later becomes a vesicle by a new growth of epithelium forming the anterior wall of the vesicle, and still later, there is absorption of the vesicular fluid leaving no trace of erosion or vesicle, until the closing of the lids during sleep furnishes opportunity for a repetition of the process.

The condition is that of imperfect healing of epithelium, without apparent abnormality of Bowman's membrane. This imperfect healing has been attributed by different writers to different causes: it has been thought to be a neurosis like herpes zoster; a neuritis of the nerve terminations with trophic disturbances; a result of mechanical factors, minute foreign bodies interfering with the normal growth of epithelium, or alteration of the surface of Bowman's membrane preventing normal adhesion of the cylindrical epithelial cells to the membrane. Stood adopts this last explanation based on the statements of Rollett, Lott, and Langerhans that normally the deepest layer of epithelium adheres to Bowman's membrane by means of little processes which pass into the clefts and furrows of the membrane. Ewing's observation of fatty degeneration of Bowman's membrane in a case of bullous keratitis in a glaucomatous eye favors the belief that Bowman's membrane has a part in the etiology of both conditions.

Treatment recommended has been excision of the wall of the vesicle, cauterization, curetting, and the use of ointments with or without massage. Quinine has been advised in the cases of supposed neuritis. I have found no reference to lachrymal disease, except Stood's general statement that in case of infection of the floor of the vesicle the lachrymal passages may need attention.

The purpose in reporting this case is to call attention to the possibility which the case suggests, of the imperfect healing being due to the presence of tears in abnormal quantity. It is well

known that tears have such influence on operation wounds of the lower lid, and especially where there is ectropion and imperfect lachrymal drainage; so that it is very difficult to get perfect healing in such cases. It also suggests the thought that the infection of cataract extraction wounds attributable to lachrymal disease, may be due as much to the imperfect healing and diminished resistance caused by the abnormal quantity of tears, as to the presence of an unusual number of bacteria.

THYROID EXTRACT IN KERATITIS

McCLUNEY RADCLIFFE, A.M., M.D.,

PHILADELPHIA, PA.

My purpose in presenting this paper is to offer an additional method of therapy, which, although not new in general medicine, is the first that I have been able to find applied to the eye.

The following condensed histories are those of the first cases in which I used this method of treatment.

In November, 1905, a case of corneal inflammation, which was both deep and superficial, reported to my clinic at the Wills Eye Hospital. The patient, a young man of twenty-three years of age, was admitted to the house for treatment, and a most careful general study as to the questions of auto-intoxication, syphilis, tuberculosis and malaria, was made with absolutely negative results.

The usual treatment of atropine, hot stupes, dionine, cleansing washes, quinine, and alteratives was instituted. This treatment was continued until January 15, 1906, at which time I found the patient decidedly worse, particularly the left eye, which was the one that was the later, and the worse affected. The superficial layers of the cornea had become densely infiltrated, the deeper lymph channels filled with red blood, and the overlying epithelium thickened and vascularized; the infiltrate being so dense that the pupillary outlines could not be distinguished.

At this time I had my colleague, Dr. Charles A. Oliver, see the case in consultation, and we decided to try thyroid extract, internally and externally, taking care to watch both the local and general effects of the drug.

Accordingly, all previous internal treatment was stopped, and thyroid extract in five-grain tablets, three times daily, was substituted, five drops of a fifteen-grain-strength solution being instilled into each conjunctival cul-de-sac at the same time. The primary effect of this treatment was a marked clearing of the cornea within the first four days.

This improvement steadily continued, until at the end of three months' time, the patient, who had been only able to count fingers, possessed a vision of two-thirds with the right eye, and two-fifths with the left. There remained but one small spot of infiltrate situated at the lower pupillary margin of the right cornea; with slight general haze in the left. The patient was then transferred from the hospital to the dispensary department. I continued the thyroid extract for several months' time, when the corneæ became entirely clear; the ultimate vision having arisen to full acuity with the right eye, and to two-thirds with the left.

Coincident with this case, January, 1906, a boy of eleven years of age, with a typical interstitial keratitis of both eyes, was admitted to my dispensary clinic at the Wills Eye Hospital. He was put on specific treatment, and kept under close observation for about two months, during which period no marked improvement could be observed. On March 12, 1906, I admitted him to the hospital, substituting thyroid extract for the former general treatment, and continuing the local. With this change the corneæ cleared rapidly, the patient being discharged on May 25, 1906, with but a slight temporary corneal haze, which eventually cleared, under the continued use of the extract, the final vision being two-thirds with each eye.

Subsequent to the treatment of these cases I have continued the employment of the thyroid extract in varying dosages, being

guided by the degree and character of the general and local reactions, with the result that I have seen similar cases, both in my own and other clinics, cured in less time, with less disturbance, and with infinitely better results, than I had previously obtained from any other combination of methods.

In all of my cases, it must be remembered, that each selected one was carefully chosen, properly studied and judiciously treated, just as I had formerly done with similar ones.

REMARKS.

Whether the rapid betterment of these cases by the use of this method of treatment was a mere coincidence or not, it is impossible to state definitely at the present time, but I am strongly of the opinion that it was not; but that it was due to some specific action of the thyroid extract. Should we accept Sajous' theory of "Internal Secretions," as I feel we must, then the explanation of the rapid improvement becomes easy of solution in the correction of faulty metabolism in structures which need better lymph supply and a more rapid interchange of the contained nutrient and cleansing fluids.

From my experience, I would advocate a smaller dosage than I at first used, having found that from one to two grains, given twice or three times daily, will give equally good, if not better results, than larger doses.

I would urge the *early* administration of the extract, but in small doses, even where other drugs are properly indicated, as giving the most beneficial results.

I have simply given my clinical experience with thyroid extract in order to bring it to the notice of the ophthalmologist, not only for discussion, but that the exposition of the plan may be an inducement for proper laboratory research in this interesting field of ocular therapy.

DISCUSSION.

DR. WALTER L. PYLE, Philadelphia: I think no one now questions the growing belief in the great value of thyroid extract in all conditions of malnutrition, particularly when there is glandular involvement. Dr. Risley had recently called attention to its value in ophthalmic practice at a meeting of the College of Physicians of Philadelphia. Dr. Sajous believes that thyroid treatment will eventually become an invaluable and almost indispensable adjunct in the treatment of constitutional syphilis.

Referring to Dr. Carpenter's paper Dr. Pyle did not think the scant reports of the condition in American literature were a reliable index of its rarity. He had found in personal conversations with many American ophthalmologists that they had almost all seen cases similar to those of Dr. Carpenter.

G. E. DE SCHWEINITZ, Philadelphia: I desire to say a few words in regard to the use of thyroid extract in the treatment of keratitis. My first experience with this drug was about ten years ago, when my then Chief of Clinic, Dr. C. A. Veasey, asked me to see in consultation with him a case of relapsing keratitis which followed removal of the lachrymal gland, and the history of which he has reported in detail in the American Journal of the Medical Sciences. All manner of remedies had been tried without success, and therefore I suggested to him the trial of thyroid extract, which was given with markedly good results. Whether these results depended upon the physiological action of the thyroid extract or not I cannot say. My interest at that time was stimulated sufficiently to make other experiments with the drug, and I obtained through the kindness of Dr. Hobart Amory Hare a very pure article of it. It was not again used in keratitis, but in degenerative processes of other types, particularly in incipient cataract, without, however, being followed by the slightest beneficial result. This does not mean that I would not commend its use in the manner already reported by Dr. Radcliffe, but only means that in so far as any relief from the processes which I have described are concerned, its effects were negative.

DR. F. H. VERHOEFF, Boston: I should like to say a word in connection with Dr. Curdy's paper. It seems to me difficult to understand how there could be any connection between the

lachrymal stricture and the keratitis. If such a connection were possible, considering the great number of such strictures and the relative frequency of this form of keratitis we should see the two conditions associated more often.

In regard to the cause of this relapsing keratitis, the neuropathic theory appeals to me most strongly because the corneal condition is exactly the same as we have in any neuropathic case, such as herpes zoster or lesion of the fifth nerve due to syphilis or to pressure of a tumor.

In regard to treatment, Dr. Curdy failed to mention, it seems to me, the most essential measure, the use of the bandage.

Dr. S. C. Maxon, Utica: I would like to inquire in regard to this treatment of subsequent opacities what has been the experience of the members with the use of dionine. I am coming to think very much of it as a remedy in these conditions of opacity.

S. D. Risley, Philadelphia: My colleague at the Wills Eye Hospital, Dr. Radcliffe, very kindly gave me the opportunity to study the cases he has reported today. There was no doubt in his mind or mine as to the benefit following the administration of the thyroid extract. The observation is of signal importance, not only as to the value of thyroid medication in some cases of interstitial keratitis, but because the fact that it proves useful suggests the important relation which may exist between impaired function of the thyroid or other ductless glands and diseases of the avascular tissues, of which the cornea is a striking example.

Dr. Samuel Theobald, Baltimore: It might be interesting in this connection to mention a case that has been under my observation for some time, in which an operation was done on the Gasserian ganglion for the relief of neuralgia, and in which there has been recurrent clouding of the cornea up to the present time, 18 months after the operation. I have not seen any of the recent attacks, but was told by the patient only a few days ago that the cornea still clouds up from time to time. The case was operated on by one of the most skillful surgeons of the Johns Hopkins Hospital. His practice is to use the Buller shield for some time after the operation. There is complete anæsthesia of

the cornea, and with exposure to cold or wind the cornea would cloud up so markedly as to reduce vision greatly. The condition of the cornea looked threatening, but the Buller's shield would be put on, and the cornea would clear up promptly. Such an experience after excission of the Gasserian ganglion is, I believe, rare.

DR. J. T. CARPENTER, Philadelphia: My motive in presenting these cases of interstitial keratitis in acquired syphilis was not to show a rare clinical picture, because I do not believe the condition is rare, and yet if we search the literature and text books, and take the records of 12,000 cases in the eye dispensary representing the general run of cases, it would appear to be a rare affection.

I do not think it is sufficient to say we have seen a number of cases, but we should put on record cases we know to be due to acquired syphilis, in order that it may be put down as a condition not uncommon. A practical reason is that its curability is so much greater than the other form, and it is well for us to bear in mind that acquired syphilis may produce interstitial keratitis and that mercury will in an incredibly short time cure it.

DR. R. J. CURDY: In reply to Dr. Verhoeff the bandage is used in the treatment of the original lesion.

The point I wished to bring out was the possible influence of the tears in damaging the epithelium and Bowman's membrane.

DR. MCCLUNEY RADCLIFFE, Philadelphia: I have used thyroid in other conditions than keratitis, and am now using it in a case of subretinal hemorrhage, having treated the case for some time previously in other ways with no improvement. I have now used the thyroid for two weeks with a decided improvement, not only an improvement that I can notice in the clearing of the fundus, but an improvement noticeable to the patient. My colleague, Dr. S. Lewis Ziegler, told me that he has been using it for some time in similar cases with great success.

As Dr. Risley has stated, its use was at first empirical as the physiological action of thyroid is not fully understood. I believe it has a dual action; that its first action is on the lymphatic system, and secondly on metabolism and nutrition. It does not seem to me possible that the nutrition could be affected within

the first three or four days, for I have seen a decided improvement in several of my cases in four days. I believe, however, that it has a decided effect on metabolism and nutrition. I have observed that the nutrition improves in two to three weeks.

I now have a case of interstitial keratitis, in which I have used thyroid for four weeks. Having previously had him on other treatment with no improvement, after substituting thyroid the cornea cleared rapidly. In the last ten days I could notice a decided improvement every time I saw him, which was every other day.

THE TREATMENT OF IMMATURE CATARACT.

BY MAJOR HENRY SMITH,

Indian Medical Service Civil Surgeon,
of JALANDHAR, PANJAB, INDIA.

Immature cataract is generally recognized as unsuitable for the capsulotomy operation while in the immature condition, and I think justly so. By that operation, it is impossible to get all the lens matter detached from the capsule, the result of which is that, if operated on by that method, a considerable amount of lens matter is left behind. This swells up and becomes opaque, and is exceedingly likely to give rise to a severe form of iritis which will probably bind down the iris to the capsule and which with the capsule and its cell proliferation will form a very dense after-cataract.

For the treatment of such an after-cataract, a mere needling operation is not sufficient. To efficiently treat such an after-cataract, it is necessary to extract it. If the iris is extensively bound down to such an after-cataract, it is necessary at the time of its extraction to mechanically detach it from the after-cataract with an instrument and then to proceed with the extraction of it.

Such an after-cataract could be couched if not adherent to the iris, but couching would in my opinion be certain to be followed by the degenerative condition of the retina which invariably follows couching of the cataractous lens — retinitis pigmentosa sine pigmento — though not with so much rapidity of

progress. I have seen the results of the work done by the immemorial lens coucher in the Panjab, and have examined the cases carefully. This form of degeneration is invariable in their most favorable results. The larger the nucleus of the lens couched, the more rapid its progress as the nucleus and capsule are apparently never absorbed whereas the soft matter within the couched capsule is absorbed.

It will thus be seen why few are willing to undertake the treatment of the after-cataract which follows the extraction of the immature lens by the capsulotomy method with a light heart. The following case in my observation is a typical example of the complication which practically always follows the extraction of the immature lens by the capsulotomy method. A. B.— immature cataract in both eyes — was the principal of an extensive business firm. His visual incapacity involved large monetary issues to himself and others, so he was willing to accept any risk. In the autumn of 1906, an iridectomy was performed with the object of maturing the cataract by one of the most experienced operators by the capsulotomy method in the world. The result was *nil*. There was no more progress in the maturing of the cataract in that eye than in the other eye which was equally advanced. A few months after the iridectomy he had the immature cataract extracted by the capsulotomy method by the same operator.

Five months after the extraction I saw him for the first time. The condition then was as follows: — His eye was, and had been bandaged ever since the operation and he was suffering considerable pain. He was using atropine drops. On examination there was marked evidence of an active irido-cyclitis; the perception of light was very good; the after-cataract was very dense; the margin of the iris was bound to it all round. The operator and another consultant of the same school informed him that they regarded the operation as a failure, and that nothing further could be done.

The pressing claims of patients, with cataracts slowly maturing by nature's process, often keeping the patient almost blind

for years before, the case would be suitable for operation by the capsulotomy method, rendered it imperative that some means should be tried for their relief; hence the various procedures adopted for the maturing of immature cataract. The procedures adopted for this purpose are:

1. Puncturing the lens capsule with a needle.
2. Iridectomy (simple).
3. Iridectomy with massage through the cornea.
4. Iridectomy with direct massage with some form of instrument.

Puncturing the lens capsule is liable to be a complete failure or to establish a traumatic cataract. A traumatic cataract thus established may constitute a serious ophthalmic emergency. The formation of the traumatic cataract may be so rapid and the lens may swell up to such a degree as to cause acute glaucoma and the lens matter may escape into the aqueous chamber and cause acute iritis or irido cyclitis.

The extraction of such a traumatic cataract admits of no delay. The conditions under which it has to be extracted are highly unfavorable and difficult and the results are far from being as satisfactory as in the extraction of a cataract matured by nature's process. It will thus be seen that when this procedure is efficient in maturing a cataractous lens, that is, when it causes a traumatic cataract, it is fraught with serious trouble and serious danger, and is now, I think, relegated to the operations of the past.

2. Iridectomy in my opinion has no influence whatever on the maturing process.

3. Iridectomy with massage through the cornea I have done extensively. In my observation it has no influence on the maturing of immature cataract, if the massage be done with a justifiable degree of pressure, — that is pressure which will not dislocate the lens, — it is only an experienced operator who knows the amount of pressure justifiable. If any excess of pressure be

used, the operator is very liable to dislocate the immature lens in an eye from which the aqueous humour has been released by an iridectomy. Under these circumstances, the immature lens is often very easily dislocated, so that in my opinion, if this procedure be adopted within safe limits, both the surgeon and the patient are almost certain to be disappointed.

4. Iridectomy with direct massage of the lens with an instrument. This procedure was adopted on account of the failure of simple iridectomy and of iridectomy with massage through the cornea, — the simpler methods. This is a daring and a most unsafe procedure. Only those familiar with the extraction of the immature lens in the capsule can fully realize how delicate the capsule in these cases is, and how easily it can be lacerated by the application of the bluntest and smoothest of instruments, in the hands of men most highly trained in ophthalmic manipulation and also how easily the lens can be dislocated in these cases by such direct manipulation. If neither of these undesirable accidents occurs, I cannot see how direct massage can be more effective than massage through the cornea. If either of these accidents does occur, the operator is in the awkward position of being obliged to extract the immature lens without delay, the best way he can. It will thus be seen that ripening procedures are either dangerous or disappointing, and that the surgeon would be better advised to either wait on nature's ripening process, or to extract Immature Cataract in the capsule.

While I condemn these ripening procedures, I fully appreciate the demand which has caused their initiation, — the demand for some procedure by which men of active mental and bodily habits could be relieved of their condition without remaining practically blind for the years through which nature's process would run, before they could be operated on by the capsulotomy method. The demand is pressing; delay may mean want to the family whose breadwinner is the subject; it may mean, when the subject has waited for his cataract to mature by nature's process, that his business has passed into other hands, and that at his time

of life, he is badly fitted to begin a career *de novo*. It may mean that the community has lost a number of years of the services of one of its most important members. In any case the delay occasioned by waiting for the completion of nature's ripening process, involves mental depression, the degree of which can be best appreciated by those of extensive experience in the treatment of cataract, but hardly less so by the general practitioner whose patient the subject is; mental depression allied to that incident to the prospects of confinement in a dark cell without labor, — a form of judicial punishment admissible in no civilized country. We come across patients who insist on a definite opinion, be it good or bad, and who will not be shelved. I have known such men, when told that they had immature cataract and that they would have to wait for a year or two before it could be operated on, suffer from mental depression consequent thereon, which was little short of what would follow a death sentence. The surgeon who intends to wait on nature's process of maturing, should be very careful to avoid informing patients that they have immature cataract until he cannot help it, and then he should not lead them to believe that they have long to wait for it to mature. This may seem to be humbugging the patient: it is not, it is saving him as much as possible of the mental strain to which he would otherwise be subject. The surgeon can save his own reputation by informing some member of the family of the real state of affairs.

It will thus be seen that:

1. Extraction of Immature Cataract by the capsulotomy method is hardly justifiable.

2. Ripening procedures are either unsatisfactory or dangerous.

3. To wait for nature's maturing process is highly unsatisfactory and detrimental to the patient.

The treatment of immature cataract, which I practise extensively, of which I am an ardent advocate, which I regard as the procedure of the future, which will leave mature senile cataract a much rarer condition than it is at present, is extraction of the

lens in its capsule, — a procedure to which immature cataract is admirably suited. In fact even the normal lens can be extracted in the capsule as easily as the ripe one by those skilled in the art.

I have extracted the normal lens in its capsule in a number of cases like the following. A patient has mature senile cataract in one eye — I extract it. He has a large leucoma in the other eye to which the margin of the iris is adherent all round. It is thus impossible to see his lens. His perception of light is good, and the eye is otherwise normal — I assume, and generally correctly, that the lens of this second eye is also cataractous. I make the incision for extraction of the cataract, perform a large iridectomy, and extract the lens in its capsule. On several occasions I have been mistaken in supposing it to be cataractous, and have found that it proved to be absolutely normal when extracted. Such cases are very common in India, the result of trachoma, and such patients see remarkably well through a small portion of clear cornea.

The stage of immaturity at which I advocate the extraction of immature cataract in the capsule is the stage at which it unfits its possessor for the performance of his ordinary duties. I hold that if for no other reason than for the treatment of immature cataract, every ophthalmic surgeon should be familiar with the art of extracting the cataractous lens in its capsule.

The time allotted does not admit of my going over this operation in full detail. I have a monograph in the press on the treatment of cataract, in which I go into full detail on everything concerning extraction in the capsule among other things; but here I wish to state concisely a few of the leading points in this operation.

The patient and his eye are prepared as for the ordinary operation, atropine is not necessary on account of the exceeding infrequency of iritis following this operation. The operator sits on a stool at the patient's head, the assistant stands beside the operator. The assistant is thus not in the way of the operator.

The sclero-corneal incision is made with the speculum in and

includes a little less than half the circumference of the sclero cornea. I personally prefer the incision finished in the cornea without a conjunctival flap, as the flap is more or less in the way. An iridectomy may or may not be done according to the operator's fancy. The speculum is now removed, the assistant draws down the lower eyelid with the face of his thumb, placed on the skin below it; with his other hand he lifts the upper eyelid forward with a large sized strabismus hook, in his first three fingers, as if he were lifting the contents of the orbit out of the socket, and not lifting it towards the brow, using the ring and little finger of the same hand to draw back the brow and orbicularis muscle. This does not imply any violence on the part of the assistant.

The operator now places the end of a large sized ophthalmic spatula on the left side of the cornea over the junction of the middle and lower third of the lens. He places the end of a large sized blunt pointed strabismus hook over the corresponding position to the right of the spatula. He makes steady pressure backwards towards the optic nerve with this spatula and he makes similar pressure with the strabismus hook except that in making pressure with his strabismus hook he draws it backward and forward across the cornea. The edge of the lens at the wound will be seen to tilt forwards and the clear vitreous will be seen between it and the scleral margin of the wound. As soon as this occurs, the pressure with the spatula should practically cease and the same stroking movement of the strabismus hook should be continued, its position not being altered on the cornea at first but the direction of the pressure exerted through it should be altered gradually more and more in the direction of the wound until it finally folds the cornea beneath the lens; at this stage the lens is delivered. The iris should be replaced if prolapsed. The assistant should then let go the eyelid, and the patient's eye should be dressed up.

I may here state that my experience now extends to about 20,000 cataract extractions, about 17,000 of which have been in the capsule, and amongst the latter have been many immature cataracts, especially in recent years.

DISCUSSION.

DR. KIPP and DR. PYLE asked the essayist to demonstrate his use of the strabismus hook in the operation, which he did.

DR. W. E. LAMBERT asked the essayist to tell something about his experience with the operation in high myopia.

DR. EMIL GRUENING, New York, asked what the percentage of loss of vitreous was and if he had been able to follow these cases in which there was loss of vitreous and what became of those eyes? In how many in which iridectomy was not performed was there incarceration of the iris? And, if this occurs what does the operator do, not having in a speculum and not having the eyeball fixed?

Dr. Gruening said we have to consider that all this has been done before. It is only a new cycle. Fifty years ago this was tried by some men and abandoned, but of course it has never been done on so large a scale.

DR. T. R. POOLEY, New York: I wish we had an opportunity of going over the whole subject of immature cataract. After a critical review of all the methods of extraction I came to the conclusion that it was far better to take the risk of operating on immature cataracts than to perform any ripening operation. Whether this new phase of the question is going to alter my opinion as to the manner of treating these cases or not must take some time to decide.

To begin with it would seem to require a great deal of skill. Yet we find when not attempting it that the lens is very readily delivered in capsule. That happened to me some time ago. I intended to do an extraction with iridectomy, but the lens presented in its capsule and was delivered with ease and without loss of vitreous. Whether or not in immature cataracts it is as easy as that is difficult to say. The whole thing for me depends upon a statement from Major Smith in answer to the questions that have been propounded by Dr. Gruening as to what is the ultimate result and how we may deal with prolapse if it occurs during the operation.

DR. C. S. BULL, New York: I feel obliged to Major Smith for the pronounced way in which he has spoken against the so-

called operations for maturation of immature cataracts. A number of years ago when Förster first published his paper on maturation of cataracts I had a case which I thought needed interference, and following out strictly his directions, I operated on this patient. It turned out for the patient most fortunately, but was disappointing for the surgeon, for the entire lens opacity cleared up. That has occurred four times in my experience.

I agree fully with Major Smith that the operations for maturation of cataracts consisting of manipulations of the cornea, with or without iridectomy, are disappointing to the surgeon and in many cases dangerous.

Dr. Walter L. Pyle, Philadelphia: For a number of years I have expressed myself editorially against operations for maturing cataracts, and I am pleased to hear so many expressions of condemnation regarding the so-called "ripening methods." In reference to the greatly feared loss of vitreous in Major Smith's operation I would like to cite an experience I had in the Wills Eye Hospital in operating on a very vigorous Irishman. Just as I seized the iris with the forceps he squeezed his lids violently and popped his lens out over the nurse's head. The eyeball almost collapsed. I filled the globe with saline solution while reprimanding the patient and telling him that he had probably lost the eye. But despite the enormous loss of vitreous and collapse of the bulb, recovery was prompt, and subsequently satisfactory vision was obtained with correcting lenses. This was extraction in the capsule with a vengeance.

Dr. Herbert Harlan, Baltimore: I was struck with one particular phase of the question. A good many years ago I thought it improper to operate on an immature cataract and tried all the various methods of maturation with the usual lack of success. I think for at least ten years past I have not made any attempt to ripen a cataract, but have told my patients that we do not wait so long before operating as we formerly did.

There is a little more reaction after the extraction of immature cataracts and probably a few more capsulotomies required, but I do not believe most of us now wait a long time before operating.

Dr. W. B. Johnson, Patterson: I should like to ask in what percentage of cases there is necessity for spooning the lens and

what is the result in such cases and what amount of vitreous escape accompanies the procedure.

DR. SAMUEL THEOBALD, Baltimore: One point not mentioned is the age of the patients. We all recognize, when we operate on patients of advanced age, that it is not a matter of so much moment that the cataract should be fully mature, for as there is very little cortical substance, it is not apt to cause trouble, even if it has not undergone degeneration. Therefore we can operate upon the cases with comparative safety by the usual method of opening the capsule. In more decidedly immature cataracts my practice has been to perform a preliminary iridectomy and do "trituration" by Förster's method, although I have often found, as Dr. Bull has said, that no result follows, for I feel that the preliminary iridectomy lessens the risk of the subsequent extraction, though it may have had no effect upon the maturity of the cataract. This method I have followed for some years. Having a patient, 60 years of age or older, with poor vision in both eyes, neither cataract ripe, I perform a preliminary iridectomy, triturate the lens, and, after five or six weeks without reference to the effect of the trituration, go ahead and extract in the usual way. These cases almost invariably do well.

DR. BYERS, Montreal: I was surprised that Major Smith did not mention the sub-capsular injections of saline solutions that have been advocated in Belfast. I have had a little experience with this method and have been impressed with its value. I saw the late Dr. Buller remove a cataract in this way with 6/6 vision. I would like to ask if the Major has had any experience with this method and what objections there are to its employment?

DR. C. J. KIPP, Newark: I have used Förster's method and have had several cases with diabetes where this operation was followed by ulceration of the cornea.

DR. J. A. LIPPINCOTT, Pittsburgh: In my early experience I removed the lens in its capsule by means of the wire loop in 14 or 15 cases. I abandoned this method from a consideration of the theoretical danger of changes in the vitreous which might follow later. Such changes, however, so far as I could learn did not occur and the results were brilliant.

As to the advantage of Major Smith's method in immature cataract on account of the difficulty of removing the cortical matter in such cases, it may be remarked that the difficulty is pretty well overcome by irrigation of the anterior chamber — using if necessary the tip of the syringe nozzle to dislodge the adherent masses.

We must all feel under obligations to Major Smith for the trouble he has taken to demonstrate his method.

DR. EMIL GRUENING, New York: What we understand usually by capsulotomy is not really a capsulotomy, but a capsulectomy. Here and in Europe immature cataracts are operated on by capsulectomy, the larger part of the anterior capsule being removed by forceps and then the lens substance is easily washed out if we wish to wash it out. I have operated on a number of immature cataracts in this way and the results are certainly very good.

DR. LUCIEN HOWE, Buffalo: I would like Major Smith, in replying, to take up these points; whether preliminary operation is desirable, and, the comparative advantage between the operation removing the lens in capsule and one of the others leaving the capsule.

DR. E. S. THOMSON: I would like to ask if Major Smith has had any trouble with vitreous membranes following the operation? I recall two cases in which notwithstanding a small amount of secondary iritis there was decided vitreous membrane formed.

DR. T. Y. SUTPHEN, Newark: Does the Major find a certain number of cases in which the vitreous seems inclined to come instead of the lens and where the more pressure he makes the more vitreous escapes, and what does he do in such cases?

DR. DAVID WEBSTER, New York: I would like to ask what he does with cases that we meet with from time to time that roll the eyes up and we can not get them to look down, as he does not use fixation forceps?

DR. S. D. RISLEY, Philadelphia: I would like Major Smith to tell us how frequently he has observed post-operative glaucoma,

or increase of tension; and the average period of convalescence after extraction within the capsule.

It should be remembered that any one who had the opportunity to operate on so large a number of cases as 20,000 would ultimately come to do the operation very well by almost any method. I am sure if either of us had done 1,000 or 5,000 immature cataracts by any one of the various methods suggested in the discussion by several of the members of the society we would be able to do it with better results than at first, because of increased dexterity and improved technique.

MAJOR HENRY SMITH: As to the question regarding high myopia, I have really never done one. High myopia is a very rare thing in advanced life in India. It is becoming more common and will be less rare in the next generation because of the rapid advancement being made in education. I have a couple to do when I reach Bombay in September and intend to do them in this way.

As to the percentage of loss of vitreous; with me at the present time it amounts to a small fraction over 5% of the cases — that is taking cases of every kind, without selection, except children and juveniles. It is practically impossible to extract the lens in capsule in children.

As to the age; the age I refer to is that of ordinary senile cataract. They occur in India from the age of thirty-five upward. Of course the escape of vitreous may be anything according to the operator. With first class experience it should not be I should say much; with beginners not over 10%.

As to the following up of these cases of escape of vitreous. A friend of mine Captain Lister, in the service, searched the records of the hospital for something like eight years back and got out a list of cases in which escape of vitreous had occurred and sent out cards to something like 500 of these people. About 100 of them came. He examined these cases from seven years down to one year's standing and there was no detachment in a single case. They were all apparently as when discharged from the hospital. Average vision was something like 6/6. The amount of escape of vitreous was marked on the tickets, from a bead to 1/3 of the vitreous. None seemed to have suffered from the escape of vitreous. There were such cases as this; patient has both eyes operated on at same sitting, with escape in one and not in the other; he comes in in a few years on this invitation and

is found to be blind in one eye; had splendid vision for a couple of years, has an attack of fever and at end of attack is blind in that eye, but not both eyes and not in the one in which there was escape of vitreous. There is another class in which I do extraction whenever they come. The lens has been couched by a coucher and leaves a little hinge in the ligament and the lens floats up again; he comes to me to have the lens taken out. At the time he is really suffering from retinitis pigmentosa, sine pigmento. We take out his cataract and give him a chance. Captain Lister went over these records as an outsider lest some might think I had a personal bias in the matter. His opinion was that there was nothing deleterious following the escape of vitreous except in one case, a case of one of these couched lenses. His paper will appear in the Archives giving full details of the cases.

As to Dr. Pyle's case, where there was such escape of vitreous it would be interesting to have recorded his vision three or four years afterwards. My impression is that an escape not exceeding a third of the vitreous, the lens in its capsule being out, is not to be looked upon as such a terrible thing. Of course we prefer not to have it. As regards the escape of vitreous following the ordinary operation, which I understand occurs more frequently when the douche is used, it would be interesting to have records of them as to whether degeneration of the retina follows. Where it occurs in the ordinary operation there is more liability for irido-cyclitis to follow.

As to returning the iris, when the assistant holds the lid forward you see that the iris drops back except that perhaps just the base gets in the angle of the wound — then you just drop the point of the blunt hook on the base at each angle. The border of the iris is of no importance in my observation, it is the base that needs to be replaced — the border will take care of itself. As to the amount of prolapse that follows, with people over whom we have no control, it is difficult to tell.

Hypermature cataract and immature cataract are treated in this procedure exactly the same. Hypermature cataract is in my experience the most difficult of the senile cataracts to dislocate because the capsule has become thickened. If there is actual prolapse of the vitreous I always snip it off. I have seen a few cases in which it had to be removed from the wound two or three days afterwards.

If vitreous shows when the edge of the lens is dislocated, you

drop the spatula into the vitreous just behind the lens, and stroke it up from the outside. If you use it to lift out the lens you are liable to burst the capsule.

As to the percentage in which the spoon may have to be used, I should say about 5%. If when the edge is seen to be dislocated the operator helps further dislocation and at the same time keeps it up against the central edge of the wound, he will not have to introduce the spoon.

As to the sub-capsular saline injections, I have never tried them for immature cataract. Personally I think I would prefer the more straightforward operation.

As to post-operative glaucoma. There is a particular class of patients I see in India — wealthy native merchants as a rule — men in advanced life, very fat, diabetic, gouty, or both, in whom I am very anxious as to what is going to happen up to three weeks after operation. I have no statistics on this subject, but I probably see three or four in a year. You extract the lens in capsule in these patients, do an iridectomy at the time, no escape of vitreous, and you cease seeing him at the end of the tenth day. About the fourteenth day he sends for you and says he has pain and you find post-operative glaucoma. It begins as soon as the wound becomes firm. As long as there is a little leakage everything goes on all right as in the healthy eye. I have rarely seen it except in this particular class of cases I refer to.

As to the preliminary operation. I never do it except for the relief of glaucoma a few months before operating. I never do a preliminary iridectomy and personally I do not see any necessity for it. It subjects the patient to two operations and these patients are very nervous about the number of operations and I do not see any advantage in the results obtained in this way. Of course from the operator's point of view it is very simple. It is harmless. I do not see any objections except from the patient's point of view.

As to vitreous membranes. I have seen very few cases; so few that I would neglect them.

It has occurred to me that I thought I had extracted the lens in capsule and found that I had left the capsule behind. The lens may come away with such ease and slip out, leaving a membrane.

Now suppose you have dislocated the margin of the lens and the vitreous seems to want to come, the proper thing to do is to

drop in the spatula behind and with the hook on the outside you stroke it up and the vitreous drops back all right.

As to the patients who roll up the eyes. If your assistant holds forward the lid properly for you it does not matter how high he rolls up the eye the lens comes out just as well. If the capsule bursts you must then try to get him to roll the eye down so as to get hold of the capsule.

As to the day of discharge; for some years past the day of discharge at my hospital has been on an average the 8th or 10th day. I would prefer to keep them longer if I had greater accommodation. There is then usually but slight congestion and perhaps some photophobia. The photophobia probably lasts a little longer than in the ordinary operation.

EXTRACTION OF CATARACT WITH A LANCE-SHAPED KNIFE.

BY J. HERBERT CLAIBORNE, M.D.,
NEW YORK CITY.

The Graefe knife is now, and has been since its invention, the classical knife for the removal of senile cataract, and it would border almost on the impious to doubt its efficiency or proclaim that it does not completely fulfill the requirements. Nevertheless, there are a number of sound objections which may be raised against it.

In the first place, its use necessitates a counterpuncture which should relatively correspond with the puncture; in the second, a sawing motion is necessary to conclude the section — this causes an irregular and jagged wound, delays union, increases the risk of suppuration and the degree of postoperative astigmatism; in the third place, it necessitates the greatest precision in adjusting the size of the section.

These objections are valid, and I do not believe they can be successfully combated. If a knife can be invented with which the lens can be removed and which does not possess the disadvantages outlined above, I believe it should be preferred to the Graefe knife. I have long thought that if the lens could be removed by means of an irregular lance-shaped keratome of dimensions to make a wound large enough to allow the easy exit of the cataractous lens, the disadvantages of the Graefe section would be avoided.

We are all familiar with the rapidity and smoothness with which a wound caused by a lance-shaped keratome heals. The difficulty, however, lay in constructing a knife of such dimensions as would make a wound large enough for the exit of the lens. To do that, it was necessary to know the dimensions of the cataractous lens without its capsule and the diameter of the

anterior chamber. Investigation led me to believe that the cataractous lens, when measured just after its delivery, had in general a diameter of 9 mm. I accepted this as a fact, and attempted to find the diameter of the anterior chamber. I wished, of course, the diameter in the vertical meridian, and I experienced considerable difficulty in finding it. After investigation, I concluded that it was safe to assume it to be 11.6 mm. in diameter, at least in the vertical meridian, and I proceeded with this as a fixed quantity. It therefore became necessary to construct a lance-shaped knife which would make an opening in the anterior chamber large enough to allow the easy exit of a lens 9 mm. in diameter. In studying the dimensions of the anterior chamber by the double corneal magnifying lens, I could see very plainly that the anterior chamber extended back much further than the sclero-corneal margin, as apparent to the naked eye. But in using a knife it is quite impossible to avail one's self of the aid of the corneal magnifying glass at the same time, so I assumed that the cataract knife generally enters the anterior chamber about 2 mm. within its actual limit. I therefore concluded that I had to deal with a circle of 9.6 mm. in diameter, and I had a knife so constructed that when it was thrust into the anterior chamber and its apex had arrived in the inferior corneal angle, the chord which measures two-fifths of the diameter of the anterior chamber would correspond to a wound 9.2 mm. in length. (Fig. 1.)

Mr. H. S. Andrew, C. E., kindly made the mathematical calculation and drew the figures which are shown herewith.

As can be seen, the base of the knife was 12 mm. and the length 8.048 mm. Antecedent to having this knife constructed, I had another made, the base of which was 12 mm. and the length 6 mm. I tried this knife on a cadaver, but the experiment was unsatisfactory, and non-conclusive on account of the time the cadaver had been in the dead house. The knife, however, was boiled and resharpened, and I used it in a case of soft cataract in a woman thirty years of age. The angle caused by

the above-stated dimensions was so obtuse (90°) that the knife entered the cornea only to one-half its length. Nevertheless, the cataract was delivered, but by an incision which really amounted to the old linear one. This experiment, therefore, proved nothing.

The knife mentioned above, as estimated by Mr. Andrew, to wit, with a base 12 mm. and length 8.048 mm., was constructed, and in two weeks a typical case for its exploitation was found.

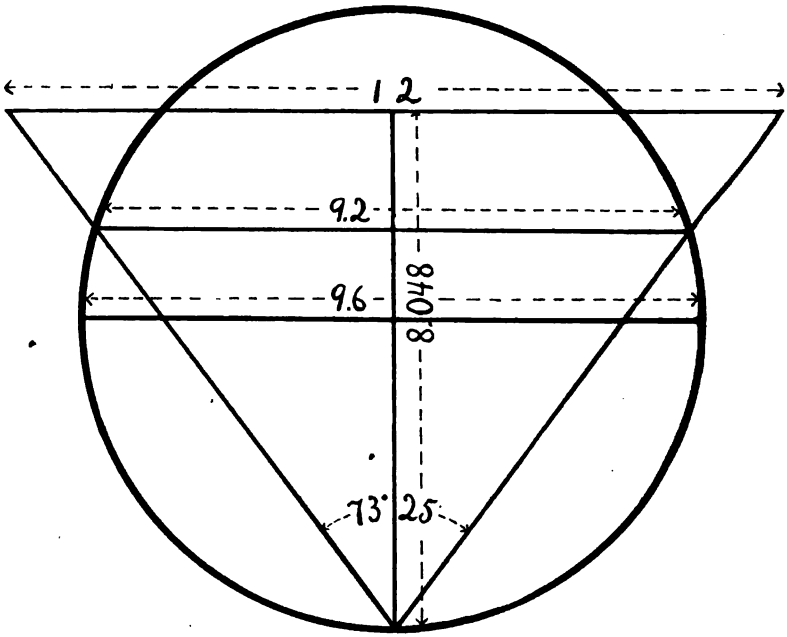

FIG. 1.

The cataract occurred in a woman of forty, and had been completely ripe for several months. It was one of those dark-yellow sticky cataracts which are well known to eye surgeons and which are so difficult to extract from the capsule. The case, therefore, presented ideal conditions for testing the value of the knife.

The knife entered about 2 mm. behind the apparent sclerocorneal margin. The entrance was easy and the knife was shoved home, the apex of the blade apparently entering the lower iris angle. As the knife was withdrawn, a sideways

cutting stroke was employed, in order to slightly enlarge the corneal section. This is a maneuver well known to those who use the lance-shaped keratome in performing iridectomy. A small iridectomy was done, and afterward a peripheral cystotomy. The wound gaped and the lens presented at the wound mouth as if anxious to come out, but when pressure was made by two spoons, one above and the other below the cornea, it failed to come. I then attempted to enlarge the nasal lip of the wound by De Wecker's scissors, but they failed to cut, and I at length repeated the cystotomy, making it more extensive and more thorough. Pressure below and counter-pressure above caused the lens to be delivered as easily as such sticky lenses usually are. The lens measured 9 by 8 mm. and was delivered whole.

I am convinced, as well as were others who witnessed the operation, that the corneal wound was not enlarged at all by the scissors and that had I made a cystotomy more extensive and more thorough in the beginning the lens would have been delivered at the first attempt.

The wound closed in forty-eight hours, although there was some striped keratitis. This disappeared in a few days, and the patient left the hospital on the seventh day without having had an untoward symptom.

No cortical substance remained and the vision, without a disission, equalled 20/20 mm. w. + 9 D. S. ⌣ + 1.5 D. C. ax 180°.

My colleague, Dr. Thomas R. Pooley, has called my attention to a paper by Weber, of Darmstadt, published in 1867, in which he sets forth the idea of removing cataract by a keratome. After all is said and done, however, the idea is not original with Weber, for the most cursory glance at the recent paper published by Hirschberg in the Graefe-Saemisch Handbuch shows that Daviel, in 1752, and les Freres Grandjean, Paris, 1766, removed cataracts with knives which more nearly resembled that of Weber than his resembles the one I have just described. I conclude, therefore, that the idea is not Weber's, but Daviel's; that the

brothers Grandjean followed him, that Weber followed them, that I have in turn followed Weber, in a measure. All of these knives, however, differ, and each is entitled to its place in the archives of ophthalmology. Sattler also has extracted cataract with a keratome.

Weber, in his paper entitled "Die normale Linsenentbindung der modificirten Linear Extraction gewidmet" describes his knife. It is a bent knife of a heart shape, whose back is hollow-ground. It has on the handle a rough surface for better manipulation. It has a length of 10.25 mm., so that it may cross an anterior chamber of 12 mm. diameter to the opposite scleral limbus; 6.5 mm. from its point it has a breadth of 10 mm., and it increases in width 2 mm. more at its base. It then tapers off to the handle, as shown by the drawing. Fig. 2.

The curved character of the wound made by this knife is shown in Fig. 2 (b).

It will be seen, therefore, that the knife which Weber has described differs materially from the one I have devised. His knife is heart-shaped and has a hollow back. Mine is a triangle and has a flat back, so that the anterior and posterior surfaces occupy parallel planes; it therefore makes a straight wound; it increases in thickness gradually from apex to base, and the handle rises from the base of the triangle exactly as in the regular lance-shaped keratome at present in use for iridectomy. The length of the Weber knife is 10.25 mm., whereas the one I have described is 8 mm. in length. The greatest breadth of his knife was 12 mm. at the base of the triangle; mine likewise was 12 mm. at the base. His knife was so constructed that at 6.5 mm. from the apex the breadth was 10 mm.; this would insure the safe passage of a lens of 9 mm. in diameter, but it is questionable whether with so obtuse an angle the knife could be thrust into the anterior chamber at all. In support of this suspicion is his statement that in regard to the cutting qualities of his knife he had some complaints to make, but that later he was completely satisfied with the work of his instrument-makers.

My experience in that line leads me to doubt the efficiency of a heart-shaped knife which at 6.5 mm. from the point possesses a breadth of 10 mm. The angle is too obtuse for a stab wound to be made easily. The knife which I devised, however, entered the anterior chamber with as much ease as any of the lance-shaped keratomes I have ever used. The angle subtended by

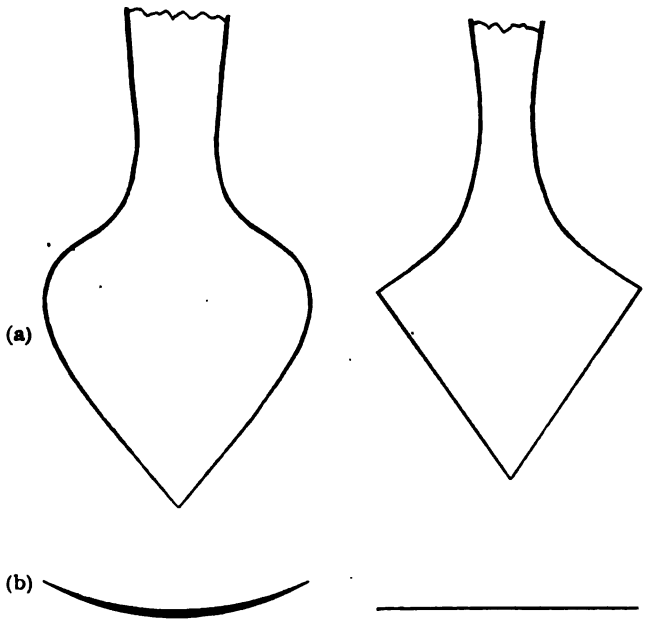

FIG. 2

the point of the knife I have described was 73.5°, as shown by Mr. Andrew's drawing.

After performing the operation, I became convinced that I could use a knife with a broader base with greater certainty of success.

It will be observed that Weber estimated the depth of the anterior chamber at 12 mm., and I found it later estimated at 13 mm. (Encyclopedia Francais, vol. I.) In view of these findings, I had Mr. Tiemann make me a final knife with a base of

14 mm. and a length up to the base line of 10 mm. (Fig. 3.) But it will be observed that there are about 2 mm. of blade above and beyond the base line, after the manner of the ordinary lance-shaped keratome; this gives the knife 2 mm. more length and insures the entrance of the point well into the lower iritic angle.

FIG. 3.

The largest keratome made by Mr. Tieman has a base of 10 mm. and a length of 14 mm. This last knife, then, just reverses these measurements, and the angle subtended at the point is 70° (Fig. 4). If now a knife with a base of 12 mm. and an angle of 73.25° at the point was sharp enough to enter the anterior chamber with ease, a knife which possesses a more acute angle (70°) will do the same thing beyond peradventure, and the value of this knife as a cutting instrument is established.

If we then allow that the knife will enter the anterior chamber 2 mm. within its actual limits, the diameter of the anterior chamber may be estimated at 11 mm. By referring to Fig. 4 (A), it will be seen that a knife of the above mentioned measurements, when it enters an anterior chamber 11 mm. in diameter and its point reaches the lower iritic angle, will make a wound at the chord XY, 10.337 mm. in length. If, however, we allow that the knife enters 1 mm. within the actual limit of the anterior chamber, we have to reckon with a circle the diameter of which is 12 mm. and the length of the cord X y in this case is 11.276 mm. Fig. 4 (B). In either case there will be ample room for the easy exit of a lens of 9 mm. in diameter. These calculations also furnish a generous allowance for the personal equation of error in introducing the knife. The theorem, therefore, set at the beginning of this paper is amply demonstrated.

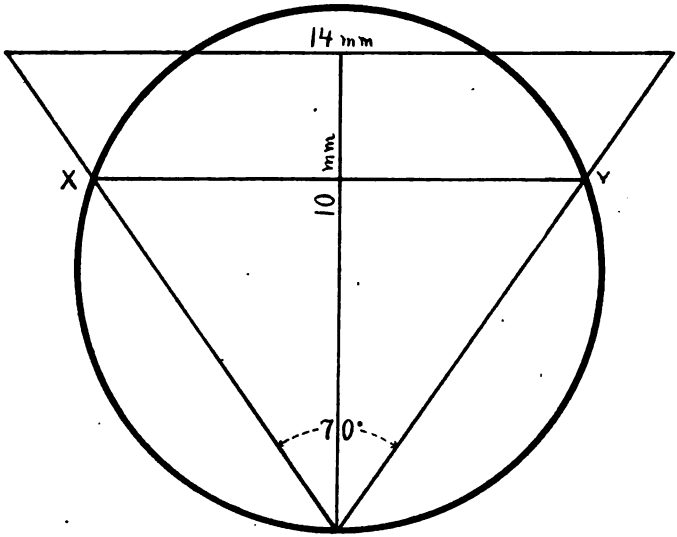

A.— Circle 11 mm. diameter Chord XY = 10.337 mm.

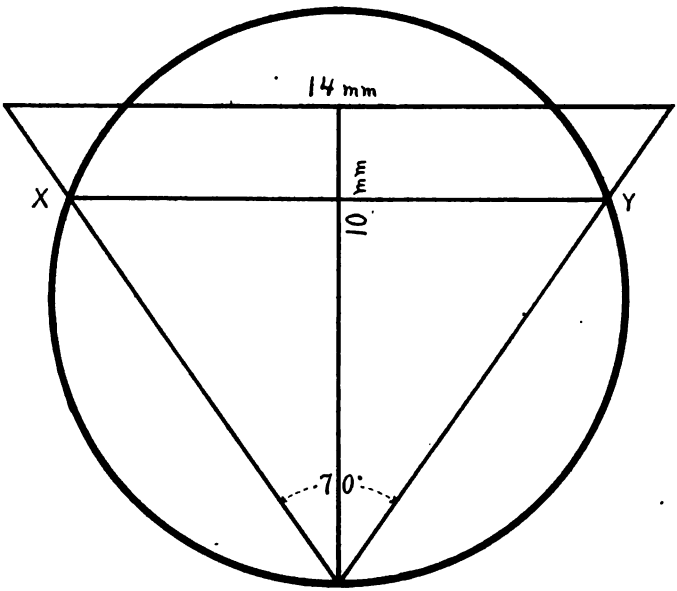

B.— Circle 12 mm diameter. Chord XY = 11.276 mm.

FIG. 4.

The rule for using the knife which I have employed is as follows: The surgeon should stand behind the patient and a fixation forceps should be applied directly below the cornea opposite the point of entrance of the knife; eye being rotated downward, the point of the knife is entered about 1 to 2 mm. behind the sclero-corneal margin in the median plane of the vertical meridian. The knife should then be shoved straight across the anterior chamber until its apex arrives at the limit of the inferior iritic angle, when it should be withdrawn slowly. A cutting motion to the right being made in order to slightly enlarge the size of the wound, if the operator thinks necessary. If the knife is withdrawn too quickly, aqueous escapes rapidly and the iris is apt to prolapse. The simple or the combined extraction may be performed. For my part, I prefer the combined, as it renders the exit easier. Care should be taken to maintain the point of the knife at the same plane in which it entered. The section is executed within 3 seconds, and forms a marked contrast to the time required to perform the Graefe section.

With the knife just described, having a base width of 14 mm. and a length of 10 mm. I performed a combined extraction upon a woman aged 70 in the presence of Dr. C. S. Rodman of Waterbury, Connecticut. The operation was done under general anesthesia.

The vision of the eye before operation equaled fingers at 3 feet. I judged the cataract to be slightly degenerated, suspected that the vitreous was fluid and that the suspensory ligament was frail.

The patient having been thoroughly anesthetized, the broad keratome was entered 2-3 mm. behind the apparent sclero-corneal margin. The knife was exhausted and withdrawn in the plane in which it was entered without any cutting motion to the right being employed. A peripheral cystotomy was done, but when it was attempted to deliver the lens, a bead of vitreous appeared above it, and, for fear of losing more, I enlarged the incision with scissors, when the lens leaped out under the slightest pressure possible without further presentation of vitreous.

The wound closed in 48 hours, and no untoward symptom whatever appeared thereafter. The columns of the coloboma were parallel, not incarcerated, and ultimate vision in one month without secondary operation equaled 15/40 w. + 11 D. S. No cortical substance remained. These notes were furnished me by Dr. Rodman.

It is my opinion that I entered the knife too far behind the sclero-corneal margin in this case, so that the wound did not gape as readily as it should have, and to this fact, as well as to the semi-fluid vitreous and the weak ligament, I attribute the necessity of enlarging the wound to deliver the lens.

Within the last three weeks, I have operated a third time, and with another model of the lance-shaped knife. This knife measured 14 mm. at the base line, and 9 mm. from point to base line, being therefore, 1 mm. shorter than the knife used in the preceding operation. There was this difference also — from the base line to the angle where the shaft rises from the blade, there was only 1 mm. of length. This knife, then, from point to shaft, measured 10 mm. all told, whereas the preceding knife measured 12 mm.

The third case was that of a woman of 42 who had a swollen lens, the opacity being mostly central; a dim reflex could be observed at the periphery when the pupil was widely dilated with atropin.

The pupil was slightly dilated at the time of the operation, the result of the atropine which had been instilled to facilitate the examination. The operation was done under cocaine in the presence of Dr. Thomas R. Pooley, Dr. E. B. Coburn, and others. The knife was entered about 1 mm. behind the sclero-corneal margin, a trifle to the left of the median line, and pushed in to the hilt. Owing to the exceeding shallowness of the anterior chamber, the point engaged in the upper edge of the dilated sphincter but became at once extricated as the knife was pushed further in. In withdrawing the knife, a sweeping motion to the right was used, wherewith it was my intention to slightly enlarge

the wound. As this was done, the right edge of the iris fell before the side of the knife and it was nicked. Notwithstanding all of this, the iris did not prolapse and a central pupil remained. It would have been easy to have performed a simple extraction, but according to my custom, an iridectomy was done. The capsule having been incised by a peripheral incision and slight pressure having been made above and below the cornea, the lens was delivered as easily as I have ever seen it done after the Graefe section. The lens was rather soft, but it measured 9 by 8 1/2 mm. This section appeared to be in every sense ample.

The wound was closed in 48 hours. The patient left the hospital on the 9th day, but from my inspection of the wound on the 5th, I am convinced she could have left it then without danger, as at that time the wound was firmly healed, and the eye without irritation. No cortical substance remained.

The vision at the end of three weeks equalled 20/40 with + 10 D. ⊂ + .75 D. c. ax. 15°.

The glass worn before the operation was a plus sphere combined with + 50 D. c. ax. 180°.

In the future, I shall always operate with the model used in the last operation, but the blade will be 10 instead of 9 mm.

It will be observed that no cortical substance remained in any of the three cases; the columns of the colobomas were parallel and it might be said, classical; the remaining capsule was exceedingly thin and the vision was remarkably good without discission — the vision in the first case being 20/20, in the second 15/40, and in the third 20/40 with correction. The astigmatism in the first case was 1 D., in the second no cylinder was accepted, and in the third it was only .75 D. This may be attributed, in part at least, to the position of the section, but also largely to the character of the wound. Of course, cases at times occur in which there is as little astigmatism after the use of the Graefe knife as after the use of this knife, but in the great majority of cases, the astigmatism after the Graefe section is

considerable and often very marked. The absence of cortical remnants may be incidental, or accidental, but the last case was one in which remaining cortical substance was naturally expected. I always syringe out the anterior chamber as far as that can be done by flushing the wound, but I did not push the tip of the flushing syringe between the lips of the wound. The fact is at least worthy of record.

If we look for a moment at the modern Graefe knife with which the now classical operation of modified linear section is made, we see at a glance that it is a fac-simile, greatly reduced, of the Catlin knife for amputation at the hip. It is, in effect, an extremely delicate and finely-tempered sharp-pointed scalpel.

The disadvantages of the Graefe knife, I think, may be categorically stated in this wise:

1. The necessity of counter-puncture.

2. The difficulty of making counter-puncture correspond with puncture.

3. The necessity of a sawing movement to finish the section.

4. The necessity of making puncture, counter-puncture and section at an angle to the support of the fixation forceps.

5. The difficulty of finishing the section at exactly the point intended.

6. The loss of aqueous and consequent exhaustion of anterior chamber after counter-puncture during the performance of the section.

7. The falling of the iris before the knife.

8. Imperfect apposition of lips of wound on account of its ragged and serrated character; increase of liability to suppuration by reason of raggedness of wound; tardy healing; increase of post-operative astigmatism.

9. Necessity of ambidexterity, in order to operate on each eye equally well.

10. Necessity of adjusting size of section.

11. Danger of prolapse of vitreous when section is too large or ends too far back of sclero-corneal margin.

12. Length of time required.

The advantages of a section made by a properly-constructed lance-shaped keratome are practically the corollary of the above. They are:

1. There is no counter-puncture.

2. The section is made in the plane of the support furnished by the fixation forceps.

3. The wound is a stab-wound, and by virtue of that fact is smooth; no sawing motion is employed.

4. The section is practically finished by shoving the knife home.

5. There is no loss of aqueous while the section is being made, because the knife increases in thickness from the apex to the base, and the further it is shoved in the tighter it stops the wound.

6. The iris is not so apt to prolapse on withdrawing the knife, because the broad back of the knife holds it in place.

7. The iris cannot fall before the knife from loss of aqueous because no aqueous is lost during the section on account of the shape of the knife.

8. Perfect apposition of lips of wound by virtue of its smoothness; rapid healing; less liability to suppuration; less post-operative astigmatism.

9. Use of right hand for both eyes.

10. If the knife is entered properly and shoved home, the section is bound to be correct; it automatically commands success.

11. Less danger of prolapse of vitreous, because of the support furnished by the broad back of the knife.

12. Diminished time.

Although I have categorically outlined the advantages of the section by the lance-shaped keratome, it appears worth while to lay stress upon the difference between it and the Graefe section in one respect.

That space of time which elapses between the puncture and the completion of the Graefe section is fraught with danger at

every second and it is a trial alike to the nerve of the patient and the surgeon. It requires from 10 to 15 seconds at the hands of the most skillful surgeon. During this time, there is the danger of too great pressure with the fixation forceps, of pricking of the lid or nose by the point of the knife, and of squeezing of the lids or general nervous conduct on the part of the patient with consequent destruction of the eye by loss of vitreous. Fortunately, it has never occurred to me, but I know of several instances in which the eye has been lost by this accident at the completion of the section, at the hands of thoroughly skillful surgeons.

With the lance-shaped keratome, the section can be completed in three seconds. The thing is done almost before the patient or the surgeon is aware of it. The time required for the extraction is reduced at least 15 to 20 seconds.

Very skillful surgeons may contend that they have accomplished the Graefe section many hundreds of times without disaster, but no reasonable objection can be raised to a section which requires shorter time, is surer and is attended by less risk than the Graefe one.

Owing to the limited experience in the use of this knife it may be argued that some of the claims for its superiority over the Graefe knife are academic, and indeed it may be held with justice, but the fact is that with it three different kinds of cataract have been removed *cito, tuto et jucunde.*

The instrument is particularly applicable to soft cataract, to Morganioan cataract, to artificially matured cataract or to cases of glaucoma in which it is desired to make an exceptionally large coloboma.

DISCUSSION.

Dr. T. R. Pooley, New York: In the early seventies I made several extractions with the Weber knife. In each instance the wound made was too small and my experience in the few cases was such that I abandoned it. The experience I gained by this led me to look askance at the knife described by Dr. Claiborne and I was therefore an interested observer of one or two of the

operations he did and in the last case which he described which was a very mature cataract with nucleus of ordinary size the delivery was as easily accomplished as I have ever seen it done with the Graefe section. I was very skeptical as to its ability to make a proper section, but I am convinced that it can be used with success, but whether applicable to all cataracts or not I am not quite certain. I intend to try the method.

DR. DAVID WEBSTER, New York: This method of making the incision as we are all aware is not a new one. Many years ago, fifteen or twenty at least, when I was in London, Mr. McNamara was doing all his operations with a knife like this except that it was a straight knife, not bent upon the flat, and, I am not aware that he ever had to enlarge his incision. He, of course finished his extraction in a different way — he went in with a spoon, and without iridectomy, pressed upon the temporal side of the cataract and caused it to turn a somersault. The incision, however, was exactly as the doctor describes, except that it was on the temporal side instead of above.

DR. H. B. CHANDLER, Boston: In using a keratome it is difficult to get one the sharpness of which can be depended upon. It is impossible to pass a keratome through some corneas and you have to use a Graefe knife. I have also found that the keratome is the most unsatisfactory instrument to get sharpened. One would have to have a new knife for each operation.

MAJOR HENRY SMITH: With the remarks of the last speaker I fully agree. I have used this instrument for iridectomies only and regard it a difficult instrument to use and one that is very difficult to keep in good cutting order. The advantages claimed for it over the Graefe knife I personally do not see. If the operator using the Graefe knife catches the handle as he would hold a pen in writing, directs it straight across to the heel and finishes with one clean sweep there can be no more perfect incision made. With the other instrument in doing iridectomies I have frequently had to rock it and make a sawing cut. Personally I cannot see how the incision can be made cleaner, straighter or more rapidly with this instrument than with the Graefe knife. We must use the Graefe knife occasionally and the fewer instruments we use the more dexterity we acquire with them. If we use a multiplicity of instruments our dexterity with

any one of them is not as great as where we familiarize ourselves with few.

DR. T. Y. SUTPHEN, Newark: It seems to me that one of the greatest objections to this knife is the danger of splitting the layers of the cornea.

It is an extremely difficult matter to avoid this, even if the point itself penetrates the cornea at a right angle. In my experience the cases in which the iris is apt to fall before the knife, are those where the counter-puncture is difficult, requiring considerable pressure, and the passage of the blade through the anterior chamber is slow — hence I have favored the use of a Graefe knife with a rather slender point, which penetrates with rapidity and ease, and a thin blade which completes the corneal section quickly.

DR. J. H. CLAIBORNE, New York: Dr. Pooley possibly has forgotten the first case in which I used this knife, that of a young woman with a ripe cataract. She was 42 years of age, but the cataract was one with all the appearance of a senile cataract. It was quite possible to make the measurements accurately. The case illustrated the fact that such a cataract could be as easily delivered as the others.

There is no difficulty in keeping these knives sharp in my experience. I have used one several times without sharpening it. I always test it with the drum and if it is not sharp it can be easily sharpened.

As to the difficulty of entering the cornea, I don't accept that for an instant. We all know that we must enter the knife at a right angle and then turn it; if that is done there is no difficulty.

Major Smith unquestionably has acquired the faculty of making the incision with one sweep of the Graefe knife, but in this country I have never seen any one who could do it. There is always a sawing motion.

I hope some of the members will try this method. I feel sure that it is possible to remove any form of cataract in this way. I am aware that I am not the first one to use a similar knife, as I have said. I have just heard from a gentleman here that it is being used in Philadelphia.

AN ATTEMPT TO DETERMINE THE NORMAL RANGE OF ACCOMMODATION AT VARIOUS AGES — BEING A REVISION OF DONDERS' EXPERIMENTS.

BY ALEX. DUANE, M.D.,
NEW YORK CITY.

Donders in his classic experiments on the accommodation determined the absolute near point in a series of subjects under 45, who were assumed to be emmetropic, and in a series of subjects over 45, who, for the most part hypermetropic at the time of examination, were assumed to have been emmetropic earlier in life. Since, in the absence of cycloplegic tests, no person below the age of 45 can be pronounced to be emmetropic — since, in fact, we know that 1 or 2 D of hypermetropia may remain latent up to and even beyond that age — both of Donders' assumptions must be regarded as at least open to criticism.* However this may be, what we wish to know as clinicians is not the way in which the absolute near point recedes in an eye which began by being emmetropic and afterwards became more or less hypermetropic, but rather the absolute range of accommodation at each age and the limits within which this range may vary. To ascertain this in a sufficiently large number of cases, a series of experiments have been made by Dr. J. B. Thomas and myself. In carrying them out we first rendered each patient absolutely emmetropic by glasses; then ascertained his near point with this correction. This, of course, gave the range directly. The values thus obtained for the range were

* Especially the second. In speaking of the hypermetropia which he believes to develop late in life and cause a recession of the far point, he says: "I have not infrequently met with this in persons of sixty years of age, who in their youth probably exhibited no H. whatever. This was inferred when they did not before the forty-fifth year of their life need spectacles in the evening for close work." With our present knowledge this inference would certainly be unwarranted.

then plotted on a diagram like that used by Donders. Under the conditions employed the diagram assumes the form shown in Fig. 1. That is, the line, CC, denoting the far point at different ages coincides everywhere with the zero or base line, instead of falling below it at the age of 45; and after the age of 50, the line, AA, denoting the near point, instead of approaching the base line, runs nearly parallel with it, i. e., is almost horizontal.

In pursuing the plan above outlined close attention had to be paid to the following points:—

1. The subject must be made really emmetropic, i. e., his refraction must be wholly and accurately corrected. In order to effect this, the refraction was carefully determined in every one of our cases, and a cycloplegic was used in all under 48 and in some over that age. Especial care was taken to determine the astigmatism accurately, to within 0.25 or even 0.12 D.

2. The subject's vision must be such that he is capable of making the fine distinctions required in the test. That is, he must have clear and good vision with his glasses. Hence we were obliged to reject cases of irregular astigmatism, of high astigmatism even when corrected, of high myopia, of amblyopia from any cause but especially amblyopia associated with any defect in central vision, of poor vision from corneal or lenticular opacities, etc. Subjects thus affected, can not discriminate between the blurring due to accommodative failure and the blurring due to their naturally defective vision.

3. When the near point is not further than 50 cm. nor closer than 10 cm., it is best to apply the full correction, without addition or subtraction, and then determine the near point. This, of course, gives the range of accommodation directly.

4. When the near point is closer than 10 cm., a slight error in determining its position will involve an error of several D. in the estimation of the range of accommodation. In such cases it is well first to make the test as above described, i. e., with the full correction alone, and then with the latter combined with a—4

or a — 5 D. spherical, so as to carry the far point out beyond 10 cm. It must be noted, however, that tests made in this latter way — either because of the diminution in the apparent size of the test-object or because of the sudden strain put upon the accommodation — usually give an underestimate of the patient's accommodative power. Thus a patient to whose distance correction we have added — 5 D. may show a near point of 13 cm. corresponding to 7 D. of accommodation and indicating a total range of only 12 D., and yet when otherwise tested he may show an actual total range of 14 or 15 D.

5. In subjects whose near point is beyond 50 cm., a suitable convex glass must be added to their full correction to bring the near point within measurable distance. Such convex addition should be as small as possible. For, a strong convex glass, probably on account of the magnification that it produces, sometimes brings the near point closer than it should be theoretically. Thus, a patient with + 3.50 D. added to his distance correction may have a near point of 17 cm. indicating an accommodation of 6 D., or a net range of 2.50 D., and yet when we test him in other ways we find that his true range is not over 1.50 D. In general, then, when we make tests of this kind, the auxiliary convex glass is made just strong enough to bring the near point to 50 cm. or somewhat less.

6. The subject's accommodative power, or rather his will and ability to exercise it, vary a good deal according to circumstances, especially in young subjects. Hence, in order to establish the actual accommodative power, repeated tests are necessary even in the same subject. Some of our cases afforded a striking example of this variability. Thus, Lena B. when tested at the age of 15 showed an accommodation of 8.50 D., which a year later rose to 9.50 D. So Dr. H. at the age of 30, had a range of about 5 D., and some months later a range of 7 D. In each case the first measurement surely meant a range which was not only below the average for the age but also below the average of the individual.

Regard to this point, i. e., to the necessity of making repeated observations in a case before deciding as to its accommodative range, has forced us to exclude a number of cases in which we were able to make the test but once under proper conditions.

7. We must always be on the lookout for erroneous or careless observation on the part of the patient. Careful attention to details and careful explanation of what he is required to notice will obviate this cause of error. Particularly must we urge young subjects to put forth all their efforts and strain as hard as they can, so as to focus down upon the test-object at the closest possible point. Again they must be careful to notice the first sign of blurring or doubling of the test-object — indicating the point where this begins to occur and not the point where the object becomes entirely confused.

8. Last, and by no means least, our method must be such as to afford the most accurate results. Here we must consider:—

(*a*) The character of the test-object. Donders used fine print in order to ascertain the near point. This, however, for most people does not afford a very accurate test. With me, for example, it gives a near point corresponding to a range nearly 1 D. greater than the true one. After trying a number of objects — dots in pairs and groups, parallel lines, simple geometrical figures, etc., we have concluded that the best test-object for practical purposes is a simple engraved line 0.2 mm. thick and 3 mm. long. This when brought within the near point blurs slightly and then doubles. If the subject's attention is called to this fact and he is cautioned to indicate the very nearest point at which the line is still clear and sharp, a good estimate of the true punctum proximum will be got.

As Hess points out, Scheiner's test gives a more accurate means of determining the absolute near point, but while the test is suitable for physiological experiments, repeated trials have convinced us that it is not available for clinical purposes. What we require of a test of this sort, for it to be practically useful, is that it shall be applicable to all sorts of subjects, even the un-

trained and unintelligent. If it does this and if, furthermore, when used under proper conditions, it gives the near point with fair accuracy, it will be much better for our purposes than a test which is difficult of application but scientifically more precise.

So far as accuracy is concerned, tests on myself seem to show that the fine line if made slender enough and sharp enough gives almost precisely the same results as Scheiner's test.

(*b*) The illumination. This is a matter of great importance. The light should come from behind over the right shoulder when the right eye is tested and over the left shoulder when the left eye is tested. Furthermore, care should be taken that there is no shadow on the card and no dazzling reflections or confusing lights beyond it or alongside. For this reason when the test is made with Prince's rule, the latter should be held with its broad side vertical and not horizontal, as in the latter position the graduations on the rule and the glare from its surface are apt to distract the patient's attention or cause confusion.

(*c*) The starting point of the measurement. Generally the measurements are made from the anterior principal point of the eye. For practical purposes, this is taken to be equivalent to the anterior surface of the cornea — the small error of less than 2 mm. being disregarded. I, however, in making my estimates have preferred to reckon from the anterior focus of the eye, i. e. from a point 13 mm. in front of the cornea. My main reason for doing so is that this is the point at which we place the convex glass that we use to measure the accommodative power and to replace the latter when absent. Thus, when we speak of a deficiency of accommodative power of 6 D, we mean a deficiency that will be replaced by a lens of that strength placed at the anterior focus (not at the anterior principal point) of the eye.

The difference between the results obtained by the two methods of measurement is shown in the following table computed from the figures obtained by Donders:

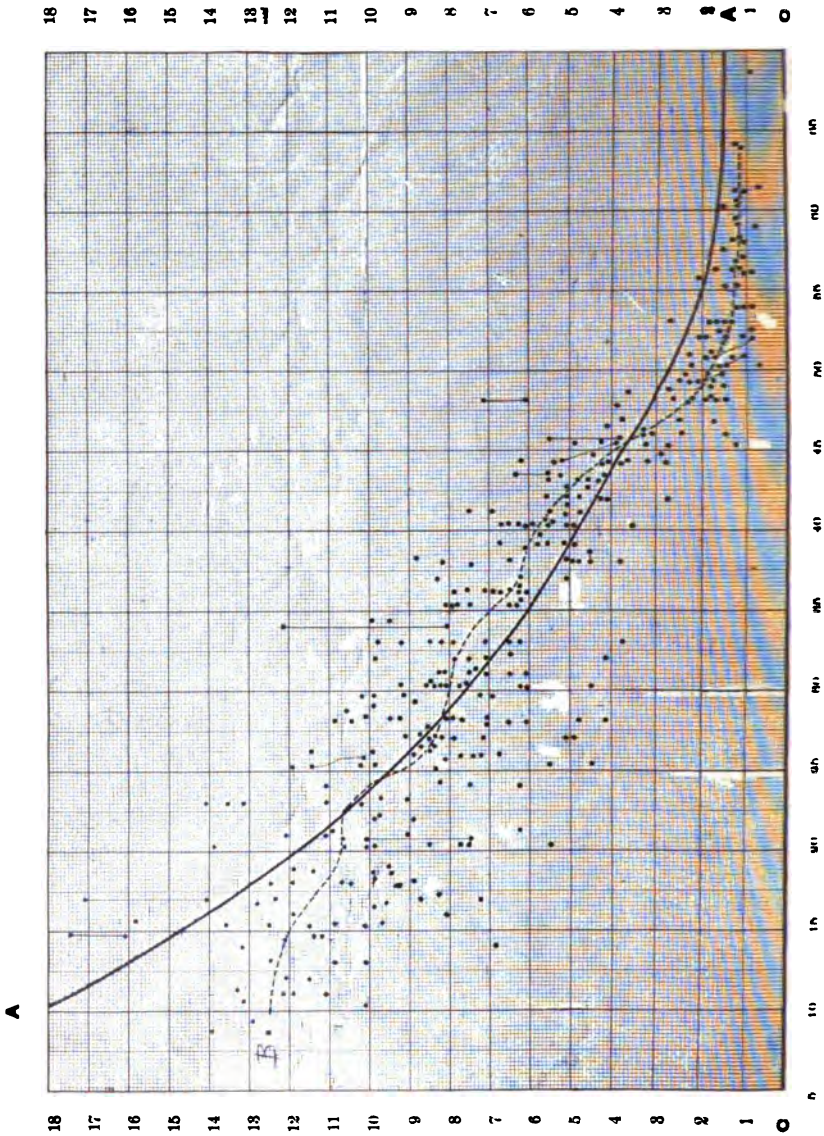

FIG. 1.

RANGE OF ACCOMMODATION AT DIFFERENT AGES.

Each dot denotes the range found in a certain case at a certain age — the patient being rendered strictly emmetropic by glasses. A marked and constant difference between the accommodation of the two eyes in the same subject is indicated by a pair of dots connected by a vertical unbroken line — the accommodation in the right eye being shown by one dot and that in the left by the other. Dots connected by a fine dotted oblique line denote different findings at different ages in the same case. The near point was measured always from the anterior focus of the eye. The heavy black curved line, AA, is Donders' curve modified so as to conform to this measurement and to represent not the absolute near point but the absolute range of accommodation at each age. The heavy broken line, BB, shows the average curve as we found it in 390 cases.

Age.	Range computed on the assumption that the glass equivalent to the amount of accommodation is placed at the anterior principal point of the eye. (1. 7. mm. behind the cornea.)	Range computed on the assumption that the glass equivalent to the amount of accommodation is placed at the anterior focus of the eye (13 mm. in front of the cornea.)
10	14	18
15	12	15
20	10	11.8
25	8.5	9.7
30	7.0	7.8
35	5.5	6.0
40	4.5	4.8
45	3.5	3.7
50	2.5	2.6
55	2.0	2.0
60	1.5	1.5
65	1.5	1.5
70	1.5	1.5

It will be seen that when the near point is close to the eye, the differences are considerable (3 or 4 D). This is also obvious from our Fig. 1, in which the black curved line AA represents Donders' presbyopic curve when plotted according to the method of measurement here advised. It will be seen that the curve at its beginning rises much higher than the curve as ordinarily depicted.*

(*d*) Uniformity in the methods and the test-objects employed. If our results are to be comparable with each other, we must in every case employ the same sort of test-object, take the same precautions as regards illumination and other conditions, and make our measurements from the same point of reference.

Having regard to these requirements, Dr. Thomas and I have examined a large number of cases, of which nearly 400 have proved available for tabulation. This is about three times the number of cases that Donders used to base his results on.

Many as the cases are, they are yet too few for a final analysis, and the conclusions based on them must be regarded as tentative only. Some of these conclusions are as follows:

1. The findings as regards the absolute range of accommodation and consequently the shape of the presbyopic curve differ

* And for the reason stated before is much flatter at its end.

somewhat from those got by Donders (see lines AA and BB in Fig. 1).

2. As a particular exception, the accommodation in childhood and youth seems to be not so high as he stated. I have rarely found a range much above 14 D (11 D if the near point is measured from the cornea) in children between 8 and 13.

3. The range does not apparently seem to diminish much between the ages of 10 and 15. It is even possible that it may rise, and that the maximum accommodation is found somewhere about the age of 16 or 18. But many more observations than we have would be required to prove or disprove this.

4. The accommodation does not decrease year after year by any steady sweep, but at some periods of life seems to remain about the same for years together and then descend rapidly.

5. Two periods of apparent stasis are those from 25 to 30 and again from 35 to 40. To make sure of this point, however, many more observations would be required than we have in hand.

6. Much more certainly demonstrated seems to be the decided and rather abrupt plunge that begins at the age of 40 and continues uninterrupted to the age of 51. The accommodation during these eleven years falls from 5.9 to 1.50 D, a drop of 4.4 D, while in the preceding eleven years it falls 3.4 D.

7. After 51 the accommodation remains nearly constant, diminishing not more than 0.50 D in ten years.

8. The average, minimum, and mean ranges that we have found at the different ages (excluding the cases that were probably distinctly sub-normal) are as follows:—

		RANGE.		Donders'
Age.	Mean	Low.	High.	Average.
10	14.0	10.0	16.5	18.0
15	13.0	9.7	16.0	15.0
20	10.7	7.5	14.0	11.8
25	9.6	8.2	12.0	9.7
30	8.8	6.3	10.4	7.8
35	7.0	6.5	8.0	6.0
40	5.9	4.9	6.7	4.8
45	3.8	1.3	5.0	3.7
50	1.8	0.7	2.3	2.6
55	1.3	1.2	2.0	2.0
60	1.2	1.2	1.5	1.5

9. Owing to the variations shown by the same case from time to time, a single determination of the accommodative power is of little value. This is particularly so if the value found is subnormal or if the proper conditions of examination have not been fulfilled.

10. Some peculiarities may be mentioned.

(*a*) The highest range noted (17 D) was found in a patient of 17.

(*b*) Three at the age of 23 had an accommodation of 13 to 14 D.

(*c*) One patient of 48 had an accommodation of 6 D in one eye and 7 D in the other. This was associated with a marked (probably spastic) miosis, paresis of the abducens, and some other symptoms indicative of brain irritation. I regarded the condition as a true spasm of accommodation. It is not unlikely, however, that it was an instance of the spurious accommodation, which Hess regards as so frequently in presbyopes. That is, the patient on account of her miosis was able to see objects at close range without really accommodating for them.

11. Cases of unequal accommodative power — not meaning by this cases in which the two eyes accommodated unequally when working together but cases in which the maximum power of one eye was persistently higher than that of its fellow when tested by itself, were not very uncommon.

12. Corrected myopes frequently showed a surprisingly high power of accommodation. Thus a patient of 21 with a myopia of 3 D had a range of 12 D, a patient of 23 with a myopia of 3.50 D a range of 14 D, and a patient of 25 with a myopia of 7 D a range of 11 D, and a patient of 18 with a myopia of 13 D a range of 12 D.

THE CLINICAL MEASUREMENT OF RELATIVE ACCOMMODATION.

BY DR. LUCIEN HOWE,

BUFFALO, N. Y.

In view of the indefinite manner in which the term relative accommodation is sometimes used, it is desirable, for the sake of clearness, to recall a few familiar facts. We know, of course, that relative accommodation is that amount of accommodation which it is possible for a pair of eyes to exert or to relax with relation to a given degree of convergence. For example, when an emmetrope looks at an object one-third of a meter distant he exerts normally with each eye three diopters of accommodation, and converges three meter angles. But if we place before each eye of that emmetrope a minus 1 diopter glass, he still converges, as before, three meter angles, but he then uses four diopters of accommodation. It will be remembered that this amount of extra accommodation we could call the positive part of the relative accommodation. On the other hand, if we place a minus 1 diopter glass before each eye, and he still looks at an object one-third of a meter distance he converges, it is true, three meter angles, but he accommodates only two diopters with each eye. This amount of accommodation, which is less than the amount of convergence, we call, of course, the negative part of the relative accommodation, and the positive with the negative gives the total range of the relative accommodation. Fig. 1. p′ pp″.

The importance of relative accommodation has long been known. Donders said, "*The accommodation can be maintained only for a distance at which in reference to the negative, the positive part of the relative accommodation is tolerably great.*" This dictum is of enormous importance, and has stood the test of half a century of every-day experience. Nearly all of our efforts in what we call "refraction work" are to increase properly the positive part of the relative accommodation.

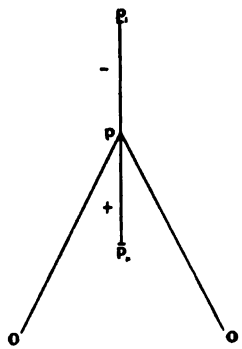

FIG. 1.

In the clinical measurements of relative accommodation there are two points to which our attention is naturally directed. These are:

First. The relative accommodation with parallel visual axes. In a certain sense it is not accurate to speak of relative accommodation with parallel visual axes, because there is no convergence. Moreover, an emmetrope can evidently have no negative part of the relative accommodation, for if we place before his eyes convex glasses, no matter how weak, he has no latent accommodation which he can relax, the focus falls in front of the retina, and the image is blurred. But we do know the very important fact that when an emmetrope in early life views a distant object — like test letters, for example — if we place before his eyes concave glasses of two, two and a half, or three diopters he will be able to make such an effort of accommodation as to "overcome" these glasses,— that is, to keep the focus on the retina. Now these concave glasses which are placed before his eyes under such circumstances represent a definite amount of accommodation, which for convenience at least we may designate as "the positive part of the relative accommodation with parallel visual axes." This is, for practical purposes, a measurement of the strength of the ciliary muscles when no convergence is made.

This positive part of the relative accommodation with parallel visual axes begins to decrease, however, after early life, and that decrease continues at a certain definite rate. After quite a careful search through the literature I could not find that this curve had been described, but by testing a considerable number of presbyopes I found that it could be represented by the curve here given.

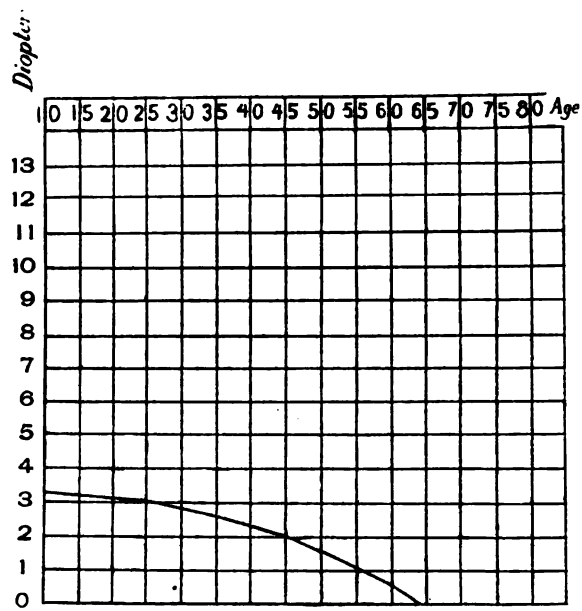

FIG. 2.

In a word, in order to measure clinically the relative accommodation with parallel visual axes, no apparatus is required, except the ordinary test frames so arranged as to properly center the trial glasses. Any ametropia which exists having been corrected, the strongest concave glasses which the patient can overcome represents practically the positive part of the relative accommodation. By comparing the results thus obtained with the curve already referred to, we know nearly enough for clinical purposes, how the relative accommodation with parallel axes compares with that of normal eyes.

The second question of importance in this connection is how to measure clinically the amount of relative accommodation at the near point. It would require too long a digression to refer to the details of measuring accurately the relative accommodation with any given degree of convergence. To do this with real exactness requires laboratory apparatus and a very considerable expenditure of time and patience. The method, or rather the different methods of doing this, have been described in my first volume on the muscles. I venture to refer to that be-

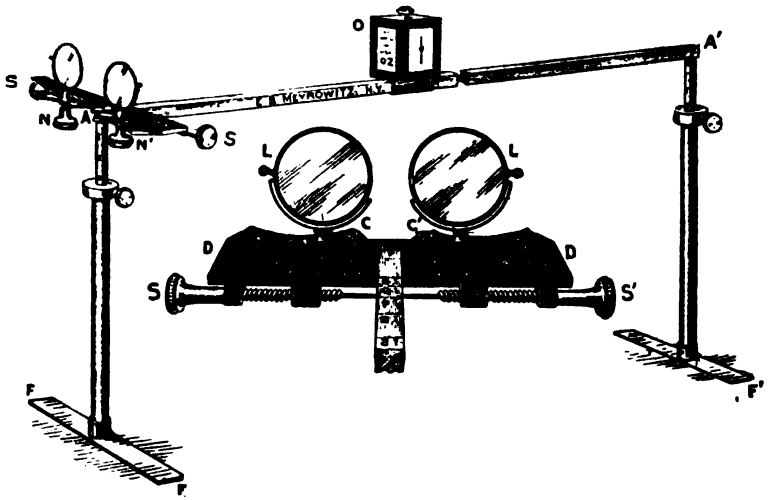

FIG. 3.

cause it is, as far as I can find, the only description of the method given, at least in English. In that connection, I described an apparatus for making these measurements. This is seen in Figure 3.

The principal object of this paper is to show that the same apparatus can be easily transformed into another, which is well adapted for the clinical measurement of the relative accommodation at the near point. For this purpose it is only necessary to unscrew the foot plate at either end of the instrument, to unscrew the distal half of the horizontal bar at its center, and then

to attach a handle beneath what has been described as the carrier of the instrument. As thus transformed, it is seen in Figure 4. This leaves a bar of fifty centimeters graduated in meter angles from a point which corresponds to the centers of the base line. The bar carries a traveler with test types which have been photographed down to such a size that each letter subtends accurately the angle of minimum vision for a given distance. The so-called carrier or cross-piece of the T has a screw at one side (s s′) by which the arcs which hold the test glasses can be made

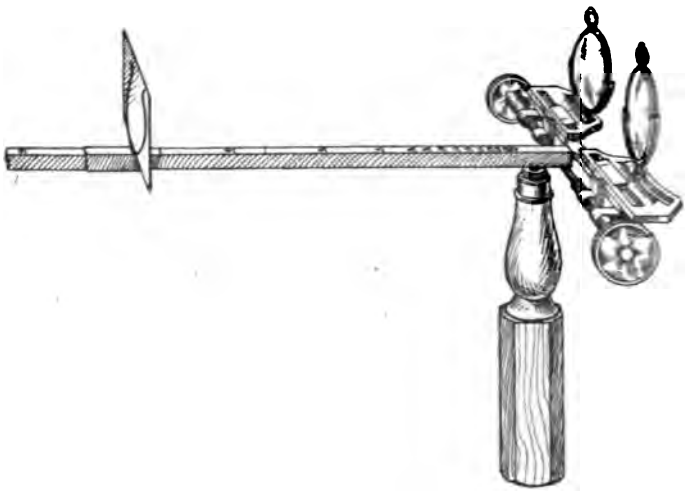

FIG. 4.

to approach or be separated from each other. Moreover, each of these arcs moves in a curved groove, the center of this curve corresponding to the center of motion of the globe, on that side.

In practice we first measure the base line of the individual by any one of the various well known methods. Let us suppose that this base line is found to be 62 millimeters. We then turn the screw at the side of the carrier so that the center of the test glasses measures 62 millimeters when the eyes are in the primary position.

Next, suppose we wish to measure the relative accommodation at one-third of a meter. The test letters are placed at the

distance of three meter angles. In order to have the center of the test glasses correspond with the axis of vision, we must know how many degrees each eye turns in, toward a point thirty-three and a third centimeters distant, when the base line measures sixty-two millimeters. In the volume referred to there is a calculated table, which gives meter angles of convergence in degrees and seconds, for base lines of different lengths from 55 to 65 millimeters. On turning to this table we find that when a person with a base line of 62 millimeters converges three meter angles he turns each eye in 5° 20″. Therefore we loosen the screw which allows the test glass to move in a horizontal arc, and turn that glass about five and one-half degrees inward. It seems at first a little complicated to be obliged to consult a table, but practically, as we measure the near point only at three or possibly at four meter angles of convergence, and as the length of the base lines vary comparatively little from each other, in reality it is only necessary ordinarily to turn each test glass inward about 5 to 6 degrees from the zero point, without the bother of referring to the table.

Any existing ametropia which the patient has having been corrected, the strongest concave glasses which can be overcome give approximately the positive part of the relative accommodation with that degree of convergence. In a similar manner the strongest convex glasses give approximately the negative part.

This approximation can be made exact if we take into account the distance at which the test glass is placed in front of the nodal point of the eye. That, however, requires some little calculation — a feature which is too bothersome for the haste of routine office work. We do know, however, that ordinarily, with a convergence of three meter angles, in order to make allowance for the distance of the test glass from the eye, we must subtract about 0.50 from the concave glasses, and subtract about 0.25 from the convex test glasses which can be overcome. With that slight change we know the range of the relative accommodation quite enough for all clinical purposes.

This gives us at least a rough measure of the action of the ciliary muscle — and only recently have we begun to appreciate that imbalance due to faulty accommodation is quite as frequent as that due to faulty action of the extraocular muscles.

As the importance of such measurements is apparently too often neglected, it seems worth while thus to call attention to this simple method of obtaining data, which, in some cases at least, prove of very decided value.

DISCUSSION.

DR. WALTER L. PYLE, Philadelphia: For ten years I have made careful observation in private patients past 35 years of age, to determine the range of accommodation in adult life; and I have been struck with the disagreement of my findings with the classic charts and tables that has been published and republished unchallenged in the text-books for a half-century. I am in full accord with the purpose of Dr. Duane's careful work, for with the progress of our modern knowledge of ciliary action and methods of testing refraction and accommodation, I believe the whole subject needs revision.

DR. F. H. VERHOEFF, Boston: Dr. Duane has rather apologized for his method as not being scientific, and says that it is probably less accurate than that of Scheiner. In Scheiner's method, for the results to be precise the pin holes must be some little distance apart. The refraction of the eye at two small points some distance from the principal axis is therefore determined, so that the aberration of the eye must enter largely into the result. On the other hand, in the method of Dr. Duane, the test is made under natural conditions and the result must be more accurate though seemingly less precise.

I think Dr. Duane's results are valuable in that they will tend to prevent us from using the old time method of asking the patient's age and then prescribing a certain glass without measuring the accommodation.

DR. J. A. LIPPINCOTT, Pittsburg: Soon after going to Pittsburg I was struck with the number of cases in which impairment of accommodation was delayed. A considerable proportion of people of 48 to 50 years of age required no reading glasses at

all. At 55 the amount of presbyopia was often only 1 to 1½ diopters; and at 60 a + 2 was frequently better than a stronger glass. Such cases were usually found among the sturdy race from the North of Ireland by which Western Pennsylvania was so largely settled. Very soon I began to question my patients presenting this characteristic in regard to the longevity of their forebears and as a practically invariable rule their parents, one or both, or their grandparents, had lived more or less beyond the allotted "three score and ten years," and it was not long before I could say to such patients "you come of a long-lived stock" with the assurance of receiving an affirmative reply. The question as to what constitutes vitality, the power to resist disease, in virtue of which one man will easily triumph over an acute pneumonia or a more chronic affection like tuberculosis or diabetes while another less happily endowed succumbs, is an interesting one. It would seem to be connected with a high degree of elasticity of important tissues. Judging from my experience the old saying "a man is as old as his arteries" might be supplemented by the statement that a man is as old as his crystalline lenses. This idea might be utilized by insurance societies; and the prognosis in a case of injury or disease in a person past middle life might to a certain extent be influenced by the degree of presbyopia. Dr. Duane's modification of the presbyopia curve given by Donders accords very well with the result of such observations as I have made.

Dr. Alexander Duane: I am glad Dr. Howe brought up the question of subnormal accommodation. A number of such cases were included on the chart, but were not included in making the curve. These are conditions which often give very troublesome symptoms. There were also some of the cases he speaks of of excessive accommodation.

As to the matter of Scheiner's experiment I agree with Dr. Verhoeff that it is not a scientific test unless applied with great care.

Of course, the results shown here are only tentative, because to make a complete chart would require double the number of cases.

Dr. Lucien Howe, Buffalo, N. Y.: In regard to Dr. Duane's paper it should be observed that when we measure the range of

accommodation of normal eyes and plot the results, we obtain practically the same curves as were described long ago by Donders. On the other hand, when we measure the ranges of accommodation in pathological cases like those of Dr. Duane's and plot the results, we find variations from those curves. Such variations are very instructive, and by them I think we will ultimately discover some order in the data which now appear so chaotic, concerning the ranges of accommodation. Our attention has been so much occupied of late years with heterophoria — in other words, with anomalies of the extraocular muscles — that I think we have neglected the anomalies of accommodation.

DR. ALEXANDER DUANE: I must take exception to the statement of Dr. Howe that these were pathological cases. They are not. They were ordinary refraction cases; patients in full vigor; they were not pathological cases any more than the cases that Donders had to avail himself of.

SOME PRACTICAL POINTS IN THE USE OF PRISMS.

BY B. L. MILLIKIN, M.D.,
CLEVELAND, OHIO.

On the question of the use of prisms for the examination of muscular imbalance, paresis or paralysis, I do not care to enter. What I have to say concerns the use of such glasses as a therapeutic measure. Prisms are used as a rule in one of three ways: (a) a means of muscular exercise for weak muscles; (b) for more or less temporary use in cases of paresis; (c) worn constantly as a permanent means of relief for muscular insufficiencies.

Prior to the discussion of the special uses of prisms, I should like to say that for twenty-five years I have used prisms in various ways for therapeutic purposes, and what I have to say is based on this experience. In cases of errors of refraction, with or without asthenopia, I am in the habit of examining the muscular condition at a distance of twenty feet, and also for the reading distance of fifteen inches, and keeping full notes on the

results. Either the Maddox rod or the Graefe prism test is used as a rule, unless there is some special reason in a given case for doing otherwise. It goes without saying that all cases of errors of refraction are carefully corrected, under a mydriatic, almost without exception under forty-five years of age, as a necessary foundation and starting point for the use of prisms. A good many cases, however, have been met with where no error of refraction has been found. It seems to me essential that the refraction must first be thoroughly determined, and suitable correction ordered. I am also, as a rule, in the habit of testing the muscle balance in the preliminary examination; with the eye under a mydriatic, with and without the correction, and later after recovery from the mydriatic if possible, and ordering or not prism combinations, depending on the result. It is an interesting fact that many cases of marked asthenopia, with a considerable amount of muscular imbalance, are entirely relieved without prisms, whether the error of refraction is one of considerable or slight degree.

1st. The use of prisms for exercising weak muscles. Prisms may be used as a means of exercise in either esophoria, exophoria, or hyperphoria. In my judgment, it matters little what method is used for exercising the weak muscles, except that the muscle is required to make a decided effort, on the same principle that a dumb-bell exercise for a weak arm muscle may prove advantageous. I have never been able to well satisfy myself, that in cases of esophoria, prism exercises were of any marked advantage, my feeling being that whatever relief has come in these cases has been from corrected errors of refraction, sometimes after the correction has been worn for a long time, six months or a year, or from the better general nutrition and improved nerve tone of the individual. I am equally skeptical in the matter of the benefits to be derived from prism exercise in cases of hyperphoria, my feeling being that this form of therapeusis is of little avail in those cases. In the matter of cases of exophoria, the convergent inability, on the other hand, I am thoroughly satisfied

that great advantage is derived from muscular exercise in whatever way administered. Generally the method is used of having the patient look at a small flame twenty feet distant, placing before the eye a strong prism with the base out, and inducing fusion of the images. The patient under this effort will be able, after a little practice, to overcome prisms of 35° to 50° base out, rapidly relieving asthenopia in certain cases. Two such sittings a week for ten minutes, followed after a short time by once a week or less often, frequently give great relief. There is a form, however, of exophoria, which in my experience has usually proved troublesome, many cases being so obstinate that I have come to look upon these as cases demanding permanent moderate use of the eyes for near work. These are cases who may or may not have insufficiency at a distance, but who show at the near point of fifteen inches, a degree of exophoria varying from 2° up to 8° more than at the distance. With the error of refraction corrected, this relation does not vary, and no amount of exercise permanently relieves the asthenopia frequently found in such cases. My judgment has come to be that these patients are permanently handicapped, and all such should abstain from entering upon a life work requiring hard, continuous close work. Nor does the continuous wearing of prisms give definite relief in this class of cases.

2d. The use of prisms worn as a temporary relief in case of paresis or paralysis. Not infrequently great advantage is derived from the use of prisms worn temporarily to relieve the confusion and discomfort of double images, in cases of paralysis more or less complete. Patients will frequently bear very strong prisms, sufficient to enable them to fuse images, and by gradually diminishing the strength of the prisms, as the paresis improves, great benefit may be afforded. In complete paralysis, prisms are of course of little avail. The following case is a good illustration of what may be accomplished:

CASE I. M. H. T., aet. 40, was examined on January 13, 1908, giving the following history: Had been nearsighted since

a child, and had worn glasses since fifteen years of age. A few days previous to his visit he complained of much confusion, discomfort, photophobia, but not distinct doubling of images. Without a mydriatic his refraction was as follows:

O. D. — 3.50 Ds V = 6/6 — 2.
O. S. — 4.00 Ds (.) — 0.50 D. cy. ax. 180° V = 6/6 — 2.

Muscular tests showed an esophoria of 20°, but with ability to move the eyes pretty freely in all directions, while alternately uncovering, the eye moved out distinctly. His tendency was to close one eye constantly in order to relieve the confusion, and for this he was wearing a patch over one eye, and otherwise suffered much discomfort. There was a specific infection at twenty-four years of age. He had an ulcer of the leg three years previously, but no other symptoms of late years. The following glasses were ordered to be worn constantly:

O. D. — 3.50 Ds (.) prism 10° base out.
O. S. — 4.00 Ds (.) 0.50 D. cy. ax. 180° (.) prism 10° base out.

Iodide of potash in increasing doses was ordered. Ten days later he reported having worn the glasses for all purposes with great comfort, and there was a distinct gain in the muscular condition.

February 7, 1908. His esophoria was found to be only 10°. Glasses with no prism on the left eye were given him, leaving the correction 10° in the right eye. On February 20th he had 8° esophoria, but with the refraction correction things were single, and there was no confusion. Therefore the right glass was changed to the myopic spherical and he had no prism left in the glasses. Since then he has simply worn his refraction correction, and has gone on perfectly with no disturbance. There is no question that the prisms in this case were of great advantage, enabling the man to follow an active business avocation with comfort for a period of some two or three months, which otherwise might have been very depressing.

3d. The use of prisms in cases of heterophoria. Of all the forms of heterophoria, cases with esophoria suffer the least from muscular asthenopia. In fact many patients with a considerable degree, do not seem to be conscious of any trouble. It is obvious why, as the converging effort is without strain. However, not infrequently the partial correction of the esophoria gives great comfort, especially when the use of the corrected refraction proves not to be satisfactory.

Patients will wear from 1° prism base out, up to 10° or more, often with distinct advantage. Muscular asthenopia is by far more frequent, and severe in cases of exophoria, and correspondingly the relief afforded by prisms, worn base in, is very much more marked. Rarely do we give a glass with the full amount of the exophoria corrected, for constant use, as not infrequently half, or even less of the full amount, will afford quite sufficient relief, especially if the use is associated with some form of exercise of the weak muscle. It may be advisable at times to increase the strength of the prism in such cases, and occasionally it may be advisable to prescribe the full muscular correction, though this is rare in my experience. I should not hesitate to prescribe prisms of 8°, 10° or even 15° base in, should a case seem to require it, dividing the prism between the two eyes. What has been said of cases of exophoria apply with equal force to those of hyperphoria, wherein we all know that even a slight degree produces often great asthenopia, reflex headaches of various kinds, digestive disturbance, neurasthenia, etc. We have all had frequent experiences of the kind. As in refraction errors, there seems to be no definite relation between the degree of the error and the amount of discomfort produced. Not infrequently we have found that 1/4° or 1/2° of vertical muscular insufficiency has been the cause of great discomfort. On the other hand, patients will not infrequently bear very strong prisms with the base up or down, with great satisfaction; often as much as 10° or even more. In these cases too there is often a large amount of latent insufficiency, which only shows up after wear-

ing weaker prism than the full correction. The following case will illustrate several points connected with this subject:

CASE 2. Mrs. J. B.., aet. 52, was referred to me by Dr. Stearns, and first examined on February 23, 1905. Her history was one of neurasthenia, with headaches all her life. Her vision was perfectly normal in both eyes, and the eye grounds good. She was wearing + 2.75 Ds (.) prism 5° base in each eye, which had not relieved her symptoms. Examination indicated emmetropia and presbyopia of 2.00 Ds. At twenty feet she had an exophoria of 10°, and a manifest right hyperphoria of 5°. The following glasses were prescribed:

O. D. prism 4° base in.
O. S. prism 3° base down.

to be worn for constant use. For reading, the same prisms combined with + 2.00 Ds, each eye, were given. The glasses were worn with much comfort up to November, 1905, when she complained somewhat of headache at times, though she had been able to read an hour or more a day. Examination then showed an exophoria of 10°, and a right hyperphoria of 6°. The left glass was changed to prism 5° base down before left eye. This gave additional relief. In November, 1906, she reported that she was quite nervous, with some headache, though she had no "break-down," and was able to do some reading. Examination at this time showed exophoria of 10° with right hyperphoria of 10°. The following glasses were then ordered:

O. D. prism 8° base in.
O. S. prism 8° base down.

I examined her again on April 13, 1908, and found her insufficiency about the same. She had worn the glasses with much comfort, and she has not had a period of as good general health for a number of years, though she has done a good deal of reading, sewing, etc., during the time.

We not infrequently meet with another class of cases, where prisms worn constantly are of value, viz.: the cases of multiple

muscular imbalance, hyperexophoria, and hyperesophoria. Usually prisms are used in these cases with the base in or out before one eye, and up or down before the other. They often give very satisfactory results as thus worn, though in the stronger prisms the weight of the glasses may be an objection. Anything which would simplify the glasses, required in such cases, is a desirable thing, and anything which would enable us to use a less strong prism is surely of value. Some years ago I reported using prisms with the base at other than the vertical or horizontal position. During the past few years I have also been led to try this practice in a much more extensive way, and with much satisfaction. I have come to feel that one can prescribe prisms with the base or apex at any axis, and the patient will bear them with no greater annoyance than in the vertical or horizontal position. Besides, in this class of cases, the prism may often thus be confined to a single glass, and the strength of the glass required to correct the double imbalance is decidedly less than the sum of the two corrections, or in some cases less than that of either. As a rule, one's object is not to give the full strength of the prism correcting the imbalance, but this is modified by experience, so that one will order one-third, one-half, or more of the full correction in any given case. Generally one would prescribe a larger proportion of the full correction in a case of exophoria than in esophoria, and a larger proportion of a hyperphoria than an exophoria. One is usually justified, in fact, in giving close to the full correction in hyperphoria; so one takes into consideration these facts in ordering a prism at an angle off from the vertical or horizontal position. Generally the vertical displacement is less than the horizontal, so that a prism correcting an exophoria of 3° or more, would need to have its base only a little above or below its horizontal axis to correct a very annoying hyperphoria of 1/2°, 1° or even more. In determining practically the prism we shall prescribe, we may arrive at a conclusion by determining first the full amount of the exophoria or esophoria, and the hyperphoria. Suppose the con-

dition is one of exophoria of say 5°, and there is a hyperphoria of 2°, with a Maddox rod placed before the eye, the 5° prism, base in, would be rotated, base up or down until the vertical position of the two images nearly coincided. This would of course diminish the correction for the exophoria, but would correct largely the hyperphoria, and a sufficient amount of the exophoria if not all of it. The angle at which the axis of the prism rests in the trial frame, would indicate the position of the base or apex as desired. As a result, however, of experience we have very often found that a prism of considerably less strength than would be required for either the vertical or the horizontal insufficiencies, much less the combination of these two insufficiencies, when placed with its base at a position lying between the vertical and horizontal meridians, will correct a total insufficiency. To illustrate, if there is an exophoria of 5° and a hyperphoria of 5°, we may find that a prism of 3°, placed at some angle between the vertical and horizontal axis, will cause the images to be superimposed. In cases of a considerable degree of insufficiency of this sort, we may arrive at a practical conclusion of the glass to be prescribed, by placing before one eye a red glass, which is often sufficient to enable the patient to see two images, as of a candle flame, vertically, laterally, or in a diagonal position to one another. It is then a simple matter to place before one eye such a prism glass at such an angle as will cause the two images to fuse, noting the position of the base or apex on the trial frame. A little experience will lead one to judge as to what proportion of the full correcting prism it will be wise to prescribe for continuous use by the patient. As illustrating several points indicated above, let me briefly give the history of two or three cases.

CASE 3. W. H. W., aet. 26, was referred to me by Dr. J. P. Sawyer on account of very prolonged and disturbing stomach trouble, lasting over a period of some four years. There was no history of trouble with the head or eyes. The man was a graduate of Case School, and had worked for a year or more at

drafting before his attack of stomach disturbance came on. On February 4, 1907, examination showed the vision of both eyes normal, the eye grounds normal, and refraction under a mydriatic showed a hyperopic astigmatism of

O. D. plus 0.50 Ds (.) plus 0.25 D. cy. ax. 90°.
O. S. plus 0.50 Ds with no astigmatism

Prior to the mydriatic, at twenty feet there was an exophoria of 10°, and a right hyperphoria of 3°; while at fifteen inches there was an exophoria of 8°. The following glasses were ordered on February 6, 1907:

O. D. plus 0.25 Ds (.) plus 0.25 D. cy. ax. 90° (.) prism 4° base in.
O. S. plus 0.25 Ds (.) 0.25 D. cy. ax. 90° (.) prism 1½° base down.

These glasses were worn with considerable benefit during the balance of the year. On January 9, 1908, examination indicated an exophoria of 10°, and a right hyperphoria of 3°-4°. By means of the Maddox rod, placed in the trial frame a 5° prism base in, in the opposite side, it was found that when the prism was rotated to a point with the apex 25°, the images were nearly on the same horifiontal plane. Based upon this examination the following glasses were ordered:

O. D. plus 0.25 Ds (.) plus 0.25 D. cy. ax. 90° (.) prism 5° base in.
O. S. plus 0.25 Ds (.) plus 0.25 D. cy. ax. 90° (.) prism 5° apex 25°.

These glasses have been worn continuously since that time, and with very decided comfort, and with a gradual improvement in his general condition.

CASE 4. L. C. H., aet. at the present time about 63; was first examined by me on August 9, 1893. His history was some trouble for two or three years in doing close work, with much

discomfort in the back of the head at the base of the brain; quite severe at times.

O. D. V = 6/24.
O. S. V = 6/9?.

Without a mydriatic his refraction was determined as follows:

O. D. — 1.75 Ds (.) plus 2.50 D. cy. ax. 90° V = 6/6.
O. S. — 1.50 D. cy. ax. 170° V = 6/6.

There was also a presbyopia of 1 Ds present. The eye grounds were in good condition. The above glasses were prescribed and worn until August 18, 1896, when an increased glass for presbyopia was prescribed. He was again seen on the 18th of April, 1901, when a history of developing locomotor ataxia was given. There was no evidence of disease of the optic nerves, but there was some increase in his presbyopia, plus 2.50 Ds being given with the cylinder correction. On July 10, 1901, he reported that for six weeks he had noticed seeing things double, and especially in reading close work, one image being above the other. A careful examination at this time indicated the following refraction and muscular condition:

O. D. — 1 Ds (.) plus 2.50 D. cy. ax. 110°,
O. S. — 0.25 Ds (.) plus 1 D. cy. ax. 90°.

The muscular condition showed at twenty feet 2° exophoria, and 4° left hyperphoria, but no paralysis so far as could be determined. Glasses were given him for his presbyopia, including a prism of 3° base up before the left eye. These glasses were worn for all close work until July 7, 1908, when he again reported to me seeing things double at times, especially when tired or directly after night reading. His case was carefully gone over at this time, with the following result of refraction:

O. D. — 0.50 Ds (.) plus 1.75 D. cy. ax. 110° V = 6/6.
O. S. plus 0.50 Ds (.) plus 0.50 D. cy. ax. 90° V = 6/6.

With and without the glasses, at twenty feet, there were 2° of exophoria, and 8° left hyperphoria. When a red glass was

placed before one eye, a gas jet twenty feet distant was seen to be double, the two images being considerably separated. With and without the corrected refraction, it required a prism of 6-8° base up, to enable him to fuse the two images. With the astigmatic correction on, it was found that with a prism of 4° base down before the right eye, and 4° base at 100° before the left, the images fused, his vision was sharpened, and he seemed in every way more comfortable. The following glasses were therefore ordered for him:

O. D. — 0.50 Ds (.) plus 1.75 D. cy. ax. 110° (.) prism 4° base down.

O. S. plus 0.50 Ds (.) plus 0.50 D. cy. ax. 90° (.) prism 4° base 100°.

To these were added plus 2.25 Ds scales or bifocals, to be worn constantly, the latter for a sixteen-inch reading distance.

CASE 5. On July 2, 1908, I examined Miss M. E. H., aet. 52, who gave the history of poor eyes all her life, with headaches in the back of the head and around one or the other eye. Examination without a mydriatic gave the following refraction:

O. D.— 5 Ds (.)— 7 D. cy. ax. 180° V= 6/12 plus.

O. S.— 7 Ds (.)— 6 D. cy. ax. 10° V= 6/12.

Her vision without any glass was 1/60 in each eye. Her eye grounds were fairly good considering the high myopia. The muscular test at twenty feet gave an exophoria of 2°, with a right hyperphoria of 20°. With the correction before her eyes, and a red glass placed before one eye, there was a vertical displacement of the two images of a considerable amount. It was found, however, that with a prism of 6°, placed with the base down before the left eye, she was able to fuse the two images fairly well. With this fact in mind, the following glasses were prescribed:

O. D.— 5 Ds (.)— 7 D. cy. ax. 180° (.) prism 3° base up.

O. S.— 7 Ds (.)— 6 D. cy. ax. 10° (.) prism 3° base down.

To which was added a plus 3 Ds for bifocals, to relieve her presbyopia, etc., for near work.

CASE 6. C. T. H., aet. 19, was examined March 31, 1908. O. D. V = 6/60. O. S. V = 2/60. Has been nearsighted since childhood, and had worn glasses since four or five years of age. Formerly had much headache; less at present time; was wearing the following glasses:

O. D. — 3 Ds (.) — 2.25 D. cy. ax. 10° (.) prism 2° base up.

O. S. — 4 Ds (.) — 2.25 D. cy. ax. 180° (.) prism 1° base out.

With those glasses there was an esophoria of 5°, and a right hyperphoria of 4°. The eye grounds were in fairly good condition. On July 7, 1908, under atropine, used for several days, the following refraction was determined:

O. D. — 2.75 Ds (.) — 3.50 D. cy. ax. 20° V = 6/9 plus 1.

O. S. — 3.50 Ds (.) — 2.75 D. cy. ax. 170° V = 6/9 plus 1.

Without the glasses, at twenty feet there was an esophoria of 8°, and a right hyperphoria of 5°; while with the glasses there was an esophoria of 6°, and a right hyperphoria of 8°. With the glasses and a red glass placed before one eye, there were two distinct images, some distance apart, which fused readily with a 5° prism with the apex 130°. Fusion took place also with a 4° prism in the same position, but not with a glass of less strength. The following glasses were therefore ordered:

O. D. — 2.75 Ds (.) — 3.50 D. cy. ax. 20°

O. S. — 3.50 Ds (.) — 2.75 D. cy. ax. 170° (.) prism 5° apex 130°.

CASE 7. C. S., aet. 13, was examined on October 5, 1907, giving the following history. Since childhood his eyes have been quite sensitive, but has not had headaches, but a peculiar nervous condition which prevented his getting to sleep in the evening, and compelling him to get up several times in the early part

of the night to readjust himself before going to sleep. Examination showed V = 6/6 in both the eyes, with no disturbance of the eye grounds. At twenty feet there was an exophoria of 6°, and a right hyperphoria of 4°. On July 9, 1908, under atropine, there was a hypermetropia of plus 1 Ds in each eye, which gave normal vision. In addition, there was an exophoria of 6°, and a right hyperphoria of 5°. It was found in this case that a prism of 5° apex 30°, before the left eye, practically corrected both insufficiencies. It was also found, that a red glass placed before the eye, did not prevent the fusion of images. In view, however, of the nervous disturbance and the muscular imbalance, the following glasses were ordered:

O. D. plus 0.75 Ds (.) prism 2° base 30°.

O. D. plus 0.75 Ds (.) prism 3° apex 30°.

These glasses have been ordered for constant use.

The above cases indicate, in a fairly broad way, the varieties of muscular imbalance in which we have found prisms of very great advantage. I believe no one can tell, prior to an actual trial, how strong a prism any given case will require to relieve the symptoms present. My experience has taught me that the unexpected often happens, and that a patient would bear a very much stronger prism glass, frequently, than one might be disposed to think. One cannot give an absolute limit to the strength of the prism, which often will be accepted by a patient in whatever position the base may be placed. I do not hesitate, however, to put on as strong prisms as can be practically manufactured for spectacles, with the base either in or out, up or down, or at any axis lying between these different meridians. I believe a patient will bear a prism at any angle between the vertical and horizontal meridians, as well as at either of these positions, and with as gratifying results in so far as relief from asthenopic symptoms are concerned. The advantage of placing a prism with the base at other than the vertical or horizontal meridian, is the weaker glasses often needed, the confining of the prism usually to one side, and the consequent less cosmetic disturbance.

DISCUSSION.

DR. ALEXANDER DUANE, New York: As to the use of prisms as exercise I agree with Dr. Millikin that we get little result except in exophoria. He speaks of not having had much result when exophoria for near was marked as compared with exophoria for distance. I have not found this so. We must make a distinction between these cases; where exophoria is marked for distance and slight for near, the exercise with prisms should be made with test object at distance, and little attention paid to exercise for the near point; on the contrary, when there is little or no exophoria for distance and marked exophoria for near, and these are the troublesome cases, our main attempt should be to make them converge when looking at a comparatively near point. The prism exercise should be made with the test object at reading distance and not at twenty feet.

As regards prisms for constant wear, I am skeptical as to the advantages except for hyperphoria. It has been my experience in exophoria and esophoria that they may be helpful for a time, but exaggerate the difficulty if their use is kept up.

DR. C. H. WILLIAMS, Boston: I think that a long experience with the use of prisms makes one more and more skeptical as to the results to be obtained, and there is this disadvantage; it is like giving a person a crutch — they use them, and then you have to increase them, and so it goes on from bad to worse. For small deviations in the vertical meridian correcting prisms are often a relief, but for deviations in the horizontal meridian they are less serviceable.

As regards the objection to the weight, we can get some advantage by using the new Jena glass. The ordinary index of refraction is about 1.5, but they are now making a glass which has an index of 1.9, so that you can have a prism of very much less weight, giving the same deviation as a prism of ordinary glass of greater thickness, you can also use the same glass in high degrees of myopia and hyperopia. I have found it of distinct advantage in myopes. The disadvantage is that the glass is rather soft, being a dense lead glass, and scratches easily.

DR. SAMUEL THEOBALD, Baltimore: There are several points in Dr. Millikin's paper that I want to speak of. One is the fact that he found cases of hyperphoria of one-quarter or one-half

a degree that gave trouble. In every case of refraction that comes into my hands, I test carefully the muscle balance, and if I find only a half degree or less of hyperphoria I pay absolutely no attention to it, and I have never in a single instance had reason to believe that I had made a mistake in doing so. The other point is as to the cases spoken of being particularly troublesome where there is a *difference* between the muscle balance for distance and near vision. If there is *not* a difference of at least two degrees, and usually three degrees, I think there is something wrong because of this fact. If we have normal muscle balance for distance we ought to have an exophoria for near of two or three degrees.

Another point is the very strong prisms he seems disposed to use rather than to tenotomize. I have had considerable experience in tenotomies, and I think if one first goes carefully into the refraction, and, after taking this into account, still finds that he has a considerable amount of muscle fault, especially in distant vision, he will obtain much better results from a tenotomy than from giving prisms of 7 or 9 degrees. I would not hesitate if I had a case requiring 6° prisms for distance to tenotomize. The advantages are manifest. On the other hand, in muscle faults, less pronounced in degrees, I have gotten extremely satisfactory results from prescribing prisms for constant use, and I have not found, as Dr. Williams has, that under such circumstances the muscle defect increases, and the prisms have to be made stronger and stronger.

Dr. B. L. Millikin: With reference to the point of tenotomy in contradistinction to wearing prisms, that was not the question I intended to discuss. Of course, there are many cases where tenotomy is a matter of importance to the patient, and where they prefer to wear any sort of glass rather than submit to operation, and these are cases where high degree prisms are of value. I have also found, in a great many cases, prisms of 1/4 or 1/2 degree have made a great difference in the comfort of the patient in cases where correction of the refractive error has been tried without comfort.

With reference to muscle imbalance for distant and near points, in my experience, when the difference has been of considerable degree, 3° to 8°, very often the condition has proved one of much disturbance in the ability of the patient to do close work.

STRABISMUS FROM THE OPERATIVE STANDPOINT.

BY DR. P. A. CALLAN,
NEW YORK CITY.

Strabismus from the operative standpoint has been well threshed out during the past seventy years. Still ophthalmologists are by no means in accord either as to the method of operating or how soon to interfere after its onset. All are in accord as to correcting the refractive error and orthoptic training. However, there is no rule how long this is to be kept up before surgical interference.

In the case of squinting children it is the exception rather than the rule that they are brought to us at the beginning of the strabismus. Months and often years elapse before the surgeon is consulted as to what will remedy the defect. If these cases could be seen at the beginning, correcting the refraction and the other non-operative methods would give much better results. In the case of very young children it is a difficult problem to put on glasses and have them worn with safety. However, the majority of such patients begin to squint between the third and fourth year.

Many surgeons prefer to await the growth of the child, knowing that some cases of strabismus are cured spontaneously. This is quite true, but it is always at the expense of an amblyopic eye. At the same time we see patients with one eye amblyopic that never did squint. There is no fixed period for operating after all other means have proved unsatisfactory. Various periods from five years of age to fourteen have been advocated as proper and likely to give most satisfaction. In this connection, I recall the advice of Donder's to a small class of students in Utrecht, given many years ago. He said in the case of girls with strabismus don't put on glasses, but operate when they are old enough to wish for and need the cosmetic effects. The wearing of glasses apparently lessened their matrimonial chances.

After all is not the cosmetic effect the desideratum? Parents with squinting children and adults come to us mainly for the blemish which they desire to have corrected. As to binocular vision they know but little and care less, provided the squinting eye is straightened; all other things are of little consequence. In how many of our strabotics, even after operation, do we get fusion, — where binocular vision is complete. If the operation has been deferred for years, we may get binocular fixation in a large percentage, but not perfect fusion. In not a few of my cases with the most perfect cosmetic result after operating it is impossible to create double image except under a cycoplegic. There was perfect binocular fixation, but one eye continued to do the work.

I believe that we defer operating too long, so long that the fusion sense is lost and am, therefore, in favor of operating early; it being understood that the usual training and glasses have been conscientiously used.

All operations on the ocular muscle are classified under two heads. Those that weaken the contracted muscle fall under the first category, viz., the tenotomies; and, under the second, those that tend to increase the power of the weak or stretched muscles. These comprise advancement of a muscle or tenons capsule, lapping, folding and resection.

It is a safe assertion that of all operations for the relief of strabismus fully eighty per cent. are tenotomies. A tenotomy is easy to perform, not followed by much reaction and incommodes the patient but little. Besides it has the sanction of the fathers of modern ophthalmology. To my mind it is time to break away from tradition and not to do a tenotomy unless other means fail. This should be the rule during the growing period. To this there is one exception — a tenotomy is justifiable in cases of hyperphorias. A tenotomy will frequently give good temporary results in strabismus. However, the ultimate results are not seldom unsatisfactory. During the growing period the muscular inervation is at its strongest. The child accommodates and converges

unduly, objects are held too close to the eye. This strain is gradually relaxed with growth and this is particularly true of young strabotics. So a tenotomy in a young subject not infrequently results in an over effect.

As a result of a tenotomy we obtain a certain amount of protrusion of the globe. In some cases this amounts to positive disfigurement. If an internus is cut the caruncle sinks. Further, the motility of the muscle is permanently impaired. The cut tendon retracts in proportion to the extent of the tenotomy and it reunites chiefly with tenons capsule and only in part to the sclera by means of a fibrous cellular band.

Guerin soon after Dieffenbachs' myotomy advocated advancements instead of tenotomies.

In 1874 the late Dr. I. F. Noyes read a short paper at the annual meeting of this society, giving in detail the lapping operation. This consisted of severing the tendon from the muscle, and resecting some of the muscle, if necessary, thus lapping the cut ends, and sewing them firmly together. In 1875, Vievsse improved on Noyes' operation by leaving only 1 mm. of the tendon attached and cutting out as much as he thought necessary, then uniting by suture the shortened muscles to the original insertion. In 1876 Driver advocated a similar operation. Müller and Schweigger in 1893-4 made resection, but first performed a tenotomy on the contracted muscle. Dr. Reese of the New York Eye and Ear Infirmary has done a large number of resections — generally combined with a tenotomy at the same time, provided that the cosmetic effect is not sufficient.

Dr. I. F. Noyes was the first to advocate the removal of a piece of the muscle and used the tendinous attachment as an anchorage.

The advantages of a resection over an advancement are as follows: The union of the sutured muscle to the stump is firm and unyielding. There is no danger of an oblique union of the cut surfaces, causing hyperphoria. It is easier of accurate measurement. There is less reaction, and after the lapse of a

month or six weeks, there is little, if any, trace of the operation — no raised ridge to mar the effect.

In measuring the amount of lateral muscle to be removed 1 mm., linear measure, is equal to about 5 degrees angular. This holds good for the interni, but not for the externi — 4 degrees would be the maximum in estimating the effect on the externus. In case a tenotomy of an internus is done immediately after a resection on an externus, the effect is in proportion to the extent of the freeing of the tendon from tenons capsule. When a certain amount of atrophy of a muscle with loss of its elasticity and power to contract has ensued the effect is not so great. I have removed as much as 12 mm. from an external rectus in order to correct a convergence of 35 degrees.

If the average length of an internus is 40 mm. and that of an externus 50 mm., removing a quarter of the muscle is not too much. Motais has pointed out that the contraction of a rectus necessary for the maximum movement of an eye is about one-half of its length. Striped muscles have a maximum shortening equal to half the length during extreme contraction.

OPERATIONS.

I find the following form of resection easy to do and quite satisfactory. A vertical incision 20 mm. long and 8 mm. from cornea, having the tendon for a center, is made through the conjunctiva. Free the conjunctiva over the field of operation. Make an opening through capsule above and below — insert strabismus hook under tendon, then free muscle to the full extent of resection. When muscle is entirely freed, insert a second hook which the assistant holds. The hooks are gently raised, and one of the two needles attached to thread is pushed under and through the lower third of the muscle and conjunctiva beyond the second hook. Then pass second needle through upper third of muscle including conjunctiva.

Two smaller sutures may be used, each with a fine needle one above and below including conjunctiva and muscle back of

the chief suture. These serve to reunite the conjunctiva better.

The muscle can now be cut 2 mm. anterior to posterior suture. Then cut off tendon, leaving about 1 mm. of a stump. Then pass each of the two needles of thread through episcleral tissue under the tendinous stump and conjunctiva. The single sutures are passed through episcleral tissue and conjunctiva 5 mm. above and 5 mm. below the other sutures. Then draw parts together and tie.

This is practically Dr. Reese's method except that he places a special clamp forceps under the tissue and then cuts it free, and sutures the muscle after freeing it from tenons capsule. It appears to me more accurate to measure off in situ the muscle to be resected and then insert sutures.

Schweigger used cat gut for this operation and cut off the muscle close to the sutures. As the cat gut is buried in the tissues it means an extra amount of suturing to unite the conjunctiva; at least some muscle should be left in advance; otherwise they are liable to slip.

During the growing period of youthful strabotics avoid doing a tenotomy. Operate, however, after six month's use of glasses and orthoptic training show no results.

If the deviation exceeds 30 degrees operate on both eyes with an interval of a year between the two operations, but no tenotomy.

Under 30 degrees confine the operation to the stretched muscles of the defective eye and try for full effect, not under effect.

In the case of adults, where immediate cosmetic effect is only desired, resect the weak muscle and do a slight tenotomy on contracted muscle of same eye at one sitting. Avoid too free dissection of tendon from its capsule. Try for a slight under effect.

The resection should secure the major part of the effect and the tenotomy the minimum. Better still to divide the effect between both eyes, avoiding a tenotomy, if possible.

Granting that in many cases of very high degree of strabismus resection of both eyes may not quite accomplish the desired

cosmetic effect, the major part should be due to the resection and only a subordinate role to a slight tenotomy.

DISCUSSION.

Dr. W. F. Mittendorf, New York: My experience is that in divergent squint nothing but advancement of the muscle will give the best results. In convergent squint, however, I have had gratifying results with the other method. I usually perform tenotomies of both internal recti at the same time, and in bad cases resort to the stretching of the muscles previously to dividing them according to Panas. Deformity is avoided and the eyes look alike. The main point is in applying the suture; you have to put the suture in such a way as to avoid a slipping back of the muscle and to regulate the effect by means of the suture. I have been much pleased with the result in divergent squint in making advancement of the capsule of Tenon.

Dr. David Webster, New York: I have been very favorably impressed with Dr. Callan's paper on this subject. All of us who have practiced ophthalmology a long time have seen many failures from the old operation of tenotomy for the correction of convergent squint. In the first place a certain proportion of cases fail to get sufficient correction and the eyes still turn in. I have seen cases that have been operated on five or six times. One of my colleagues had a case operated on eight times. I have seen a good many cases in the course of the last thirty-five years that turned out after the operation. Some turn out shortly after the operation; some, years afterwards. You never know when an eye is going to have divergent squint after tenotomy.

For some years I, in common with others at the Manhattan Eye and Ear Hospital, have been doing a modification of Landolt's operation, advancement of both interni, which has its defects and advantages. I have seen one eye lost by panophthalmitis after that operation. I have seen another eye that was almost lost. I have seen three or four cases in which an ulcer of the cornea developed at the corneal margin. On one or two

occasions I have seen the operator's needle enter the anterior chamber so anxious was he to get a good hold with the suture. It seems to me that Dr. Callan's operation, while more complicated than the old tenotomy, is much simpler than Landolt's operation and avoids the danger to the cornea and if done antiseptically I do not see why any bad results should follow.

DR. W. B. JOHNSON, Patterson: I think Dr. Callan quite correct when he says delay in these cases is dangerous. If anything is to be done it should be done early. I have made it a practice to correct with glasses as early as possible such cases of squint as appear and following that in a reasonable period of time to resort to advancement or tenotomy. While I realize that in many cases the results of tenotomy are not perfect and that it is not uncommon afterwards for an eye which has converged to swing out, I still believe there are a certain number of cases in which tenotomy will not be sufficient and will have to be combined with other precedures to get good cosmetic results. In many cases where the result is apparent binocular fixation there is no binocular single vision. In my experience the very limited number of squint cases operated by tenotomy, or any combination of operative procedures, in which there was a return to single vision, such return occurred in the cases where glasses were at once applied and worn, and in which the operative procedure was undertaken early. When the condition which is the cause of the loss of vision in a squinting eye is amblyopia ex anopsia there is always some hope that an operative procedure which restores the ocular excrescences to a moderately perfect alignment, will result in stimulating the ocular sight centres to resume conjointly the visual act.

DR. LUCIEN HOWE, Buffalo: It strikes me that our confusion of ideas comes from lack of definition. We should get rid of the word strabismus; it may mean anything, an excessive action of one set of muscles or a paresis of others. We should know too

whether the trouble is due to excessive or to insufficient action of a given group of muscles.

As to the operation itself there are so many methods that it is useless to discuss them here. The underlying principle is that when the deviation is due to excessive action of a group of muscles we can make tenotomy as has been done for so many generations by many ophthalmologists with excellent results. On the other hand when the deviation is due to insufficient action, however slight, of a group of muscles advancement is required.

After trying many methods I have found the most convenient form of advancement to be the one described in the second volume of a work on the muscles. As this volume has just been published and not yet distributed I venture to show the illustration there given of the operation referred to.

DR. PETER A. CALLAN: I did not bring this matter forward as an academic question but as a practical one. An adult patient comes with a squinting eye and wants to know the best thing to be done for cosmetic appearance. If you have to operate, a section with a resection is a better operation than advancement. As to tenotomies we have all been guilty of doing them indiscriminately and have had them come back with over correction. We should try to do something better and during the growing period we should not do a tenotomy but a resection.

As to measurement it is all an approximation. There is no means of accurate measurement.

A SIMPLIFICATION OF DE GRANDMONT'S OPERATION FOR PTOSIS

BY SAMUEL THEOBALD, M.D.,
BALTIMORE, MD.

Not long since there came under my care at the Johns Hopkins Hospital a case of acquired, bilateral ptosis, in which the lid fault — itself but one of many manifestations of a grave, general myasthenia — was decidedly more marked upon the left than upon the right side.

As there was little ground to hope for improvement from non-surgical measures, I operated upon the more affected, left, eye, by the method of de Grandmont as modified by Gruening, and, with a view to obtaining as perfect a cosmetic result as possible, I decided to wait for a few days and see the effect of this first operation before proceeding with the second eye.

Meanwhile, I considered how I might correct most exactly the slighter defect of the right lid, and after some reflection it occurred to me that this could be accomplished best by everting the lid and, without any disturbance of the external integument, removing directly from the tarsal cartilage — the outlines of which would then be easily seen — a strip of such width as might seem to be indicated, the excision to include, of course, the overlying conjunctiva. This procedure, furthermore, commended itself as involving less traumatism, and as being altogether a simpler and more easily performed operation than that of de Grandmont.

After waiting three days to see the result of the first operation, I proceeded to operate upon the second eye in accordance with the plan determined upon. The eye having been first anæsthetized by the installation of a 10% solution of cocaine, the upper lid was everted and a few drops of a 2% solution of cocaine, to which had been added a small quantity of a 1:1000

suprarenalin solution, was injected into and, perhaps, beneath the cartilage at several points along the line of the proposed incisions. An incision, begun with the knife and completed with scissors, was then made through the conjunctiva and the whole length of the cartilage parallel with, and about 3½ mm. from the free border of the lid. In similar fashion a second incision was made *parallel with the first* and about 3 mm. from it, and the included strip of cartilage and conjunctiva was excised. The edges of the divided cartilage were next brought accurately together by means of three fine, black silk sutures, and, in less than half the time required to execute the de Grandmont procedure upon the other eye, the operation was completed. Furthermore, when the lid was turned back into its normal position, one could see at a glance exactly to what extent the ptosis had been corrected, the elevation of the lid-margin being practically the same as was found a few days later, when the œdema consequent upon the incisions had disappeared. The anæsthesia induced was complete, and there was no complaint, whatever, of pain. Probably a weaker solution of cocaine would have been equally effective, but the house surgeon, who looked after this feature of the operation, did not care to take this chance. Snellen's lid-clamp might possibly have facilitated the making of the incisions through the cartilage, but it did not occur to me to use it.

I have emphasized the point that the second incision through the cartilage was made *parallel with the first.* This, again, is a departure from the de Grandmont operation; and it seemed to me to possess an important advantage, in that both edges of the divided cartilage are straight — not one straight and the other concave as in his procedure — and therefore more apt to unite evenly and without distortion. Furthermore, it seemed that the removal of a broader strip from the middle of the cartilage could have only the effect of elevating disproportionately the centre of the lid-margin. The result proved the correctness of this reasoning — the lid was raised equally throughout its length.

It was feared that the stitches upon the conjunctival aspect of the lid — which, as a matter of precaution, were not removed until the fourth day — might cause the patient considerable annoyance, but this did not prove to be the case.

To summarize the advantages which the procedure I have outlined seems to possess, it may be said: That it is a simpler operation, involving considerably less traumatism, than that of de Grandmont, and consequently may be performed in half the time; that it does away with the buried stitches which he employs or the deep ones, coming out on the lid-margin, suggested by Gruening; that the parallel incisions through the cartilage are preferable to those made by de Grandmont for the reasons just set forth; that one may judge at once exactly the effect produced in elevating the lid, and may with little trouble increase this effect, if it seems desirable to do so; and that the restoration of the parts to their normal condition occurs in much less time than in either the de Grandmont or Gruening operation.

The simplicity and advantages of the plan which had suggested itself of attacking the cartilage from the inner surface of the lid seemed so obvious, that I could not but ask myself whether this method had not occurred to others. A perusal of de Grandmont's description of his operation[1] showed, at all events, that it had not been thought of by him. Turning next to the account of Bowman's operation[2], which differs from de Grandmont's in that the upper lip of the cartilage, with a portion — in the case described "about half an inch" — of the tendon of the levator palpebræ is removed, I was interested to learn that in his first case (the one just referred to) he operated from the conjunctival surface of the lid, though in subsequent cases he went through the external integument; which is not surprising, as he doubtless found it easier to resect the levator tendon by this route.

Since this paper was presented to the Society, I have re-

[1] "Jour. de Med. de Paris," 1891, p. 296.

[2] "Royal London Ophthalmic Hospital Reports," Vol. I, p. 34.

ceived from the patient's physician, Dr. G. F. Bush, of Carnesville, Ga., a letter in reply to one which I wrote him asking for information as to the further progress of the case. Writing on July 13, the operation on the left eye having been performed May 22, and that on the right eye May 25, he says: "The operation on the left eye is not a success. The lid remains œdematous and heavy. . . . . The weight seems sufficient to produce a dropping or ptosis. The right is all right. The result is excellent. You can not detect that it has been operated upon."

DISCUSSION.

Dr. Emil Gruening, New York: de Grandmont described his operation as "résection tarso-musculaire," meaning that it is essential in his operation to cut out a part of the levator muscle; he did not limit his operation to the tarsus. The modification that I made, without knowing of de Grandmont's paper, was that of confining my incision to the cartilage. He makes his measurements from the border of the brow to the edge of the lid and finds, for instance, that there is a difference in the length of the lid of 5 mm.; he cuts out 5 mm. of the tarsus plus the levator muscle. I made the measurements on the cornea; when I found 4 mm. of the cornea covered in one eye more than in the other, I cut out 4 mm. of the cartilage, believing that it is not necessary to cut out the muscle. The modification that Dr. Theobald made occurred to me, but I refrained, thinking that the silk knots would cause lesions of the cornea. I think, however, that perhaps we may dispense with the sutures completely.

Dr. P. A. Callan, New York: I did this operation in one case, but made a modification — the upper incision was bow-shaped. I put the sutures, like Dr. Gruening, on the outside. I think it can be modified by not cutting the skin, but putting three needles through the outside and then threads over them. I think this is a good idea and shall certainly try it. With the bow-shaped incision there is a little irregularity of the conjunctival

surface. It is only necessary to remove the cartilage and not the muscle. In my operation the sutures cut through and I had to search for them after a little skin abscess had formed.

Dr. W. B. Marple, New York: I have done this operation a good many times, using the catgut sutures which did not need to be removed. It has always seemed to me that the crescentic incision was of advantage, because it is desired to have the effect greater in the center of the lid than at the sides. I shall take the first opportunity I have to try this method, as it seems to be a considerable advance over the others.

Dr. Samuel Theobald: I would only add that in the operation on the first eye, in which I did Dr. Gruening's modification, removal of a wide piece from the middle of the cartilage gave a "hiking up" of the central part of the lid-margin in an unpleasant way. I think therefore there is a decided advantage in the parallel incisions in the cartilage. The conjunctival sutures were complained of a little, but caused no trouble with the cornea.

Dr. Risley: Would there be any disadvantage in separating the skin and taking the cartilage out from the outside?

Dr. Theobald: It is much simpler to do this in the way I have described. If I had a case of redundancy of skin I would remove as much of it as might seem to be indicated by external incisions; but, even under such circumstances, I would prefer to excise the strip of cartilage from the conjunctival aspect of the lid.

RESTORATION OF SIGHT AFTER NEARLY A MONTH'S BLINDNESS FROM GLAUCOMA

By J. L. MINOR, M.D.,
Memphis, Tenn.

It is not so unusual to restore sight to an eye blind from an attack of acute glaucoma, if the case is seen early, and promptly operated upon; but in the case I am about to relate, blindness had existed for nearly a month, and it really belonged to the hopeless class. I never saw a case myself, nor do I know of one in literature, where, after so long a period of blindness, vision was restored by any means. Miss H., aged 57, referred to me by Dr. J. F. Cochran of Memphis, was seen Sept. 26, 1903, when the following history was elicited. While traveling in California, on July 5, 1903, she had a sudden and severe attack of pain in the left eye, lasting thirty-six hours. A few days later, a like attack was experienced in the right eye, when it was noticed that vision was reduced in both eyes. Such attacks repeated themselves every few days — being usually worse in the left eye — and with each attack there came more impairment of vision; and by Aug. 22, she was totally blind, with more or less continuous pain, in each eye. She was taken to an infirmary in Los Angeles, several weeks after the first attack, where she remained a week or more, under treatment, when she was dismissed, with eserine drops, to be used as demanded (they gave slight relief from pain, but had no effect on vision). Her case was pronounced hopeless as to vision, and operative measures were refused by the attending oculist.*

After this, the condition remained practically unchanged until I saw her. She told me that she could see, at times, large

* There may have been some confusion as to refusal to operate, for in a letter which I later received, Nov. 7, 1903, from Dr. W. D. Babcock of Los Angeles, one of the oculists who saw Miss H., he said "I saw her first July 28th, and gave an unfavorable prognosis, but as the case progressed, lost all hope of her ever regaining vision, and advised only an operation for relief from pain."

objects, but I found not even perception of light. The tension was + I. Scleral vessels enlarged; anterior chamber shallow; pupil dilated; media so hazy that nothing more than a red reflex could be obtained. This description applies to both eyes. Pain was more or less constant and severe, and the patient was worn to a shred by her continued suffering, and depression over her condition. The case presented a pitiable out-look, for vision had been lost for a month, and the condition pronounced hopeless by an oculist of repute. Moreover, the opinion had been expressed six weeks prior to my seeing her, when clear media admitted a clear view of the fundus; and as at that time, I was told that the oculist refused to operate, I naturally inferred there was some contraindication — probably a hemorrhagic condition, hence I was in a serious dilemma as to what course to pursue. I was not long in deciding that an iridectomy could hardly make her worse, and that it offered the only hope for relief from pain, and the only avenue to possible vision. With the assistance of Dr. J. F. Cochran and Dr. Alfred Moore, and under cocaine anæsthesia, I performed an iridectomy, upward, in each eye. The operations were smoothly performed, and the customary dressings applied. The healing process was normal. No further pain was experienced. The eyes were dressed daily on account of a slight conjunctivitis; but not until the fourth day after the operation, was effort made to determine the amount of vision in a coarse way, when it was found that she could recognize faces some feet away. By the end of a week, she could see the hands of a clock across the room, and tell the time by my watch. The first careful tests were made at my office, on Oct. 13, 1903, with the following results:

O. D. V. = 20/40 — 1.25 d. c. ax .120 V = 20/30.
O. S. V. = 20/100 — 2.00 d. c. ax .90 V = 20/40.

Visual field in each eye was concentrically contracted to a circle 10 degrees from the point of fixation. The wounds had closed, with good key-hole colobomas, and the media were clear.

T. N. The ophthalmoscope, showed in the right eye, with the exception of the optic disc, a normal fundus, which could be seen with a — I. d. The disc showed general cupping of — 7.00 d., with kneed vessels, and was of almost of atrophic whiteness. The left eye showed the same condition, except the cupping of the disc was less (fundus — 2.00; disc — 5.00).

I have seen Miss H. from time to time, at intervals of every few months, up to Jan. 20, 1908. The condition of the right eye is unchanged, as to vision, visual field, and intra-ocular appearances, but a small cystoid cicatrix, which appeared first April 12, 1904, at the upper and outer portion of the seat of the corneo-scleral incision, and has remained unchanged since. The left eye on March 16, 1905, could not be brought beyond 20/100. On Jan. 18, 1906, 20/200; Oct. 30, 1906, it was, movements of the hand at two feet, which it still retains. There have been no changes in tension, or to the ophthalmoscope.

DISCUSSION.

Dr. F. H. Verhoeff, Boston: Is it not possible that hysteria may have been a factor in this case? Perhaps the marked impairment of vision from the glaucoma served as a suggestion to the patient and the complete loss of vision was due to hysteria.

Dr. Emil Gruening, New York: These cases are not so very rare. I have had a number of them that have been considered hopeless, the eye hard, the anterior chamber almost abolished and patients practically blind for a period of several weeks, but in all there was some perception of light. In these cases an iridectomy sometimes restores sight. I think that in these cases of sub-acute glaucoma that have lasted some weeks we should not consider the outcome invariably hopeless. I do not think there is any element of hysteria in Dr. Minor's case.

Dr. W. B. Johnson, Patterson: I had a case of a colored woman on whom I operated after seven weeks, the operation being performed for the relief of pain. There was light perception,

but that was all. A very satisfactory visual result was obtained. I do not think it would be possible for a hysterical patient to present all the appearances of this picture indicating a severe glaucomatous process that had been in progress for such a length of time.

DR. J. L. MINOR: Dr. Gruening and Dr. Johnson have already answered the proposition of Dr. Verhoeff as to the possibility of the existence of hysteria. I do not think it could have been present. There was every indication of glaucoma. No view of the fundus could be obtained. There was no light perception. Then she too has been practically blind in one eye, the left one for three years. There was also great cupping of the discs showing the glaucomatous process. In other words every thing pointed to glaucoma — nothing to hysteria.

BILATERAL OPTIC NEURITIS AFTER ETHMOIDITIS.

BY DR. ARNOLD KNAPP,
NEW YORK.

Mrs. E. S., 30 years old, was seen on Nov. 19, 1907, on account of loss of sight in the left eye. She had had a severe cold in the head one month ago, which was followed two weeks later by headache, and pain about the left eye in the afternoon and blindness in that eye on the following morning.

On examination the left pupil is smaller than the right; irresponsive; constant hippus. There is no light perception. Optic neuritis is distinct. The disc presents a swelling of 2 1/2 D. On examining the nose, both middle turbinates are found enlarged and soggy. Patient states that she has had no unusual amount of discharge from the nose. On cocainizing the region about the left middle turbinate some muco-pus is seen in the upper meatus.

Nov. 20th, 1907. Dr. C. G. Coakley of New York, kindly examined the patient for me and carried out the subsequent

nasal treatment. He found some muco-pus on the left lateral wall on posterior rhinoscopy. The anterior half of the middle turbinate was removed; it was cystic, containing muco-pus and thickened lining membrane. After operation some neuralgia. Bloody discharge. In afternoon vision improved.

Nov. 21st. Sees movements of hands in temporal and lower field. Distinct central scotoma. Pupil immobile. Hippus. Fundus picture unchanged.

Nov. 22d. More discharge from nose.

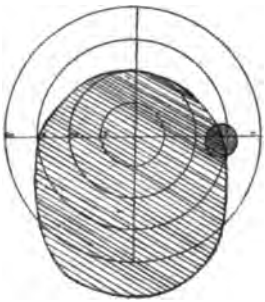

CHART 1.
Left.

Nov. 25th. Discharge continues. V. no change. Field shows central scotoma, extending further down than up (Chart 1). Circulation in optic nerve much improved. The posterior half of the middle turbinate remains and hides the sphenoidal ostium.

CHART 2.
Left.

Nov. 27th. Pupil now reacts to light but instantly dilates again. Central scotoma smaller (Chart 2). Optic disc better, except below.

Nov. 29th. More discharge from nose; patient seems to have a fresh cold. There is some pus between septum and middle turbinate. The nasal treatment consists in daily irrigation and cleansing. Eye: no change.

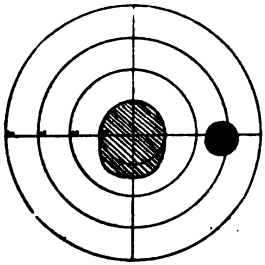

CHART 3.
Left.

Dec. 2d. V = $\frac{2}{200}$. Fundus about normal (Chart 3). Discharge as before.

Dec. 6th. Discharge less. V = 2 — $\frac{2}{200}$. Pupil reacts but does not stay contracted. Scotoma: no change.

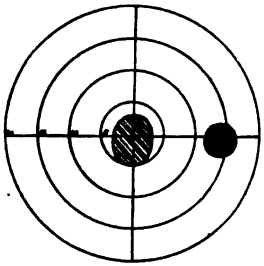

CHART 4.
Left.

Dec. 9th. Better. V = $\frac{5}{200}$ (Chart 4).

Dec. 12th. Slight discharge from nose in morning. V = $\frac{20}{70}$. Scotoma: slight relative central for white; no perception of red and green. Pupil normal.

Dec. 16th. V = $\frac{20}{40}$. Optic disc pale. Green not recognized.

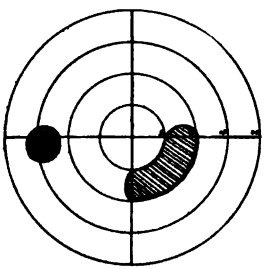

CHART 5.
Right.

Dec. 18th. The patient today states that she had had headache on the right side of the head for three days, with pain in right eye and diminution of sight. The right eyeball is tender V = $\frac{20}{50}$. There is some discharge from the right side. Paracentral scotoma (Chart 5). The optic nerve is hazy, and there is some congestion.

Dec. 19th. The right middle turbinate is partly removed.

Dec. 21st. Feels better. On looking off rotary nystagmus, both eyes; vertical meridian is pulled inward. Right pupil normal. V=$\frac{20}{70}$.

Dec. 23d. Right eye tender. V=$\frac{20}{70}$. Optic disc hazy. Discharge from right nose.

Dec. 27th. Right $\frac{20}{100}$; left $\frac{20}{40}$. Less discharge. Right eye still sore. Right pupil slightly dilated; reacts; hippus. Left optic disc distinctly pale. Scotoma larger, relative includes point of fixation.

Dec. 30th. R=$\frac{20}{70}$. No headache. Scotoma is relative today. In nose some swelling in middle meatus and pus.

Jan. 2d, 1908. R$\frac{20}{30}$. L$\frac{20}{20}$. No scotoma. Discharge less.

Jan. 6th. $\frac{20}{20}$ each. Right slight, left no discharge. The nasal condition in the right side chiefly involves the ethmoid (bulla very large).

Jan. 11th. Right $\frac{20}{20}$, left $\frac{20}{30}$. Nose the same.

Jan. 18th. No headache. Slight discharge. Right bulla removed. R $\frac{20}{20}$. L $\frac{20}{30}$. Nose dry. Pupil normal.

Jan. 27th. $\frac{20}{20}$ each. Right disc not quite clear. Ethmoid troublesome.

Jan. 8th. R $\frac{20}{20}$. L $\frac{20}{20}$. Left optic disc white. Right hazy. Pus in hiatus.

March 20th. Vision normal. Right disc normal. Left pale. Nose dry. No headache. Some nervous symptoms.

The unusual features of this case are as follows:

1. Localization of the inflammatory changes in the nose to the middle turbinate and ethmoidal cells.

2. Inflammatory changes in the head of the optic nerve.

3. Restoration of vision and improvement in the eye grounds coincident with intranasal treatment.

4. The order of the return of vision and changes in the field. From no light perception to hand movements in lower and outer field, then large central scotoma which diminished gradually; finally only for colors, then normal vision.

5. Condition of pupil. At first immobile with clonic spasm of the iris muscles, so-called hippus. Then reaction to light but only for a second, the pupil promptly dilating. Finally normal reaction.

6. A similar, but less marked condition developed on the other side six weeks later; moderate optic neuritis and paracentral scotoma; a similar condition existed in the right half of the nose to that found in the left side. Gradual recovery after intranasal treatment.

OCULAR AFFECTIONS ASSOCIATED WITH DISEASE OF THE SINUSES CONTIGUOUS TO THE ORBIT.

By S. D. RISLEY, M.D.,
Philadelphia, Pa.

A most important advance in our understanding of the etiology and nature of a considerable group of obscure ocular affections has been set forth during recent years, in a rapidly growing literature covering the border lines between ophthalmology and rhinology. It is not my purpose in this paper, nor is it necessary before this society, to review this literature, but rather to present briefly the histories of a few selected cases from my own experience which will furnish additional evidence and serve to emphasize the very frequent relation of cause and effect existing between various forms of eye disease and affections of the bony sinuses in the anterior segment of the skull, contiguous to the orbits and accessory to the nasal fossæ. A full appreciation of the frequency and importance of migratory inflammations from the nasal chambers and these cavities to the orbital contents was doubtless delayed by the neglect upon the part of the ophthalmologist to keep in mind the contiguity of these mucus-lined cavities and their intimate anatomical connections with the orbits.

It is true that we have not been unmindful of the fact that disease of the ethmoidal cells was the *fons et origo* of orbital abscess; that malignant disease of the maxillary sinus or of the

ethmoidal cells was especially prone to invade the orbit, but I am convinced that, so far as the literature affords an indication, we have not appraised at its full value the responsible part played by affections of these cavities in the production of ocular discomfort and ocular disease. Those who have had any extended experience in the treatment of the upper air passages know how difficult it is to secure surgical cleanliness in the nasal fossæ.

It should be remembered that the mucous membrane lining the interior of the nose is continuous through narrow drainage canals with the lining "*muco-periosteum*" of all the accessory sinuses. These sinuses are likely therefore not only to participate in the infectious diseases of the nasal membrane, but by their anatomical situation, and by turgescence of the nasal membranes, are removed from any favorable opportunity for natural protection by the usual methods of secretion and free drainage. The intimate anatomical connection of the inflamed membrane lining the thin bony walls of these cavities; the frequent lapses in the bony continuity of their walls; the network of sutures which in adult life unite the different centers of ossification; the numerous foramina for the passage of nerves, arteries, veins and lymph channels all give opportunity for the migration of infectious products to contiguous tissues.

Since the walls of these sinuses form so large a part of the walls of the orbit, reasoning *a priori*, it is not cause for surprise that the contents of the orbit are liable to invasion, as has been so abundantly proven by comparatively recently published observations and clinical reports. It is however a cause for surprise that the frequency of its occurrence and its serious significance in ocular affections was not sooner, and certainly more generally, recognized.

More or less serious and obscure ocular disease has, I am sure, in some instances been ascribed erroneously to more remote causes; or a rebellious asthenopia, which would not be vanquished by the correction of an error of refraction or some muscular imbalance, has been laid at the door of neurasthenia,

toxemias or other causes when the real origin of the trouble was to be found in some affection of one or more of these bony-walled cells. It may often be nothing more serious than pressure, *e. g.*, in a frontal sinus, or in the anterior ethmoidal cells due to a blocking or closure of its drainage outlet by a so-called "chronic cold in the head" which, when investigated, proves to be due to a turgescence or a chronic hypertrophy of the nasal mucous membrane in the middle fossæ of the nasal chambers, or to some mild chronic sinusitis, probably the persisting result of some antedating acute infection. I have seen many examples of the truth of this suggestion. The following case will serve to illustrate the importance of careful attention to this field of observation.

CASE I. Mr. F. had for many years been the victim of pain in the head, aggravated by using his eyes and often culminating in violent attacks of sick headache. He had a high degree of mixed astigmatism, the correction of which gave him entire relief from his violent attacks, but he was nevertheless unable to use his eyes with comfort. Repeated corrections of the error of refraction failed to give him either satisfactory use of the eyes or to relieve him of a persistent frontal headache with which he would rise in the morning. It would be aggravated by exposure to strong light or by the persistent use of his eyes.

The symptoms therefore pointed, definitely, only to ocular disturbance. That the eyes were probably the sole cause of his suffering found emphasis also in a constantly congested state of the *fundus oculi* which presented a flannel red fluffy appearance. A careful study of the nose at one of his visits, when he was in an especially uncomfortable state, revealed a swollen middle turbinate on both sides, which completely blocked the upper nasal passages and probably closed the ethmoidal and frontal sinuses. Cocaine with adrenaline contracted the tissues and his pain promptly subsided. A few cauterizations with tri-chloracetic acid and careful daily cleansing of the parts with a suitable wash

relieved the blocking, the pressure was removed and his eye symptoms disappeared.

A point which should be borne in mind in the class of affections under consideration is the abnormal anatomical relations which, not infrequently, either lie at the foundation of the sinus disease or afford especial liability. The importance of this statement was strongly illustrated in the case just reported. He had an abnormally shaped skull, affecting especially its anterior segment. One side of the face was smaller than the other, the zygoma being flat on the small side, rounded and bulging on the other, while the pupil on the flat side was much nearer the median line than the left.

This distortion of the skull modified the form of the orbits and the relation of parts in both nostrils, and doubtless, also the size and location of the ethmoidal and other sinuses. The middle turbinate on the right side was forced backward and tightly wedged between the deflected septum and the orbital wall, so that the breathing space was limited and still farther blocked by the hypertrophied and boggy soft tissues which effectually prevented all normal drainage from the ethmoidal cells. In addition to these unfortunate congenital anatomical defects, the eyeballs, having developed in the abnormally shaped orbits, were highly astigmatic, *i. e.,* misshapen, the corneal curvature being ellipsoidal instead of a rotated sphere.

There can be no question but that this man's liability to disease, both in the nostrils and the accessory sinuses, and also the astigmatic eyeballs with asymmetrical meridians, were all due to the congenital malformation of the anterior segment of the skull.

Many clinical examples could be brought forward to demonstrate the importance of these congenital defects in causing both ocular and rhinologic disturbance. That affections of the nose are important is emphasized by the well-known weakness of the eyes during an acute coryza even when these abnormal anatomical states are not present. The increased lachrymation, photo-

phobia and inability to use the eyes in the presence of a so-called cold in the head is a common experience.

It is not unreasonable to anticipate that any prolonged turgidity of the uveal tract, caused and maintained by the conditions which have been described, must in many cases lead to more serious sequellae through disturbance of the ocular nutrition.

CASE 2. P. S. Age 42. A gardener in the employ of one of my personal friends was sent to me for failing vision and constant frontal headache. He had made the round of various clinics without relief. His vision was reduced to 1/5. Both lenses were swollen and opalescent, and the vitreous was filled with floating opacities. Under the persistent use of atropia and dionin locally, with the iodides internally, he secured partial relief, but had many relapses into attacks of violent headache. A careful study of the nostrils and frontal sinuses was then made. Transillumination revealed a blocking of both frontal sinuses, and both middle turbinates were found tightly wedged against the bony septum. The amputation of the middle turbinates was followed by a profuse discharge of pus and almost immediate relief from the headache and undue sensibility to light. There was, however, a tendency to recurrence of accumulation in the sinuses and return of pain, probably due to a blocking of the ethmoidal as well as the frontal sinuses. The man declined any radical procedure for securing freer and permanent drainage and sought other advice. The relief from both the pain and ocular symptoms following the amputation of the middle turbinates and the temporary drainage of the sinuses leaves but little room for doubt as to the responsibility of the sinus disease for the affection of the eyes.

In the periodical literature much stress has been laid upon optic nerve affections secondary to disease of the sinuses, but the preceding cases have been presented to show that the origin of affections of the uveal tract will often be found in inflammation of one or more of these bony cavities. In June, 1904, I presented a paper on the subject to the section on specialties of the Penn-

sylvania State Medical Society, in which the history of two such cases were narrated.

The first, a case of acute purulent inflammation at the root of a molar tooth, with extension of disease to the maxillary antrum followed by a general uveitis which resulted in blindness, and sympathetic irritation of the fellow eye. The ball was enucleated and found firmly adherent throughout its lower half by the products of inflammation.

The second case was a case of chronic inflammation of the sphenoidal and ethmoidal sinuses with secondary uveitis and blindness of the right eye.

I now present Case 3 of this paper, in which events seem to have succeeded each other in the following order:

Firm blocking of the right upper nasal fossa by hypertrophy of the middle turbinate; purulent inflammation of the right frontal sinus; filtration into right maxillary antrum; necrosis and destruction of the floor of the frontal sinus; abscess of the orbit; proptosis of the eyeball; optic neuritis with reduction of vision to 1/5. Recovery through surgical procedure.

Mr. M., age 47, consulted me August 5, 1903, for confusion of sight due to diplopia; right hemicrania, which radiated from the mid-frontal region to the right ear and occiput. There was slight puffiness of the right upper eyelid, the ball was proptosed forward, downward and outward, but the field of forced fixation was but little disturbed, except upward where it was limited to the horizontal line. Deep palpation under the orbital rim revealed only a soft fullness, leaving the impression of displaced orbital fat, but no nodular masses were discoverable. The movements of the left eye were normal and both pupils reacted normally to light and shade. The fields of vision were not impaired; there was no scotoma. V. = 6/VII 1/2 in each eye. There was a low grade of hypermetropic astigmatism in each. In the position of rest the proptosed ball was estimated as 1 cm. in front of its fellow and the center of the pupil 8 mm. lower. On everting the upper lid the retrotarsal fold came forward and

there was moderate chemosis of the conjunctiva. Firm pressure upon the ball through the closed lids reduced the exophthalmus, increased the periorbital pain and caused a painful sense of fullness or pressure in the right nostril. The ophthalmoscope showed no change in the calibre of the blood vessels, but the disc was grayish red and opaque and its margins obscured, while the entire fundus was a fluffy, homogeneous dark red color. A study of the nostrils showed the left nearly normal, but the right was stuffed with polypoid masses, which bled freely. A portion of this tissue was removed, sent for examination, and reported as malignant, but a second examination did not confirm this opinion. Transillumination showed that both the frontal sinus and maxillary antrum were blocked by opaque contents.

After consultation with Dr. G. E. De Schweinitz and Dr. Randall, it was decided to attempt the drainage of the frontal sinus and antrum through the nostril before adopting a more radical procedure. At my request, Dr. B. A. Randall amputated the middle turbinate and enlarged the opening into the maxillary antrum. A canula was then introduced into each sinus daily, and large quantities, at first of semi-inspissated pus washed into the nostril. The proptosis of the eyeball was greatly diminished by this procedure and the pain became less severe, but both the pain and the prominence of the ball recurred after any neglect of the troublesome and painful irrigation. After several weeks, vision sank to 1/5 in right eye, the optic nerve margins were entirely obscured, the veins were full, dark and tortuous, and the summit could be seen with + 4D.

He was then admitted to the Polyclinic hospital, and assisted by Dr. Randall, the frontal sinus and anterior ethmoidal cells were freely opened through an incision under the orbital rim, extending from a point under the middle of the eyebrow inward to the nasal bone and downward along its border. On attempting to separate the periosteum, the bone of the floor was found necrosed and was curetted away.

There was a profuse gush of foul, glairy, purulent contents,

which was found to fill not only the entire sinus but the orbit back of the eyeball. The cavity after a painstaking removal of the diseased bone and granulation tissue, was carefully and thoroughly cleansed by irrigation with bichloride solution and diluted peroxide of hydrogen, followed by warm physiologic salt solution. A drainage tube was inserted into the frontal sinus and a second into the nostril from the inner angle of the incision, and the wound closed.

The pain and proptosis promptly disappeared and convalescence progressed uninterruptedly. The neuritis slowly subsided and vision rose to normal. Notwithstanding the displacement of the trochlear attachment of the superior oblique during the operation, normal binocular balance was restored.

In November, 1906, there had been no relapse. V. with correcting glass was 6/V in each eye, and there was no remaining signs of the optic neuritis. There was orthophoria. There was no visible scar remaining from the operation except at the point of emergence of the drainage tubes, and as this was under the nasal end of the brow could be seen only when the head was tilted backward. This result emphasizes an important point in the technique of the operation for opening the frontal sinus. The incision under the orbital rim gives equal, if not readier access to the sinus, secures more favorable drainage and does not result in the deforming scar so often seen when the operation has been made above the rim of the orbit.

That serious optic neuritis associated with a symptom complex suggesting intracranial disease may find its origin in an unsuspected sinusitis, is demonstrated by the history of the following case.

CASE 4. Optic neuritis; impaired central vision, contracted fields; recovery after drainage of frontal and ethmoidal sinuses after duration of nearly three years.

Thos. C., age 40, was sent to my clinic at the Wills Hospital, May 26, 1905, by his physician, Dr. Fetterolf. He had been suffering from insomnia and faulty vision with frequent exacer-

bations of greatly increased but transient impairment of sight. At his first visit V.= 6/X in the right eye and 6/VI in the left. The ophthalmoscope showed H = 2 D at the fovea in each eye, but the papillæ were swollen and the margins of the discs hidden by the infiltrated overlying tissues. There were numerous flame shaped hemorrhages on each nerve and throughout the fundus. The summit of the nerve was + 6 in the right eye, and + 4 in the left. The fields of vision were concentrically contracted to approximately 40°, but no scotoma could be demonstrated. The urine was normal. The man's mother had diabetes but otherwise the family history was good. He never had gonorrhoea or syphilis. The patient was sent to Dr. Weisenberg, then consulting neurologist, to the hospital for consultation. After an elaborate and painstaking study, Dr. Weisenberg reported the neurologic examination as negative, with the exception of a general increase in the tendon reflexes. There was "entire absence of focal symptoms and of general pressure phenomena," but he nevertheless advised that the skull should be trephined because of the great swelling of the optic nerves, and for the reason that a "new growth might be present in the cranial cavity in a region such as would not give any definite focal symptoms."

The man would not consent to this and the operation was not strongly urged. Even though there was no cause to suspect specific infection, large doses of potassium iodide, mixed treatment, mercurial inunctions to the point of commencing ptyalism were at different times persistently employed for many months with varying results. For a series of weeks the subjective symptoms would subside, the retinal hemorrhages absorb, and the swelling of the papillæ diminish, and a partial, or at times, a nearly complete restoration of the fields of vision, so that on several occasions the man returned to his employment, the care of a stationary engine, only to suffer a recrudescence of the entire symptom — complex. He had from the first complained of difficulty of breathing, especially at night, but on March 9, 1907,

after a particularly bad and sleepless night, he came to my private office complaining of frontal pain. I then found a fresh crop of hemorrhages in the retina and observed his great difficulty in breathing. I then examined the nostrils and found both middle turbinates hypertrophied and polypoid masses filling tightly the upper nasal space on both sides. The stuffing of the upper nasal fossæ was so complete as to effectually prevent all drainage from the accessory sinuses. I then amputated the middle turbinate on the right side, and two weeks later the same operation was performed on the left nostril. This was nearly two years after his first visit to the clinic, during which time he had been constantly under observation and treatment by his physicians, Dr. Fetterolf, Dr. Weisenberg and myself, or my assistants.

The relief which followed these operations was phenomenal. The drainage from the frontal and ethmoidal cells was free, and at first profuse, consisting of a creamy white discharge. Irrigation was not adopted, as it seemed unnecessary. The distress in the frontal region disappeared, and he slept well. Vision rose to 6/VI in each eye, and on April 20th, one month after the operation, the fields of vision were normal, and have remained so to date of writing, April 20, 1908. The swelling of the papillæ have slowly diminished, notwithstanding his continuous occupation at his engine. In the right eye it can still be seen with + 1 D through the correcting glass, but in the left the swelling has disappeared. The nerve margins can be seen indistinctly through the long time infiltrated overlying tissue. There has been no return of the hemorrhages. I can now but feel that the long delay, two years, before a study of sinus conditions was made, is a just cause for self-reproach.

MIXED STREPTOCOCCUS AND PNEUMOCOCCUS INFECTION OF THE ORBIT AND ADJACENT SINUSES.*

By CHARLES STEDMAN BULL, A.M., M.D.,
New York City.

The subject of Pneumococcus and Streptococcus Infection has developed great importance and interest during the last two or three years, within which period this particular form of infection has greatly increased in frequency and gravity. Prof. Osler has called attention to the fact that this increase is especially pronounced in the United States. During the last year the infection has been so widespread that the subject seems to demand organized systematic study and investigation, from the standpoint of preventive medicine.

The conditions attributable to this infection are very numerous and of great variety. We have as yet no certain knowledge of the mode of transmission of the infection, whether lymphatic or hematogenous, and it is just along these lines that our research work must be done.

One of the singular conditions prevailing is the widespread prevalence of pneumococci and streptococci in apparently healthy persons. Clinically speaking, the most marked feature of the infection seems to be the extraordinary variability in the virulence of action of the germs.

For instance in the Journal of the American Medical Association for Jan. 6, 1906, appears the report of a series of twelve cases of brain infection by the pneumococcus, in which the same channel of infection was determined, viz: Otitis media following traumatism, followed by septicaemia and acute pneumonia.

In the same Journal for May 2, 1908, Green reports a case of brain infection, with rigidity of the neck, Kernig's sign on both sides, low delirium and moderately high temperature with nor-

mal fundus. In this case the channel of infection could not be determined.

In the Medical Record, Vol. LXV. p. 215 Gruening reports a case of pneumococcus infection through the nose ending in orbital cellulitis.

At the first operation, the orbit, ethmoid cells, and frontal sinus were curetted and drained. Cerebral symptoms followed, and a second operation disclosed a large abscess in the frontal lobe. Pneumonia followed and death ensued in five days.

In a series of 65 cases of conjunctival infection reported by Smith, the pneumococcus was found to be the cause in 12 cases.

In 10 cases of corneal infection, the streptococcus was the cause in 4 cases.

In 10 cases of infection of the lachrymal sac the pneumococcus and streptococcus were found in 7 cases.

Haltenhoff reports a case of severe conjunctivitis, diphtheritic in character, in a child nine months old, which extended to the eye and orbit, and the infection was found to be due to a mixed infection.

De Schweinitz has reported a case of bilateral pneumococcus conjunctivitis, which later involved the cornea, but which healed without infection of the deeper corneal tissue by the virulent secretion.

During the past winter and spring, I have seen a goodly number of cases of severe inflammation of the eye and its adnexa, due to a mixed infection by the pneumococcus and streptococcus. Of these cases quite a number involved orbit and adjacent sinuses and of these I have selected six of the most virulent for presentation to the Society. It was not possible in every instance to trace the channel of infection but there seems to be little doubt that in four of the six cases the infection began in the nose and thence spread to the orbit and neighboring sinuses.

The points which I desire to emphasize in the study of these cases are as follows:

First: The marked insidiousness of the attack, and varying duration of the period of incubation.

Second: The extreme violence of the symptoms in the sudden onset of the attack.

Third: The very rapid rise of temperature, and the equally sudden fall after operative interference has opened the purulent deposit.

Fourth: The rapid development and violence of the symptoms point apparently to an unfavorable prognosis.

Fifth: Immediate and active interference, with free incisions, through curetting and irrigation, and prolonged and careful hunting for the purulent foci, soon bring about a more favorable condition.

Sixth: The necessity for great vigilance in watching the cases and searching for new foci on any sudden and rapid rise in temperature.

Seventh: The patients were all young, the oldest being 21 years, and the youngest nine months old.

Eighth: In only one case was the eye lost from suppuration.

CASE I. Infection of Nasal Meatus, Ethmoid, Orbit, Frontal Sinus and Lachrymal Gland.

G. S., man, aged 21, first seen Jan. 4, 1908. The patient stated that for a week or more he had noticed a dull pain high up in the nose, and that he could not breathe through the left side of his nose. On Dec. 29, 1907, five days before I saw him, the left eye became slightly inflamed, and this condition remained unchanged for two days. Then suddenly the pain became very severe in the orbit and forehead, the eye began to protrude, the lids became swollen, and the swelling began to extend upwards upon the forehead, outwards on the temple, and downwards on the cheek. When I saw him on Jan. 4 both eyelids were enormously swollen and so tense and hard that they could not be opened. The tissues on the forehead, temple and cheek became œdematous. The patient's temperature was 101 3/5, his respiration was 26, and his pulse was 64. A careful rhino-

scopic examination showed a very swollen mucous membrane and pus coming from the superior nasal meatus. Trans-illumination of the maxillary antrum and frontal sinus proved negative.

The patient was admitted to the hospital the same day, and a long incision was made into the orbit just below the supra-orbital margin. A probe passed in various directions discovered no pus, but revealed erosion of the roof and inner wall of the orbit. After free irrigation, a stout grooved director was introduced and passed at once freely into the superior nasal meatus, ethmoid cavity and frontal sinus. The periosteum on the roof of the orbit was eroded almost to the apex of the orbit. The ethmoid cavity was completely curetted, and fragments of bone and broken down tissue removed.

The opening in the floor of the frontal sinus was enlarged with bone forceps, and the sinus was carefully curetted and a mass of pus and broken down tissue removed. The septum between the two frontal sinuses was found intact but far on the right side of the median line. The opening into the nasal meatus was then enlarged and the meatus curetted, and a drainage tube introduced and free irrigation through the nose instituted. The eyeball was found in a state of panophthalmitis. After free irrigation with a bichloride solution, the orbital wound was packed with iodoform gauze and the drainage tube left in the nasal meatus. An examination of the pus and shreds of broken down tissue from the orbit, ethmoid cells and nose showed large numbers of streptococci and pneumococci.

On the next day the swelling and infiltration showed no diminution, and the patient lay in a stupor, with pulse 64, and temperature 102 1/5.

On Jan. 8 the wound was enlarged towards the median plane, and a stout probe was introduced far back in the orbit on the nasal side, and at length near the apex of the orbit, after some resistance, the abscess was opened and about one ounce and a half of pus evacuated. The whole cavity, including orbit,

ethmoid antrum and nasal meatus, was carefully irrigated, and a careful examination was made of the roof of the orbit, but no opening into the anterior fossa of the skull was found. All broken down tissue was removed and the orbit packed with iodoform gauze.

The superficial cervical glands on the left side were inflamed and sensitive as far as the clavicle. The next day there was a free discharge of pus and fragments of bone, and copious irrigation from the orbit into the ethmoid and superior meatus was ordered twice daily. The stupor became less marked and the temperature dropped to 100 1/5.

There was a slow but steady improvement until Jan. 15, when the temperature again rose to 102 1/5 and on the next day another collection of pus was discovered in the upper and outer angle of the orbit. This was freely incised and found to involve the lachrymal gland. The external canthus was divided and the gland and all broken down tissue was removed. From this time the patient made a slow but steady recovery, and the temperature fell to 100°, and on Jan. 28, to the normal. Irrigation of orbit, ethmoid and nose was done twice daily. The upper lid which had enormously swollen, almost reaching to the ala of the nose, slowly retracted as the infiltration diminished. The irrigation was continued daily and the drainage tube retained in the nose until all discharge ceased, which was on March 2. The patient was discharged on March 9, nine weeks from the date of entrance into the hospital.

Case II. Infection of the Nasal Meatus, Frontal Sinus and Orbit. A. U., boy aged 13. First seen Feb. 1, 1908, and gave the following history. He had been ill with the "grippe" early in the winter, and since his recovery there had been a foul discharge from the nose. About two weeks before I saw him he noticed a dull pain in the left orbit, and three days later the left eye began to protrude. When I saw him there were all the signs of orbital cellulitis — great swelling of the lids, chemosis of the conjunctiva, exophthalmos, the protrusion being directly

forward and the eyeball being almost immovable. The temperature was 102° and there was severe pain. Palpation through the upper lid above the eye seemed to indicate the presence of pus just beneath the fascia, and there was marked œdema over the left supraorbital region. Transillumination showed that the left frontal sinus was involved.

A long incision was made Feb. 6 through the upper lid, just beneath the orbital arch, through the tarso-orbital fascia. A probe was introduced in all directions, but no pus was discovered. A stout director was then introduced, and far back near the apex of the orbit, the abscess was discovered and nearly an ounce of pus evacuated. This pus, as well as numerous threads of necrosed cellular tissue were preserved for examination, and large numbers of pneumococci and streptococci were found. After careful irrigation of the cavity, further examination showed erosion of the roof, floor and external wall of the orbit, a small opening into the nasal meatus and a large one into the frontal sinus. Both of these openings were enlarged, all fragments of bone removed, and the nasal meatus and frontal sinus were carefully curetted. The septum between the frontal sinuses, and the orbital plate of the ethmoid were intact, as was also the floor of the orbit. Free irrigation from the orbit through the nose was then carried out, and a drainage tube inserted in the nose.

On the next day the cornea was found to be anæsthetic, and an ulcer appeared near the lower margin of the cornea, surrounded by a zone of infiltration. The œdema of the supraorbital region was more marked. The gauze packing was removed from the wound, and the parts freely irrigated, but no new abscess was discovered. The orbit was loosely packed, and irrigation was ordered twice a day. From this time all the symptoms subsided. The cellulitis rapidly disappeared, the temperature fell to the normal on the 8th day, but rose again to 100 1/5 on two different occasions. The suppuration was quite free for four days and then slowly diminished, but to the end, the pus always

showed the bacilli. The corneal ulcer did not perforate, and as the anæsthesia disappeared, the ulcer healed, leaving a rather dense opacity.

The patient's temperature ranged as high as 102 2/5, and at times the curve showed decided sepsis.

The patient was discharged cured on March 13, all signs having disappeared except a slight drooping of the lid.

CASE III. Infection of the Nasal Meatus, Ethmoid and Orbit. L. R., boy, age 16. First seen March 11, 1908. This case was of special interest, because he presented an acute septic process grafted on a chronic inflammation of the nasal and frontal sinus. The patient about a year ago began to suffer from frontal headache, which soon became constant and confined to the right side of the forehead. There was a dull ache in the orbit and he had difficulty in breathing through the right nostril. An examination of the nose showed enlargement of the turbinated bones but no discharge. Later there appeared a swelling just above the inner canthus, which slowly increased in size. About two weeks before I saw him there began to be some signs of local inflammation. The tumor over the canthus grew larger, the orbital tissue became inflamed — the eye was pushed towards the temporal side and forwards, and the pain became severe. When I saw him, the exophthalmos was forwards and outwards, and there was no mobility upwards or inwards. The lids were swollen, especially the upper lid, and somewhat congested. There was a tumor in the supero-nasal angle of the orbit, extending far backwards, as well as forwards and outwards. This was of bony hardness anteriorly and downwards but seemed to simulate fluctuation backwards. It was excessively sensitive to pressure. Except for the obscure sense of fluctuation at the back of the tumor, I should have made a diagnosis of osteoma.

The boy was taken into the hospital for observation and that night the temperature rose to 103 1/5 and he fell into a stupor, from which however he could be roused.

On March 13, 1908, a deep incision was made through the

upper lid, just beneath the orbital arch, beginning near the inner third of the eyebrow and carried to the glabella, at the middle of the bridge of the nose. This was followed by the discharge of a large amount of pus, and the posterior part of the tumor collapsed. After free irrigation, a stout probe was introduced and found bone erosion in every direction. The probe passed freely into the superior nasal meatus and backwards into the ethmoid cells. A large part of the orbital plate of the ethmoid was gone. The ethmoid cavity and nasal meatus were then thoroughly curetted and many fragments of bone removed. The opening into the nose was enlarged and free irrigation from the orbit into the nose was established.

Further examination showed that what gave the impression anteriorly of an osteoma was a dense ridge of bone extending from the nasal process of the frontal bone and the nasal bone itself, forwards, outwards and downwards. There was no opening into the frontal sinus.

The pus and detritus were crowded with pneumococci and streptococci.

The patient's temperature fell that evening to 101° and the next morning was 99 1/5°. The symptoms of orbital cellulitis subsided rapidly but the purulent discharge continued to be profuse for nearly two weeks, in spite of free irrigation, loose packing with iodoform gauze, and a drainage tube through the nose, and it was not until May 10 that the patient could be discharged.

CASE IV. Infection of Nasal Meatus, Ethmoid and Orbit. Rose S., a girl baby, aet. 9 months. First seen March 20, 1908. Child vigorous and well nourished. Mother stated that a swelling appeared just above the left eye two days before. This swelling rapidly extended, and when I saw the child both lids were greatly swollen and completely closed, and could not be opened. The subcutaneous infiltration extended upon the forehead and outwards upon the temple. Pressure through the upper lid elicited nothing, as the tissues were hard and resisting.

Pressure below the eye through the lower lid seemed to indicate the presence of pus. The temperature was 99 4/5° and the pulse was 90. A long deep incision was made through the base of the lower lid directly into the orbit below the eyeball, hugging the floor of the orbit. The knife was then withdrawn, and a bistoury with guarded point was then introduced, and the free incision carried back to the apex of the orbit. There was immediately discharged about half an ounce of pus, mingled with shreds of broken-down connective tissue and small fragments of bone. This pus and the shreds of tissue were carefully examined and found crowded with pneumococci and streptococci. After careful irrigation, a probe was introduced and roughened bone was felt on the floor of the orbit as far as the apex, on the nasal wall, and on the roof of the orbit near the superior bony margin, over which the periosteum was necrosed and cast off. There was an irregular ragged opening into the ethmoid and another into the superior nasal meatus. The ethmoid and nasal meatus were carefully curetted, and all fragments of bone removed. Irrigation from the orbit into the nasal meatus was carried out, as the fluid passed out through the nose. The wound was then loosely packed with gauze and the parts bandaged. The operation was followed by a rapid rise in temperature to 104 4/5°, and that night there were symptoms of meningeal irritation, the head being retracted, and accompanied by convulsive movements of the right side.

The gauze was removed the next morning and free irrigation brought away fresh masses of necrotic tissue and a thin seropurulent discharge. This irrigation and repacking were done twice a day. On March 22 the temperature rose to 105 3/5° but sank the next morning to 101 1/5° and rose in the evening to 102 4/5°.

The next morning, March 24, it sank to 100 1/5° but that evening rose to 104 4/5°. It was then noticed that there was a swelling at the outer canthus which extended to the upper lid, and the cornea was ulcerated near the lower margin. The swell-

ing was freely incised and a quantity of pus removed from the outer angle of the upper lid. The temperature again sank to 101 3/5°, only to rise again to 103 4/5°. The orbit was again thoroughly irrigated and more necrotic tissue removed. The temperature sank to 100° the next morning, March 26, rose to 101° that evening and again sank on March 27 to 99 4/5°.

The swelling of the surrounding parts gradually subsided. On March 28 the temperature rose to 103 4/5° and then gradually sank on March 31 to 100°. On April 1 it rose to 102 2/5° and on April 2 to 103 2/5°. It then sank to 100° on April 3, but again rose to 102 2/5°. Careful search was made for some other septic focus, but nothing was discovered till April 8, when the temperature suddenly rose from 98 4/5° to 104 2/5°, and this was followed by a discharge of pus from the left ear. Then after irrigation of the canal, the temperature fell to 101°

On April 9 a free myringotomy of the left membrana tympani was done and the temperature fell to 99 2/5°. There was a free discharge from the ear assisted by irrigation until April 15, when it ceased. From this time all the symptoms rapidly subsided and on April 18 the temperature fell to the normal and remained there. The corneal ulcer gradually healed and the surrounding zone of infiltration disappeared.

This case was one of great gravity and for many days the result was exceedingly doubtful. The temperature was essentially a septic one, ranging as high as 105 4/5 and changing rapidly from high to low. The pulse rate varied between 89 and 176, and the respiration from 24 to 82 per minute.

The case ended in complete recovery, with a clear cornea, and a slight eversion of the lower lid from contraction of the cicatrix of the incision. The patient was discharged on May 4.

Another notable point in this case was the extreme youth, the patient being only nine months old.

CASE V. Pneumococcus and Streptococcus Infection of the Orbit, Lachrymal Gland and Eyelids. Boy, N. F., aged 2 years.

Mother noticed a protrusion of eyeball and swelling of eyelids two days before I saw him. First inspection on March 23, 1908, showed enormous swelling of both lids of left eye, marked protrusion of eyeball directly forwards, and a prolapse of the lachrymal gland between the closed lids. There was great chemosis of the conjunctiva and a cloudy cornea without ulceration. The eyeball was immovable. Temperature 103 4/5° and pulse 160 to the minute. Child cries constantly and is very restless. Eyelids could not be separated. No conjunctival discharge. Under chloroform anæsthesia, a free canthotomy was done and the external canthal ligament completely divided. The orbital cellular tissue was then incised on the nasal and temporal sides, and above and below the eyeball, the knife being introduced far back in the orbit. These incisions were followed by a large flow of pus, which was collected and kept for careful examination. The lachrymal gland was then incised and a large amount of pus followed. After continued irrigation of the orbit and cavity of the gland by a bichloride of mercury solution (1.5000), the lachrymal gland was carefully dissected out and removed. The same was done with the palpebral portion of the gland. Exploration was then made on the nasal side of the orbit. The orbital plate of the ethmoid was intact and no rough bone could be felt. At the extreme inner angle of the orbit there was a small area of necrosed bone opening into the superior nasal meatus. All bits of diseased bone were removed and a large free opening was made into the nasal meatus, through which free irrigation was established to the floor of the nose.

After a second free irrigation of the orbital tissue and nose, the incisions were stuffed loosely with fine iodoform gauze.

The child rallied well from the operation and that evening the temperature went down to 99 3/5°. There was a daily rise of temperature to 103 for six days, but free irrigation followed by loose packing with gauze invariably caused a fall in the temperature. For two days the child was delirious, but after the

third day the delirium did not return. The orbital infiltration rapidly subsided and at the end of a week the mobility of the eye was restored. The anæsthesia of the cornea disappeared, there was no loss of substance, and the cornea cleared up entirely at the end of three weeks. The infiltration of the lids lasted longer and was not entirely gone at the end of five weeks, when the patient was discharged.

CASE VI. *Pneumococcus and Streptococcus Infection of Nasal Meatus, Ethmoid Cells, Frontal Sinus, Orbit and Tympanic Cavity.* Private patient. J. L., a young man, aged 23, first seen March 8, 1908. For a month or more he had some obstruction with nose and could not breathe through the right nostril. Three days before I saw him, he complained of deep-seated pain in right orbit and over right eye. The next morning the eyelids were swollen and the eye protruded.

When I saw him on the third day the exophthalmos was marked, the eyeball immovable, and the eyelids enormously swollen, the swelling extending upwards to the forehead, outwards to the temple and downwards upon the cheek. The temperature was 103 4/5, he complained of severe pain, and the parts were very sensitive. Under general anæsthesia a deep incision was made into the orbital tissue on both sides of the eyeball, the knife being passed far back into the orbit. The hemorrhage was abundant, but no pus was found. The wounds were freely irrigated and were packed with gauze. The next day there was no pus, and all the symptoms were worse. A long incision was then made through the upper lid just below the orbital margin, involving about four-fifths of the length of the lid, the incision passing through the tarso-orbital fascia, and extending far back in the orbit. This was followed by the exit of a large amount of pus. A probe passed directly into the nasal meatus, and also into the right frontal sinus. After careful irrigation, which brought away fragments of bone and pieces of broken-down tissue, a more extended examination showed that nearly the entire orbital plate of the ethmoid was

gone, and roughened bone on the roof and floor of the orbit. The septum between the frontal sinuses was broken down, and both sinuses were full of pus and fragments of bone. The opening into the left frontal sinus was enlarged, and both sinuses were thoroughly curetted and then freely irrigated until all detritus was removed.

The opening into the nasal meatus from the orbit was enlarged and the meatus curetted and irrigated, and a drainage tube inserted. The cavity of the ethmoid was thoroughly curetted and irrigated, and the wound was then packed with gauze. That evening the temperature fell to 100 1/5 and the severe pain disappeared.

The next morning the symptoms had markedly subsided, but that afternoon the temperature rose to 103 2/5 and he complained of severe pain in the right ear. Inspection showed a bulging reddened tympanic membrane, but no tenderness over the mastoid. The membrane was at once incised and a small quantity of pus came out, which on examination was found filled with pneumococci and streptococci. The tympanic cavity was carefully irrigated and the auditory canal was plugged with antiseptic cotton. The temperature again fell to 100°, and did not rise above this point for three days. Then it rose rapidly to 104 4/5 and the infiltration of the orbit increased. The dressings were removed and the orbital cavity, frontal sinuses, ethmoid and nasal meatus thoroughly irrigated, but brought no great flow of pus. The aural symptoms had entirely subsided and there was scarcely any discharge from the ear. A careful examination was then made of the orbit, and far back at the apex the knife opened another abscess, from which there was a free discharge of pus. The pus on all occasions was found loaded with pneumococci and streptococci. From this moment the symptoms rapidly subsided. A spot of infiltration and ulceration had appeared in the cornea near the lower margin, which had threatened to perforate, but after the evacuation of the deep abscess, the orbital cellulitis rapidly subsided, and the corneal complica-

tions began to heal, and eventually the cornea cleared up entirely. The course of the disease lasted nearly three weeks, during which the temperature varied between 100° and 104 4/5°. At times the patient was delirious, and at other times somnolent and in a stupor, which was alarming. He was discharged from treatment at the end of the sixth week. The exophthalmos had all gone, and the eye was freely movable in the orbit. The cornea was clear, the membrane tympani was healed, and the hearing was only moderately impaired.

There is some ptosis, but not so much as might have been expected from the extensive incision, and this can be improved by subsequent operation.

DISCUSSION OF THE LAST THREE PAPERS.

Dr. L. H. Taylor, Wilkes-Barre: The subject of Dr. Risley's paper opens up a wide field of discussion and a field that has been cultivated quite extensively during the last few years. My maiden effort before an association of this kind was on this subject, over twenty years ago. It is very necessary that we should pay particular attention to the nose. As Dr. Risley says it is oftentimes nothing more than pressure, and yet this pressure is a very important matter.

A patient that I have in mind illustrates a certain group of cases that are very easily relieved. A young man who came to me a number of years ago complained of headaches and of some difficulty with his eyes, but examination showed an enlarged middle turbinate, and one application of the cautery, and some attention to the nose afterwards, entirely relieved the symptoms and he does not wear glasses yet, although he came with the intention of having his eyes examined for glasses. The majority of the cases, of course, are not so easily relieved. I think the chief difficulty is in the middle turbinate; that is the offending portion as a rule with these severe cases of headache that are not relieved by the correction of the refractive error. There may be considerable refractive error and yet its correction does not cure the condition and then we find that there is nasal trouble.

Another group is like this: a patient suffering with severe headache on the left side and the removal of a portion of the

turbinate released a large amount of pus, with immediate relief of the headache. I have an appointment on Saturday to operate on a patient from whom I expect to remove a portion of the middle turbinate for the relief of headache. I make it a rule always in every case that comes to me with headache to examine the nose and find out what its condition may be. It is very important that this should be done. Of course, it is very fortunate for those who do not do nose and throat work if they can have some one else to make these rhinological examinations.

Dr. G. E. de Schweinitz, Philadelphia: In connection with these three interesting papers I would like to speak of two cases recently under my care, and to exhibit these stereoscopic X-ray pictures made by Dr. Henry Pancoast at the University Hospital. The first of these cases illustrates the importance of recognizing sinus disease, lest its influence produce serious optic nerve changes. The patient, a man aged 52, in the latter part of November, following what was evidently an attack of influenza, noted marked depreciation of vision. The symptoms as he detailed them and which occurred at that time were typically those of a retrobulbar neuritis, and his other symptoms typically those of sinus disease, although there seems to have been no very good examination made, nor any treatment directed toward the sinuses. When I examined him, about five months after the beginning of his visual disturbances, the right eye showed marked atrophy of the optic nerve and only faint light perception in the upper and inner portion of the field. The left optic nerve was also atrophic and the eye absolutely blind. An examination by Dr. Ross Hall Skillern revealed thick pus coming behind the posterior pillar from the sphenoid. Catheterization of the sphenoid revealed the presence of necrotic bone, and the inflammatory products were further demonstrated by washing out of the sinuses. Dr. Skillern was uncertain whether the frontal sinuses were affected or not; there seemed no doubt that there was infection of the posterior ethmoidal cells. The accompanying stereoscopic X-ray picture of the sinuses shows, I think, that there is great distention of the frontal sinus and indicates the loss of part of the wall of the sphenoid.

The second patient, a young woman in the early twenties, who for some time had been troubled with recurring attacks of episcleritis, and who had had on several occasions attacks of

mastoiditis, never severe enough, however, to call for operation, following prolonged exposure after an imprudent mountain climb, began to be troubled with severe headaches and marked congestion of both scleras, particularly upon the outer sides. Vision was somewhat lowered but ophthalmoscopic examination was negative. The field of vision, however, was concentrically contracted and there was a little beginning wedge-shaped loss of color perception near the fixation point. The symptoms gradually increased, and the most searching examination by her medical attendants failed to reveal any general cause for this optic nerve degeneration, except perhaps some secondary nephritic irritation owing to failure of proper elimination of the uric acid series. Vision rapidly declined until it was reduced to the ability to count fingers at half a meter, the visual fields continued to contract, and a typical central scotoma developed in each field, at first only for colors but subsequently for white light. Even at this period there was not much ophthalmoscopic optic nerve change, although for a time there was a distinct edema of the corneal epithelium. The whole naso-pharynx was enormously congested and there was some hypertrophy of the turbinate bones. Catheterization of the sphenoid brought to light some flake-like material, which unfortunately was not examined bacteriologically. Treatment of the naso-pharynx, on several occasions washing out of the sphenoid sinus, and a residence in the far south to escape the unpleasant winter weather were followed by a rapid amelioration of the symptoms; the headache disappeared, the scleral congestion ceased to be evident, and the vision improved so that at the present time it is about 6/60 in one eye and 6/50 in the other. The field of vision has widened, but the central scotoma is still evident, at least for colors. While it is not absolutely certain that sinus disease was the factor in this case, the evidence is strongly in favor of this diagnosis. The accompanying X-ray stereoscopic picture of the sinuses fails to throw any light on the subject, although there seems to be some thickening of the anterior wall of the sphenoid.

Dr. C. R. Holmes, Cincinnati: Certainly a new theory has developed with regard to the relation between the eye and the sinuses and those of us who think back twelve or fifteen years and then see what is done today and what relief is obtained by the proper study of and operation upon the sinuses must cer-

tainly say that there has been great progress made. I was very much interested in the papers that have been presented and Dr. Risley's paper, which covers the ground so very thoroughly, leads me to remark that in many of these cases it is absolutely impossible at first to discover in the nose any signs whatever of disease and it is for this reason that we should be so very careful in passing judgment on a patient after only one or even two or three examinations. Those of you who have gone into this work very thoroughly will bear me out in that statement; and if the eye symptoms cannot be relieved by the most careful refraction and muscle correction, even though the nose doesn't show any signs of inflammation, we have no right to say until after repeated examinations that there is no nasal disease. I have on several occasions observed this and I call attention to the fact because patients have come to me and to some of my colleagues who have been examined by most able men but not frequently and repeatedly. There are some cases where we should make an exploratory operation.

Twelve years ago I reported a case very much like Dr. Knapp's, although nine was unilateral. A double infection is very rare. In my case there was total blindness with atrophy of the optic nerve and intense pain and after opening and draining the sphenoid sinus there was complete restoration of vision.

With regard to the bacterial infection there is one thing we should bear in mind, in these acute cases, especially, and that is, — and I am speaking from experience that was rather unpleasant, — if we have a case where the bacteria are active we should hesitate to do any very radical operating at that time. The case that caused me to especially take this stand was that of a man of great importance in the part of the country where he lives who came on account of an acute frontal sinusitis, double. He had had trouble for years, but an attack of influenza caused an acute exacerbation. I told him I did not like to operate during an acute attack but his symptoms were so severe that I had to do it. I made this mistake — instead of making just enough opening to give drainage I did a radical double frontal sinus operation with a severe erysipelas as a complication and a result. The lids sloughed in part but were restored finally with no disfigurement — but the right cornea was damaged. The point I would call attention to is that frequently the doctor is charged in such cases with having infected his patient. So was I. But,

past winter a young woman of twenty-one who had been thoroughly examined by a nose and throat specialist without any nasal trouble being found, came to me. She had very marked exophthalmos, the eye being pushed forward and downward and immediately back of the upper lid a movable tumor could be felt. This was cut down upon and found to be a sac of pus which had been there for six years. The operation was continued into the frontal sinus and pus found. Pus was also found in the sphenoid. Here was a saculated collection of pus that had been there for six years with no suspicion of the presence of such trouble.

In the acute infectious diseases and the exanthems of course our suspicions are aroused inasmuch as we know that in these conditions we have engorgement of the nasal mucous membranes. Of course the whole medical profession, especially in our line of work, are now on the alert and these cases will be much more frequently reported.

There is one form I have not seen mentioned; that is a puffiness about the optic nerves. It occurred in both eyes in a patient I had with obstructive turbinates. In this case an operation was not permitted. The picture is very interesting. You are looking through a fog at the optic nerve. There is no question about there being both ethmoid and sphenoid disease but not acute enough probably to cause atrophy.

Dr. Samuel Theobald, Baltimore: We have been interested in this subject in Baltimore. Recently Dr. Harry Friedenwald made a splendid series of sections of the head of the nerve which showed, especially, the very close relationship between the sphenoid sinus and the optic nerve. It was apparent at a glance how easily trouble in the sphenoid might involve the nerve.

Dr. Emil Gruening, New York: Interest in this subject is not as recent as it seems to be. In 1886 I wrote an extensive paper on reflex ocular symptoms due to nasal affections. This paper was read before the Academy of Medicine in New York and published in the New York Medical Record.

I have never seen the symptom of hippus referred to by Dr. Knapp.

In Dr. Risley's paper he says that he makes the incision in frontal sinus disease and ethmoid disease below the rim of the

brow. I think that is a mistake. The incision should be made along the brow. There is no disfigurement when that is done. The caries is very rarely in the anterior wall but in the floor of the frontal sinus, the roof of the orbit; and in all the cases I have had it is necessary to remove the floor, and that can be very much better done when a portion of the anterior wall is removed. I don't think the Killian operation causes disfigurement when properly done. The method has decided advantages. I have done a number of these operations and showed two cases before this society two years ago when it met in New York. There was no disfigurement in those cases.

Dr. S. D. Risley: I was very glad indeed to hear Dr. Holmes refer to the difficulties of diagnosis in many of these cases. We are by no means sure, as he has so well said, that the sinuses are not involved even when the nose shows no indication of disease. This is especially so when the sphenoid sinus is the one involved. In 1904 I read a paper on this subject before the State Society of Pennsylvania and a whole group of these cases was then reported.

The simulation of other forms of disease is quite common too. Dr. Harlan I am sure will recall a case which he and the late Dr. Norris saw with me where we concluded that there was a new growth in the orbit and that enucleation and exenteration should be done, but it turned out to be an abscess of the frontal sinus in which the sinus was unusually large and the whole floor had fallen down back of the eyeball and the whole orbit was filled with pus. Yet it presented all the signs of a malignant growth in the orbit.

I quite agree with Dr. Taylor that no examination of rebellious cases of asthenopia is complete that doesn't include a study of the sinuses and the nasal passages. Transillumination of the sinuses is of great advantage in the study of these cases, as shadows are often present when other symptoms are absent. Headache is not always present.

I wish to emphasize the fact that the affections of the eye associated with sinus disease are by no means confined to the optic nerve. Asthenopia and choroidal irritation, or inflammations are even more frequent. In the cases reported in my paper there were no scotomata. I imagine that the kind of ocular disease produced depends upon the location of the sinus disease

in some measure; whether in the anterior or posterior ethmoidal cells or in the sphenoid sinus. Many of the cases of ocular affections which prove so rebellious to treatment are often due to some unrecognized disease of one or more of the sinuses contiguous to the orbit.

Dr. A. Knapp, New York: In answer to the question regarding hippus, it is a term referring to chronic oscillation of the pupil, a clonic spasm of the iris muscles. In this case I do not think it had anything to do with the change in the optic nerve.

As to the controversy about opening the sinus above or below the brow, I think it is simpler to open below in most cases, but in some the sinus extends so high up that it is necessary to remove part of the anterior wall.

Dr. G. E. de Schweinitz: I desire to say that the skiagrams passed around were the work of Dr. Henry Pancoast.

HEMORRHAGE FROM THE CORNEA IN GLAUCOMA.

By THOMAS R. POOLEY, M.D.,
New York.

The case which I am about to report presented a phenomenon which I have never seen before, nor have I ever read or heard of such an occurrence. It is for this reason that I have thought it worth while to report it here, with a view to ascertaining whether any of the members of the society have met with or heard of a similar case.

The patient, a woman of 38, was admitted to my service in the New Amsterdam Eye and Ear Hospital on February 16, 1907. She stated that she had entirely lost the sight of the left eye four years ago after a very severe attack of pain and inflammation, no doubt acute glaucoma, but she had suffered no pain since until seven weeks before.

Status Praesens: The eye showed, besides the condition soon to be described, the usual picture of absolute glaucoma —

circumcorneal injection, wide vertically oval pupil, hazy and anaesthetic cornea and cataract. Tension of the globe was the highest I have ever met with, hardly defined by our numerical expression of +T-3, for the eye was stony hard. But, besides these usual conditions of absolute glaucoma, the following very unusual ones were observed.

There were two points on the cornea, one situated a little to the outer side of the vertical meridian, and a smaller one near the inner side of the same meridian; both were near the sclerocorneal junction, and over both a blood clot had formed, which hung downward toward the pupillary margin. Upon wiping them off with a piece of cotton, there was seen to be an underlying congeries of blood vessels, from which, even with the naked eye, blood could be seen freely flowing, and the hemorrhage recurred each time the blood was removed with a cotton swab. The blood was of rather a bright color, suggesting an arterial source. No distinct loss of the epithelium could be made out however.

Examination with the corneal microscope showed a most remarkable condition. Situated entirely around the sclerocorneal margin, there are various blood vessels which extend into the cornea just as is seen in the newly formed blood vessels in pannus of the cornea. None of these were visible to the naked eye however.

The drawing made by Dr. Coburn shows this, as well as the two points from which the hemorrhage occurred, where the vascularity extends to and even beyond the pupillary margin. One of these shows a bulbous formation, the other is arborescent in form. At one point, this is on the lower corneal margin, the blood vessels are more abundant and extend, by some small branches, to a place on the cornea where there is a small defect in the corneal epithelium, the only place where the cornea seems to show any loss of substance, and this is to be seen only with the corneal loup. The drawing was made under the loup and is therefore enlarged in all its proportions.

Dr. Pooley's case of
Hemorrhage into cornea

Enucleation of the globe was made the same day and followed by perfect and uneventful healing.

Dr. Coburn examined the eye. Section showed a deep glaucomatous excavation, but there was no revelation made by either the macroscopical, or microscopical examination to account for the occurrence of the corneal hemorrhage, the report being that the flushing of the eye by fluids, during the operation of its removal, had so destroyed the epithelium as to render any examination worthless.

It may be added that the lids were perfectly normal and there was therefore no reason for assuming a trachomatous process as responsible for the appearance presented by the cornea.

As to the possible duration of this condition, I am entirely unable to say, as I only saw the patient once and all attempts to obtain a history from her as to this particular were useless. However, I am inclined to think that the process had been one of considerable duration. I have not been able to evolve from my own mind any suitable explanation for the corneal pannus, since the increase of tension does not seem to satisfactorily explain the cause. I have therefore left it for others to do and shall be glad to hear any discussion thereon. My time was too much taken up to search the literature of the subject and I have been content to report the case without further comment.

DISCUSSION.

Dr. W. F. Mittendorf, New York: I think these cases are exceedingly rare. I have seen only one case of this kind which occurred in a patient 55 years of age, in an old glaucomatous eye and would regularly three or four times a year have one of these hemorrhages into the corneal tissue. The attacks were generally preceded by slight pain. In two or three weeks the blood would become absorbed again, the cornea remaining hazy.

ADENO-CARCINOMA OF ORBIT.

By THOMAS R. POOLEY, M.D.,
New York City.

The patient, a young man of 30, was referred to me by Dr. St. John, of Hartford, on September 17, 1907.

A year ago, he first noticed a small growth under the outer side of the right brow, which his family physician told him would not amount to much. It remained stationary for about three months and then began to grow quite rapidly.

On June 5, 1907, he consulted Dr. St. John, who writes that "he has an intra-orbital growth, evidently originating from the periosteum and, from its feel, it was either an exostosis or sarcoma, especially as the past month a similar growth has appeared on the temple opposite, suggesting perforation."

Status praesens: There is a slight drooping of the upper lid, proptosis, the movements of the eye are restricted in the upper and outer direction, and there is diplopia in the upper left field of fixation. A tumor can be felt just under the outer third of the orbital ridge, extending deeply into the orbit and firmly connected with the periosteum. The growth is hard, feels nodular in form, and there is also a second tumor just above the outer margin of the eyebrow, which is very tense and firmly adherent to the bone. This tumor is about 2.54 centimeters in diameter.

The ophthalmoscopic examination shows a normal fundus with + 150 Ds. Vision = 20/30. The left eye was normal with + 1 D Cylinder, Axis 180° = 20/20.

My opinion was that the case was one of sarcoma with metastasis to the brow — that the prognosis was exceedingly bad, but that, nevertheless, the patient, after having been fully informed, should have the chance of operation, to which he readily consented, and an operation was made the same day, under ether.

Operation: Beginning at the outer margin, an incision was carried along the orbital ridge, extending almost to the inner canthus. The periosteum was then freely separated so as to give access to the tumor, which was found to occupy nearly three-quarters of the upper part of the orbit. Care was taken to keep behind the muscular sheaths of the eye muscles so as not to wound them. The bulk of the tumor lay in the outer part of the orbit and probably involved the gland. The tumor was not encapsulated and had to be removed piece-meal. Its posterior attachments to the periosteum were very firm. The under surface of the superior orbital ridge and the orbital plate, at its upper and outer parts, were found to be involved, as manifested by softening and discoloration, and were therefore curetted.

The incision already made was then extended posteriorly across the right temple and a flap formed, exposing the second tumor, which was situated 19.05 millimetres posteriorly to the end of the right superior ridge and 12.70 millimetres superiorly to the superior border of the zygomatic arch; from thence extends into temporal fossa to the orbital plate of temporal bone and under the temporal muscles and fascia. This tumor was not encapsulated either but very firmly adherent to the integument and the surrounding tissues and to the periosteum as well. The bone was softened over nearly the entire extent occupied by the tumor, and was curetted. No perforation of the orbital plate could be found, and the second tumor was therefore probably metastatic in origin. The incisions were closed with catgut sutures, leaving a gauze drain in the temporal region, and a bandage applied.

The operation lasted one hour and three-quarters and was well borne by the patient. Healing was without accident, wound healed by primary union and, on the 24th of June, five days after the operation, the patient was discharged.

September 17, 1907, the patient returned with a relapse. He first noticed a return of the growth about five weeks previously.

An examination showed a prominent tumor in the upper

inner part of the orbit, as well as in the site of the former secondary tumor. There was a moderate degree of exophthalmos and the vessels of the conjunctiva were dilated and tortuous.

Ophthalmoscopic examination showed choked disc in its first stage. Vision, with correction, = 20/50.

Although the case now seemed hopeless, and the speedy return of the growth after the first operation was most discouraging, nevertheless, at the earnest request of the patient, another operation was done on the same day.

An incision was made, extending from the supra-orbital ridge down to and below the inner canthus. Upon reflecting the periosteum, a tumor mass, which entirely filled and distended the orbit, was found. This was removed as thoroughly as possible but, because of the earnest protest of the patient, the eye was not enucleated. The bones of the orbit were found to be pretty generally involved; the anterior-ethmoid cells were curetted so as to make free communication with the nose, and a drainage tube passed through the nostril. He remained in the hospital for about two weeks; the wound again healed by primary union; the eye assumed its normal position, its movements were unimpaired and the disc looked the same. The tumor on the temple was not interfered with.

On October 5th, I saw him for the last time and his condition was about the same as above described.

March 2, 1908, his mother wrote to me that, a week subsequent to his last visit, he began to have occasional severe headaches, which became more constant and increased in severity so that rest was impossible unless under narcotics. He died December 11, 1907, apparently from meningitis. No autopsy was made.

Dr. E. E. Smith, who examined the tumor, reports as follows:

The histo-pathologic structure is that of an extensive growth of masses of epithelial cells in alveoli, with a moderately abundant stroma. In places, it presents the appearance of an adenomatous arrangement, which suggests the glandular origin of the

growth. In some areas, there is hemorrhagic infiltration and associated degenerative changes.

The structure, then, is that of adeno carcinoma.

Remarks: I have reported the case for several reasons.

First: The form of tumor found by the pathologist is very rare, and although the location in which it developed suggested its having its origin in the lachrymal gland, it was nevertheless supposed to be a sarcoma. I have not examined the literature on the subject to find out the frequency with which such tumors occur in this location but, from my own observation, they are very rare.

Second: There is, and I am not prepared to deny the general truth of it, the prevailing opinion that, in operating upon these malignant growths of the orbit, we only hasten the fatal issue, and yet occasionally we meet with a most surprising success.

On October 24, 1885, I removed a sarcoma of the antrum, which also extended into the nostril. The first operation was followed by a relapse; a second more thorough one, including enucleation of the eye, and exenteration of the orbit, and removal of most of the superior maxilla, which resulted in a complete cure. This man is still alive after 22 years. (Transactions Medical Society, State of New York, 1886).

Several years ago, I showed to the Section of Ophthalmology of the Academy of Medicine, an aged man of 84 from whom I had removed a sarcoma of the orbit. In commenting on the case, one of my esteemed colleagues said: "Mr. President, it is true that sometimes calves are born with two heads, but Mr. President, calves have but one head." This epigrammatic remark was, as I construed it, meant to emphasize the very unusual fact that there has been as yet no return of the tumor. However, that old man was alive when last heard from, a short time ago, and I believe still is.

One other case of osteo-sarcoma, which I operated upon for Dr. Pellett of New Jersey, which seemed of a hopeless character, lived a long time thereafter.

Exceptions prove the rule? Yes; but when the exception means the prolonged life of the patient, why not give him the benefit of the exception?

Third: I want to say that I think most orbital tumors can be removed by the incision I have described and I think, in most cases, it is preferable to the Kroenlein operation. The resultant scar is much less conspicuous than that left by the Kroenlein, which from its osteoplastic character, and lying on the temple in full sight, makes a very disfiguring and conspicuous scar. There are cases however in which this procedure may be specially applicable, as for instance, in large growths which entirely surround the optic nerve, or develop in its sheath, and when re-section of the nerve has to be made, but I am equally sure that, in many others, the incision under the brow is to be preferred.

HISTOLOGICAL INVESTIGATION OF A CASE OF BLEPHARO-CONJUNCTIVITIS CAUSED BY THE DIPLOBACILLUS OF MORAX-AXENFELD.

By BROWN PUSEY, M.D.,
Chicago.

Our knowledge of the histopathology of blepharo-conjunctivitis caused by the diplobacillus of Morax-Axenfeld — an important subject in eye pathology — is based on the study of one case by Stock. A few investigators have studied small pieces of conjunctival tissue excised from patients suffering with this disease and their findings have supplemented those of Stock, also they have differed somewhat. The study of excised pieces of conjunctiva is of limited value, because from the nature of things, such tissue can only be taken from the region of the transitional fold, where the conditions differ greatly from those existing in

the ocular and palpebral conjunctiva, and completely from those existing in the lid edges.

Realizing the desirability of another study, like Stock's, of the whole tissue of a case of this disease I set about to obtain it, and recently by great good fortune, in one of the large hospitals of Chicago a case was found a few days before death in a man whose family allowed us to take the whole tissue post mortem.

Clinically the case was one of chronic blepharo-conjunctivitis occurring in a man. It was one of many cases which were found in a ward where a number of elderly men had been kept together for a long while — the disease was epidemic in the ward. The case presented the typical picture of the disease in the chronic form.

The bacteriological diagnosis depends on smears, for through a misunderstanding cultures were not made, though cultures had been made from other cases in the ward. Smears were made from both eyes and typical Gram negative Morax-Axenfeld diplobacilli exist in the smears in great numbers, together with Gram positive bacilli of the diphtheria group and Gram positive cocci. Aside from the bacterial content of the smear it is that usually gotten from eyes infected with the diplobacillus of Morax-Axenfeld, being rich in fibrinous matter and relatively poor in cells, there being only a few degenerated epithelial cells and a few polymorphonuclear leucocytes. Some of the polymorphonuclear leucocytes show phagocytosis of the diplobacilli.

The tissue was fixed in 10% formalin solution, then put into alcohol of ascending strengths, and finally imbedded in paraffin and celloidin, and sectioned. Sections were stained by various stains.

The histopathology of the four regions, the lid edge, the tarsal conjunctiva, the conjunctiva of the fornix and that of the bulb is markedly different, and for convenience is described separately. Figure 1 shows all the parts.

In the lid edges, the striking change is in the increase of epithelial cells, the new cells growing into the underlying tissue

in cone-like masses. (Figure 2). This growth of cells in the lid edges is universal, but it is more marked in the lower than in the upper lids. There is no diffuse infiltration of the connective tissues by the epithelial cells as in malignant processes. The superficial pavement epithelium is not composed of as many layers of cells at the inner angle as at the outer, and cornification of these cells stops at about the middle of the lid edges or a little back of the middle. Around the epithelial ingrowths there is an increase of cells, these cells showing the character of new connective tissue cells with here and there plasma cells and mast cells — there are no lymphocytes and no polymorphonuclear leucocytes. There is a slight increase of blood vessels. The Meibomian glands are not affected. The glands of Moll as a rule are not affected, but one series of sections shows the lumin of one of these glands filled with leucocytes mostly of the polymorphonuclear variety. I was unable to find micro-organisms in this cavity and the cause of this abscess formation in all probability was not the Morax-Axenfeld bacillus.

The tarsal conjunctiva is much thickened, the thickened tissue being composed of a mass of folds, tubules (glands of Henle) and new supporting tissue. (Figure 3.) The folds and tubules have a lining cell wall composed of 2 or 3 cells. Within the folds and tubules there are cast-off epithelial cells, mucoid material and bacteria-diplobacilli. Between the epithelial cells of the walls of the folds and tubules one finds in the superficial layers a few diplobacilli. There are many wandering cells — mononuclears and polymorphonuclears — in the epithelial cell layer. The epithelial cells of this region show a slight tendency to undergo mucoid change. The connective tissue substructure of this region is cellular and fairly vascular. In it there are small round cells with a relatively large nucleus and a small amount of cytoplasm, larger cells like connective tissue cells, plasma cells and an occasional mast cell. Plasma cells are the most abundant. Polymorphonuclear leucocytes occur, but are rare. Returning to the subject of the architecture of this thickened conjunctival tissue, I

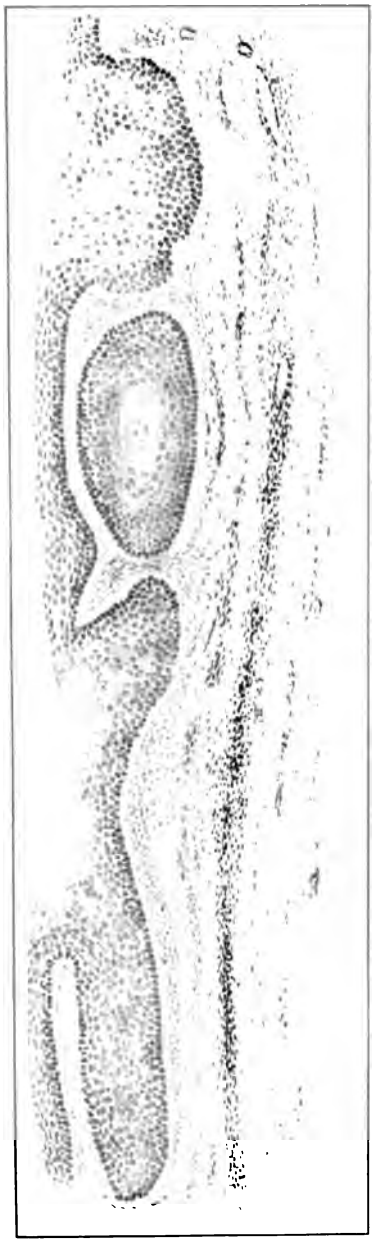

Fig. 1. Blepharo-conjunctivitis caused by the Bacillus of Morax-Axenfeld

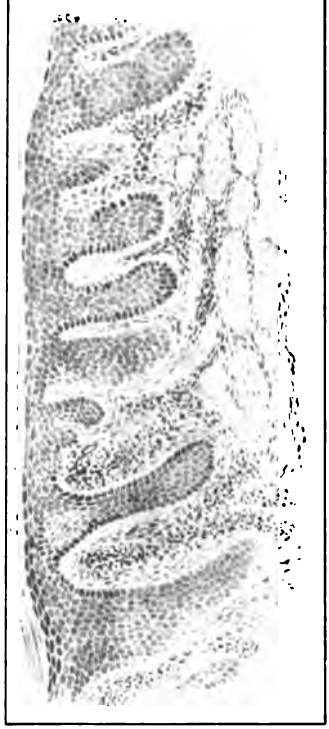

Fig. 2. The lid-edge in blepharo-conjunctivitis due to the Bacillus of Morax-Axenfeld

Fig. 3 The Tarsal Conjunctiva in conjunctivitis due to Bacillus of Morax-Axenfeld

would emphasize the statement that it is made up of a mass of folds, tubules, and new supporting tissue. Sections made at right angles to the long axis of the tubules (or in other words made parallel with the conjunctival surface) leave no doubt about the fact that they are true tubules.

In the conjunctiva of the transitional fold there is also a great increase of epithelial cells. Here the increase of cells consists of an increase in the number of the cells which make the epithelial cell layer of the conjunctiva, not the formation of cones or tubules. The epithelial cell layer is made up of from 4 to 7 or 8 cells and there is marked desquamation of cells. The epithelial cells of this region show a very marked tendency to undergo mucoid changes; in some places, particularly on the lower lid, the superficial cells have all become mucoid. Stained with a specific stain for mucin (Figure 4) they make a striking picture. The mucoid cells when near the surface discharge their contents in thread-like masses and when the mucin is among masses of desquamated cells it appears to hold them together. Over much of the surface of this region of the conjunctiva one finds desquamated cells apparently adhering to the underlying epithelial cell layer by means of mucoid shreds which have been thrown out from mucoid cells, the cell bodies of which retain their places in the epithelial cell layer. Among the free desquamated cells, and among those desquamated cells spoken of as adhering to the underlying epithelial cell layer by means of mucoid shreds, there are many Morax-Axenfeld diplobacilli, some cocci and some Gram positive diphtheroid bacilli. (Figure 5.) Between the superficial cells of the epithelial cell layer occasionally one finds diplobacilli. The organisms within the epithelial cell layer are rare and apparently do not penetrate deeply, for in a search through many sections I did not find them below the second layer of cells. Many wandering cells — mostly mononuclear but a few polymorphonuclear — lie between the epithelial cells.

The subepithelial tissue of the transitional fold shows the same structure as that found in the similar lymphoid tissue of the

region of the tarsal cartilage. The new cells form a diffuse mass, there being no localized masses of cells or follicles such as are seen in trachoma or follicular conjunctivitis. Plasma cells are the predominating cells. In the subepithelial tissue I did not find bacteria.

In the glands of Krause there are many plasma cells in the supporting tissue; this probably is pathological. Some of the epithelial cells of the ducts of these glands show mucoid change.

The conjunctiva of the bulb shows the same increase of cells in the epithelial cell layer that exists in that of the transitional fold. There is the same marked desquamation of cells, but a much less tendency to form mucoid cells, there being no mucoid cells in the region near the cornea. One sees the same condition described in a foregoing paragraph of the apparent adherence of desquamated cells caused by shreds of mucoid material discharged from goblet cells which retain their position in the epithelial cell layer. Among these desquamated cells along the surface of the epithelial cell layer there are Morax-Axenfeld diplobacilli. Between the superficial cells of the epithelial cell layer there are diplobacilli. There is diffuse infiltration of a lesser degree of the subepithelial tissue by new cells, these cells being of the same type as those found in the similar tissue in the region of the tarsal cartilage.

In the limbus region in one eye (the tissue of the other eye was imbedded in paraffin and in separating the conjunctiva from the cornea the incision unfortunately was made at the limbus, rendering this part of the tissue useless for study) along the greater part of the upper half of the cornea the epithelial cells have multiplied and formed ingrowths in the underlying subepithelial tissue. These epithelial ingrowths vary in size and might be spoken of as having a neck and branches, the neck being the region near the surface, the branches being masses of cells lying in the episcleral tissue (Figure 6). The drawing is typical of what is found. The neck of these ingrowths has a long and short diameter. In the ingrowth shown in the drawing at the

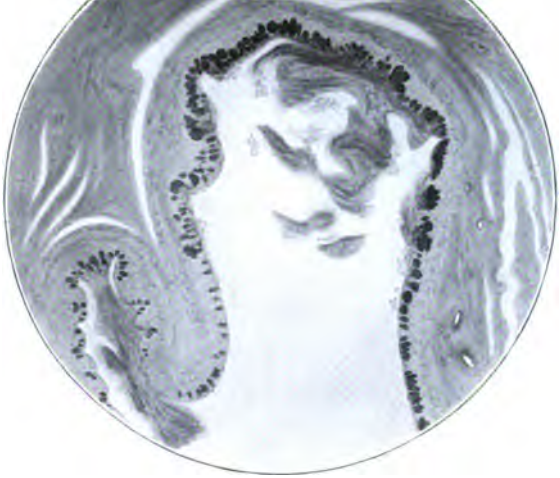

Fig. 4. Showing mucoid cells in conjunctiva in blepharo-conjunctivitis due to Bacillus of Morax-Axenfeld



Fig. 5. Epithelial ingrowth at limbus

left there are in the short diameter about 15 cells, in the long diameter the neck can be followed through 12 sections averaging in thickness about 20 microns. At the right in the drawing such an ingrowth is shown with the neck cut in the long diameter. The mass of epithelial cells in the middle of the figure shows a branch of an ingrowth; in this instance this mass of cells branches from the mass of cells shown at the left of the drawing and can be followed in the series through 10 sections. Such a mass of cells in a series eliminates the possibility of these formations being simply folds. The central cells of these ingrowths undergo changes, ultimately showing necrosis, and the necrotic masses of cells may or may not be in contact with the surface. In the neck of one of these formations in the superficial cells I found diplobacilli. I could not find organisms in the deeper cells and I am of the opinion that organisms have nothing to do with the changes found in the interior of these masses of cells. The cells do not invade the scleral tissue and in no place do they infiltrate the tissue like malignant growth. The tissue surrounding them is cellular and fairly vascular.

The facts brought out in the foregoing study may be briefly summarized: In the lid edges there is an invasion of the deeper tissue by epithelial cells in the form of cone-like ingrowths; the superficial pavement layer of cells is thinner than normal at the posterior edges of the lids and these cells do not show kerato-hyalin changes; the glands emptying on the lid edges are unaffected. The conjunctiva of the tarsus is much thickened and in it there are folds and tubules; there is great desquamation of epithelial cells and the epithelial cells show a moderate tendency to undergo mucoid changes; within the folds and tubules there are diplobacilli; there are diplobacilli between the superficial cells of the epithelial cell layer; wandering cells in large numbers are found between the cells of the epithelial cell layer; the subepithelial tissue of this region is fairly vascular and is the seat of a diffuse infiltration of new cells of which cells plasma cells are the predominating ones; no bacteria are found in the subepithelial

tissue. The epithelial cell layer of the transitional fold shows a great increase in cells and the cells show a very marked tendency to undergo mucoid change; there is marked desquamation of cells but at no place is there complete desquamation of cells as in some other forms of conjunctivitis; desquamated cells and débris appear to be held in contact with the epithelial cell layer by means of mucoid shreds which remain adherent to mucoid cells which in turn hold their position in the epithelial cell layer; in this débris and other débris in the folds of the conjunctival sac there are Morax-Axenfeld diplobacilli; between the superficial cells of the epithelial cell layer there are Morax-Axenfeld diplobacilli; the subepithelial tissue of this region is like that of the similar region of the tarsus. The epithelial cell layer of the bulb shows a moderate tendency to undergo mucoid change; along the surface débris adheres as on the surface of the conjunctiva of the transitional fold and in this débris there are Morax-Axenfeld diplobacilli in abundance; between the superficial cells of the epithelial cell layer there are diplobacilli; the subepithelial tissue of this region is like that of the similar region of the tarsus but much less involved. At the limbus in the episcleral tissue there are epithelial cell ingrowths which show necrotic areas.

On comparing Stock's finding and the foregoing it is seen that so far as the work of Stock goes the findings in this tissue confirm his in every point; on the findings, which are similar, comment is not necessary. In such a comparison it is also seen that this tissue carries us several steps further in our knowledge of the histopathology of this disease.

Stock did not find bacteria in his tissue, attributing this to the process of preparation. The finding of the bacteria in my tissue settles this point and shows that the organisms are in the folds of the conjunctiva in masses of débris, and along the superficial surface, again in débris consisting of desquamated cells, which appear to be held in contact with the conjunctiva by mucous shreds, and shows that, in small numbers diplobacilli lie in the in-

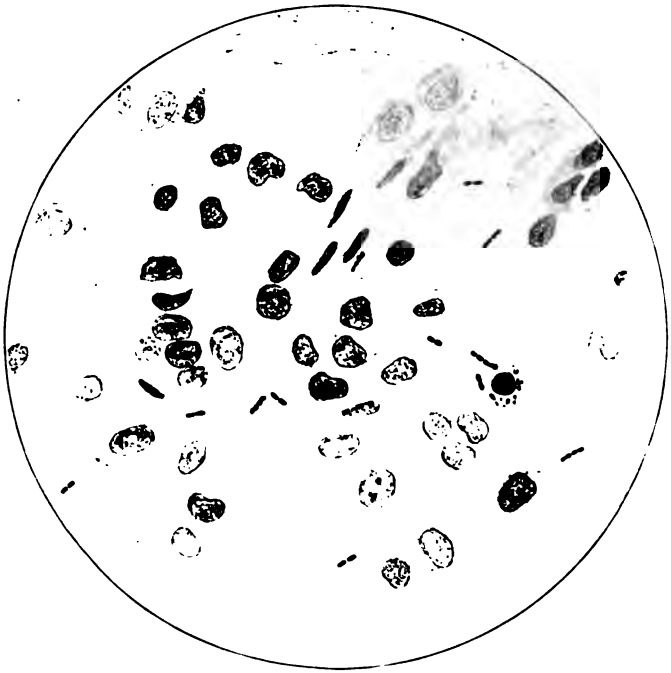

Fig. 6. Bacteria in fold of conjunctiva

terspaces between the most superficial epithelial cells of the conjunctiva; they are not found among the deeper layers of cells. I think it is a matter of pratical interest that débris consisting of desquamated cells, mucous, bacteria, etc., appears to be held in contact with the conjunctival surface by mucous which is adherent to the conjunctiva. It has been suggested that mucus has a protective function and that it may be even bactericidal. In this tissue appearances indicate that it may promote trouble by holding débris together and even in contact with the conjunctiva.

Stock speaks of the new cells found in the mucosa as round cells. Mayou, who has recently studied pieces of tissue removed from the lower conjunctival sac in several cases of this disease, points out the fact that Stock did not demonstrate the character of these cells by means of cytoplasmic stains. Mayou, using Pappenheim's plasma stain, found in his tissues that the new cells of the subepithelial tissue consist almost entirely of plasma cells. It is my good fortune to possess several sections of Stock's tissue and in a section stain with hæmatoxylin-eosin it is perfectly clear that the new cells of the mucosa are mostly plasma cells (Stock's Rundzellen). I stained many sections with Pappenheim's stain and with Unna's polychromemethyl blue and my findings confirm those of Mayou.

Mayou in writing of the cells of the subepithelial tissue says that "directly beneath the epithelium the cells are somewhat broken up no doubt owing to the presence of the toxin." My tissue does not confirm this finding.

The finding in this tissue of evidence of involvement of the glands of Krause, which Stock does not speak of, is worthy of attention and becomes of much interest when considered together with the well known clinical fact of the difficulty met with in eradicating the organism from the conjunctival sac. Krause's glands because of their comparatively long ducts are removed from the action of remedies applied in the conjunctival sac, and as this infection is not a self-limiting one infection of these glands

may be persistent and be a source from which reinfection of the conjunctival sac occurs. Favoring this idea are the facts that in my tissue the organisms do not penetrate the conjunctiva beyond the second layer of cells and that the folds and tubules of the tarsal conjunctiva in which I found diplobacilli are shallow, and accessible to remedial agents.

The tubular glands of Henle have been the object of much discussion, their existence being granted by a number of observers and denied by others. I would again point out the fact that I made sections of the conjunctiva on the flat surface, and these sections leave no doubt in my mind about the existence of tubules in this tissue.

The finding of ingrowths of epithelial cells at the limbus and the necrosis of these cells is by no means the least interesting result of the study of this tissue. One should proceed most cautiously in arriving at conclusions from the study of one case, but this tissue seems to justify the idea that here we have explained one mode of origin of a fairly frequent complication of this and other forms of chronic conjunctivitis, viz.: circumcorneal so-called catarrhal ulcers. The cause of the circumcorneal ingrowths was undoubtedly the same factor, probably the toxin of the organism, which caused the very similar formations in other parts of the tissue. The necrosis of the central cells, as I said above, was probably a part of the life history of the cells. As a result of the necrosis of the cells of these ingrowths we have clinically an ulcer, histologically a cyst-like formation. To answer the question which naturally arises, Why do the epithelial cells of the limbus form such ingrowths and the other cells of the bulbar conjunctiva not do likewise? we have the fact that these cells are active under all stimulations, for example, they have been found to be the most active cells in repairing injuries of the epithelial layer of the cornea. In the light of this finding it is interesting to recall the fact that the efforts made to explain the circumcorneal ulcers of chronic conjunctivitis on the basis of traumatism and subsequent infection have been unsuccessful.

A DESCRIPTION OF CASES OF SHRINKAGE OF THE EYEBALL WITH REMARKS ON THE PROCESSES UNDERLYING ATROPHIA BULBI IN GENERAL.

BY W. GORDON M. BYERS, M.D.,

MONTREAL, CANADA.

To make clear the points which I wish to bring out in this paper, it is necessary first to outline the pathological findings in cases of atrophia bulbi consecutive to a plastic inflammation, and to discuss briefly the generally accepted views in regard to the processes producing this condition.

Macroscopically, on examining a typical case of this kind, one finds the globe characteristically squared, with, often, an appreciable buckling of the sclerotic behind the line of insertion of the extrinsic muscles, while, on section, the arrangement is such as one sees in the following slide: The squaring, previously mentioned, is well shown in the contour of the specimen, and the cornea is often reduced in size and markedly crinkled. The retina, extensively detached, adheres only at its fixed points, the optic disc and the orra serrata, and anteriorly comes in more or less close contact with the posterior surface of the lens. In addition, one frequently sees the ciliary body and the anterior part of the choroid separated to a varying extent from the sclerotic, and the subretinal space filled by an extensive exudation which, in cases of long standing, shows cholesterin or bony formation.

Microscopically, one finds as the most striking feature newly-formed fibrous connective tissue which extends from the ciliary processes on the one side, around the lens, especially behind, to the ciliary processes on the other side of the eye. These cicatricial bands, which are, without question, the products of an inflammation of the anterior divisions of the uveal tract, constitute the feature I particularly wish to discuss.

The contraction of this fibrous tissue, which occurs during the process of its organization, is almost universally held to be the sole factor at work in producing the changes in atrophia bulbi which I have outlined. Fuchs[1] and, less clearly, Parsons,[2] and Ginsberg[3] accept this view in its entirety; while Greff[4] mentions "displacement" of the vitreous and retina, through subretinal exudation and œdema of the anterior part of the uveal tract with extravasation into the supra-choroidal lymph spaces as the result of a damming back of secretion by inflammatory deposits on the secreting surfaces of the ciliary body, in addition to the contraction of the newly-formed connective tissue already mentioned. Of these writers, Fuchs, who alone ascribes a rôle to the pressure of the extrinsic muscles of the eye, is the only one who gives a logically connected account of the sequence of events in these cases; and one emerges from a study of the standard works on ophthalmology with the feeling that our knowledge in this field is incomplete and unsatisfying.

Only Schirmer,[5] not content with the views already advanced, has tried to find some other cause for atrophia bulbi and the diminished tension constantly present in this condition. After artificially producing shrinkage of the globe in rabbits by means of injections of quicksilver, Schirmer made out microscopically engorgement of the vessels of the ciliary body, and œdema of this structure, especially marked in its processes; and concluded that these inflammatory disturbances of the ciliary body tended to produce a diminished amount of aqueous, richer in albumin, and an observable diminution of tension. To account for the cases in which, though a severe inflammation has run its course and the eyeball has quieted down, hypotonia continues, Schirmer found so many of the vessels of the ciliary body obliterated that, though the aqueous was qualitatively normal, it was impossible

[1] Text-book of ophthalmology.
[2] The pathology of the eye.
[3] Grundniss der path. Histologie des Auges.
[4] Pathology of the eye.
[5] Deut. Med. Woch. 1906, p. 794.

for the secreting structures to furnish the usual amount of this fluid. As a consequence intra-ocular tension is continuously reduced and the walls of the globe, no longer held in tension, contract through their own elasticity and simultaneously increase in thickness — "non-irritative phthisis." Schirmer could only allot to the pulling of the shrinking exudation within the globe a rôle in more strongly retracting certain parts of the wall of the eyeball, *e. g.* scars. Finally, if, in addition to the numerous obliterated vessels, inflammatory foci and the attendant inflammatory disturbances of circulation remain behind, one has a combination of the two processes: an aqueous richer in albuminous ingredients is secreted in smaller amount — "phthisis dolorosa."

A few years ago I was struck with the inadequacy of the fibrous-tissue theory as the sole explanation of the changes in atrophia bulbi, and have since come to believe that numerous other factors are at work in producing this condition, principally as the result of a study of the following cases to which I should like to draw attention:—

CASE I. J. K., aged three years, was brought to the Royal Victoria Hospital in December, 1898, with a history of an injury to the right eye by a piece of wood four months previously. The patient had been treated outside by a general practitioner and was said never to have experienced any pain as the result of the accident.

The child's right eye was visibly shrunken, and, though pale and free from injection when first seen, marked filling of the pericorneal and conjunctival vessels of the globe was noticed after the usual slight examination. A large cicatrix, situated about the middle of the cornea, extended from the outer almost to the inner corneo-scleral margin, and to the posterior surface of this the central parts of the iris were firmly attached. The anterior chamber was thus divided into two compartments, that on the temporal side being the deeper. V. = no p. l.; T. — 1, at least.

The parents were apprehensive of sympathetic inflammation,

and, with their consent, Dr. Buller removed the globe on the grounds that it was useless and a source of danger to the other eye.

After hardening in formalin and freezing in the usual manner, the globe was divided in a vertical direction; the section passing through the inner half of the iris internal to the pupil and the anterior synechia, and, of course, at right angles to the corneal scar.

Examining the cut surface of the outer half of the globe, one saw the central corneal scar, and a depression of the cornea at this point which gave the structure as a whole an epsilon-like appearance. The pupil seemed to be entirely closed by a purse-like contraction, and the whole central area of the iris was drawn forward and attached to the convexity of the posterior surface of the cornea, the depression in which was probably attributable to the dragging of the adhesion. As before remarked, the anterior chamber was thus divided into two compartments. The lens was very much shrunken, but a small portion remained in close contact with the posterior surface of the iris. On each side, from the corneo-scleral margin to well beyond the equator of the globe, the ciliary body and choroid were extensively detached from the sclerotic; and the spaces thus formed were filled by a clear, firm exudate which was seen, with the aid of a lens, to be traversed by fine, stretched fibrils of the lamina fusca and lamina suprachoroidea. To the inner side of the choroid the retina was extensively detached and thrown into numerous folds, and the subretinal space was filled with an exudate similar to that beneath the choroid. The sclerotic coat gradually increased in thickness from about the orra serrata to the entrance of the optic nerve, on each side of which it measured between three and four mm.

Microscopically, one can make out in the sections of this globe no appreciable leucocytic infiltration of the tissues. The evidences are those of a mild passive congestion of the uveal tract: contraction of the arteries with moderate filling of the

veins, and well marked evidence of interstitial œdema. One finds only several layers of cells regularly deposited on the surface of the ciliary body with vascular spaces, the walls of which are formed by the cells themselves. This is apparently a low form of connective tissue, but no definite cicatricial bands can anywhere be made out. The retina, swollen, œdematous, and cystically degenerated, shows small hæmorrhages or marked diapedesis of red cells towards the subretinal space.

What I wish to emphasize in connection with this case is, that one has to do here with a passive rather than an active vascular disturbance; that, even if one grant that the low connective tissue described is the product of a true inflammation, it is insufficient to account for the macroscopical appearances which were typically those found in atrophia bulbi; and that, therefore, in this case one must look for some cause other than the contraction of fibrous tissue bands to account for the changes present.

Let me first meet the possible objection that the changes in this case were artificially produced during the hardening and sectioning of the globe by saying that, inasmuch as the eyeball was placed only in formalin for a few days and cut after freezing, this can hardly have been the case, as it is our general experience that one seldom, if ever, gets detachment of the coats in this way. The detachments were present from the first, and it was possible macroscopically to see that the newly-formed spaces were filled with morbid exudations. Further, that, while few in number, sufficient cells are present to denote an ante mortem diapedesis, and the pathological findings as a whole speak for such an occurrence.

The most plausible explanation in this case is found, I believe, if one presupposes a loss of vitreous as the starting point of the changes present. This may be said almost with certainty to have occurred, either through the corneal wound itself or through a ruptured hyaloid membrane into the anterior chamber, and to have immediately led to a sudden diminution of intraocular tension. The diminished tension was, in turn, followed by a detach-

ment of retina which took place, either immediately, or only later when the vitreous had still further diminished in bulk, under the influence of one or more of the following possible causes: a disturbance of the anatomical relations which made it impossible for the aqueous to refill its cavity; an impeded fluid interchange dependent upon an increase in the specific gravity of the aqueous from added albumins; or, an arrested secretion of aqueous, from passive congestion of the ciliary body, which cut off the fluid supply necessary to re-establish the bulk of the vitreous, and indirectly led to nutritional decay of whatever remained of this substance. The detachment of the retina was no doubt favored by the actual increase in weight of this structure, consequent upon the passive filling of its vessels which can be readily seen, and helped by the exudation which occurred into the subretinal space, as well from the retina as the engorged uveal tract.

As regards the detachment of the ciliary body and choroid, similar factors must have been at work. The increased weight of the vascular coat through congestion undoubtedly favored a sagging in the line of least resistance; an extravasation into the suprachoroidal lymph spaces, due in the first instance to œdema of the uveal tract and later on, as Greff has pointed out, to a deposition of fibrous tissue over the secreting surface of the ciliary body, helped along separation from the sclerotic; and dragging of the retina tended also in a purely mechanical way to bring about the detachment.

I think it is not unreasonable to conclude that some such factors were at work in this case, and that one has here for practical purposes an eyeball in which all the changes characteristically occurring in atrophia bulbi are present, but attributable, not to the contraction of fibrous tissue bands, but to the mechanical, secretory, and trophic changes I have mentioned.

If it be argued that one is not justified here in taking for granted a primary loss of vitreous, one must, as no fibrous tissue bands are present, fall back upon a theory of arrested secretion or primary degeneration to account for the diminution in bulk of

the vitreous. The only other possible explanation for the shrinkage is the view of Greff, that the retina and vitreous were "displaced" by the accumulating subretinal exudation. It is more likely, however, that the diminution of the vitreous preceded the subretinal exudation, as the latter would naturally only occur in the presence of the former. In either case one comes back to a purely mechanical or secretory view of the causation of the changes.

That the same factors are at work in addition to fibrous tissue bands in producing the morbid changes in atrophia bulbi, seems clear from a study of the following case of early plastic shrinkage of the globe: —

CASE 2. The case was that of a boy aged ten years, whose left eye, struck six weeks previously by a stone, was removed because its fellow had begun to show signs of irritation.

The specimen was handed to me in formalin without notes, but it was possible to make out a slanting wound of the cornea which extended downwards and inwards into the corneo-scleral margin from about the middle of the line of junction of the outer and middle thirds of the cornea.

On section, one could make out again the corneal scar with adherence of the outer half of the iris to its posterior surface, in other words, evidences of a previous perforation of the globe.

Under the microscope one sees in this eye a marked contraction of the arteries with extreme dilatation and engorgement of the veins of the whole uveal tract. The tissues, but slightly infiltrated with leucocytes, are, on the other hand, markedly œdematous; and hæmorrhages and diapedeses of red cells are common. The picture is that of a very marked passive congestion. One notices only a slightly-marked accumulation of leucocytes toward the pupillary margins of the iris, and a small amount of partially-organized fibrous tissue, containing a few leucocytes in its meshes, in and over the pupillary area. The retinal pigment epithelium of the whole anterior part of the uveal tract is increased in thickness, and a few pigment cells and leucocytes can be made out

along the margins of the same structure. A delicate band of connective tissue can be seen behind the lens and followed to the most anterior portion of the detached retina on one side where it is definitely adherent. Otherwise there are no fibrous tissue bands visible in the vitreous or other parts of the eye behind the iris. The subretinal space is filled with an exudation consisting largely of degenerated red blood cells, while a few white cells are seen in the dilated suprachoroidal clefts. The retina, swollen and degenerated, shows œdema and marked extravasation of red cells along its outer borders.

The one feature that calls for special notice here is the small, fibrous-tissue band mentioned above. In the photograph, this can be seen in broken continuity, extending from behind the lens to the retina and apex of the ciliary body which has been apparently detached by its contraction.

The question arises, however, if this delicate strand is really the cause of the separation, or if its deposition has not been determined by the anatomical relation of the parts; for, when one comes to the vitreous, other considerations arise. No fibrous tissue is present to account for its shrinkage, and, admitting that the contraction of the exudate caused the retinal detachment, the most that one can say is that the vitreous "shrank" after this occurrence. This, however, is no real explanation and one must go further to seek the cause of the degeneration. For a proper explanation one must look, I think, to the ciliary body. It is known now from abundant clinical, pathological, and experimental evidence, that this structure is responsible for the secretion of the aqueous and the life of the vitreous. Schirmer, as I have previously pointed out, has attributed atrophia bulbi and the hypotonia occurring in this condition, to a diminution in the secreting power of the ciliary body, which I believe he has clearly established. But I would go further than Schirmer and say that not only are the atrophia bulbi and hypotonia due to diminished intraocular secretion, but are to be traced as well to a nutritional degeneration of the vitreous consequent upon a disturbance of

the function of the ciliary body. I have mentioned in connection with my first case the possibility of an arrest of secretion from a continued congestion of a purely mechanical character. I am prepared to admit that this is open to question, but about the possibility of such an occurrence in inflammatory conditions there can be little doubt. Other factors too,— the disturbance of the anatomical relations of the parts favorable to a free interchange of fluid from a primary loss of vitreous, as so often occurs, increased specific gravity of the aqueous, and obstruction by connective tissue bands, undoubtedly also play a part, if a minor one, in bringing about the death of the vitreous.

Granting then a primary shrinkage, from causes which are, to say the least, highly probable, it is equally justifiable to think that the changes in this case occurred more or less in the same mechanical manner as that pointed out in connection with Case I., and that the fibrous tissue was laid down on parts already displaced.

A few other points need to be mentioned. It will be noticed in the micro-photograph that the displaced retina is directly drawing on the ciliary body, and it seems equally probable to me that this was, as much as the fibrous tissue band, the cause of the detachment. Another factor, namely, buckling of the sclerotic, has to be taken into consideration. This occurs as the result of the diminished intraocular tension and the pressure of the extrinsic muscles. In this case it has taken place at the periphery of the cornea, and in such a way that one can see that the ciliary body and choroid have in a purely mechanical way been pulled away from their attachments. In other cases the depression occurs behind the line of insertion of the recti muscles, but the effect produced upon the uveal coat is the same.

In conclusion I should like to say that I regret the weakness in this work which results from the absence of any examination of the corneal wound in my first case. The other half of the globe containing the adhesion was, however, unfortunately lost in the recent fire at McGill, at a time in the preparation of this

paper when I particularly wished to study the changes at that point. I felt also that more evidence might with advantage have been brought to the elucidation of my subject; but, as there seemed no immediate chance of my obtaining the necessary pathological material, I decided to read the paper as it is. The ideas are to a certain extent well grounded and may prove suggestive to others working in this field. For the sake of clarity they may again be briefly presented as follows:

Atrophia bulbi is not due solely to the contraction of fibrous tissue bands, but to several different causes. Chief among these is an inflammatory arrest of secretion from the ciliary body, which leads, not only as Schirmer has pointed out, to a diminution in the amount of the intraocular fluids, but, along with other less important factors, to a nutritional death of the vitreous.

Consecutive to shrinkage of the vitreous, the macroscopical changes observable in atrophia bulbi occur in a more or less purely mechanical way, and are attributable, in an indeterminable degree only, to the contraction of the fibrous tissue bands, the distribution of which, in this condition, is largely determined by the morbid arrangement of the parts.

REPORT OF THE COMMITTEE ON OPHTHALMIA OF INFANCY.

By Dr. L. HOWE, Chairman.

At the last meeting of this society a resolution was passed providing for the appointment of a committee on ophthalmia neonatorum. Just twenty years before that, a committee had also been appointed by this society, to investigate the apparent increase in blindness in the United States, and consequently that which was produced by that disease. It is therefore fitting for the society now to ask:

First: What has been accomplished by calling attention at that time to the importance of that disease and its prevention?

Second: What is now being done to prevent or to cure it?

Third: Of the different plans or methods suggested for that purpose which is the most important?

The first result of the inquiry initiated by this society was legislation for the prevention of blindness. This legislation was inaugurated in the state of New York, the first law being an amendment to the penal code. That proved imperfect, and later the phraseology was adopted which corresponded more nearly to the law which had meanwhile been passed in Maine, and in some other states. The general form of this law is as follows:

Section 1. Should one or both eyes of an infant become reddened or inflamed within ten days after birth, it shall be the duty of the midwife, nurse, or other persons having charge of said infant, to report the condition of the eyes at once to some legally qualified practitioner of medicine of the city, town or district in which the parents of the infant reside.

Section 2. Any failure to comply with the provisions of this act shall be punishable by a fine not to exceed one hundred dollars, or imprisonment not to exceed six months, or both.

Section 3. This act shall take effect on the . . . day of . . . .

Substantially this same law has been passed, as nearly as this committee can ascertain, in Maine, Rhode Island, Massachusetts, Pennsylvania, Minnesota, Ohio, Maryland, Michigan, Connecticut, Missouri, Iowa, Illinois and New Jersey. According to this it exists in at least fifteen states, whose population is a little more than 38,000,000. This is the first immediate result of the agitation inaugurated by this Society.

One objection urged against this law is the apparent difficulty of enforcing it. That depends, however, upon the promptness and vigor of the person or of the society which brings the complaint, and on the honesty of the local district attorney. The fact is, that shortly after the passage of the law in New York, four well known convictions were obtained in Kings county alone, and there were others elsewhere in that state. In most of these cases the ophthalmic surgeon simply reported the case to the agent of the Society for the Prevention of Cruelty to Children, and that Society followed up the District Attorney in the prosecution.

Another apparent objection to the law is that even when midwives or nurses have been found guilty they have often been let off with slight punishment or under suspended sentence. But the fact is that even the arrest of a midwife often does more to educate other midwives and nurses concerning their duties in these cases, than all the books, pamphlets, lectures, and similar means combined.

The greatest value of such legislation consists probably in its educative effect on the public. When the eyes of a new born child are only slightly reddened or inflamed and the nurse informs the parents that a law exists compelling her to report that fact in writing to some physician, those parents are fortunately at once alarmed. They recognize the existence of a condition which threatens the child's vision. They are not only more ready to call for a physician, but to listen to his directions, and to carry them out as they would not otherwise.

That mental attitude of the parents is a greater source of hope for the child's recovery than anything else. These laws may therefore be considered the first and also the most important step taken in the campaign against ophthalmia of infancy.

A second result of the movement inaugurated by the society, and an immediate result probably of the legislation, has been an apparent decrease in the number of cases of ophthalmia of infancy.

In order to ascertain the comparative frequency of these cases before the passage of the law in Greater New York, for example, and subsequently, the statistics were gathered of 112,560 dispensary cases treated previous to 1891 at the Manhattan Eye and Ear Hospital, the New York Ophthalmic and Aural Institute and at the Brooklyn Eye and Ear Infirmary. Among these there were 583 cases of ophthalmia of infancy, that is to say 0.51%. On the other hand, among 132,448 eye cases which were treated at these same institutions from 1904 to 1907 inclusive, 419 suffered from that disease, in other words 0.31%. While it is true that statistics of this kind cannot be relied upon implicitly, it is probable that the data are sufficiently accurate to indicate roughly, at least, the important fact that ophthalmia of infancy is not as common, at least in greater New York, as it was before this law was passed. It would not be surprising if some decrease were also shown by similar statistics from large hospitals in other states, even where that law has not been passed, because the medical profession and the public is being gradually educated concerning the necessity of prompt and efficient prophylaxis. It is only fair to add that at some of the schools or asylums for the blind, the proportion of children reported as having lost their sight from this disease is about the same now as ten or fifteen years ago. But it should be remembered that it is often impossible to determine the causes of blindness among those young persons. When a child at such a school has an opaque cornea, or perhaps only a shrunken globe on each side, we are apt to suspect ophthalmia of infancy as the cause. Many

of these pupils when questioned assert that they were blind since infancy. But more careful questioning, or the testimony obtained directly from the parents, sometimes shows that the inflammation which destroyed the vision was not ophthalmia of infancy. It is certain that this error in assigning the proper cause has occurred in some cases.

Another source of error in statistics of this kind is the uncertainty concerning the ratio of the total number of pupils to the total population in a given locality. Thus if the population in a given state has greatly increased, while the total number of blind remains about the same, evidently the percentage of blind from each disease,— for example, from ophthalmia of infancy — might really decrease, whereas the proportion of those blind from that disease in that school might remain practically the same.

In spite of such figures from schools of the blind, apparently the frequency of ophthalmia of infancy is gradually decreasing.

Concerning the next phase of our subject — namely, the efforts now being made for combating ophthalmia of infancy — this consists in a recent revival of the entire question concerning this disease, which has been brought about by legislation in different states relating to the education of the blind. Also in the formation, in the American Medical Association, of a committee on ophthalmia neonatorum. As early as 1893, two years after the committee of this society made its report, the legislature of Connecticut established a Board of Education of the Blind. Then after a lapse of ten years or more, similar laws were passed in other states — by Michigan and Wisconsin in 1903, by Rhode Island in 1904-1906, by Massachusetts in 1906, and by Maine, Delaware, Colorado and New York in 1907. These laws were partly for the education and employment of the blind, and in some states the subject was left in charge of a special commission. The most important result obtained however was not the education or employment of those already blind, but by thus calling attention to the principal causes of blindness, to indicate the importance of measures for the prevention of ophthalmia of infancy.

Another effort in this direction is a plan recently adopted by the American Medical Association for combating that disease. This promises to give excellent results.

In 1906 a resolution was introduced in the section of ophthalmology providing for the appointment of a special committee on ophthalmia neonatorum, to consist of "at least one ophthalmologist, one obstetrician, and one sanitarian, with the invited co-operation of a sub-committee consisting of the president and secretary of each state association, to formulate and make effective the details of a plan that may give uniform legislation and definite instruction to the profession and laity concerning the prevention and treatment of this disease." This committee, consisting of Drs. F. Park Lewis, J. Clifton Edgar, and F. F. Wesbrook, reported at the meeting of the association last year and again last month showing that the details of a plan are being gradually perfected.

According to the last report that committee considers that "In its ultimate analysis the solution of the problem would seem to lie not primarily in coercion, but in guidance." The manner in which this would be accomplished they consider should be by —

Registration of (*a*) birth (*b*) midwives (*c*) physicians. By education. (*a*) midwives (*b*) mothers (*c*) medical profession. By preparedness. (*a*) proper dissemination of a prophylactic. By co-operation. (*a*) united and concerted action in carrying these provisions into effect.

A second organization which has become interested in this subject is the American Academy of Ophthalmology and Oto-Laryngology. At its last meeting, the report of a committee was adopted recommending that ophthalmia neonatorum be legally recognized as a contagious disease, by placing it under the authority of the Department of Health in each state; and making it the duty of such department to adopt regulations to secure prophylaxis and treatment, to take steps for education regarding it, and where necessary, to furnish remedies for it. Under such

laws the legal recognition of this disease as one of the contagious diseases would not be without educative value; and where the health authorities could be aroused to take an active interest, effective measures could be adopted and enforced.

Finally, we inquire what is after all the best method of combating this disease. At the first glance it might appear that here, as elsewhere, prevention is better than cure. But as the former is now, and probably will be for many years, a practical impossibility under all circumstances, and as so much depends upon the promptness in any treatment which is used, we are forced to the conclusion that, taking all in all, the law compelling nurses of all kinds to report these cases practically at once to some legally qualified practitioner, is the most effective method at our command. But very few, if any, of these laws have been added to the statute books for several years, and as we have seen, this phase of the subject is not one to which much attention has thus far been given by the committee on ophthalmia neonatorum of the American Medical Association.

Probably we would all agree with that committee in considering guidance better than coercion when dealing with physicians individually, with the profession as a whole, or with the public. But we would also agree that coercion is necessary now and always in compelling nurses and midwives, whether registered or not, to report any symptoms of ophthalmia of infancy as soon as practicable after they develop. Then the all-important thing is promptness. That is as necessary as in an alarm of fire. Moreover, the surest way to secure that alarm is not by waiting to educate "the midwife, nurse or other person having charge of said child," but to have the strong hand of the law reach out to that person, whoever she may be, who trifles with the vision of an infant. The fear of arrest alone does more toward the education of the midwives and nurses than any other single effort. Concerning this phase of the subject this committee therefore concludes, that among the different plans suggested for combating ophthalmia of infancy, the most effective is to enforce laws

which already exist in different states compelling midwives to report these cases, and also to obtain similar laws in other states.

This conclusion is not advanced as a recommendation which would interfere with the plan of the committee of the American Medical Association. In any such efforts by different organizations co-operation is necessary, wherever that can be accomplished. Therefore this committee does not advise any action by this society at present, except thus to show the advantage of the legislation referred to. But it does seem proper for this society to acquaint itself thus with the most recent and best methods for combating a disease which still produces more blindness than any other, and to show a readiness to co-operate, if desired, through a committee in the further advancement of a movement which originated here. Therefore this committee presents this brief statement of progress in the work assigned to it, and asks for more time to contine its study, or to co-operate as may seem advisable, in efforts to lessen, as much as possible, the blindness from ophthalmia of infancy.

LUCIEN HOWE
EDWARD JACKSON
PETER A. CALLAN

VOL. XI.—INDEX.

INDEX OF SUBJECTS.

PAGE

Silver preparations in conjunctival disease; Dr. Myles Standish, . 16
Silver preparations, experimental study on bactericidal power of various; Dr. G. S. Derby, ... 21
Immersion treatment with argyrol of purulent ophthalmias; Dr. H. Bruns, ... 28
Panophthalmitis following removal of nasal epithelioma; Dr. P. Callan, ... 57
Enucleation eyeball under cocaine anesthesia; Dr. H. Bruns, . 62
Nystagmus — unilateral, rotary; Dr. A. Duane, ... 63
Tangent plane for mapping scotomata; Dr. A. Duane, . . . 67
Tumor of pituitary body, ocular symptoms in; Dr. Hansell, . . 71
Keratitis tuberculosa relieved by tuberculin injections: Dr. Ziegler, 78
Retinal signs of persistent high arterial tension, etc.; Dr. de Schweinitz, ... 87
Retinitis proliferans with development of blood vessels on optic nerve; Dr. Marple, ... 101
Cyst of orbit (congenital) with microphthalmos; Dr. Quackenboss, 106
Multiple myeloma involving orbit; Dr. Quackenboss, . . . 113
Myopia (transient) due to trauma; Dr. Pooley, ... 120
Cataract — study of 3,436 cases operated on at Wills Hospital; Dr. Oliver, ... 123
Microphthalmos with upper lid cyst — pathological report on May's case; Dr. Holden, ... 130
Siderosis bulbi; Dr. Kipp, ... 132
Invagination cyst cornea and anterior chamber; Dr. Kipp, . . 149
Extraction cataract in capsule; Dr. Cheney, ... 153
Extraction cataract in capsule in cases of immature cataract; Dr. Standish, ... 165
Cyclitis, course and treatment of simple; Dr. E. S. Thomson, . 170
Hypernephroma of iris and ciliary body; Dr. Chance, . . . 178
Sarcoma of choroid — remarks on transillumination; Dr. Marple, . 193
Bacillus pyocyaneus, ulceration and destruction of cornea by; Dr. Callan, ... 201
Bacillus pyocyaneus — virulence in eye — longevity, etc.; Dr. Ewing, 204
Optic neuritis after injury or disease of anterior half eyeball; Dr. A. Knapp, ... 215
Squint — case of inward and downward — in *near* vision — with binocular fixation and normal muscle balance in *distant* vision; Dr. Theobald, ... 218
Polio-encephalitis superior, cases of; Dr. Holden, ... 220
Electric ophthalmoscope, an improved; Dr. Marple, ... 225
Plexiform neuroma of orbit; Dr. H. Knapp, ... 229
Steel in eyeball — Haab magnet failed to remove; Dr. Taylor, . 230
Frontal sinus disease, modern operation in; Dr. Gruening, . . 234

PAGE

Bacteriological examinations of conjunctival sac in typhoid fever; Dr. Randolph, ... 238
Dislocation both lenses, congenital; Dr. Risley, ... 248
Gonococcal conjunctivitis, value of systematic bacteriologic and microscopic study in the treatment of; Dr. Oliver, . . . 263
Perivasculitis retinae; Dr. Oliver, ... 265
Vasculitis and perivasculitis; Dr. de Schweinitz, ... 270
Conjunctivitis, recurrent, produced by animals; Dr. Risley, . . 279
Cornea in normal eyes, congenital inequality of size in; Dr. Hubbell, 290
Sarcoma of corneal limbus; Dr. Veasey, ... 282
High myopia, removal of lens in; Dr. Lambert, ... 293
Glaucoma, simple chronic-post-operative, history of sixty cases; Dr. Bull, ... 300
Glaucoma, acute inflammatory, without excavation of the papilla; Dr. Pusey, ... 309
Proliferative uveitis; Dr. Zentmayer, ... 313
Retinitis proliferans in a detached retina; Dr. Shoemaker, . . 320
Ocular muscle balance — a simple method of representing by diagram; Dr. Howe, ... 326
Congenital cataract, unusual form of hereditary congenital; Dr. Chance, ... 334
Vascular changes in uveal tract — retina and optic nerve in quinine blindness and tobacco-alcohol amblyopia; Dr. de Schweinitz, 337
Optic nerve, affections of during pregnancy; Dr. A. Knapp, . 359
Cyanotic polycythemia, chronic; Dr. Jackson, ... 363
Intra-ocular tuberculosis simulating glioma of retina; Dr. Theobald, 369
Intra-ocular tuberculosis, two cases of supposed; Dr. Cutler, . . 371
Perforation (double) of eyeball by iron and steel; Dr. Sweet, . 388
Perforation (double) of eyeball by foreign body — removal — normal vision; Dr. Lambert, ... 401
Foreign body in fundus — extraction by magnet — complete post-operative aniridia — recovery; Dr. Woods, ... 402
Eye-strain, interesting cases of; Dr. Spalding, ... 406
Unilateral nystagmus; Dr. Verhoeff, ... 416
Position of the ophthalmologist in the treatment of diseases of the accessory sinuses of the nose; Dr. Posey, ... 421
Cataract (acquired) in childhood; Dr. Hansell, ... 430
Exophthalmus — pulsating — ligation common carotid — death; Dr. Jack, ... 439
Glaucoma — secondary — in curious case of keratitis; Dr. Risley, . 447
Trial frame; Dr. Wilmer, ... 452
Central artery of the retina, sudden obstruction of; Dr. de Schweinitz, ... 471
Embolism of a macular artery and thrombosis of other retinal arteries in a case of embolic softening of brain; Dr. W. T. Shoemaker, ... 502
Angioma of the orbit with invasion of globe along the ciliary nerves; Dr. A. Quackenboss, ... 510
Macular holes; Dr. C. J. Kipp, ... 518
Symblepharon — corneal opacities and a probably fibro-fatty tumor of the conjunctiva of pre-natal origin in a woman with hereditary cataracts at an early age; Dr. B. Chance, ... 528
Cyanosis retinae; Dr. H. H. Tyson, ... 531
Grill-like keratitis; Dr. C. J. Kipp, ... 537
Tuberculosis as a cause of ocular disease; Dr. G. S. Derby, . . 540
Angioma of the choroid; Dr. A. Quackenboss, ... 557

PAGE

Nystagmus, teleology and interpretation of; Dr. P. Fridenberg, . 562
Sympathetic ophthalmia, two cases; Dr. E. S. Thomson, . . . 575
Keratitis, diffuse interstitial, in acquired syphilis; Dr. J. T. Carpenter, 581
Erosion of cornea, recent traumatic; Dr. R. J. Curdy, . . . 594
Thyroid extract in keratitis; Dr. McCluney Radcliffe, . . . 597
Immature cataract, treatment of; Major Henry Smith, . . . 603
Cataract, extraction of, with lance-shaped knife; Dr. J. H. Claiborne, ... 618
Normal range of accommodation, attempt to determine, at various ages; Dr. A. Duane, ... 634
Relative accommodation, clinical measurement of; Dr. L. Howe, . 642
Use of prisms, some practical points in; Dr. B. L. Millikin, . . 650
Strabismus from the operative standpoint; Dr. P. A. Callan, . . 665
Ptosis, simplification of De Grandmont's operation for; Dr. S. Theobald, ... 673
Glaucoma, restoration of sight after a month's blindness from; Dr. J. L. Minor, ... 678
Optic neuritis (bilateral) after ethmoiditis; Dr. A. Knapp, . . 681
Ocular affections associated with disease of the sinuses contiguous to the orbit; Dr. S. D. Risley, ... 685
Infections of the orbit and adjacent sinuses — mixed streptococcus and staphylococcus; Dr. C. S. Bull, ... 695
Hemorrhage from cornea; Dr. T. R. Pooley, ... 715
Adeno-carcinoma of orbit; Dr. T. R. Pooley, ... 718
Blepharo-conjunctivitis caused by diplococcus of Morax-Axenfeld; Dr. Brown Pusey, ... 722
Shrinkage of eyeball, description of cases of, with remarks on the processes underlying atrophia bulbi in general; Dr. W. G. M. Byers, ... 731
Report committee on ophthalmia neonatorum; Dr. L. Howe, . . 741

INDEX OF AUTHORS.

Bruns, H. The immersion treatment with argyrol of the purulent ophthalmias, ... 28
Preliminary note on enucleation of eyeball under cocaine, . . 62
Bull, C. S. Post-operative history of sixty cases of simple chronic glaucoma, ... 300
Mixed streptococcus and pneumococcus infections of the orbit and adjacent sinuses, ... 695
Byers, W. G. M. Description of cases of shrinkage of the eyeball, with remarks on the processes underlying atrophia bulbi in general, ... 731
Callan, P. Operation for removal of nasal epithelioma followed by panophthalmitis, ... 57
Strabismus from the operative standpoint, ... 665
Ulceration and destruction of cornea by bacillus pyocyaneus, . 201
Carpenter, J. T. Diffuse interstitial keratitis in acquired syphilis, 581
Chance, Burton. Case of secondary hypernephroma of iris and ciliary body, ... 178
Unusual form of hereditary congenital cataract in several members of a family, ... 334
Case showing symblepharon, corneal opacities and a probably fibro-fatty tumor of conjunctiva, all of pre-natal origin in a woman with hereditary cataracts at an early age, . . 528

PAGE

Cheney, F. E. Extraction of cataract in the capsule, ... 153
Claiborne, J. H. Extraction of cataract with lance-shaped knife, . 618
Cutler, C. W. Two cases of supposed intraocular tuberculosis, . 371
Curdy, R. J. Recent traumatic erosion of the cornea, . . . 594
Derby, G. S. Experimental study on the bactericidal power of various silver salts, ... 21
The increasing importance of tuberculosis as a cause of ocular disease, the newer methods of diagnosis and the treatment, . 540
Duane, A. A tangent plane for accurately mapping scotomata and the fields of fixation and single vision and for indicating the precise position of double images in paralysis, ... 67
Unilateral rotary nystagmus, ... 63
An attempt to determine the normal range of accommodation at various ages, being a revision of Donder's experiments, . . 634
Ewing, A. Bacillus pyocyaneus, its virulence in the eye, its longevity and immunity from it, ... 204
Fridenberg, P. The teleology and interpretation of nystagmus, . 562
Gruening, E. The modern operation in frontal sinus disease affecting the orbit, with two cases, ... 234
Hansell, H. F. Acquired cataract in childhood, ... 436
The ocular symptoms in a case of tumor of the pituitary body, . 71
Holden, Ward A. Pathological report on Dr. May's case of microphthalmos with upper lid cyst, ... 130
Report of cases of polio-encephalitis superior, ... 220
Howe, L. The clinical measurement of relative accommodation, . 642
A simple method of representing ocular-muscle imbalance by diagram, ... 326
Report of committee on ophthalmia neonatorum, ... 741
Hubbell, A. A. Congenital inequality of the size of the cornea in normal eyes, ... 290
Jack, E. E. Pulsating exophthalmus — ligation common carotid — death, ... 439
Jackson, E. Chronic cyanotic polycythemia, ... 363
Kipp, C. J. Case of grill-like keratitis, ... 537
Macular holes, ... 518
Concerning siderosis bulbi, ... 132
Case of invagination cyst of the cornea and of anterior chamber, 149
Knapp, A. Optic neuritis after injury or disease of the anterior half of the orbit, ... 215
Bilateral optic neuritis after ethmoiditis, ... 681
Affections of the optic nerve during pregnancy, ... 359
Knapp, H. Plexiform neuroma of orbit, ... 229
Lambert, W. E. Double perforation eyeball by foreign body, removal with preservation of normal vision, ... 401
Removal of lens in high myopia, ... 293
Marple, W. B. Retinitis proliferans with development of a system of blood-vessels upon the optic nerve, ... 101
Case of sarcoma of choroid with observation on the use of the transilluminator, ... 193
An improved electric ophthalmoscope, ... 225
Millikin, B. L. Some practical points in the use of prisms, . . 650
Minor, J. L. Restoration of sight after nearly a month's blindness from glaucoma, ... 678
Oliver, C. A. Perivasculitis retinae, ... 265
The value of systematic bacteriologic and microscopic study in treatment of gonococcal conjunctivitis, ... 263

PAGE

A study of the nativity, sex, age, occupation and social condition of 3436 cases of senile cataract operated on at the Will's Hospital in Philadelphia, ... 123
Pooley, T. R. Hemorrhage from the cornea in glaucoma, . . 715
Adeno-carcinoma of orbit, ... 718
Transient myopia due to trauma, ... 120
Posey, W. C. Position of the ophthalmologist in the treatment of diseases of the accessory sinuses of the nose, ... 421
Pusey, Brown. Blepharo-conjunctivitis caused by diplococcus of Morax-Axenfeld, ... 722
Acute inflammatory glaucoma without excavation of the papilla, 309
Quackenboss, A. Angioma of orbit with invasion of globe along the ciliary nerves, ... 510
Multiple myeloma without involvement of orbit, ... 113
Angioma of choroid, ... 557
Radcliffe, McCluney. Thyroid extract in keratitis, ... 597
Randolph, R. L. Bacteriological examination of the conjunctival sac in typhoid fever and in pneumonia, ... 238
Risley, S. D. Ocular affections associated with diseases of the sinuses contiguous to the orbit, ... 685
Case of congenital dislocation of both lenses. Attempted removal by absorption resulting in failure followed by extraction, . 245
Secondary glaucoma in a curious case of keratitis, ... 447
Recurrent conjunctivitis produced by animals, ... 279
De Schweinitz, Geo. E. Vascular changes in uveal tract, retina and optic nerve in quinine blindness and in tobacco-alcohol amblyopia, ... 337
Sudden obstruction of central artery of retina, being a clinical record of five cases, ... 471
Concerning the signs in the retina of persistent high arterial tension and their diagnostic and prognostic import, ... 87
Vasculitis and perivasculitis, ... 270
Shoemaker, W. T. Embolism of a macular artery and thrombosis of superior and inferior retinal arteries in a case of embolic softening of the brain, ... 502
Retinitis proliferans in a detached retina, ... 320
Spalding, J. A. Interesting cases of eye strain, ... 406
Smith, Major Henry. Treatment of immature cataract, ... 603
Standish, Myles. Silver preparations in conjunctival disease, . 16
Extraction of cataract in capsule as a method of procedure in cases of immature cataract, ... 165
Sweet, W. M. Double perforation of the eyeball by iron and steel, 388
Taylor, L. H. Cases of steel in eyeball which Haab magnet failed to remove, ... 230
Theobald, S. A simplification of De Grandmont's operation for ptosis, ... 673
Intraocular tuberculosis simulating glioma of retina, . . . 369
Case of pronounced inward and downward squint in *near* vision with binocular fixation and normal muscle balance in *distant* vision, ... 218
Thomson, E. S. Two cases of sympathetic ophthalmia, ... 575
Course and treatment of simple cyclitis, ... 170
Tyson, H. H. Cyanosis retinae, ... 531
Verhoeff, F. H. Case of unilateral nystagmus, ... 416
Veasey, C. A. Sarcoma of corneal limbus, ... 282
Wilmer, W. H. A new trial frame, ... 452

PAGE

Woods, H. Foreign body in fundus — extraction by magnet — complete post-operative aniridia — recovery, ... 402
Ziegler, S. Lewis. Keratitis tuberculosa relieved by tuberculin injections, ... 78
Zentmayer, W. Proliferative uveitis, ... 313

J. HOLZER,
BINDER,
BOSTON, MASS.